

## Medical Screening Questionnaire And Examination Record

Surname: <b>TAMBOK PARSALIAN N.</b>		Forenames:	
Address:			Tel No: <b>0813-644-30275</b>
Date of Birth: <b>27 JULY 1974</b>		GP's Name:	
GP's Address:			
Date of Last Offshore Medical:		Offshore Occupation/Job Title :	
Emergency Response Role :			
Social / Occupational History			
(1)	Do you smoke? If so, how many per day?	Yes	No
		✓	
(2)	If an ex-smoker, when did you give up?		
(3)	Average weekly alcohol consumption: state quantity and type.		✓
(4)	Have you been exposed to any known occupational hazard such as noise, radiation, dusts, asbestos, chemicals or lead?	✓	
(5)	Do you use protective clothing, safety glasses or hearing protection?	✓	
(6)	Have you ever developed any medical condition in connection with your occupation? If so, please give details eg hearing loss/skin condition/wheeze/backache/muscle strain/blood disease?		✓
(7)	Have you suffered any industrial injury? If so, please give details:		✓
(8)	Have you ever had any previous audiometric screening? Was this normal? State when and where.		
(9)	Have you ever had any previous lung function screening? Was this normal? State when and where.		
(10)	Have you ever been rejected from employment on medical ground?		✓
(11)	Have you ever received compensation, or is there any industrial claim pending?		✓
(12)	Have you ever been medivaced from an offshore installation?		✓
<b>Examining Physician's comments :</b>			

\* Source : Medical Aspects of Fitness for Work Offshore Guidance for Examining Physicians Oil & Gas UK, March 2008



## Medical Screening Questionnaire And Examination Record (cont'd)

### Medical Examination

*To Be Completed By Examining Physician*

<b>Photographic ID :</b>	Passport number :	
	Driver's license number :	
	Other :	

Height	Weight	BMI	BP	Pulse	FEV <sub>1</sub>	FVC	FEV <sub>1</sub> /FVC	Urinalysis		
								Protein	Blood	Glucose
171 cm	80.4 Kg	27.49 kg/m <sup>2</sup>	120/80 mmHg	58 x/ min	2.77 L	3.23 L	85.76 %	(-)	(-)	(-)

Vision Distance			Vision Near			Colour		VDU
L	Aided L	Both	L	Aided L	Both	Normal	Abnormal	
20/25			J3			✓		
20/30			J3			✓		


	Normal	Abnormal	Comments
Audiometric Screening	✓		
Substance Abuse Screening	✓		
Stool Culture (Catering Crew)			
<b>Further investigations</b>			
Blood tests		✓	Hypertriglyceridemia, hyperuricemia
Chest X-Ray	✓		
Electrocardiograph (ECG) / Treadmill	✓		
Spirometry	✓		
USG		N/A	

\* Source : Medical Aspects of Fitness for Work Offshore Guidance for Examining Physicians Oil & Gas UK, March 2008

### Medical Screening Questionnaire And Examination Record (cont'd)

	Normal	Abnormal	Comments
1. Eyes/pupils	✓		Radix, missing, decayed and calculus teeth
2. Ear, nose and throat	✓		
3. Teeth		✓	
4. Lungs/chest	✓		
5. Cardiovascular	✓		
6. Abdomen	✓		
7. Hernial orifices	✓		
8. Genitourinary	✓		
9. Musculoskeletal	✓		
10. Skin	✓		
11. Varicose veins	✓		
12. Neurological	✓		
<b>Physician to comment on any abnormalities :</b>			

Certification	Comment/Reason
Fit for offshore work as per Oil & Gas UK guidelines	✓
Fit for restricted offshore work following discussion with operating company's medical adviser	
Temporarily unfit for offshore work	
Permanently unfit for offshore work	

Physician's signature : 

Print name : **PT. KARTIKA BINANDITA** dr. Kartika Binandita, Manteg

Date of examination : 29/4/2019

\* Source : Medical Aspects of Fitness for Work Offshore Guidance for Examining Physicians Oil & Gas UK, March 2008

## Unrestricted Offshore Work Certificate

### Medical Certificate of Fitness for Offshore Work

( Issued in accordance with Oil and gas UK Guidelines )

<b>Name :</b>	TAMBOK PARSAULIAN NAPITUPULU
<b>Date of Birth :</b>	27 July 1974
<b>Employing Company Name :</b>	INSPEKTINDO SINERGI PERSADA
<b>Occupation :</b>	INSPECTOR
<p>This individual has been examined in accordance          with Oil &amp; Gas UK Guidelines and is  <b>Medical Fit for Unrestricted To The Job Described At Offshore Work</b></p>	
<b>Examining Physician Name :</b>	dr. Frans Denis Martogi
<b>Oil &amp; Gas UK PIN No. :</b>	OGUK/2017/2465
<b>Date of Examination :</b>	29 April 2019
<b>Date of Expiry of Certificate :</b>	29 April 2021
<b>Signed :</b>	

  
**PT. KARTIKA BINA MEDIKATAMA**

## TO WHOM IT MAY CONCERN

### *Kepada yang berkepentingan*

This is certify that today Monday, 29 April 2019 Medika Plaza Clinic has performed urine drug screening and/or breath alcohol test to :

*Dengan ini menyatakan bahwa, pada hari ini Senin, 29 April 2019 Medika Plaza Clinic telah melakukan urine drug screening dan/atau breath alcohol test kepada :*


### **TAMBOK PARSAULIAN NAPITUPULU**

With the results are as follows :

*Dengan hasil sebagai berikut :*

Drugs Test <i>Uji Obat</i>	Result <i>Hasil</i>		
<b>URINE DRUGS SCREENING</b>			
- Amphetamine	<input type="checkbox"/> Non-Negative	<input checked="" type="checkbox"/> Negative	<input type="checkbox"/> N/A
- Met-Amphetamine	<input type="checkbox"/> Non-Negative	<input checked="" type="checkbox"/> Negative	<input type="checkbox"/> N/A
- Cocain	<input type="checkbox"/> Non-Negative	<input checked="" type="checkbox"/> Negative	<input type="checkbox"/> N/A
- THC/Canabis/Marijuana	<input type="checkbox"/> Non-Negative	<input checked="" type="checkbox"/> Negative	<input type="checkbox"/> N/A
- Morphine/Opiates	<input type="checkbox"/> Non-Negative	<input checked="" type="checkbox"/> Negative	<input type="checkbox"/> N/A
- P C P/Phencyclidine	<input type="checkbox"/> Non-Negative	<input type="checkbox"/> Negative	<input checked="" type="checkbox"/> N/A
- Barbiturate	<input type="checkbox"/> Non-Negative	<input checked="" type="checkbox"/> Negative	<input type="checkbox"/> N/A
- Benzodiazepin	<input type="checkbox"/> Non-Negative	<input checked="" type="checkbox"/> Negative	<input type="checkbox"/> N/A
- Methadone	<input type="checkbox"/> Non-Negative	<input checked="" type="checkbox"/> Negative	<input type="checkbox"/> N/A
- Propoxyphene	<input type="checkbox"/> Non-Negative	<input type="checkbox"/> Negative	<input checked="" type="checkbox"/> N/A
- Oxycodone	<input type="checkbox"/> Non-Negative	<input type="checkbox"/> Negative	<input checked="" type="checkbox"/> N/A
- MDMA	<input type="checkbox"/> Non-Negative	<input checked="" type="checkbox"/> Negative	<input type="checkbox"/> N/A
- 6-MAM	<input type="checkbox"/> Non-Negative	<input type="checkbox"/> Negative	<input checked="" type="checkbox"/> N/A
<b>BREATH ALCOHOL TEST</b>			
- Alcohol	<input type="checkbox"/> Non-Negative	<input checked="" type="checkbox"/> Negative	<input type="checkbox"/> N/A

Jakarta, April 29, 2019

  
 PT. KARTIKA BINA MEDIKATAMA  
 ( dr. Esther Poerwantoro, Sp.PK )  
 Clinical Patologist

# **HEALTH ASSESSMENT REPORT**

*of*

**TAMBOK PARSAULIAN NAPITUPULU**  
**01022516**

**Monday, 29 April 2019**

## **MP BELTWAY CLINIC**

Beltway Office Park, Annex Building, Ground Floor  
Jl. TB. Simatupang Kav.41, Jakarta Selatan 12550  
Tlp :(62-21) 808 66 099, Fax :(62-21) 808 66 098  
[www.medikaplaza.com](http://www.medikaplaza.com)

## MP BELTWAY CLINIC

Beltway Office Park, Annex Building, Ground Floor  
Jl. TB. Simatupang Kav.41, Jakarta Selatan 12550  
Tlp : (62-21) 808 66 099, Fax : (62-21) 808 66 098  
www.medikaplaza.com

### PATIENT DATA

MedRec.	: 01022516	EMPLOY. STATUS	: Employee
NAME	: TAMBOK PARSAULIAN NAPITUPULU	BIRTHDATE	: 27 July 1974
EMPLOYEE No.	: -	SEX	: Male
JOB TITLE	: INSPECTOR	STATUS	: Married
COMP. NAME	: INSPEKTINDO SINERGI PERSADA	NASIONALITY	: Indonesia

### SUMMARY


#### MEDICAL FINDING :

1. Hypertriglyceridemia
  2. Hyperuricemia
  3. Overweight
  4. Radix, missing, decayed, and calculus teeth
  5. Decreasing of visual acuity of both eyes
- Your fitness status is fit for unrestricted to the job described at offshore work.

#### SUGGESTION :

1. Low fat and carbohydrate diet, exercise regularly minimal 3 times a week.
2. Low purine diet such as meats including organ meats, alcoholic beverages, beans, shrimp, scallops, some vegetables in limited amount such as: spinach, cauliflower, asparagus and mushroom
3. Reduce body weight gradually 0.5 Kgs/week, by doing regular exercise (aerobic/jogging), 3-4x/week, 30-45 minutes and reduce high calorie diet until maximal body weight is 73.10Kgs (present body weight is 80.4Kgs). See a Clinical Nutrition Specialist for evaluation of Overweight
4. See a dentist for dental care, minimal once a year or better once in six month
5. You need to wear the glasses for both vision

#### Responsible Doctor



Restu Natasya Fachrini, MD

#### Notes:

If you need the further information or consultation, please contact us via :

Email : - beltway.doctor@medikaplaza.com  
- beltway.doctor2@medikaplaza.com  
Telepon Klinik : (62-21) 8086 6000



## CLINICAL EVALUATION

Name : TAMBOK PARSAULIAN NAPITUPULU	Sex : Male	MR : 01022516	Visit : 29/04/2019
Comp. : INSPEKTINDO SINERGI PERSADA		DOB : 27 July 1974	
EXAMINATION	RESULT	NOTES	

### ANAMNESA

#### PRESENT COMPLAINT AND HISTORY OF PRESENT

#### ILLNESS

Present complaint

No complaint

#### MEDICAL HISTORY

Alergy	No
Imunisasi	Yes
Surgery	No
Hospitalization	No
Disease	Yes

Bells palsy

#### LIFE STYLE

Alcohol intake	No
Smoking	Yes
Exercise	Yes

Moderate smoker

Swimming

#### FAMILY MEDICAL HISTORY

Diabetes Melitus	No
Hypertension	No
Heart disease	No
Lung TB	No
Kidney disease	No
Astma	No
Mental disease	No
Epilepsy	No
Cancer	No
Color blind	No
Stroke	No
Liver disease	No
Bone & joint	No
Others disease	No

#### WORK EXPOSURE

Noise	No
Heat Stress	No
Cold Stress	No
Vibration	No
Involving height	No
Radiation	No
Dust	No

## CLINICAL EVALUATION

Name : TAMBOK PARSAULIAN NAPITUPULU	Sex : Male	MR : 01022516	Visit : 29/04/2019
Comp. : INSPEKTINDO SINERGI PERSADA		DOB : 27 July 1974	

EXAMINATION	RESULT	NOTES
Toxic chemical	No	
Irritating fluid	No	
Smoke	No	
Bacterium/Virus/Parasite	No	
Blood	No	
Animal	No	
Operating heavy mobile equipment	No	
Manual Handling	No	
Sitting continuously over 4 hours	No	
Stand continuously over 4 hours	No	
Using monitor screen more than 4 hours per day	No	
Exposure	No	
Unergonomic body positions	No	
Shift work	No	
Work is not accordance with skills and knowledge	No	
Workload does not accordance with time	No	
Work conflict	No	
Inappropriate task	No	
Career barriers	No	
Family conflict	No	
Working around rotating machinery	No	
Administration work	No	
Handling food product	No	
Others	Yes	Offshore/onshore
<b>PHYSICAL EXAMINATION</b>		
General Appearance	Good	
Body shape	Athleticus	
<b>VITAL SIGN</b>		
Body Weight	80.4 Kg	
Body Height	171 Cm	
BMI	27.49 Kg/m <sup>2</sup>	
Normal Weight	54.10 - 73.10 Kg	
BMI Conclusion	Overweight	
Blood Pressure	120/80 mmHg	
Pulse	58 x/minute	
Body Temperature	36.4 °C	
RR	19	

## CLINICAL EVALUATION

Name : TAMBOK PARSAULIAN NAPITUPULU	Sex : Male	MR : 01022516	Visit : 29/04/2019
Comp. : INSPEKTINDO SINERGI PERSADA		DOB : 27 July 1974	

EXAMINATION	RESULT	NOTES
Neck Circumference	40 Cm	
Arm Circumference	35 Cm	
Chest size	98 Cm	
Abdominal Circumference	98 Cm	
<b>SKIN</b>		
Skin	Normal	
<b>EYE</b>		
Left	Normal	
Right	Normal	
<b>ENT</b>		
Auricle	Normal	
Ear canal	Normal	
Drums	Normal	
Septum/Conchae	Normal	
Sinuses	Normal	
Pharynx	Normal	
Tonsil	Normal	
<b>MOUTH</b>		
Gum	Normal	
Dental	Abnormal	Radix, missing, decayed, and calculus teeth
<b>NECK</b>		
General	Normal	
Thyroid Gland	Normal	
<b>CHEST</b>		
Form	Normal	
Lung	Normal	
Heart	Normal	
Breast	Normal	
<b>ABDOMEN</b>		
Form	Flat	
Palpation	Supple	
Liver	Not Palpable	
Spleen	Not Palpable	
Kidney	No Ballotment	
-	No	
Hernia inguinal	No	
<b>EXTRIMITIES</b>		

## CLINICAL EVALUATION

Name : TAMBOK PARSAULIAN NAPITUPULU

Sex : Male

MR : 01022516

Visit : 29/04/2019

Comp. : INSPEKTINDO SINERGI PERSADA

DOB : 27 July 1974

EXAMINATION	RESULT	NOTES
Bones, joint	Normal	
Muscles, tonus	Normal	
Fingernails	Normal	
Hand	Normal	
Foot	Normal	
<b>RECTAL EXAMINATION</b>		
Hemorrhoid	Negative	
Rectum	Normal	
<b>SENSORIK EXAMINATION</b>		
Tes Raba	Normal	
<b>MOTORIK EXAMINATION</b>		
Tes Grip	Normal	
<b>REFLEX EXAMINATION</b>		
Physiologic reflex	Normal	
Patologic reflex	Normal	
<b>OTHERS EXAMINATION</b>		
Coordination	Normal	
<b>LYMPHE SYSTEM</b>		
Submandibula	Normal	
Neck Gland	Normal	
Armpit gland	Normal	
Inguinal	Normal	

## OPHTHALMOLOGY DIAGNOSTIC

Name : TAMBOK PARSAULIAN NAPITUPULU	Sex : Male	MR : 01022516	Visit : 29/04/2019
-------------------------------------	------------	---------------	--------------------

Comp. : INSPEKTINDO SINERGI PERSADA	DOB : 27 July 1974
-------------------------------------	--------------------

EXAMINATION		Right	Left
Reading		-	
Previous Glasses		-	-
Without Glasses	Distant	20/30	20/25
	Near	J3	J3
Correction	Distant	-	-
	Near	-	-
Depth Perception		-	
Tonometry		-	-
Funduscopy		-	-
Visual Fields		-	
Colour Blind Test		Normal	

Impression : Decreasing of visual acuity of both eyes

**RADIOLOGY DIAGNOSTIC****Name** : TAMBOK PARSAULIAN NAPITUPULU**Sex** : Male**MR** : 01022516**Visit** : 29/04/2019**Comp.**: INSPEKTINDO SINERGI PERSADA**DOB** : 27 July 1974**EXAMINATION****RESULT**

THORAX PA

No abnormality seen in both lungs.  
Normal bronchovascular markings in both hili.  
The heart is normal in size and shape.  
The mediastinum is not widened.  
Both sinus and diaphragms are good.  
No evidence of pleural effusion.

Impression

Normal chest.  
No evidence of specific process in both lungs.

## LABORATORY RESULT

Name : TAMBOK PARSAULIAN NAPITUPULU	MR : 01022516	Visit : 29/04/2019	#Lab : IN66622808218
Comp. : INSPEKTINDO SINERGI PERSADA	Sex : Male	DOB : 27 July 1974	
EXAMINATION	RESULT	NORMAL RANGE	

### HEMATOLOGI

ABO/Rh Typing "B" Rh(+) positive

#### Automated Blood Count

White Blood Cell (WBC)	8.3	3.8 - 11.0
Erythrocyte (RBC)	5.0	4.4 - 5.9
Haemoglobin	16.1	13.2 - 17.3
Hematocrit	46	40 - 52
Thrombocytes	295	150 - 440

#### MCV, MCH, MCHC

MCV	92	80 - 100
MCH	32	26 - 34
MCHC	34.8	32 - 36
ESR	13 *	0 - 10

#### Differential Count

Basophils	0	0 - 1
Eosinophil	4	2 - 4
Bands / Stab	4	3 - 5
Neutrophils	52	50 - 70
Lymphocytes	32	25 - 40
Monocytes	8	2 - 8

### BLD CHEMISTRY/LIPID PROFILE

Total Cholesterol	182	Normal/Desireable: <200 Borderline High: 200-239 High: >=240
HDL Cholesterol	39.7 *	Normal : >40 - <60 Low HDL : <40 Desireable : >=60
LDL Cholesterol	105	Optimal: <100 Near/Above Optimal: 100-129 Borderline High: 130-159 High: 160-189 Very High: >=190
Tryglicerides	188 *	Normal : <150 Borderline High: 150-199 High : 200-499 Very High : >=500

### BLD CHEMISTRY/KIDNEY FUNCTION

## LABORATORY RESULT

Name : TAMBOK PARSAULIAN NAPITUPULU	MR : 01022516	Visit : 29/04/2019	#Lab : IN66622808218
Comp. : INSPEKTINDO SINERGI PERSADA	Sex : Male	DOB : 27 July 1974	

EXAMINATION	RESULT	NORMAL RANGE
Ureum	24.6	10.0 - 50.0
Creatinine	1.3	0.6- 1.3
Uric Acid	7.9 *	3.5 - 7.2

### BLD CHEMISTRY/LIVER FUNCTION

SGOT(AST)	16	13 - 45
SGPT (ALT)	21	13 - 50
Alkaline Phosphatase	116	30 - 120
Gamma GT	33	0 - 50

### BLD CHEMISTRY/DIABETES

Glucose Fasting	88	< 100
Glucose Urine	Negative	Negative
Keton Urine	Negative	Negative

#### Blood Glucose 2 PP

Blood Sugar 2 Hours PP	102	< 140
Glucose Urine	Negative	Negative
Keton Urine	Negative	Negative

### TOXICOLOGY - DRUGS SCREENING

Barbiturate	Negative	Negative
MDMA	Negative	Negative
Methadone	Negative	Negative
THC/Marijuana	Negative	Negative
Amphetamine	Negative	Negative
Benzodiazepines	Negative	Negative
Opiat	Negative	Negative
Cocain	Negative	Negative
Metamphetamine	Negative	Negative
Alcohol	Negative	Negative

### URINALYSIS

#### Complete Urine Analysis

##### Macroscopic

Color	Yellow	
Turbidity	Clear	Clear
Specific Gravity	1.029	1.000 - 1.030
pH	5.5	4.5 - 8.0
Leucocyte	Negative	Negative
Glucose	Negative	Negative
Nitrit	Negative	Negative



## LABORATORY RESULT

Name : TAMBOK PARSAULIAN NAPITUPULU	MR : 01022516	Visit : 29/04/2019	#Lab : IN66622808218
Comp. : INSPEKTINDO SINERGI PERSADA	Sex : Male	DOB : 27 July 1974	

EXAMINATION	RESULT	NORMAL RANGE
Bilirubin	Negative	Negative
Blood	Negative	Negative
Urobilinogen	Normal	Normal
Protein	Negative	Negative
Keton	Negative	Negative

### Microscopic

RBC	0-1	0 - 1
WBC	0-1	0 - 4
Cylinder	Negative	
Epithels Squamous	0-1	5 - 15
Crystals	Negative	
Bacteria	Negative	Negative
Others	Negative	

### STOOL / RECTAL SWAP

#### Faeces Complete

#### Macroscopic

Color	Brown	
Consistency	Smooth	
Mucus	Negative	Negative
Blood	Negative	Negative
Pus	Negative	Negative
Parasitologi Faeces	Negative	Negative
Lipid	Negative	Negative

#### Microscopic

RBC	0-1	0 - 1
WBC	0-1	0 - 5
Amoeba	Negative	
Ephitels	Positive	Positive
Worm Eggs	Negative	Negative
Yeast	Negative	Negative
Muscle Fiber	Negative	Negative
Others	Negative	Negative

#### Digestive

Amylum	Negative	Negative
Fat	Negative	
Fibers	Positive	Positive

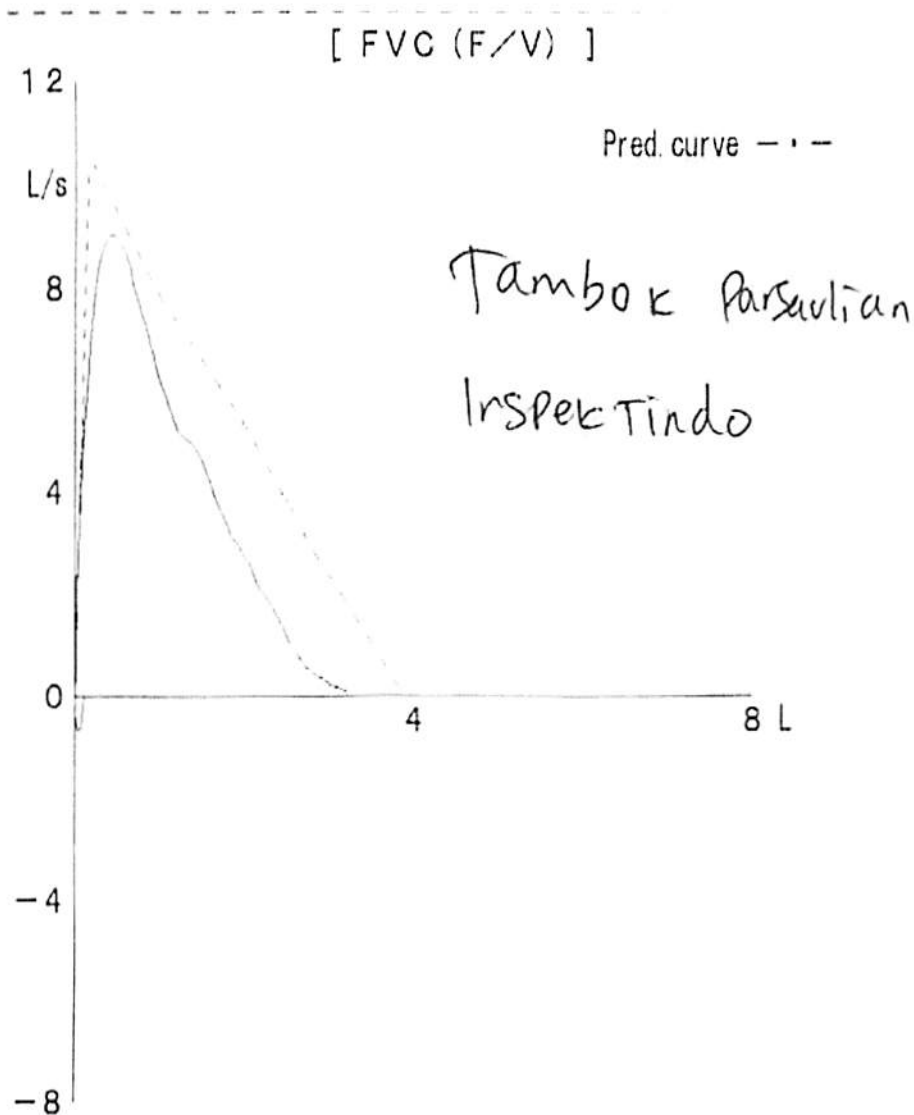
## SPIROMETRY DIAGNOSTIC

Name : TAMBOK PARSAULIAN NAPITUPULU	Sex : Male	MR : 01022516	Visit : 29/04/2019
Comp. : INSPEKTINDO SINERGI PERSADA		DOB : 27 July 1974	

EXAMINATION	RESULT
-------------	--------

FVC Result	: 3.23 L---> 83.2 %
FEV1 Result	: 2.77 L---> 80.8 %
FEV1/FVC Result	: 85.76 %---> 113.8 %
PEF Result	: 9.01 L/S---> 86.6 %
Indonesian Standart Result	:
Index	:
Spirometry Result	: Normal

Impression : Normal Spirometric Functions



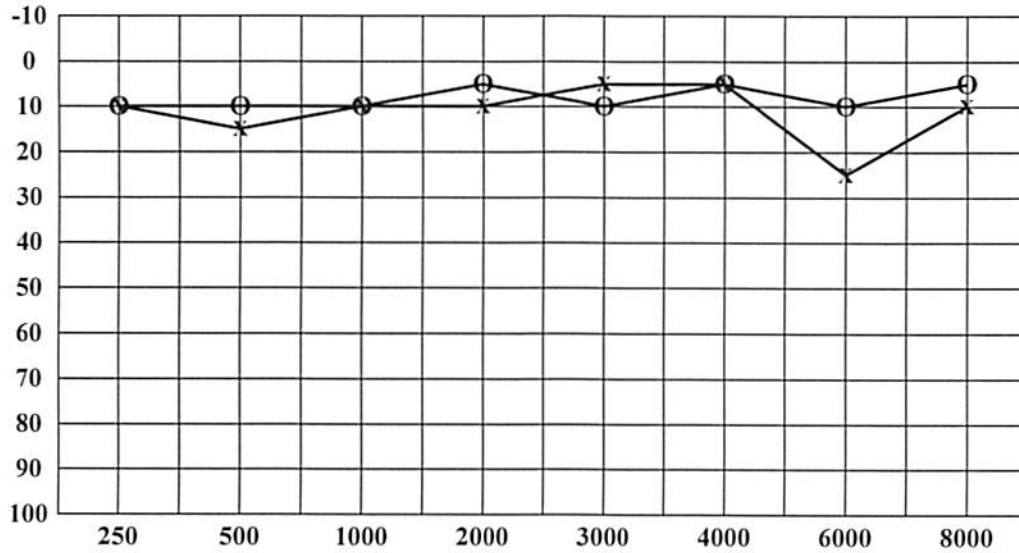
# AUDIOMETRY DIAGNOSTIC

Name : TAMBOK PARSAULIAN NAPITUPULU	Sex : Male	MR : 01022516	Visit : 29/04/2019
Comp. : INSPEKTINDO SINERGI PERSADA		DOB : 27 July 1974	

## RESULT

Left Ear	250	500	1000	2000	3000	4000	6000	8000
AC	10	15	10	10	5	5	25	10
BC	-	-	-	-	-	-	-	-

Right Ear	250	500	1000	2000	3000	4000	6000	8000
AC	10	10	10	5	10	5	10	5
BC	-	-	-	-	-	-	-	-



< : Right Ear (BC)  
 > : Left Ear (BC)  
 O : Right Ear (AC)  
 X : Left Ear (AC)

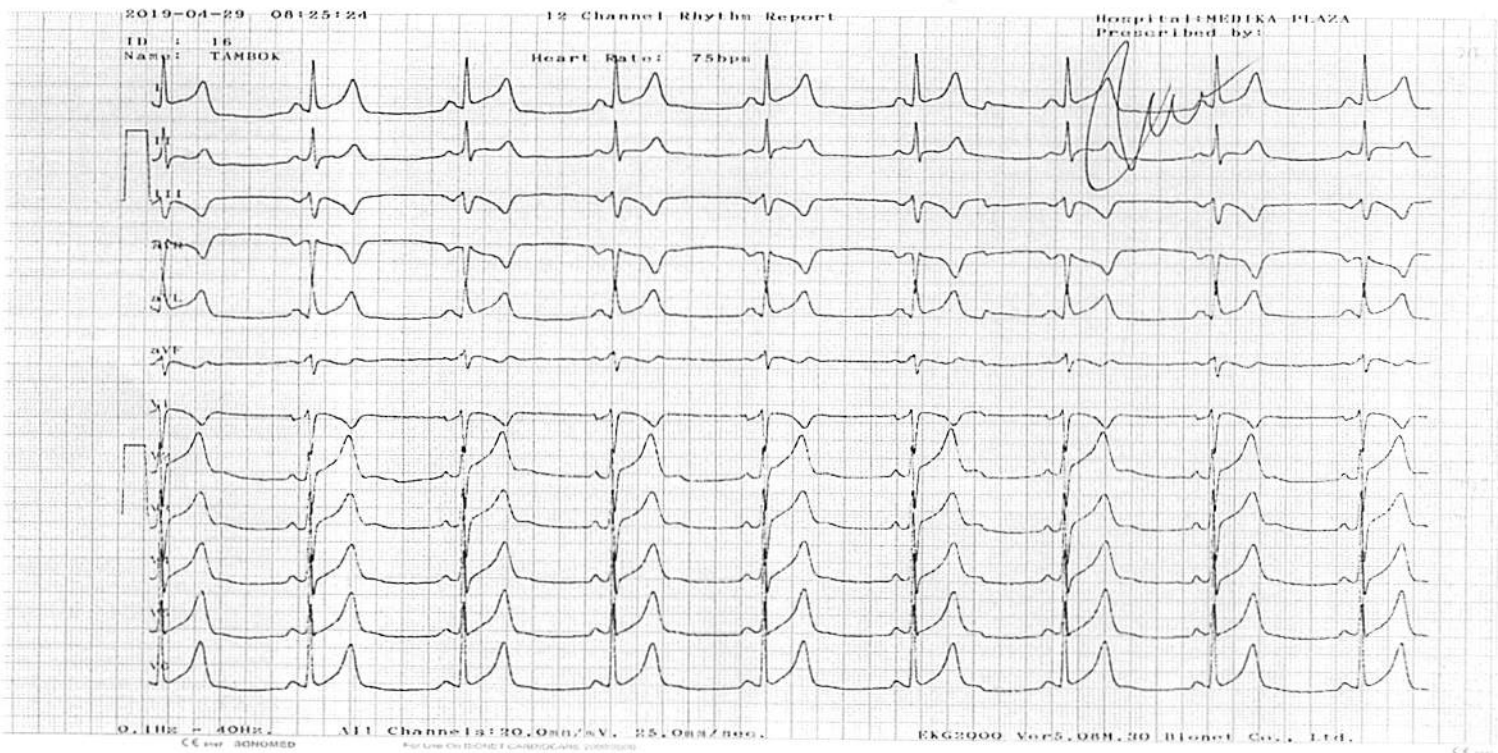
Conclusion Right Ear : Hearing threshold = 7.5 dB  
(Within normal limit)

Conclusion Left Ear : Hearing threshold = 10 dB  
(Within normal limit)

# CARDIOLOGY DIAGNOSTIC

Name : TAMBOK PARSAULIAN NAPITUPULU	Sex : Male	MR : 01022516	Visit : 29/04/2019
Comp. : INSPEKTINDO SINERGI PERSADA		DOB : 27 July 1974	

EXAMINATION	RESULT	Comments :
ELECTROCARDIOGRAPHY	Sinus Rythm axis ( N ), P wave ( N ), PR int 0.16" ST - T segment ( N ), aritmia (-)	Normal ECG
TREADMILL	Sinus Rythm axis ( N ), P wave ( N ), PR int 0.16" ST - T segment ( N ), aritmia (-)	Treadmill Exercise Test : Negative Cardiopulmonary Fitness Classification : Good METs : 10.8



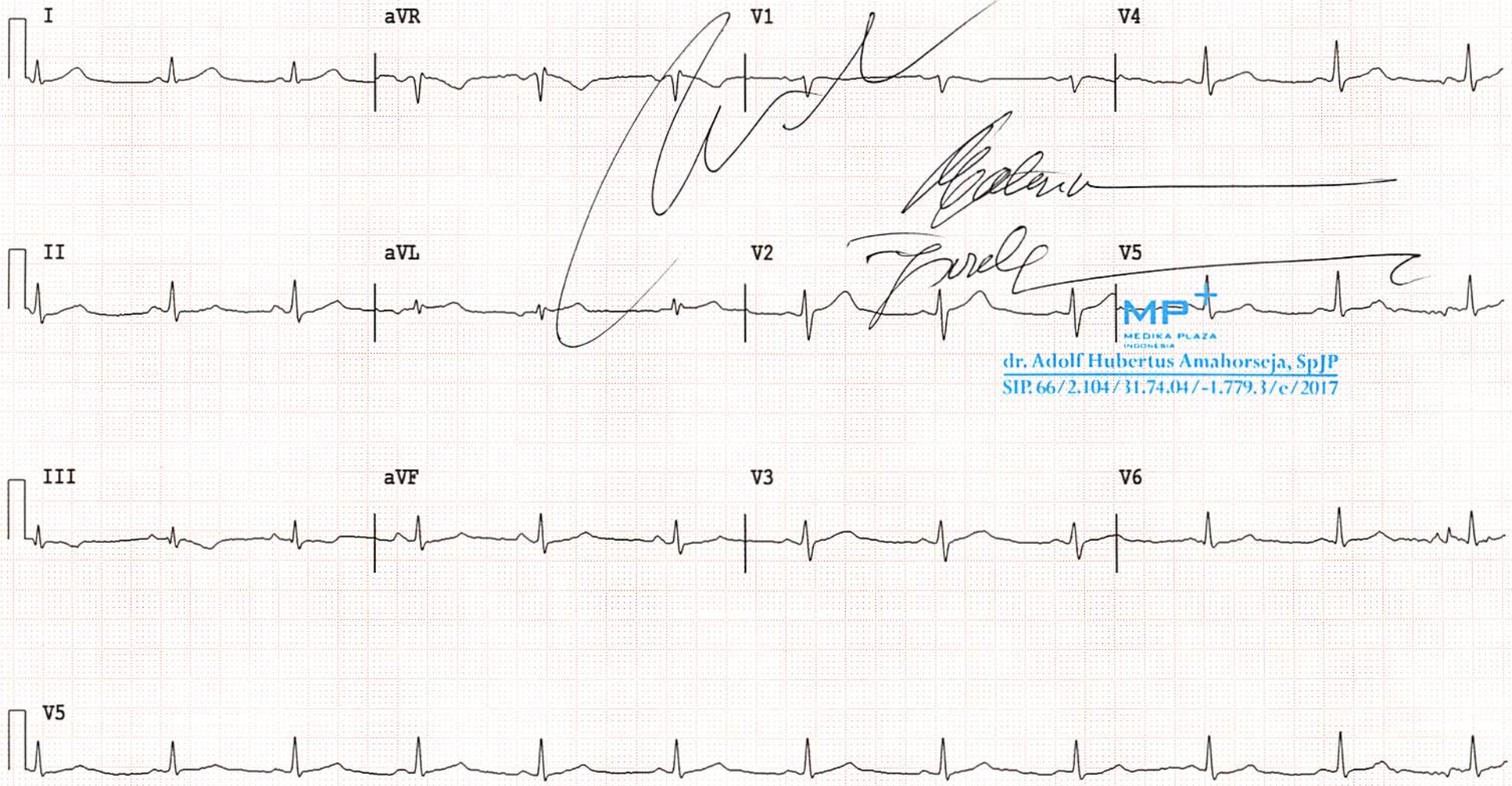
Name: TAMBOK PARSULIAN  
 ID: INSPEKTINDO 4/29/2019 09:04:14

HR: 68 Medication(s): No Medication  
 BP: 120/80 : No Medication  
 Age: 44 Years Clin. Class: Normal  
 Gender: Male : Normal  
 Race: Oriental Department: MEDIKA PLAZA  
 Height: 171 cm Technician: Nr. Jeni  
 Weight: 80 Kg Physician: Dr. Adolf DSJP

	I	aVR	V1	V4
L	0.8	-0.7	0.2	0.8
S	0.5	-0.5	0.0	0.6
	II	aVL	V2	V5
L	0.5	0.5	1.7	0.4
S	0.6	0.2	0.8	0.4
	III	aVF	V3	V6
L	-0.3	0.1	0.8	0.1
S	0.1	0.3	0.6	0.2

Baseline ECG

Levels measured at 80mS Post-J Levels in mm Slope in uV/mS



Name: **TAMBOK PARSULIAN**

ID: **INSPEKTINDO**


4/29/2019 09:07:12

Worst Case S-T Depression

HR: 90 Phase: Exercise  
 BP: Exercise Time: 02:50  
 RPE: Stage/Time: 1/02:50  
 METs: 4.7 Workload: 2.7 kmh 10.0 % grade  
 Protocol: Bruce

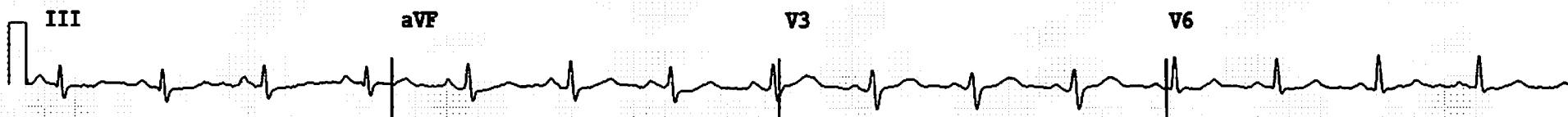
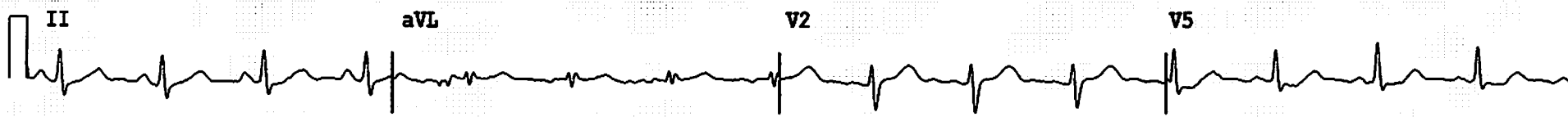
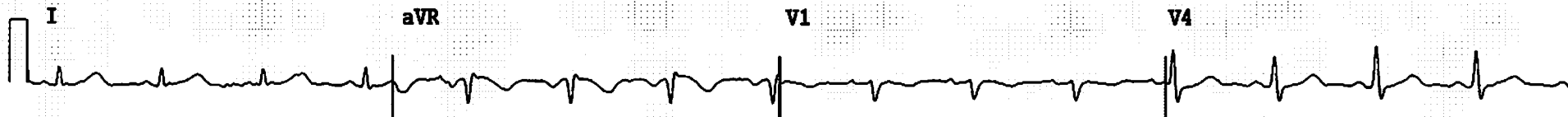
Baseline

Current



III  
 L -0.3  
 S 0.1  
 J+80ms

III  
 L -0.4  
 S 0.0  
 J+80ms



Name: **TAMBOK PARSULIAN**

Worst Case S-T Depression

ID: **INSPEKTINDO**

4/29/2019 09:10:12

HR: 114 Phase: Exercise

BP: 130/90 Exercise Time: 05:50



RPE: Stage/Time: 2/02:50

METs: 7.0 Workload: 4.0 kmh 12.0 % grade

Protocol: Bruce

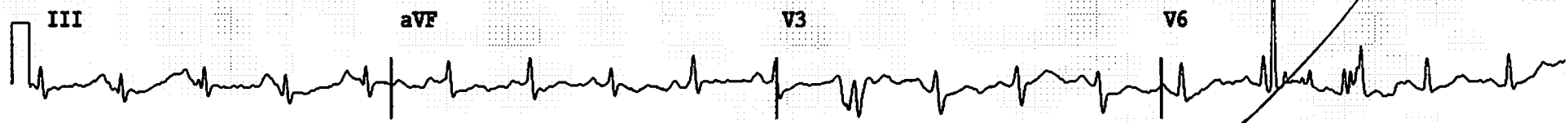
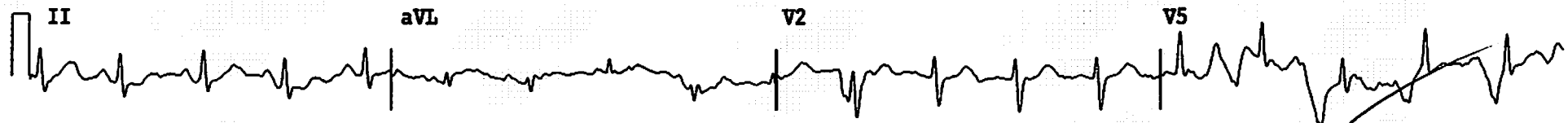
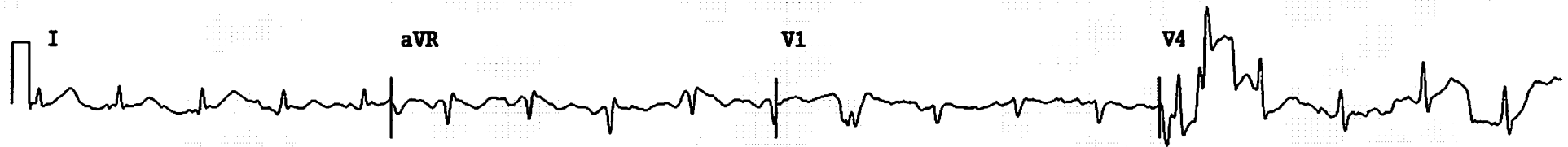
Baseline

Current



III  
L -0.3  
S 0.1  
J+80ms

III  
L -0.4  
S 0.0  
J+80ms



Name: **TAMBOK PARSULIAN**

ID: **INSPEKTINDO**

4/29/2019 09:13:12

Worst Case S-T Depression

HR: 142 Phase: Exercise  
 BP: 150/100 Exercise Time: 08:50  
 RPE: Stage/Time: 3/02:50  
 METs: 10.0 Workload: 5.4 kmh 13.9 % grade  
 Protocol: Bruce

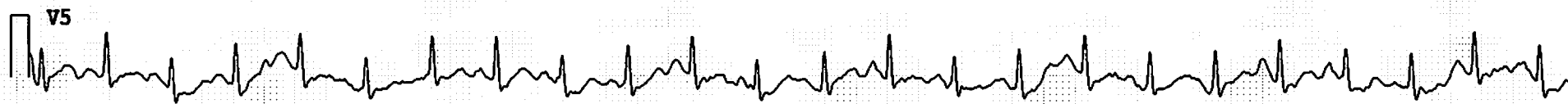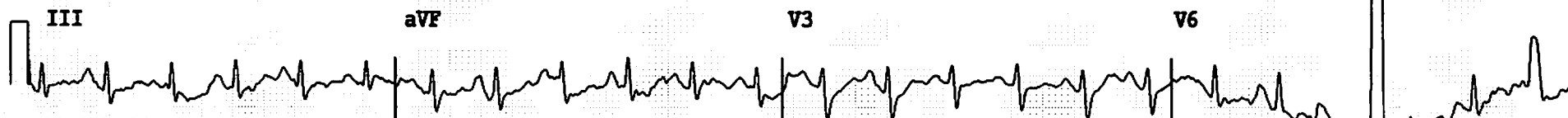
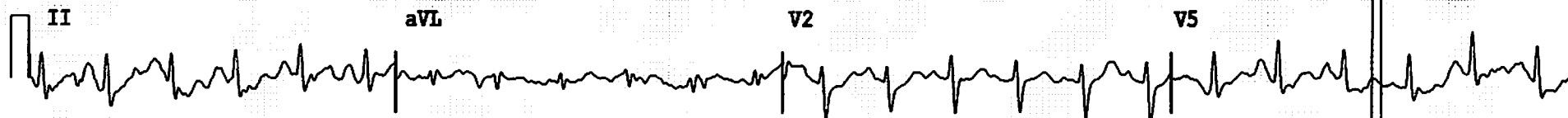
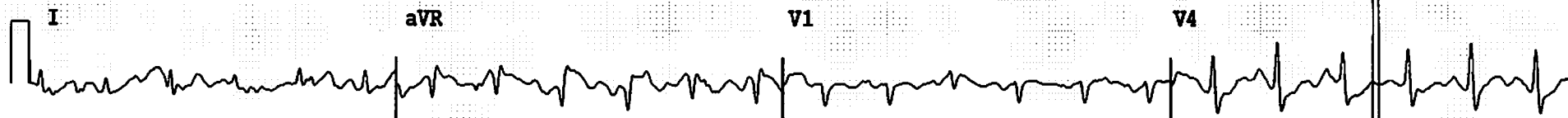
Baseline

Current



III  
 L -0.3  
 S 0.1  
 J+80ms

III  
 L -0.5  
 S 0.5  
 J+80ms





Name: TAMBOX PARSULIAN

Worst Case S-T Depression

ID: INSPEKTINDO

4/29/2019 09:13:48

HR: 151

Maximum Exercise

BP: Exercise Time: 09:26

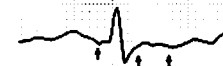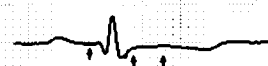RPE: Stage/Time: 4/00:26

METs: 10.7 Workload: 6.7 kmh 16.0 % grade

Protocol: Bruce

Baseline

Current



III  
L -0.3  
S 0.1  
J+80ms

III  
L -0.6  
S -0.1  
J+80ms

MAXIMUM EXERCISE ECG

