

Certificate Of Health Assessment




Name	Age	Position	Department
ACHMAD CHOIRONI	37 yo	SPV	TESTING

COMPANY :

INSPEKTINDO SINERGI PERSADA, PT

CONCLUSION

FIT TO WORK	
FIT WITH MEDICAL NOTE	✓
TEMPORARY UNFIT	
UNFIT	

Issued Date	Doctors Name	Prepared By
10 November 2020	Rezkha Amalia, MD PKTK : KEP.476/BINWASK3-PNK3/KK/XII/2018 SIP : 54/B.15a/31.74.04.1004/-1.779.3/e/2018	 
Expired Date		Verified By
10 November 2021	dr. Muhammad Ilyas, Sp.Ok SIP : 29/B.15b/31.74.04.1004.02.009.K.1/3/-1.779.3/e/2019	 PT. KARTIKA BINA MEDIKATAMA

No. Formulir : FM-DR-008-05
 No. Revisi : 00
 Tanggal Terbit : 2 Mei 2011

Certificate Number : MP-BOP/1-20201110/126313
 MCU Validity Check
<https://mcu-validasi.medikaplaza.com>

PT. KARTIKA BINA MEDIKATAMA

TO WHOM IT MAY CONCERN

Kepada yang berkepentingan

This is certify that today Tuesday, 10 November 2020 Medika Plaza Clinic has performed urine drug screening and/or breath alcohol test to :

Dengan ini menyatakan bahwa, pada hari ini Selasa, 10 November 2020 Medika Plaza Clinic telah melakukan urine drug screening dan/atau breath alcohol test kepada :


ACHMAD CHOIRONI

With the results are as follows :

Dengan hasil sebagai berikut :

<u>Drugs Test</u> <i>Uji Obat</i>	<u>Result</u> <i>Hasil</i>		
URINE DRUGS SCREENING			
- Amphetamine	<input type="checkbox"/> Non-Negative	<input checked="" type="checkbox"/> Negative	<input type="checkbox"/> N/A
- Met-Amphetamine	<input type="checkbox"/> Non-Negative	<input checked="" type="checkbox"/> Negative	<input type="checkbox"/> N/A
- Cocain	<input type="checkbox"/> Non-Negative	<input checked="" type="checkbox"/> Negative	<input type="checkbox"/> N/A
- THC/Canabis/Marijuana	<input type="checkbox"/> Non-Negative	<input checked="" type="checkbox"/> Negative	<input type="checkbox"/> N/A
- Morphine/Opiates	<input type="checkbox"/> Non-Negative	<input checked="" type="checkbox"/> Negative	<input type="checkbox"/> N/A
- P C P/Phencyclidine	<input type="checkbox"/> Non-Negative	<input checked="" type="checkbox"/> Negative	<input type="checkbox"/> N/A
- Barbiturate	<input type="checkbox"/> Non-Negative	<input type="checkbox"/> Negative	<input checked="" type="checkbox"/> N/A
- Benzodiazepin	<input type="checkbox"/> Non-Negative	<input checked="" type="checkbox"/> Negative	<input type="checkbox"/> N/A
- Methadone	<input type="checkbox"/> Non-Negative	<input checked="" type="checkbox"/> Negative	<input type="checkbox"/> N/A
- Propoxyphene	<input type="checkbox"/> Non-Negative	<input type="checkbox"/> Negative	<input checked="" type="checkbox"/> N/A
- Oxycodone	<input type="checkbox"/> Non-Negative	<input type="checkbox"/> Negative	<input checked="" type="checkbox"/> N/A
- MDMA	<input type="checkbox"/> Non-Negative	<input type="checkbox"/> Negative	<input checked="" type="checkbox"/> N/A
- 6-MAM	<input type="checkbox"/> Non-Negative	<input type="checkbox"/> Negative	<input checked="" type="checkbox"/> N/A
BREATH ALCOHOL TEST			
- Alcohol	<input type="checkbox"/> Non-Negative	<input checked="" type="checkbox"/> Negative	<input type="checkbox"/> N/A

Jakarta, November 10, 2020



PT. KARTIKA BINA MEDIKATAMA
(dr. Dian Wahyu Tanjungsari, Sp.PK)
Clinical Patologist

PT. KARTIKA BINA MEDIKATAMA

HEAD OFFICE : BELTWAY OFFICE PARK, TOWER C, 2nd Floor, Jl. TB. Simatupang Kav 41. Jakarta Selatan 12550, Phone : +62 21 808 66 088, Fax : +62 21 808 66 089

BELTWAY CLINIC : BELTWAY OFFICE PARK, ANNEX BUILDING, Ground Floor, Jl. TB. Simatupang Kav 41. Jakarta Selatan 12550, Phone : +62 21 808 66 099, Fax : +62 21 808 66 098

WTC 2 CLINIC : World Trade Center 2, Lower Ground Floor, Jl. Jend. Sudirman Kav 29. Jakarta Selatan 12920, Phone : +62 21 295 22 611, Fax : +62 21 295 22 610

www.medikaplaza.com

HEALTH ASSESSMENT REPORT

Of

ACHMAD CHOIRONI

01035755

Tuesday, 10 November 2020

MP BELTWAY CLINIC

Beltway Office Park, Annex Building, Ground Floor

Jl. TB. Simatupang Kav.41, Jakarta Selatan 12550

Tlp : (62-21) 808 66 099, Fax : (62-21) 808 66 098

www.medikaplaza.com

MP BELTWAY CLINIC

Beltway Office Park, Annex Building, Ground Floor
Jl. TB. Simatupang Kav.41, Jakarta Selatan 12550
Tlp : (62-21) 808 66 099, Fax : (62-21) 808 66 098
www.medikaplaza.com

PATIENT DATA

MedRec.	: 01035755	EMPLOY. STATUS	: Employee
NAME	: ACHMAD CHOIRONI	BIRTHDATE	: 02 March 1983
EMPLOYEE No.	:	SEX	: Male
JOB TITLE	: SPV	STATUS	: Married
COMP. NAME	: INSPEKTINDO SINERGI PERSADA, PT	NASIONALITY	: Indonesia

SUMMARY

MEDICAL FINDING :

1. Hypertriglyceridemia (KONSUL GP)
2. Non reactive Anti HBs
3. Overweight
4. Calculus, decayed, filled, and radix teeth
5. USG Abdomen: Fatty liver. Not visualized left kidney dd/ ectopic kidney, atrophy kidney (KONSUL UROLOGIST)
6. Moderate conductive hearing loss of right ear, and Decreasing of hearing acuity on high frequency of left ear


Your fitness status is fit with medical note:

1. Hypertriglyceridemia
2. USG Abdomen: Not visualized left kidney dd/ ectopic kidney, atrophy kidney
3. Moderate conductive hearing loss of right ear

SUGGESTION :

1. Low fat and carbohydrate diet, exercise regularly minimal 3 times a week. Consultation with a General Practitioner for further evaluation of hypertriglyceridemia
2. Need to get Hepatitis B vaccination
3. Reduce body weight gradually 0.5 Kgs/week, by doing regular exercise (aerobic/jogging), 3-4x/week, 30-45 minutes and reduce high calorie diet until maximal body weight is 60.84 Kgs (present body weight is 71.1 Kgs). Consultation with a Nutritionist for evaluation of overweight
4. Consultation with a Dentist for dental care, minimal once a year or better once in six month
5. Low fat diet and exercise regularly minimum 3x/week. Repeat abdominal USG 6 months later and consultation with an Internist to evaluate fatty liver
6. Consultation with an Urologist for further evaluation of USG Abdomen: Not visualized left kidney dd/ ectopic kidney, atrophy kidney
7. Avoid noisy environment or use earplug properly while working at noisy work environment to prevent further hearing impairment. Consultation with an ENT Specialist for further evaluation and examination of moderate conductive hearing loss of right ear

Responsible Doctor



Rezkha Amalia, MD

Notes:

If you need the further information or consultation, please contact us via :

Email : - beltway.doctor@medikaplaza.com
- beltway.doctor2@medikaplaza.com

Telepon Klinik : (62-21) 8086 6000

CLINICAL EVALUATION

Name : ACHMAD CHOIRONI	Sex : Male	MR : 01035755	Visit : 10/11/2020
Comp. : INSPEKTINDO SINERGI PERSADA, PT		DOB : 02 March 1983	

EXAMINATION

RESULT

NOTES

ANAMNESIS

PRESENT COMPLAINT AND HISTORY OF PRESENT

ILLNESS

Present complaint

No complaint

MEDICAL HISTORY

Allergy

No

Imunisasi

Yes

Surgery

Yes

Nasal fracture

Hospitalization

No

Disease

No

LIFE STYLE

Alcohol intake

No

Smoking

Yes

Mild smoker

Exercise

Yes

Futsal

FAMILY MEDICAL HISTORY

Diabetes Melitus

No

Hypertension

No

Heart disease

No

Lung TB

No

Kidney disease

No

Astma

No

Mental disease

No

Epilepsy

No

Cancer

No

Color blind

No

Stroke

No

Liver disease

No

Bone & joint

No

Others disease

No

WORK EXPOSURE

Noise

No

Heat Stress

No

Cold Stress

No

Vibration

No

Involving height

No

Radiation

No

Dust

No

CLINICAL EVALUATION

Name : ACHMAD CHOIRONI	Sex : Male	MR : 01035755	Visit : 10/11/2020
Comp. : INSPEKTINDO SINERGI PERSADA, PT		DOB : 02 March 1983	

EXAMINATION	RESULT	NOTES
Toxic chemical	No	
Iritating fluid	No	
Smoke	No	
Bacterium/Virus/Parasite	No	
Blood	No	
Animal	No	
Operating heavy mobile equipment	No	
Manual Handling	No	
Sitting continuously over 4 hours	No	
Stand continuously over 4 hours	No	
Using monitor screen more than 4 hours per day	No	
Exposure	No	
Unergonomic body positions	No	
Shift work	No	
Work is not accordance with skills and knowledge	No	
Workload does not accordance with time	No	
Work conflict	No	
Inappropriate task	No	
Career barriers	No	
Family conflict	No	
Working arround rotating machinery	No	
Administration work	Yes	
Handling food product	No	
Others	Yes	SPV
PHYSICAL EXAMINATION		
General Appearance	Good	
Body shape	Picnicus	
VITAL SIGN		
Body Weight	71.1 Kg	
Body Height	156 Cm	
BMI	29.21 Kg/m2	
Normal Weight	45.02 - 60.84 Kg	
BMI Conclusion	Overweight	
Blood Pressure	120/80 mmHg	
Pulse	75 x/minute	
Body Temperature	36 °C	
RR	20	

CLINICAL EVALUATION

Name : ACHMAD CHOIRONI	Sex : Male	MR : 01035755	Visit : 10/11/2020
Comp. : INSPEKTINDO SINERGI PERSADA, PT		DOB : 02 March 1983	

EXAMINATION	RESULT	NOTES
Neck Circumference	44 Cm	
Arm Circumference	29 Cm	
Chest size	98 Cm	
Abdominal Circumference	90 Cm	
SKIN		
Skin	Normal	
EYE		
Left	Normal	
Right	Normal	
ENT		
Auricle	Normal	
Ear canal	Normal	
Drums	Normal	
Septum/Conchae	Normal	
Sinuses	Normal	
Pharynx	Normal	
Tonsil	Normal	
MOUTH		
Gum	Normal	
Dental	Abnormal	Calculus, decayed, filled, and radix teeth
NECK		
General	Normal	
Thyroid Gland	Normal	
CHEST		
Form	Normal	
Lung	Normal	
Heart	Normal	
Breast	Normal	
ABDOMEN		
Form	Flat	
Palpation	Supple	
Liver	Not Palpable	
Spleen	Not Palpable	
Kidney	No Ballotment	
-	No	
Hernia inguinal	No	
EXTRIMITIES		

CLINICAL EVALUATION

Name : ACHMAD CHOIRONI	Sex : Male	MR : 01035755	Visit : 10/11/2020
Comp. : INSPEKTINDO SINERGI PERSADA, PT	DOB : 02 March 1983		

EXAMINATION	RESULT	NOTES
Bones, joint	Normal	
Muscles, tonus	Normal	
Fingernails	Normal	
Hand	Normal	
Foot	Normal	
RECTAL EXAMINATION		
Hemorrhoid	Negative	
Rectum	Normal	
SENSORIK EXAMINATION		
Tes Raba	Normal	
MOTORIK EXAMINATION		
Tes Grip	Normal	
REFLEX EXAMINATION		
Physiologic reflex	Normal	
Patologic reflex	Normal	
OTHERS EXAMINATION		
Coordination	Normal	
LYMPHE SYSTEM		
Submandibula	Normal	
Neck Gland	Normal	
Armpit gland	Normal	
Inguinal	Normal	

OPHTHALMOLOGY DIAGNOSTIC

Name : ACHMAD CHOIRONI	Sex : Male	MR : 01035755	Visit : 10/11/2020
Comp. : INSPEKTINDO SINERGI PERSADA, PT		DOB : 02 March 1983	

EXAMINATION	Right	Left
Reading	-	
Previous Glasses	-	-
Without Glasses	Distant	20/20
	Near	J1
Correction	Distant	-
	Near	-
Depth Perception	-	
Tonometry	14.0 mmHg	16.0 mmHg
Funduscopy	NORMAL	NORMAL
Visual Fields	Normal	
Colour Blind Test	Normal	

Impression :

RADIOLOGY DIAGNOSTIC

Name : ACHMAD CHOIRONI

Sex : Male

MR : 01035755

Visit : 10/11/2020

Comp. : INSPEKTINDO SINERGI PERSADA, PT

DOB : 02 March 1983

EXAMINATION**RESULT**

THORAX PA

No abnormality seen in both lungs.
Normal bronchovascular markings in both hili.
The heart is normal in size and shape.
The mediastinum is not widened.
Both sinus and diaphragms are good.
No evidence of pleural effusion.
There is costae at left side vertebra cervical (dd/ costae cervical)

Impression

Normal heart and lungs

RADIOLOGY DIAGNOSTIC

Name : ACHMAD CHOIRONI

Sex : Male

MR : 01035755

Visit : 10/11/2020

Comp. : INSPEKTINDO SINERGI PERSADA, PT

DOB : 02 March 1983

EXAMINATION

RESULT

USG ABDOMEN

LIVER:

Normal in size and contour, smooth surface, echoes structure parenchyme which are homogenous increase. No sign of SOL.

Intrahepatic vascularity and billiary tract are normal.

GALL BLADDER:

Normal in size, contour and surface. No sign of SOL/ sludge/ stone.

RIGHT KIDNEYS:

Normal in size, contour and surface. No sign of obstruction/ stone/ SOL.

LEFT KIDNEYS:

Not visualized

PANCREAS:

Normal in size, contour and surface. No sign of SOL.

LIEN:

Normal in size and contour, the echoes are homogenous. No sign of SOL.

URINARY BLADDER:

Normal in contour and surface. No sign of stone/ SOL.

PROSTATE AND VESICULA SEMINALIS:

Normal in size and contour which are homogenous echoes and no sign of focal lesion/ SOL.

Impression

Fatty liver

Not visualized left kidney dd/ ectopic kidney,
atrophy kidney

Other intra abdominal organs are normal

Suggestion : CT scan abdomen + kontras

LABORATORY RESULT

Name : ACHMAD CHOIRONI	MR : 01035755	Visit : 10/11/2020	#Lab : IN722327114313
Comp. : INSPEKTINDO SINERGI PERSADA, PT	Sex : Male	DOB : 02 March 1983	

EXAMINATION	RESULT	NORMAL RANGE
-------------	--------	--------------

HEMATOLOGI

ABO/Rh Typing "A" Rh(+) positive

Automated Blood Count

White Blood Cell (WBC)	9.6	3.8 - 11.0
Erythrocyte (RBC)	5.3	4.4 - 5.9
Haemoglobin	15.8	13.2 - 17.3
Hematocrit	44	40 - 52
Thrombocytes	307	150 - 440

MCV, MCH, MCHC

MCV	82	80 - 100
MCH	30	26 - 34
MCHC	36.3 *	32 - 36
ESR	9	0 - 10

Differential Count

Basophils	0	0 - 1
Eosinophil	8 *	2 - 4
Bands / Stab	3	3 - 5
Neutrophils	50	50 - 70
Lymphocytes	32	25 - 40
Monocytes	7	2 - 8

BLD CHEMISTRY/LIPID PROFILE

Total Cholesterol	160	Normal/Desireable: <200 Borderline High: 200-239 High: >=240
HDL Cholesterol	40.0 *	Normal : >40 - <60 Low HDL : <40 Desireable : >=60
LDL Cholesterol	64	Optimal: <100 Near/Above Optimal: 100-129 Borderline High: 130-159 High: 160-189 Very High: >=190
Triglycerides	278 *	Normal : <150 Borderline High: 150-199 High : 200-499 Very High : >=500

BLD CHEMISTRY/KIDNEY FUNCTION

LABORATORY RESULT

Name : ACHMAD CHOIRONI	MR : 01035755	Visit : 10/11/2020	#Lab : IN722327114313
Comp. : INSPEKTINDO SINERGI PERSADA, PT	Sex : Male	DOB : 02 March 1983	

EXAMINATION	RESULT	NORMAL RANGE
Ureum	26.9	10.0 - 50.0
Creatinine	1.0	0.6 - 1.3
Uric Acid	6.42	3.50 - 7.20

BLD CHEMISTRY/LIVER FUNCTION

Total Bilirubin	0.60	0.1 - 1.0
Direct Bilirubin	0.18	0.0 - 0.2
Indirect Bilirubin	0.42	0.0 - 0.8
SGOT(AST)	22	13 - 45
SGPT (ALT)	32	13 - 50
Alkaline Phosphatase	86	30 - 120
Gamma GT	28	0 - 50
Albumin	5.2	3.5 - 5.5
Globulin	2.70	2.3 - 3.5
Total Protein	7.9	6.6 - 8.7

BLD CHEMISTRY/DIABETES

Glucose Fasting	90	< 100
Glucose Urine	Negative	Negative
Keton Urine	Negative	Negative

Blood Glucose 2 PP

Blood Sugar 2 Hours PP	93	< 140
Glucose Urine	Negative	Negative
Keton Urine	Negative	Negative

SEROLOGI / IMUNOLOGI

HBsAg (Quantitative)	0.00	0.00 - 0.03
Anti Hbs (Quantitative)	0.3 *	>= 5.0

TOXICOLOGY - DRUGS SCREENING

Methadone	Negative	Negative
Phencyclidine	Negative	Negative
THC/Marijuana	Negative	Negative
Amphetamine	Negative	Negative
Benzodiazepines	Negative	Negative
Opiat	Negative	Negative
Cocain	Negative	Negative
Metamphetamine	Negative	Negative
Alcohol	Negative	Negative

URINALYSIS

Complete Urine Analysis

LABORATORY RESULT

Name : ACHMAD CHOIRONI	MR : 01035755	Visit : 10/11/2020	#Lab : IN722327114313
Comp. : INSPEKTINDO SINERGI PERSADA, PT	Sex : Male	DOB : 02 March 1983	

EXAMINATION	RESULT	NORMAL RANGE
-------------	--------	--------------

Macroscopic

Color	Colorless	
Turbidity	Clear	Clear
Specific Gravity	1.004	1.000 - 1.030
pH	5.5	4.5 - 8.0
Leucocyte	Negative	Negative
Glucose	Negative	Negative
Nitrit	Negative	Negative
Bilirubin	Negative	Negative
Blood	Negative	Negative
Urobilinogen	Normal	Normal
Protein	Negative	Negative
Keton	Negative	Negative

Microscopic

RBC	0-1	0 - 1
WBC	0-1	0 - 4
Cylinder	Negative	
Epithels Squamous	0-1	5 - 15
Crystals	Negative	
Bacteria	Negative	Negative
Others	Negative	

STOOL / RECTAL SWAP

Faeces Complete

Macroscopic

Color	Brown	
Consistency	Smooth	
Mucus	Negative	Negative
Blood	Negative	Negative
Pus	Negative	Negative
Parasit	Negative	Negative
Lipid	Negative	Negative

Microscopic

RBC	0-1	0 - 1
WBC	0-1	0 - 5
Amoeba	Negative	
Ephitels	Positive	Positive
Worm Eggs	Negative	Negative

LABORATORY RESULT

Name : ACHMAD CHOIRONI	MR : 01035755	Visit : 10/11/2020	#Lab : IN722327114313
Comp. : INSPEKTINDO SINERGI PERSADA, PT	Sex : Male	DOB : 02 March 1983	

EXAMINATION	RESULT	NORMAL RANGE
Yeast	Negative	Negative
Muscle Fiber	Negative	Negative
Others	Negative	Negative
Digestive		
Amylum	Negative	Negative
Fat	Negative	
Fibers	Positive	Positive

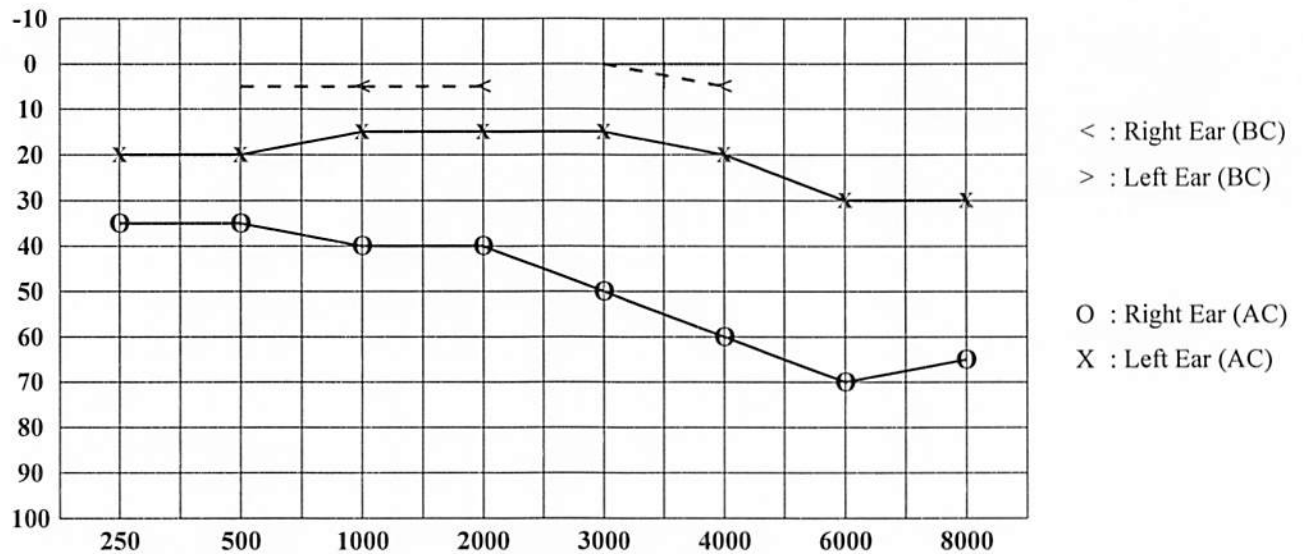
AUDIOMETRY DIAGNOSTIC

Name : ACHMAD CHOIRONI	Sex : Male	MR : 01035755	Visit : 10/11/2020
Comp.: INSPEKTINDO SINERGI PERSADA, PT		DOB : 02 March 1983	

RESULT

Left Ear	250	500	1000	2000	3000	4000	6000	8000
AC	20	20	15	15	15	20	30	30
BC	-	-	-	-	-	-	-	-

Right Ear	250	500	1000	2000	3000	4000	6000	8000
AC	35	35	40	40	50	60	70	65
BC	-	5	5	5	-	5	-	-



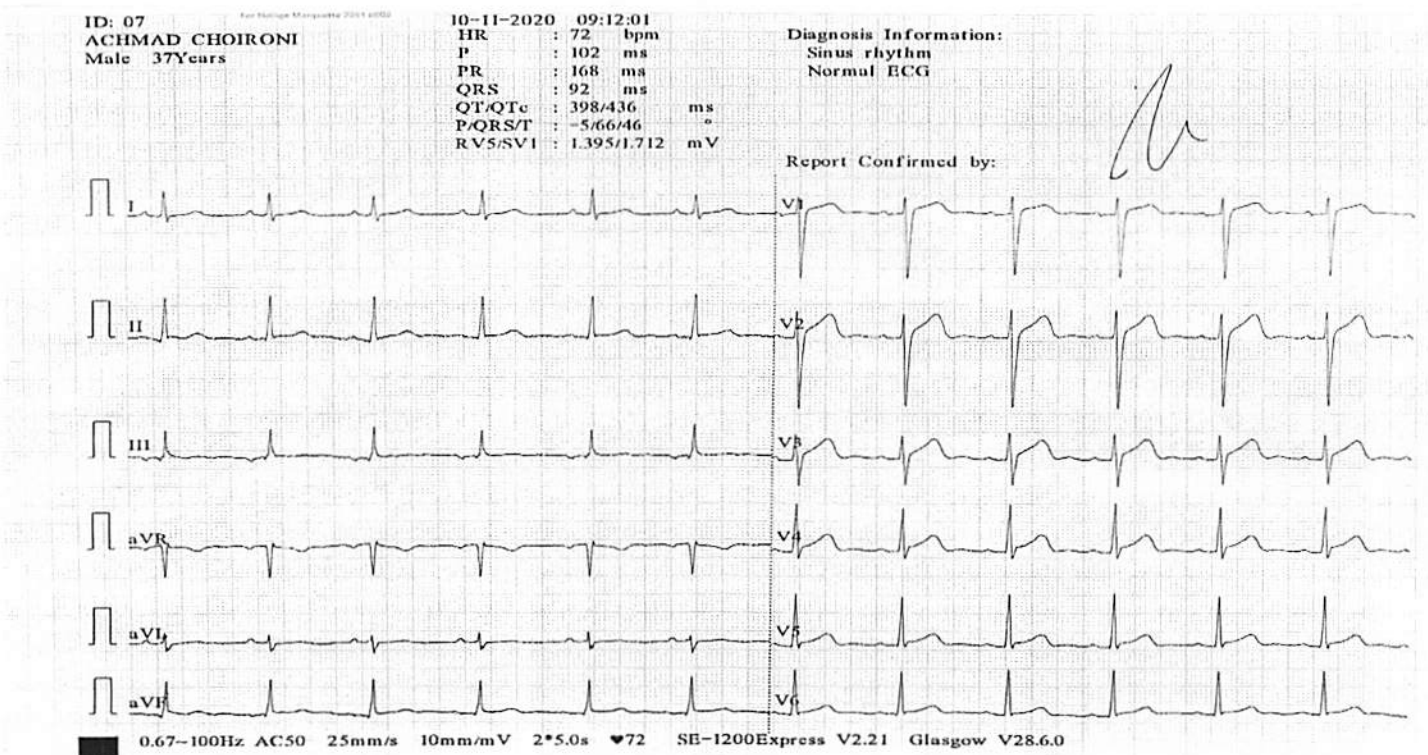
Conclusion Right Ear : Moderate conductive hearing loss = 43.75 dB
 With decreasing on frequency
 250Hz, 4000Hz, 6000Hz, 8000Hz

Conclusion Left Ear : Hearing threshold = 17.5 dB
 (Within normal limit)
 With decreasing on frequency
 6000Hz & 8000Hz

CARDIOLOGY DIAGNOSTIC

Name : ACHMAD CHOIRONI	Sex : Male	MR : 01035755	Visit : 10/11/2020
Comp.: INSPEKTINDO SINERGI PERSADA, PT		DOB : 02 March 1983	

EXAMINATION	RESULT	Comments :
ELECTROCARDIOGRAPHY	Sinus Rythm axis (N), P wave (N), PR int 0.16" ST - T segment (N), aritmia (-)	Normal ECG
TREADMILL	Sinus Rythm axis (N), P wave (N), PR int 0.16" ST - T segment (N), aritmia (-)	Treadmill Exercise Test : Negative Cardiopulmonary Fitness Classification : Good METs : 13.5



12-LEAD REPORT

ACHMAD CHOIRONI MR

Patient ID: 01035755

10.11.2020

9:57:42

74 bpm
120/80 mmHg

PRETEST
HYPERV.
00:20

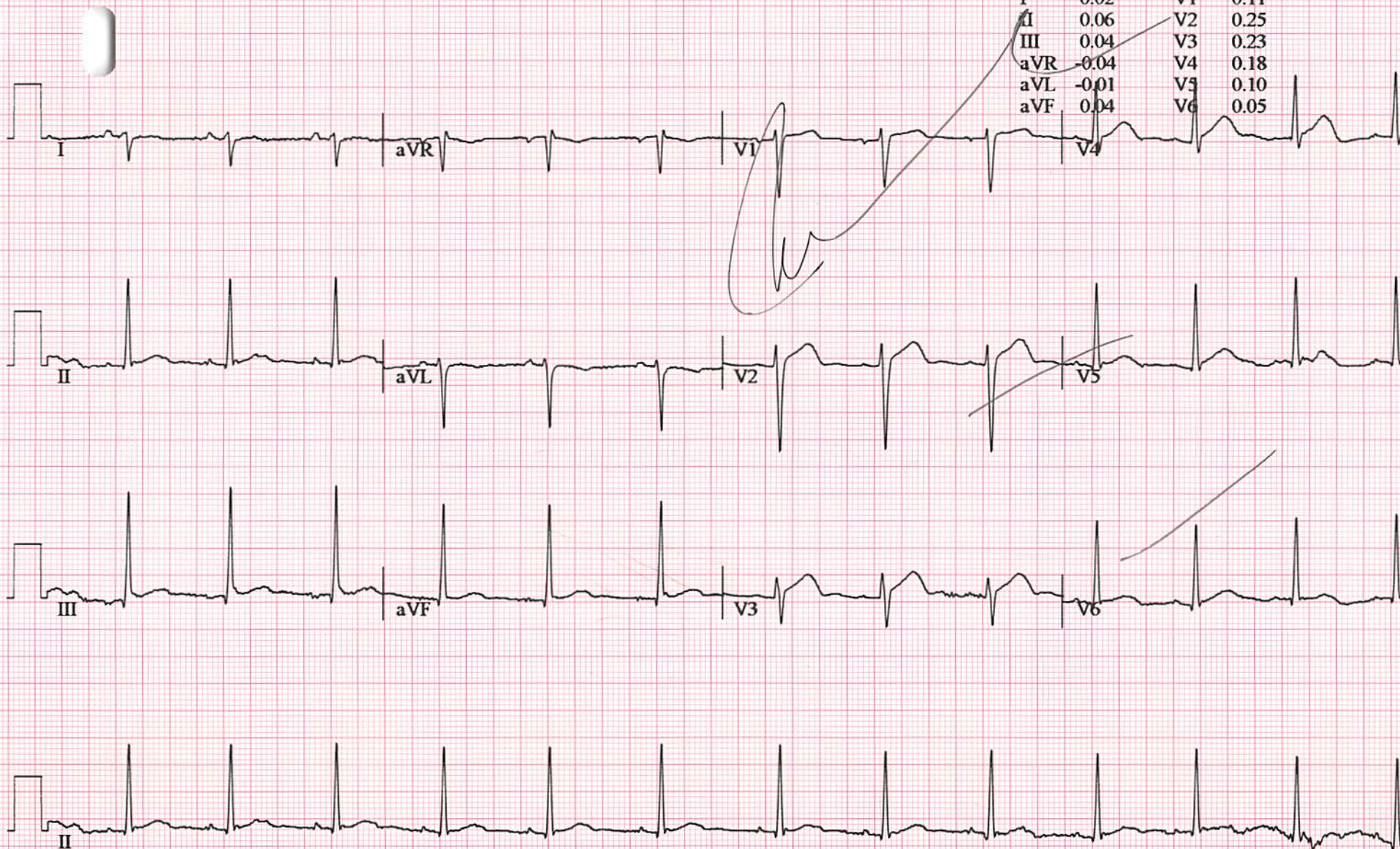
BRUCE
0.0 km/h
0.0 %

MEDIKA PLAZA

Measured at 60ms Post J

Auto Points

Lead	ST(mV)	Lead	ST(mV)
I	0.02	V1	0.11
aI	0.06	V2	0.25
III	0.04	V3	0.23
aVR	-0.04	V4	0.18
aVL	-0.01	V5	0.10
aVF	0.04	V6	0.05



GE

CASE V6.73

25 mm/s 10 mm/mV 50Hz 0.01 - 40Hz FRF- HR(IL,V2)

Start of Test: 9:57:21

12-LEAD REPORT

ACHMAD CHOIRONI MR

Patient ID: 01035755

10.11.2020

9:57:59

77 bpm
120/80 mmHg

PRETEST
WARM-UP
00:37

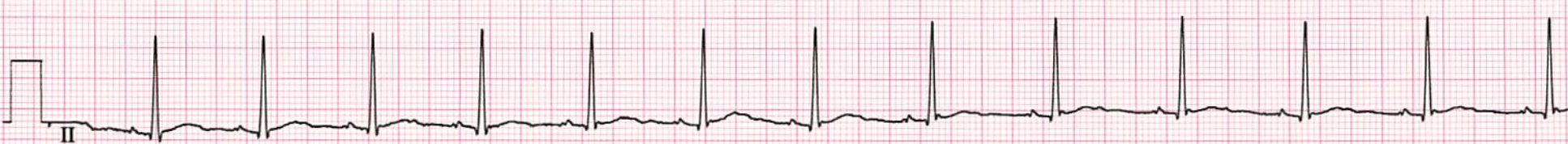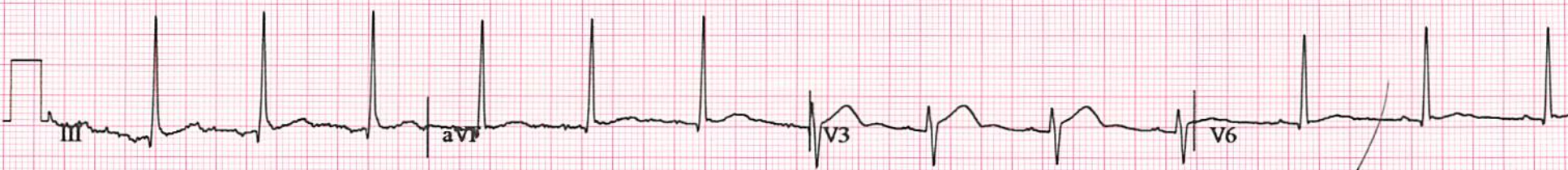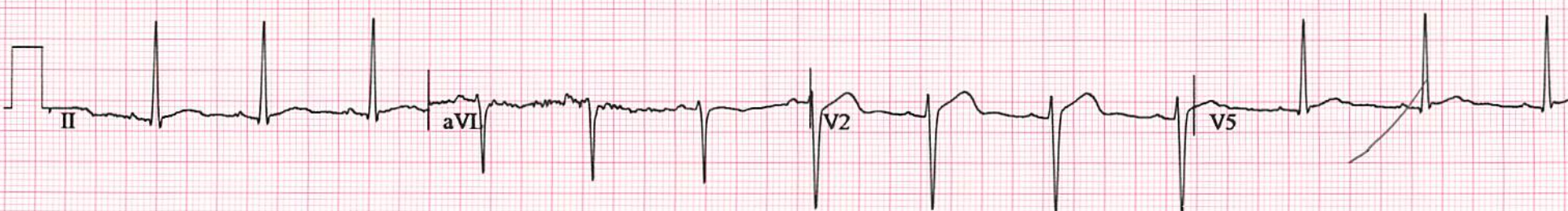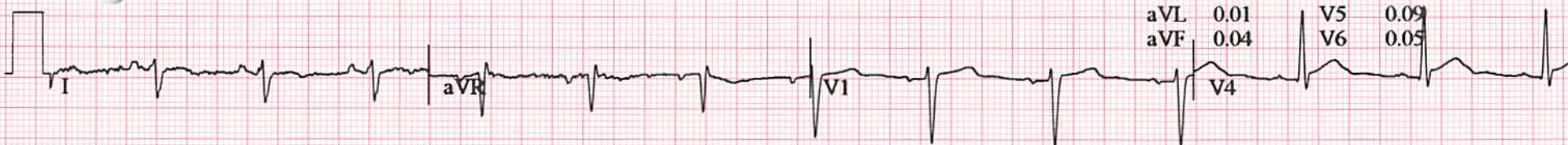BRUCE
0.0 km/h
0.0 %

MEDIKA PLAZA

Measured at 60ms Post J

Auto Points

Lead	ST(mV)	Lead	ST(mV)
I	0.03	V1	0.11
II	0.06	V2	0.25
III	0.03	V3	0.23
aVR	-0.04	V4	0.17
aVL	0.01	V5	0.09
aVF	0.04	V6	0.05



ACHMAD CHOIRONI MR
Patient ID: 01035755
10.11.2020
10:01:15

LINKED MEDIANS

92 bpm
120/80 mmHg

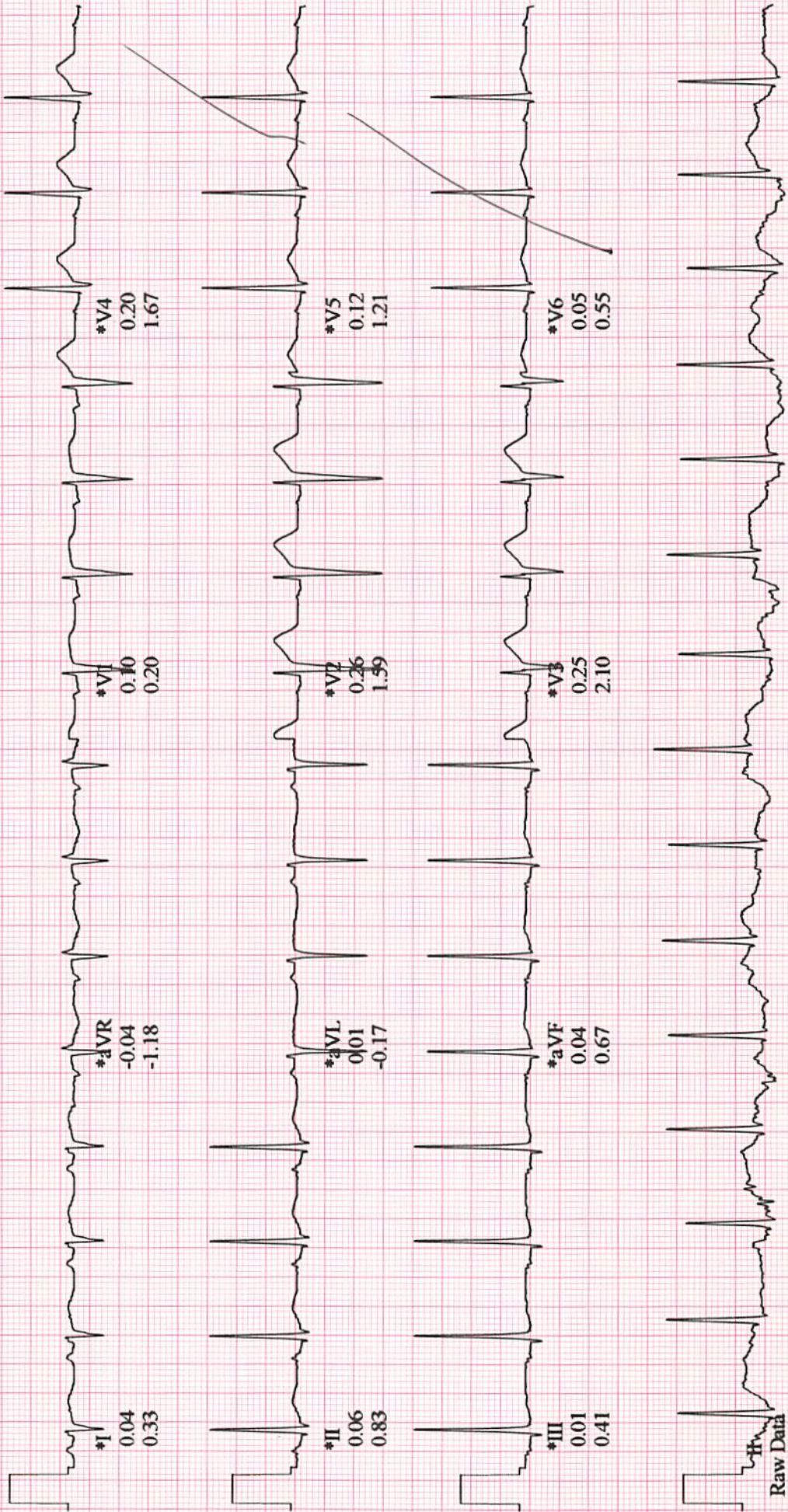
EXERCISE
STAGE 1
02:50

BRUCE
2.7 km/h
10.0%

MEDIKA PLAZA

Lead
ST Level (mV)
ST Slope (mV/s)

60 ms post J



Raw Data

*Computer Synthesized Rhythms

ACHMAD CHOIRONI MR
Patient ID: 01035755
10.11.2020
10:04:15

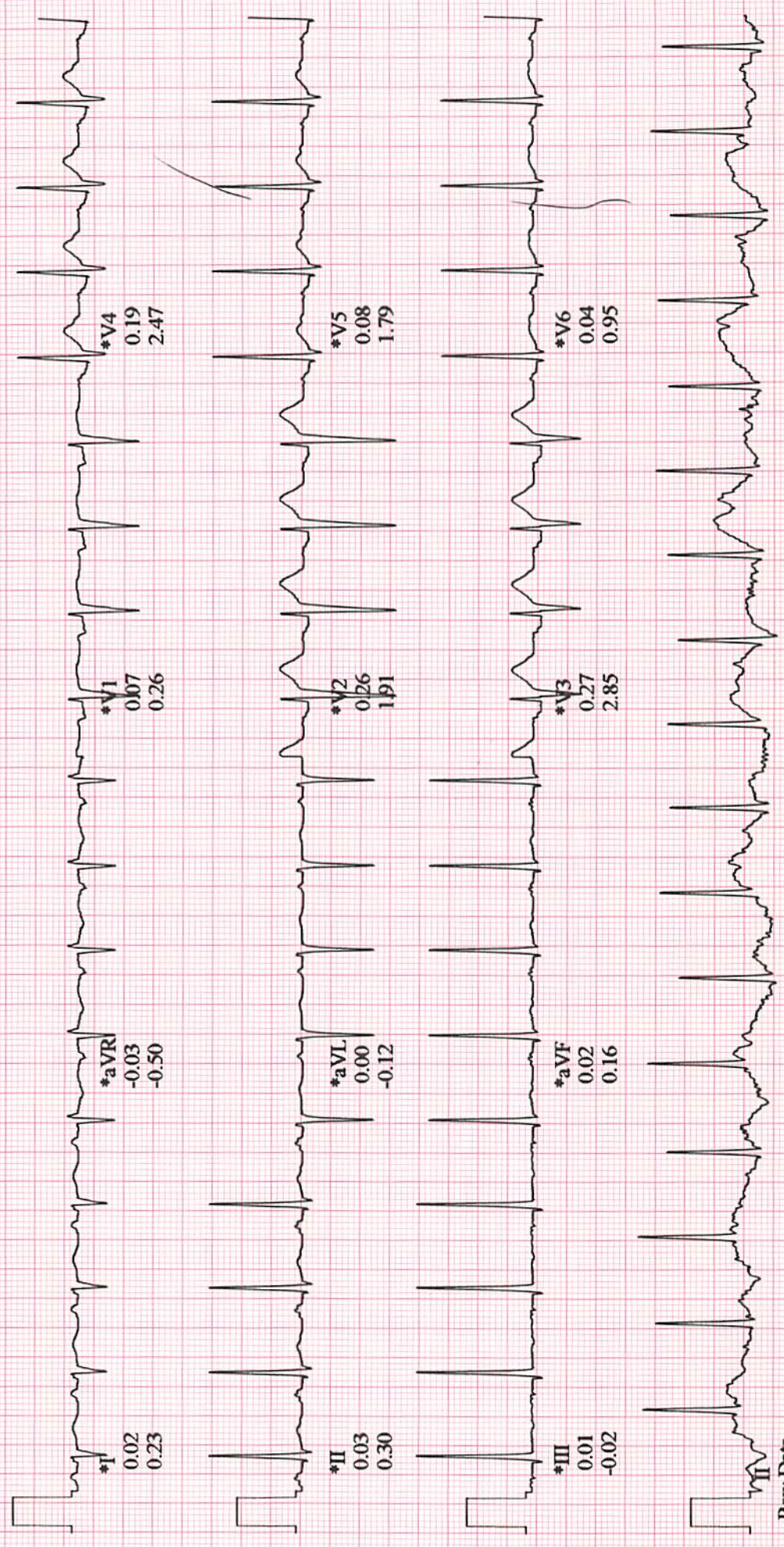
BRUCE
4.0 km/h
12.0 %

EXERCISE
STAGE 2
05:50

104 bpm
120/80 mmHg

Lead
ST Level (mV)
ST Slope (mV/s)

60 ms post J



Raw Data

*Computer Synthesized Rhythms

ACHMAD CHOIRONI MR
Patient ID: 01035755
10.11.2020
10:07:15

LINKED MEDIANS

129 bpm
130/80 mmHg

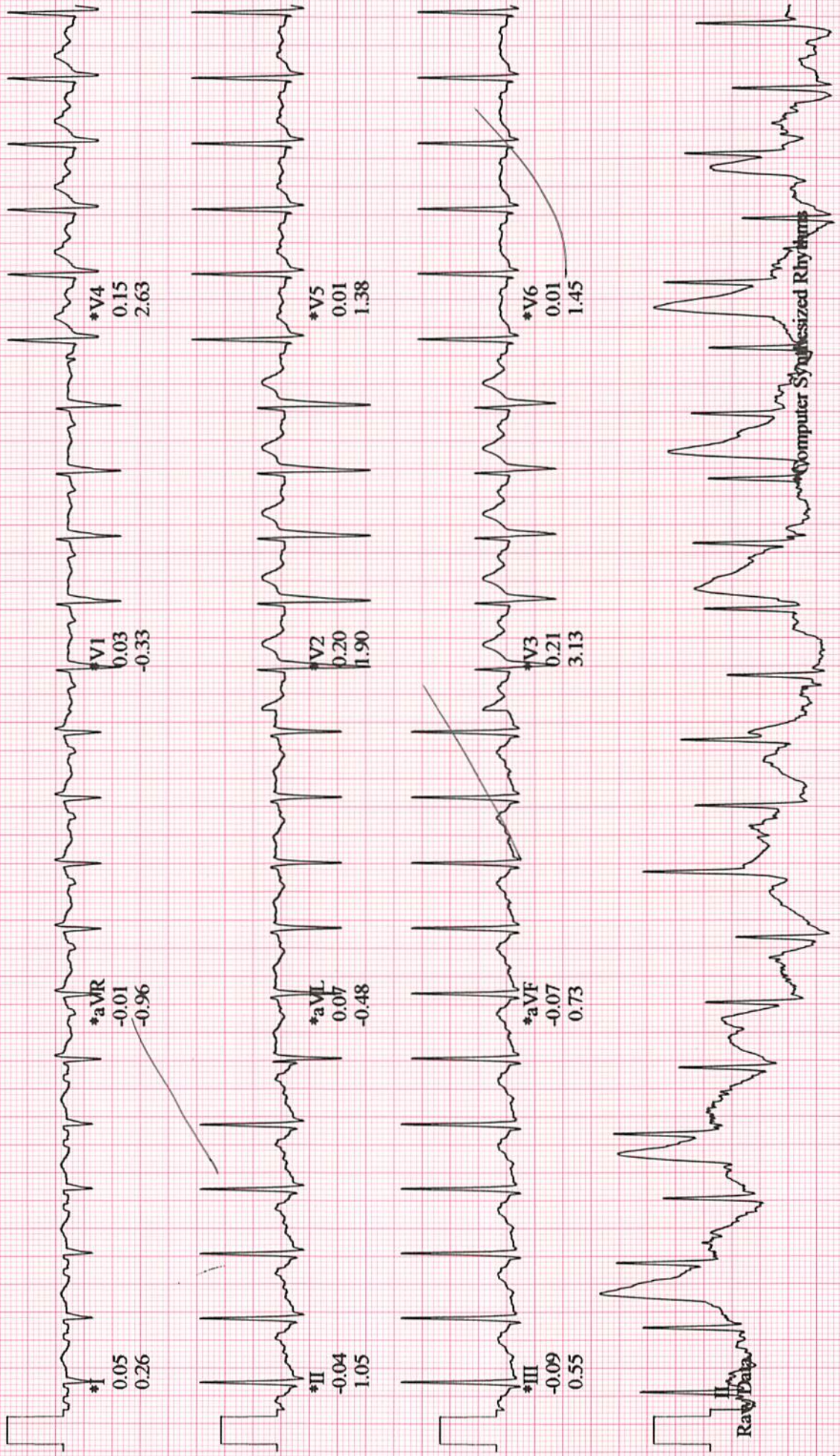
EXERCISE
STAGE 3
08:50

BRUCE
5.4 km/h
14.0 %

MEDIKA PLAZA

Lead
ST Level (mV)
ST Slope (mV/s)

60 ms post J



GE CASE V6.73 25 mm/s 10 mm/mV 50Hz 0.01 - 40Hz FRF- HR(V5,V6)

Start of Test: 9:57:21

ACHMAD CHOIRONI MR

Patient ID: 01035755

10.11.2020

10:09:01

LINKED MEDIANS (PEAK EXERCISE)

EXERCISE STAGE 4

10:36

BRUCE

6.8 km/h

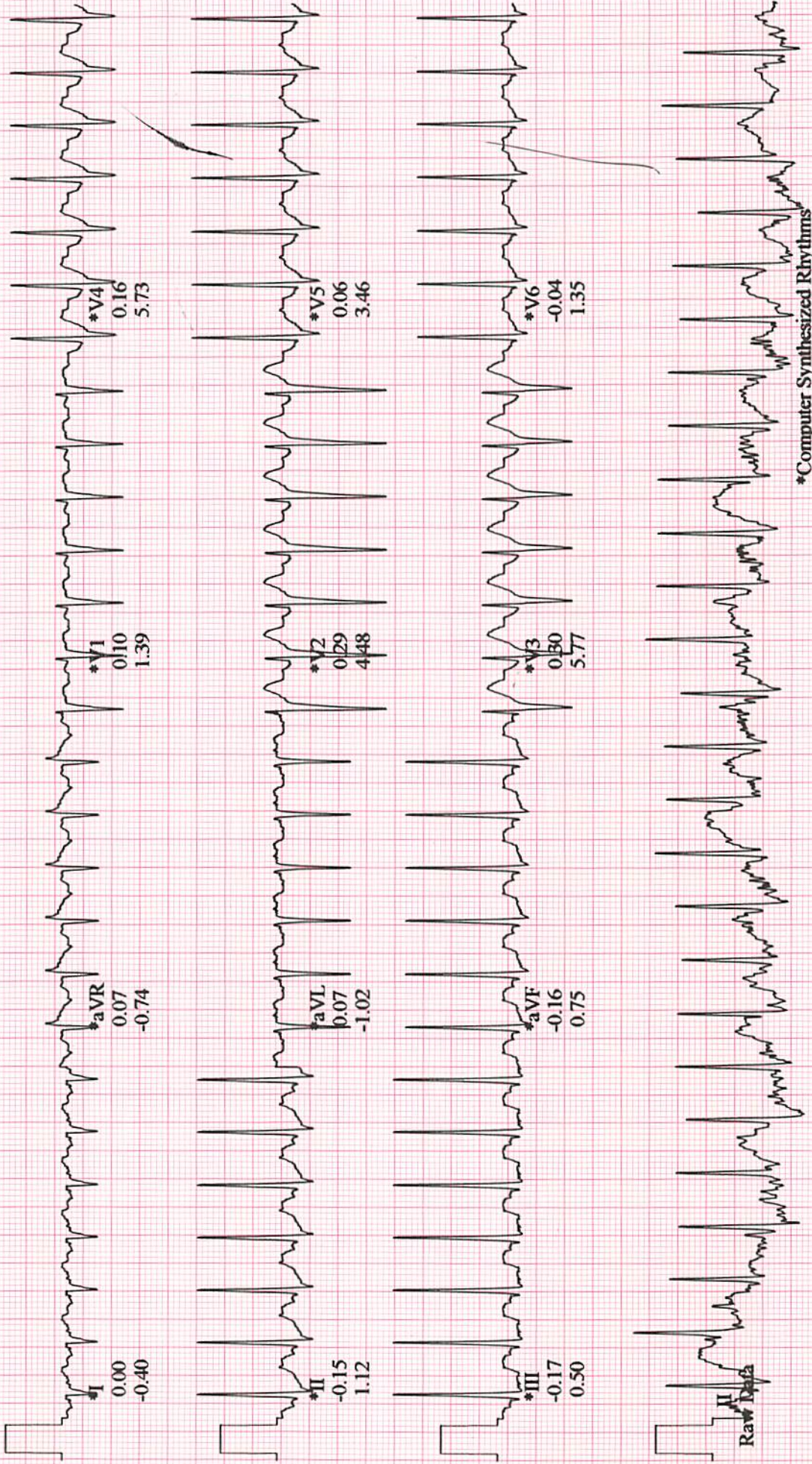
16.0 %

MEDIKA PLAZA

160 bpm

Lead
ST Level (mV)
ST Slope (mV/s)

60 ms post J



GE
CASE V6.73

25 mm/s 10 mm/mV 50Hz 0.01 - 40Hz FRF- HR(V6,V5)

Start of Test: 9:57:21

ACHMAD CHOIRONI MR
Patient ID: 01035755
10.11.2020
10:09:21

LINKED MEDIANS

151 bpm

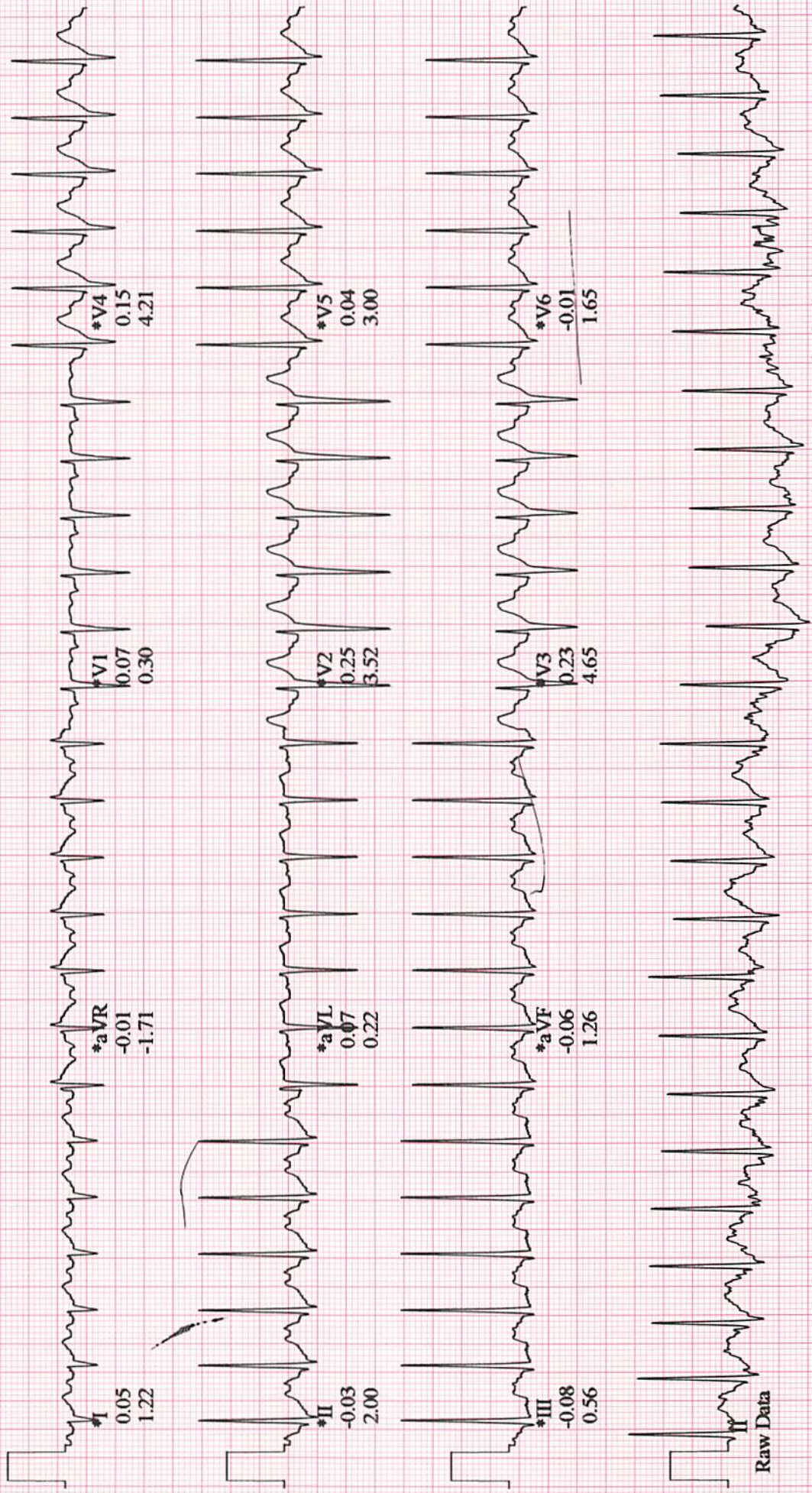
RECOVERY
Recovery 1
00:20

BRUCE
2.4 km/h
0.0 %

MEDIKA PLAZA

Lead
ST Level (mV)
ST Slope (mV/s)

60 ms post J



Raw Data

*Computer Synthesized Rhythms

GE
CASE V6.73

25 mm/s 10 mm/mV 50Hz 0.01 - 40Hz FRF- HR(V6,V5)

Start of Test: 9:57:21

ACHMAD CHOIRONI, MR

Patient ID 01035755

10.11.2020 Male 156 cm 71.1 kg

9:57:21 37yrs Asian

Meds:

Test Reason:

Medical History:

Ref. MD: Ordering MD:

Technician: HESTI Test Type:

Comment:

BRUCE: Total Exercise Time 10:36
 Max HR: 160 bpm 87% of max predicted 183 bpm HR at rest: 78
 Max BP: 130/80 mmHg BP at rest: 120/80 Max RPP: 16250 mmHg*bpm
 Maximum Workload: 13.50 METS
 Max. ST: -0.34 mV, 0.00 mV/s in III; EXERCISE STAGE 4 09:29
 Arrhythmia: VBIG:1, PVC:5, CPLT:1
 ST/HR index: 1.94 μ V/bpm
 ST/HR slope: 2.74 μ V/bpm (II)
 HR reserve used: 78 %
 Freq.VE recovery: 0 VE/min
 QRS duration: BASELINE: 96 ms, PEAK EX: 98 ms, REC: 94 ms
 Location Number: * 0 *

Phase Name	Stage Name	Time in Stage	Speed (km/h)	Grade (%)	Workload (METS)	HR (bpm)	BP (mmHg)	RPP (mmHg*bpm)	VE (/min)	ST Level (III mV)	Comment
PRETEST	SUPINE	00:15	0.00	0.00	1.0	75	120/80	9000	0	0.03	
	STANDING	00:03	0.00	0.00	1.0	74			0	0.03	
	HYPERV.	00:10	0.00	0.00	1.0	75			0	0.03	
EXERCISE	WARM-UP	00:35	1.60	0.00	1.3	84			0	0.03	
	STAGE 1	03:00	2.80	10.00	4.7	93	120/80	11160	0	0.01	
	STAGE 2	03:00	4.00	12.00	7.0	105	120/80	12600	0	-0.03	
	STAGE 3	03:00	5.50	14.00	10.2	130	130/80	16900	0	-0.14	
	STAGE 4	01:36	6.80	16.00	13.5	160			2	-0.17	
RECOVERY	Recovery1	00:36	2.40	0.00	6.7	144			2	-0.04	

[Handwritten Signature]
 MEDIKA BINA MEDIKATAMA

To. Dokter :
(Counsel)

Kindly please counsel for patient who has take cares of

Diagnose :
Clinik Summary :

Counsel Request :

COUNSEL ADVISE

Finding :

Ear: tympanic membrane intact, no cerumen.
nose: clear eustachian tube, no secretions.
Heart: T2 T2 no hyperemic, gurgling
Audiometry: Moderate Hly loss 43.75 dB
Hly threshold 6000-8000 Hz left ear

Diagnosis :

Moderate Hly loss - dextra, Chronic tonsillitis gurgling

Recomendation :

Date :

Time :

EP :

- Stop smoking
- Avoid eating fast food & frizzy drink tomor
- Use ear protect when work in noisy area

Signature **MP+**

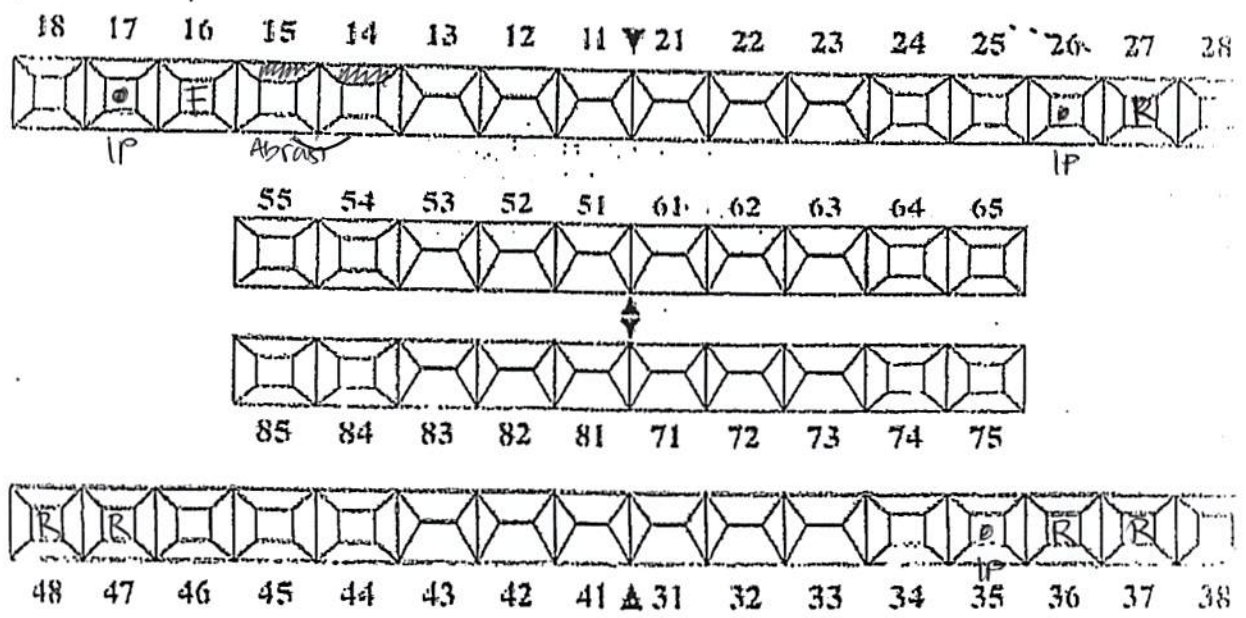
dr. MERISTIANA CHRISTIANE S.P.T.H.KI

SIP: 13/B.155/31.7.2014-1.779.31e/2018

Complete Name

7

DENTAL EXAMINATION			
Name: Achmad Choironi	Sex: M/F	MR :	Visit : 10/11
Comp.: Inspektindo Sinergi	DOB :		



Calculus + 2

DIAGNOSA

kallos baik.
 35, 17, 26 ⇒ IP.
 27, 37, 36, 47, 48 ⇒ GR.
 15, 14 ⇒ Abrasi

TREATMENT PLANNING

pro scaling RA + RB
 35, 17, 26 ⇒ pro LC
 27, 37, 36, 47, 48 ⇒ pro exo
 15, 14 ⇒ pro LC

verified by: drg. Ilona Amalia/ drg. Fajar Sulawati/drg. Siti Darjah/drg. Herlina