

**Certificate Of Health Assessment**

Name	Age	Position	Department
ARI CAHYADI	39 yo	ASST. INSPECTOR	-

**COMPANY :**

**INSPEKTINDO SINERGI PERSADA, PT**

**CONCLUSION**

FIT TO WORK	
FIT WITH MEDICAL NOTE	✓
TEMPORARY UNFIT	
UNFIT	

Issued Date	Doctors Name	Prepared By
24 August 2021	<b>Puteri Melati, MD</b> <i>PKTK : KEP.264/BINWASK3-PNK3/KK/VI/2019</i> <i>SIP : 23/B.15a/31.74.04.1004/-1.779.3/e/2019</i>	
Expired Date		Verified By
24 August 2022	<b>dr. Muhammad Ilyas, Sp.Ok</b> <i>SIP : 29/B.15b/31.74.04.1004.02.009.K.1/3/-1.779.3/e/2019</i>	 PT. KARTIKA BINA MEDIKATAMA

No. Formulir : FM-DR-008-05  
 No. Revisi : 00  
 Tanggal Terbit : 2 Mei 2011

Certificate Number : MP-BOP/1-20210824/131106  
 MCU Validity Check  
<https://mcu-validasi.medikaplaza.com>

## TO WHOM IT MAY CONCERN

### *Kepada yang berkepentingan*

This is certify that today Tuesday, 24 August 2021 Medika Plaza Clinic has performed urine drug screening and/or breath alcohol test to :


*Dengan ini menyatakan bahwa, pada hari ini Selasa, 24 Agustus 2021 Medika Plaza Clinic telah melakukan urine drug screening dan/atau breath alcohol test kepada :*

### **ARI CAHYADI**

With the results are as follows :  
*Dengan hasil sebagai berikut :*

Drugs Test <i>Uji Obat</i>	Result <i>Hasil</i>		
<b>URINE DRUGS SCREENING</b>			
- Amphetamine	<input type="checkbox"/> Non-Negative	<input checked="" type="checkbox"/> Negative	<input type="checkbox"/> N/A
- Met-Amphetamine	<input type="checkbox"/> Non-Negative	<input checked="" type="checkbox"/> Negative	<input type="checkbox"/> N/A
- Cocain	<input type="checkbox"/> Non-Negative	<input checked="" type="checkbox"/> Negative	<input type="checkbox"/> N/A
- THC/Canabis/Marijuana	<input type="checkbox"/> Non-Negative	<input checked="" type="checkbox"/> Negative	<input type="checkbox"/> N/A
- Morphine/Opiates	<input type="checkbox"/> Non-Negative	<input checked="" type="checkbox"/> Negative	<input type="checkbox"/> N/A
- P C P/Phencyclidine	<input type="checkbox"/> Non-Negative	<input checked="" type="checkbox"/> Negative	<input type="checkbox"/> N/A
- Barbiturate	<input type="checkbox"/> Non-Negative	<input type="checkbox"/> Negative	<input checked="" type="checkbox"/> N/A
- Benzodiazepin	<input type="checkbox"/> Non-Negative	<input checked="" type="checkbox"/> Negative	<input type="checkbox"/> N/A
- Methadone	<input type="checkbox"/> Non-Negative	<input checked="" type="checkbox"/> Negative	<input type="checkbox"/> N/A
- Propoxyphene	<input type="checkbox"/> Non-Negative	<input type="checkbox"/> Negative	<input checked="" type="checkbox"/> N/A
- Oxycodone	<input type="checkbox"/> Non-Negative	<input type="checkbox"/> Negative	<input checked="" type="checkbox"/> N/A
- MDMA	<input type="checkbox"/> Non-Negative	<input type="checkbox"/> Negative	<input checked="" type="checkbox"/> N/A
- 6-MAM	<input type="checkbox"/> Non-Negative	<input type="checkbox"/> Negative	<input checked="" type="checkbox"/> N/A
<b>BREATH ALCOHOL TEST</b>			
- Alcohol	<input type="checkbox"/> Non-Negative	<input checked="" type="checkbox"/> Negative	<input type="checkbox"/> N/A

Jakarta, August 24, 2021



PT. KARTIKA BINA MEDIKATAMA  
( dr. Dian Wahyu Tanjungsari, Sp.PK )  
Clinical Patologist

**PT. KARTIKA BINA MEDIKATAMA**

# **HEALTH ASSESSMENT REPORT**

*Of*

**ARI CAHYADI**  
**01.00079742**

**Tuesday, 24 August 2021**

## **MP BELTWAY CLINIC**

Beltway Office Park, Annex Building, Ground Floor  
Jl. TB. Simatupang Kav.41, Jakarta Selatan 12550  
Tlp : (62-21) 808 66 099, Fax : (62-21) 808 66 098  
[www.medikaplaza.com](http://www.medikaplaza.com)

## MP BELTWAY CLINIC

Beltway Office Park, Annex Building, Ground Floor  
Jl. TB. Simatupang Kav.41, Jakarta Selatan 12550  
Tlp : (62-21) 808 66 099, Fax : (62-21) 808 66 098  
www.medikaplaza.com

### PATIENT DATA

MedRec.	: 01.00079742	EMPLOY. STATUS	: Employee
NAME	: ARI CAHYADI	BIRTHDATE	: 09 April 1982
EMPLOYEE No.	: -	SEX	: Male
JOB TITLE	: ASST. INSPECTOR	STATUS	: Married
COMP. NAME	: INSPEKTINDO SINERGI PERSADA, PT	NASIONALITY	: INDONESIA

### SUMMARY

#### MEDICAL FINDING :


1. Dyslipidemia
2. Obesity
3. Gangren pulpa, radix, decayed, calculus and missing teeth
4. Uncorrected previous glasses with partial colour blindness
5. Moderate conductive hearing loss of right ear

Your fitness status is fit with medical note:  
Moderate conductive hearing loss of right ear

#### SUGGESTION :

1. Low fat and carbohydrate diet and exercise regularly minimal 3 times a week
2. Reduce body weight gradually 0.5 Kgs/week, by doing regular exercise (aerobic/jogging), 3-4x/week, 30-45 minutes and reduce high calorie diet until maximal body weight is 66.42 Kgs (present body weight is 84.6 Kgs). Consultation with a Nutritionist for evaluation of obesity
3. Consultation with a Dentist for dental care, minimal once a year or better once in six month
4. You need to change the glasses for distant vision
5. Avoid noisy environment or use earplug properly while working at noisy work environment to prevent further hearing impairment. Consultation with an ENT Specialist for further evaluation and examination of moderate conductive hearing loss of right ear

#### Responsible Doctor



Puteri Melati, MD

#### Notes:

If you need the further information or consultation, please contact us via :

Email : - beltway.doctor@medikaplaza.com  
- Rezkha.Amalia@medikaplaza.com  
- Puteri.Melati@medikaplaza.com

Telepon Klinik : (62-21) 8086 6099

## CLINICAL EVALUATION

Name : ARI CAHYADI	Sex : Male	MR : 01.00079742	Visit : 24/08/2021
Comp.: INSPEKTINDO SINERGI PERSADA, PT		DOB : 09 April 1982	
EXAMINATION	RESULT	NOTES	

### ANAMNESA

#### PRESENT COMPLAINT AND HISTORY OF PRESENT

#### ILLNESS

Present complaint

Flu since yesterday, fever (-), cough (-). Antigen swab negative.

#### MEDICAL HISTORY

Alergy	No
Imunisasi	Yes
Surgery	No
Hospitalization	No
Disease	No

#### LIFE STYLE

Alcohol intake	No	
Smoking	Yes	Mild smoker
Exercise	No	

#### FAMILY MEDICAL HISTORY

Diabetes Melitus	No	
Hypertension	Yes	Father
Heart disease	No	
Lung TB	No	
Kidney disease	No	
Astma	No	
Mental disease	No	
Epilepsy	No	
Cancer	No	
Color blind	No	
Stroke	No	
Liver disease	No	
Bone & joint	No	
Others disease	No	

#### WORK EXPOSURE

Noise	Yes
Heat Stress	No
Cold Stress	No
Vibration	No
Involving height	Yes
Radiation	No

## CLINICAL EVALUATION

Name : ARI CAHYADI	Sex : Male	MR : 01.00079742	Visit : 24/08/2021
--------------------	------------	------------------	--------------------

Comp. : INSPEKTINDO SINERGI PERSADA, PT	DOB : 09 April 1982
---	---------------------

EXAMINATION	RESULT	NOTES
Dust	No	
Toxic chemical	Yes	
Irritating fluid	No	
Smoke	No	
Bacterium/Virus/Parasite	No	
Blood	No	
Animal	No	
Operating heavy mobile equipment	No	
Manual Handling	No	
Sitting continuously over 4 hours	No	
Stand continuously over 4 hours	No	
Using monitor screen more than 4 hours per day	No	
Exposure	No	
Unergonomic body positions	No	
Shift work	No	
Work is not accordance with skills and knowledge	No	
Workload does not accordance with time	No	
Work conflict	No	
Inappropriate task	No	
Career barriers	No	
Family conflict	No	
Working arround rotating machinery	No	
Administration work	No	
Handling food product	No	
Others	Yes	Inspector in offshore area
<b>PHYSICAL EXAMINATION</b>		
General Appearance	Good	
Body shape	Picnicus	
<b>VITAL SIGN</b>		
Body Weight	84.6 Kg	
Body Height	163 Cm	
BMI	31.84 Kg/m <sup>2</sup>	
Normal Weight	49.15 - 66.42 Kg	
BMI Conclusion	Obesity	
Blood Pressure	110/80 mmHg	
Pulse	75 x/minute	
Body Temperature	36.3 °C	

## CLINICAL EVALUATION

Name : ARI CAHYADI	Sex : Male	MR : 01.00079742	Visit : 24/08/2021
Comp.: INSPEKTINDO SINERGI PERSADA, PT		DOB : 09 April 1982	

EXAMINATION	RESULT	NOTES
RR	18	
Neck Circumference	37 Cm	
Arm Circumference	35 Cm	
Chest size	96 Cm	
Abdominal Circumference	90 Cm	
<b>SKIN</b>		
Skin	Normal	
<b>EYE</b>		
Left	Normal	
Right	Normal	
<b>ENT</b>		
Auricle	Normal	
Ear canal	Normal	
Drums	Normal	
Septum/Conchae	Not Examined	
Sinuses	Not Examined	
Pharynx	Not Examined	
Tonsil	Not Examined	
<b>MOUTH</b>		
Gum	Normal	
Dental	Abnormal	Gangren pulpa, radix, decayed, calculus and missing teeth
<b>NECK</b>		
General	Normal	
Thyroid Gland	Normal	
<b>CHEST</b>		
Form	Normal	
Lung	Normal	
Heart	Normal	
Breast	Normal	
<b>ABDOMEN</b>		
Form	Flat	
Palpation	Supple	
Liver	Not Palpable	
Spleen	Not Palpable	
Kidney	No Ballotment	
-	No	

## CLINICAL EVALUATION

Name : ARI CAHYADI	Sex : Male	MR : 01.00079742	Visit : 24/08/2021
--------------------	------------	------------------	--------------------

Comp. : INSPEKTINDO SINERGI PERSADA, PT	DOB : 09 April 1982
---	---------------------

EXAMINATION	RESULT	NOTES
Hernia inguinal	No	
<b>EXTRIMITIES</b>		
Bones,joint	Normal	
Muscles,tonus	Normal	
Fingernails	Normal	
Hand	Normal	
Foot	Normal	
<b>RECTAL EXAMINATION</b>		
Hemorrhoid	Negative	
Rectum	Not Examined	
<b>SENSORIK EXAMINATION</b>		
Tes Raba	Normal	
<b>MOTORIK EXAMINATION</b>		
Tes Grip	Normal	
<b>REFLEX EXAMINATION</b>		
Physiologic reflex	Normal	
Patologic reflex	Normal	
<b>OTHERS EXAMINATION</b>		
Coordination	Normal	
<b>LYMPHE SYSTEM</b>		
Submandibula	Normal	
Neck Gland	Normal	
Armpit gland	Normal	
Inguinal	Normal	



## OPHTHALMOLOGY DIAGNOSTIC

Name : ARI CAHYADI      Sex : Male      MR : 01.00079742      Visit : 24/08/2021

Comp. : INSPEKTINDO SINERGI PERSADA, PT      DOB : 09 April 1982

EXAMINATION		Right	Left
Reading		J1	
Previous Glasses		20/25	20/25
Without Glasses	Distant	-	-
	Near	-	-
Correction	Distant	S-1.00 C-1.00X90 20/20	S-1.00 C-1.00X80 20/20
	Near	-	-
Depth Perception		-	
Tonometry		17.0 mmHg	17.0 mmHg
Funduscopy		NORMAL	NORMAL
Visual Fields		Normal	
Colour Blind Test		Partial Colour Blindness	

Impression : Astigmatismus myopicus kompositus ODS

## RADIOLOGY DIAGNOSTIC

Name : ARI CAHYADI	Sex : Male	MR : 01.00079742	Visit : 24/08/2021
Comp. : INSPEKTINDO SINERGI PERSADA, PT		DOB : 09 April 1982	

EXAMINATION	RESULT
-------------	--------

THORAX PA	No abnormality seen in both lungs. Normal bronchovascular markings in both hili. The heart is normal in size and shape. The mediastinum is not widened. Both sinus and diaphragms are good. No evidence of pleural effusion.
-----------	---

Impression	Normal heart and lungs.
------------	-------------------------

## RADIOLOGY DIAGNOSTIC

Name : ARI CAHYADI	Sex : Male	MR : 01.00079742	Visit : 24/08/2021
Comp. : INSPEKTINDO SINERGI PERSADA, PT		DOB : 09 April 1982	

EXAMINATION	RESULT
-------------	--------

USG ABDOMEN

LIVER:

Normal in size and contour, smooth surface, echoes structure parenchyme which are homogenous. No sign of SOL.

Intrahepatic vascularity and billiary tract are normal.

GALL BLADDER:

Normal in size, contour and surface. No sign of SOL/ sludge/ stone.

BOTH KIDNEYS:

Normal in size, contour and surface. No sign of obstruction/ stone/ SOL.

PANCREAS:

Normal in size, contour and surface. No sign of SOL.

LIEN:

Normal in size and contour, the echoes are homogenous. No sign of SOL.

URINARY BLADDER:

Normal in size, contour and surface. No sign of stone/ SOL.

PROSTATE AND VESICULA SEMINALIS:

Normal in size and contour which are homogenous echoes and no sign of focal lesion/ SOL.

Impression

Normal Sonography.

## LABORATORY RESULT

Name : ARI CAHYADI	MR : 01.00079742	Visit : 24/08/2021	#Lab : IN751025581106
Comp. : INSPEKTINDO SINERGI PERSADA, PT	Sex : Male	DOB : 09 April 1982	
EXAMINATION	RESULT	NORMAL RANGE	

### HEMATOLOGI

ABO/Rh Typing "O" Rh(+) positive

#### Automated Blood Count

White Blood Cell (WBC)	10.4	3.8 - 11.0
Erythrocyte (RBC)	5.2	4.4 - 5.9
Haemoglobin	15.6	13.2 - 17.3
Hematocrit	46	40 - 52
Thrombocytes	315	150 - 440

#### MCV, MCH, MCHC

MCV	89	80 - 100
MCH	30	26 - 34
MCHC	33.8	32 - 36
ESR	18 *	0 - 10

#### Differential Count

Basophils	0	0 - 1
Eosinophil	6 *	2 - 4
Bands / Stab	4	3 - 5
Neutrophils	60	50 - 70
Lymphocytes	23 *	25 - 40
Monocytes	7	2 - 8

### BLD CHEMISTRY/LIPID PROFILE

Total Cholesterol	202 *	Normal/Desireable: <200 Borderline High: 200-239 High: >=240
HDL Cholesterol	51.4	Normal : >40 - <60 Low HDL : <40 Desireable : >=60
LDL Cholesterol	116	Optimal: <100 Near/Above Optimal: 100-129 Borderline High: 130-159 High: 160-189 Very High: >=190
Triglycerides	171 *	Normal : <150 Borderline High: 150-199 High : 200-499 Very High : >=500

### BLD CHEMISTRY/KIDNEY FUNCTION

## LABORATORY RESULT

Name : ARI CAHYADI	MR : 01.00079742	Visit : 24/08/2021	#Lab : IN751025581106
Comp. : INSPEKTINDO SINERGI PERSADA, PT	Sex : Male	DOB : 09 April 1982	

EXAMINATION	RESULT	NORMAL RANGE
Ureum	32.6	10.0 - 50.0
Creatinine	1.2	0.6- 1.3
Uric Acid	4.85	3.50 - 7.20

### BLD CHEMISTRY/LIVER FUNCTION

Total Bilirubin	0.70	0.1 - 1.0
Direct Bilirubin	0.06	0.0 - 0.2
Indirect Bilirubin	0.64	0.0 - 0.8
SGOT(AST)	22	13 - 45
SGPT (ALT)	17	13 - 50
Alkaline Phosphatase	72	30 - 120
Gamma GT	34	0 - 50
Albumin	4.9	3.5 - 5.5
Globulin	2.90	2.3 - 3.5
Total Protein	7.8	6.6 - 8.7

### BLD CHEMISTRY/DIABETES

Glucose Fasting	95	< 100
Glucose Urine	Negative	Negative
Keton Urine	Negative	Negative

#### Blood Glucose 2 PP

Blood Sugar 2 Hours PP	110	< 140
Glucose Urine	Negative	Negative
Keton Urine	Negative	Negative

### SEROLOGI / IMUNOLOGI

HBsAg (Quantitative)	0.33	< 0.90	Non Reactive
	Non Reactive	>= 0.90 to < 1.00	Borderline
		>=1.00	Reactive
		Test method : ECLIA	
Anti HBs (Quantitative)	<2.00	< 10.00	Non Reactive
	Non Reactive	>= 10.00	Reactive
			Test method : ECLIA

### TOXICOLOGY - DRUGS SCREENING

Methadone	Negative	Negative
Phencyclidine	Negative	Negative
THC/Marijuana	Negative	Negative
Amphetamine	Negative	Negative
Benzodiazepines	Negative	Negative
Opiat	Negative	Negative

**LABORATORY RESULT**

Name : ARI CAHYADI MR : 01.00079742 Visit : 24/08/2021 #Lab : IN751025581106

Comp.: INSPEKTINDO SINERGI PERSADA, PT Sex : Male DOB : 09 April 1982

EXAMINATION	RESULT	NORMAL RANGE
Cocain	Negative	Negative
Metamphetamine	Negative	Negative
Alcohol	Negative	Negative

**URINALYSIS****Complete Urine Analysis****Macroscopic**

Color	Yellow	
Turbidity	Clear	Clear
Specific Gravity	1.025	1.000 - 1.030
pH	5.5	4.5 - 8.0
Leucocyte	Negative	Negative
Glucose	Negative	Negative
Nitrit	Negative	Negative
Bilirubin	Negative	Negative
Blood	Negative	Negative
Urobilinogen	Normal	Normal
Protein	Negative	Negative
Keton	Negative	Negative

**Microscopic**

RBC	0-1	0 - 1
WBC	0-1	0 - 4
Cylinder	Negative	
Epithels Squamous	0-2	5 - 15
Crystals	Negative	
Bacteria	Negative	Negative
Others	Negative	

**STOOL / RECTAL SWAP****Faeces Complete****Macroscopic**

Color	Brown	
Consistency	Smooth	
Mucus	Negative	Negative
Blood	Negative	Negative
Pus	Negative	Negative
Parasit	Negative	Negative
Lipid	Negative	Negative

**Microscopic**

**LABORATORY RESULT**

Name : ARI CAHYADI	MR : 01.00079742	Visit : 24/08/2021	#Lab : IN751025581106
Comp.: INSPEKTINDO SINERGI PERSADA, PT	Sex : Male	DOB : 09 April 1982	

EXAMINATION	RESULT	NORMAL RANGE
RBC	0-1	0 - 1
WBC	0-1	0 - 5
Amoeba	Negative	
Ephitels	Positive	Positive
Worm Eggs	Negative	Negative
Yeast	Negative	Negative
Muscle Fiber	Negative	Negative
Others	Negative	Negative
<b>Digestive</b>		
Amylum	Negative	Negative
Fat	Negative	
Fibers	Positive	Positive

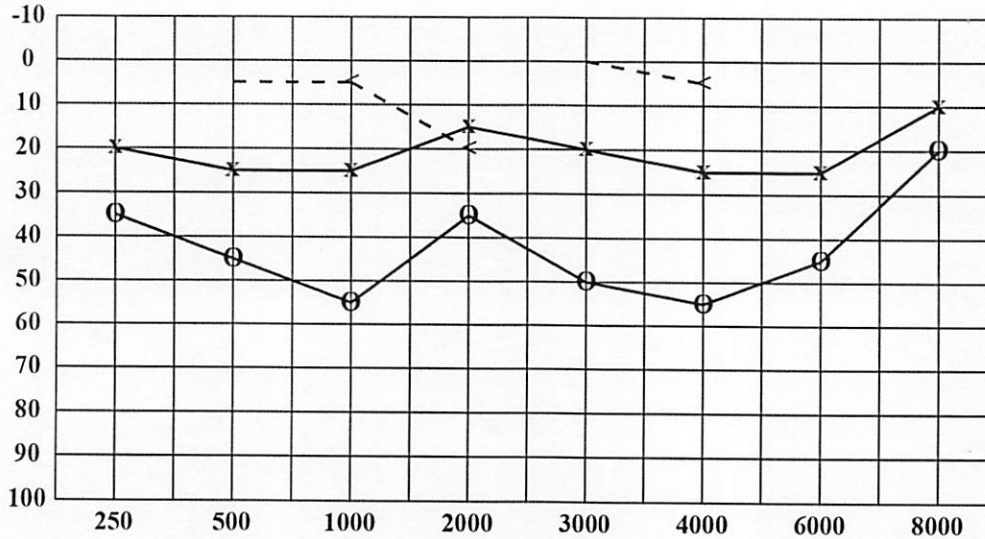
## AUDIOMETRY DIAGNOSTIC

Name : ARI CAHYADI	Sex : Male	MR : 01.00079742	Visit : 24/08/2021
Comp.: INSPEKTINDO SINERGI PERSADA, PT		DOB : 09 April 1982	

### RESULT

Left Ear	250	500	1000	2000	3000	4000	6000	8000
AC	20	25	25	15	20	25	25	10
BC	-	-	-	-	-	-	-	-

Right Ear	250	500	1000	2000	3000	4000	6000	8000
AC	35	45	55	35	50	55	45	20
BC	-	5	5	20	-	5	-	-



< : Right Ear (BC)  
 > : Left Ear (BC)  
 O : Right Ear (AC)  
 X : Left Ear (AC)

Conclusion Right Ear : Moderate conductive hearing loss = 47.5 dB  
 With decreasing on frequency 250Hz, 4000Hz, 6000Hz

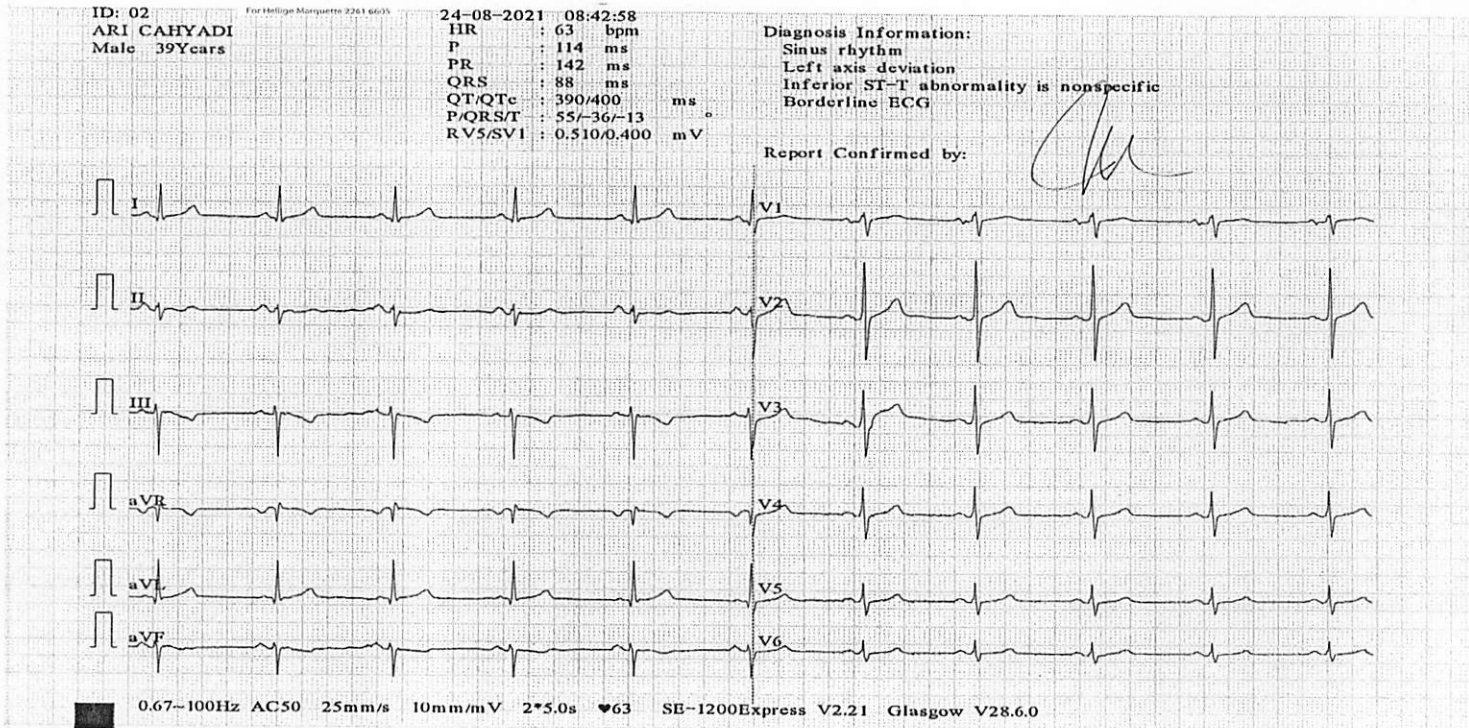
Conclusion Left Ear : Hearing threshold = 22.5 dB  
 (Within normal limit)



## CARDIOLOGY DIAGNOSTIC

Name : ARI CAHYADI	Sex : Male	MR : 01.00079742	Visit : 24/08/2021
Comp.: INSPEKTINDO SINERGI PERSADA, PT		DOB : 09 April 1982	

EXAMINATION	RESULT	Comments :
ELECTROCARDIOGRAPHY	Sinus Rythm axis ( N ), P wave ( N ), PR int 0.16" ST - T segment ( N ), aritmia (-)	Normal ECG
TREADMILL	Sinus Rythm axis ( N ), P wave ( N ), PR int 0.16" ST - T segment ( N ), aritmia (-)	Treadmill Exercise Test : Negative Cardiopulmonary Fitness Classification : Good METs : 13.4





**ARI CAHYADI, MR**

ID: 01.00079742, Born: 4/9/1982 (Male 39), 84.6 kg, 163 cm  
Test Date: 8/24/2021 9:02:18 AM

MEDIKA PLAZA

**Patient info**

orn: 4/9/1982  
ge: 39  
ex: Male  
Veight: 84.6 kg  
leight: 163 cm  
moker:  
acemaker:

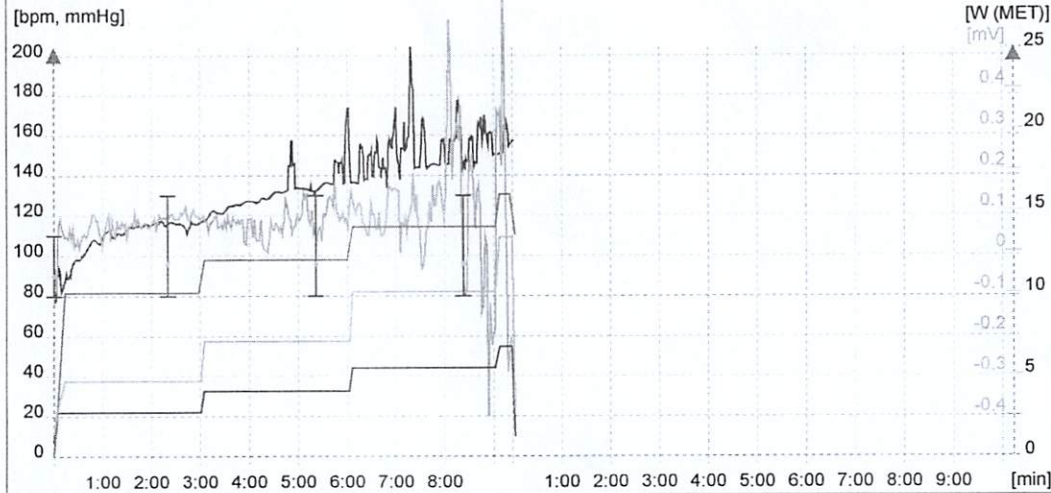
**Medical history**

**Medications**

**Reason for admission**

**Reason for Stop**

**Trends**



**Conclusion**

*[Handwritten signature]*  
 PT. KARTIKA DINA MEDIKATAMA

**Staff**

Physician: user  
Technician:

**Test info**

Test date: 8/24/2021  
 Test time: 9:02 AM  
 Stress device: BTL Treadmill  
 Protocol: Bruce  
 Total duration: 09:22  
 Stress achieved: 6.7km/h, 16.0% (~13.4MET) = 112% predicted (~12.2MET) - for 1 sec  
 HR rest: 89  
 HR peak: 161 = 89% predicted (180) --- 09:2 Exercise (13.4MET)  
 Handgrip test: ---  
 BP rest: 110/80  
 BP peak: ---  
 BP recovery: ---  
 DP rest: 9790  
 DP peak: 18705 = 1.9x DP at rest  
 ST depression max: V6 -1.26mV 03:06 Exercise 7.0ME  
 ST elevation max: V4 1.23mV 01:25 Exercise 4.6ME  
 ST/HR index: 3.6 µV/bpm (abnormal)



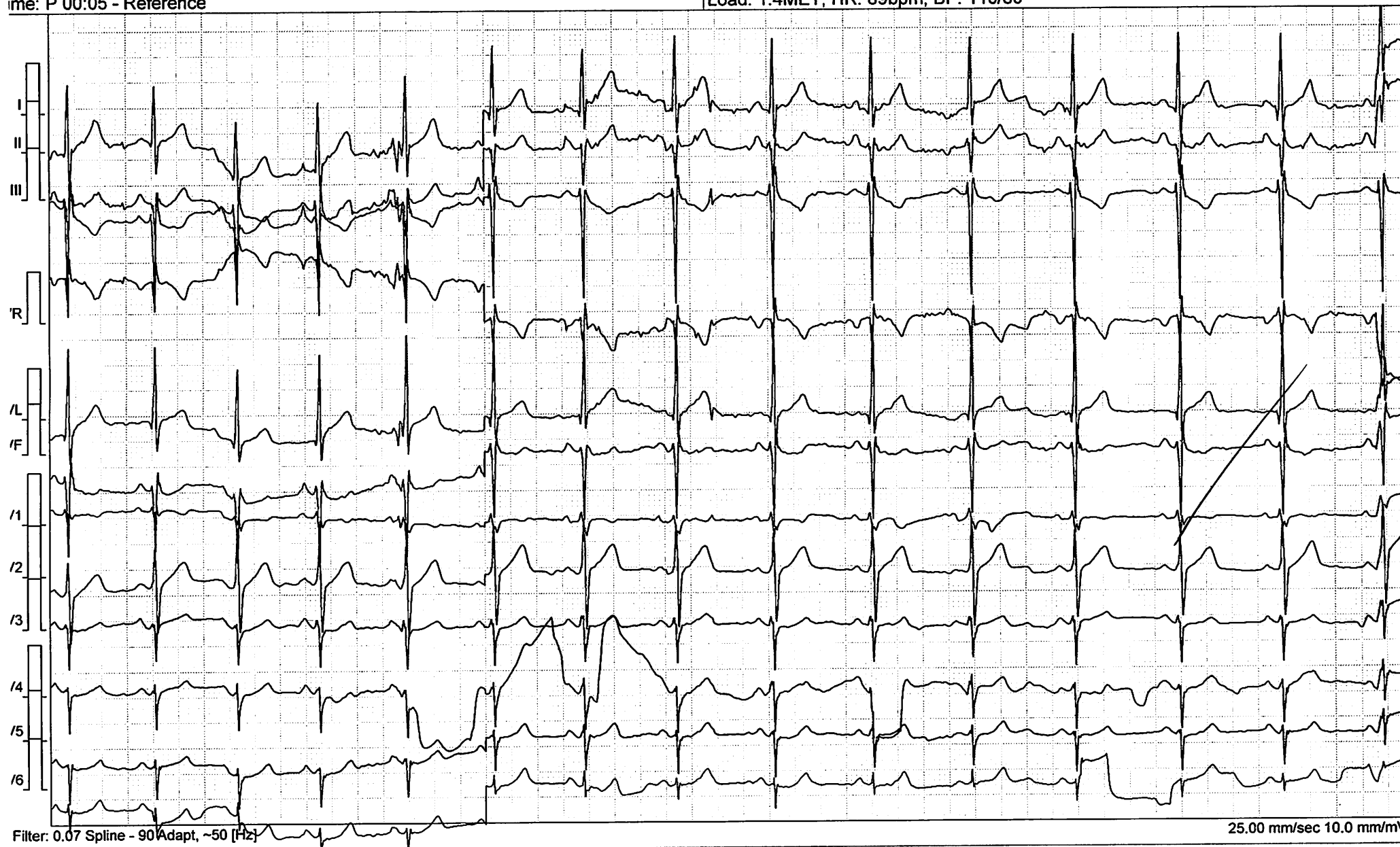
**ARI CAHYADI, MR**

ID: 01.00079742, Born: 4/9/1982 (Male 39), 84.6 kg, 163 cm  
Test Date: 8/24/2021 9:02:18 AM

MEDIKA PLAZA

me: P 00:05 - Reference

Load: 1.4MET, HR: 89bpm, BP: 110/80



Filter: 0.07 Spline - 90 Adapt, ~50 [Hz]

25.00 mm/sec 10.0 mm/mV



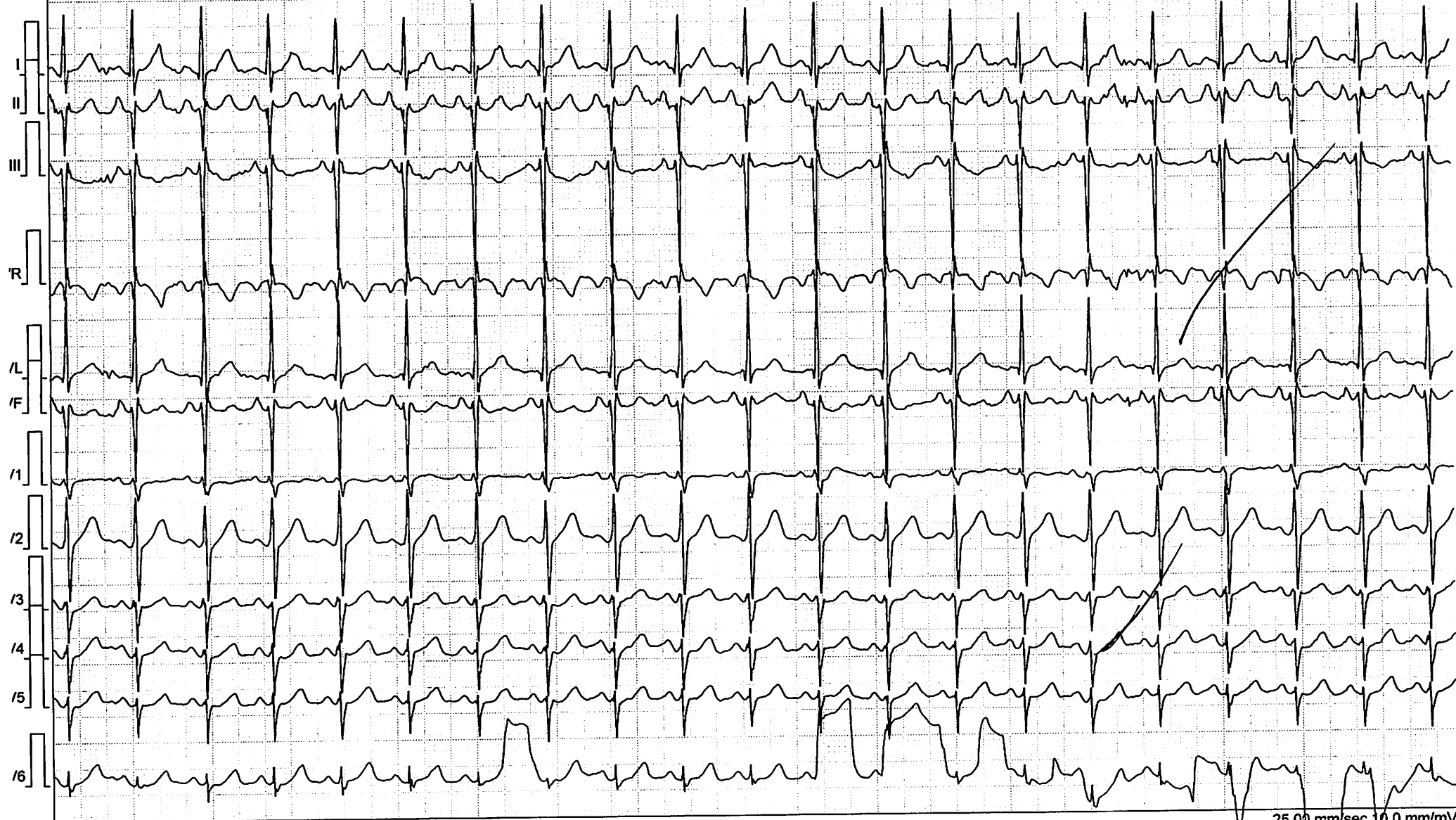
**ARI CAHYADI, MR**

ID: 01.00079742, Born: 4/9/1982 (Male 39), 84.6 kg, 163 cm  
Test Date: 8/24/2021 9:02:18 AM

MEDIKA PLAZA

me: E 02:56 - E1

Load: 4.6MET, HR: 117bpm, BP: 130/80



Filter: 0.07 Spline - 90 Adapt, ~50 [Hz]

25.00 mm/sec 10.0 mm/mV



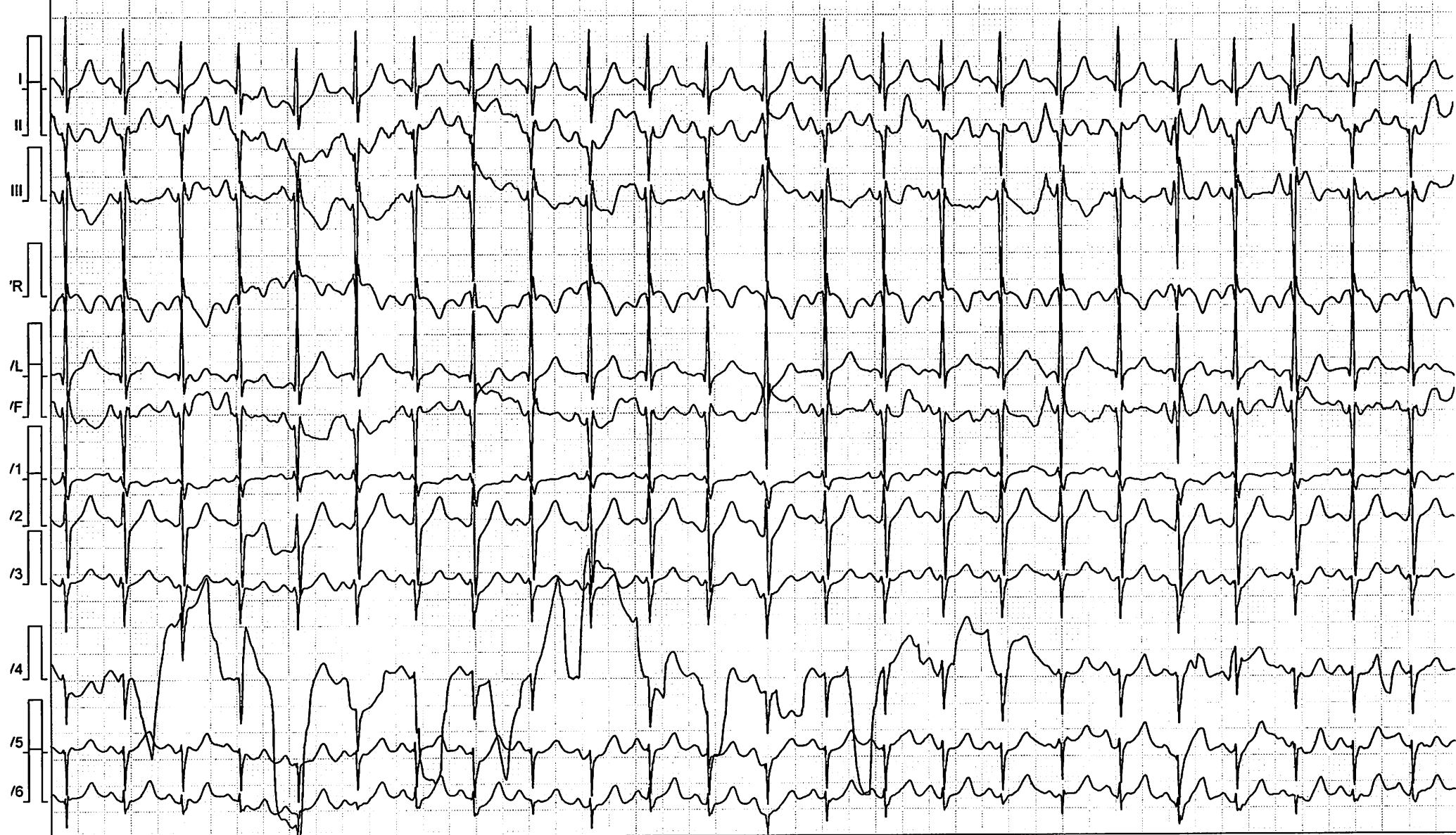
**ARI CAHYADI, MR**

ID: 01.00079742, Born: 4/9/1982 (Male 39), 84.6 kg, 163 cm  
Test Date: 8/24/2021 9:02:18 AM

MEDIKA PLAZA

Time: E 05:58 - E2

Load: 7.0MET, HR: 173bpm, BP: 130/80



Filter: 0.07 Spline - 90 Adapt, ~50 [Hz]

25.00 mm/sec 10.0 mm/mV



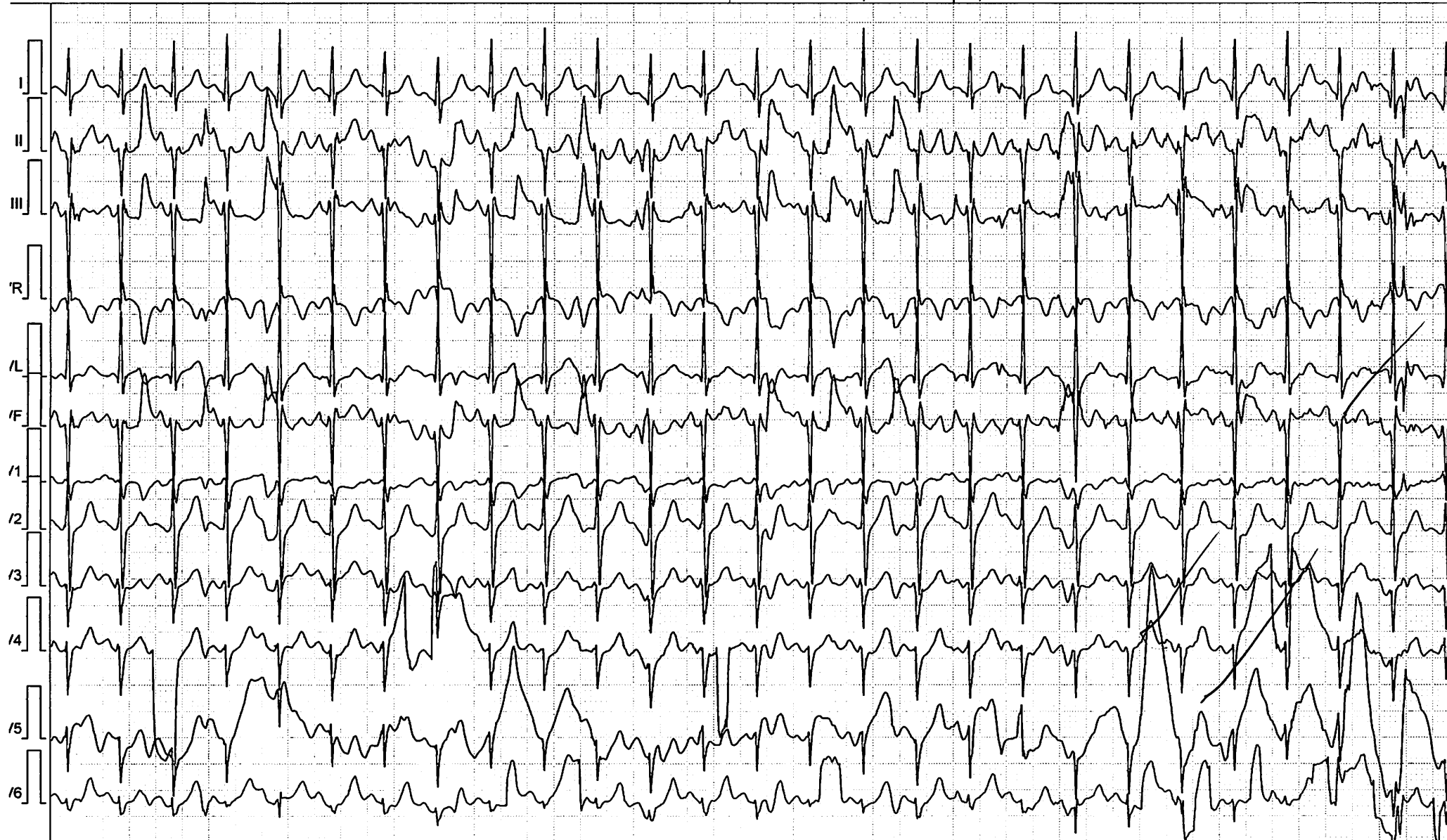**ARI CAHYADI, MR**

ID: 01.00079742, Born: 4/9/1982 (Male 39), 84.6 kg, 163 cm  
Test Date: 8/24/2021 9:02:18 AM

MEDIKA PLAZA

Time: E 08:59 - E3

Load: 10.1MET, HR: 150bpm, BP: 130/80



Filter: 0.07 Spline - 90 Adapt, ~50 [Hz]

25.00 mm/sec 10.0 mm/mV



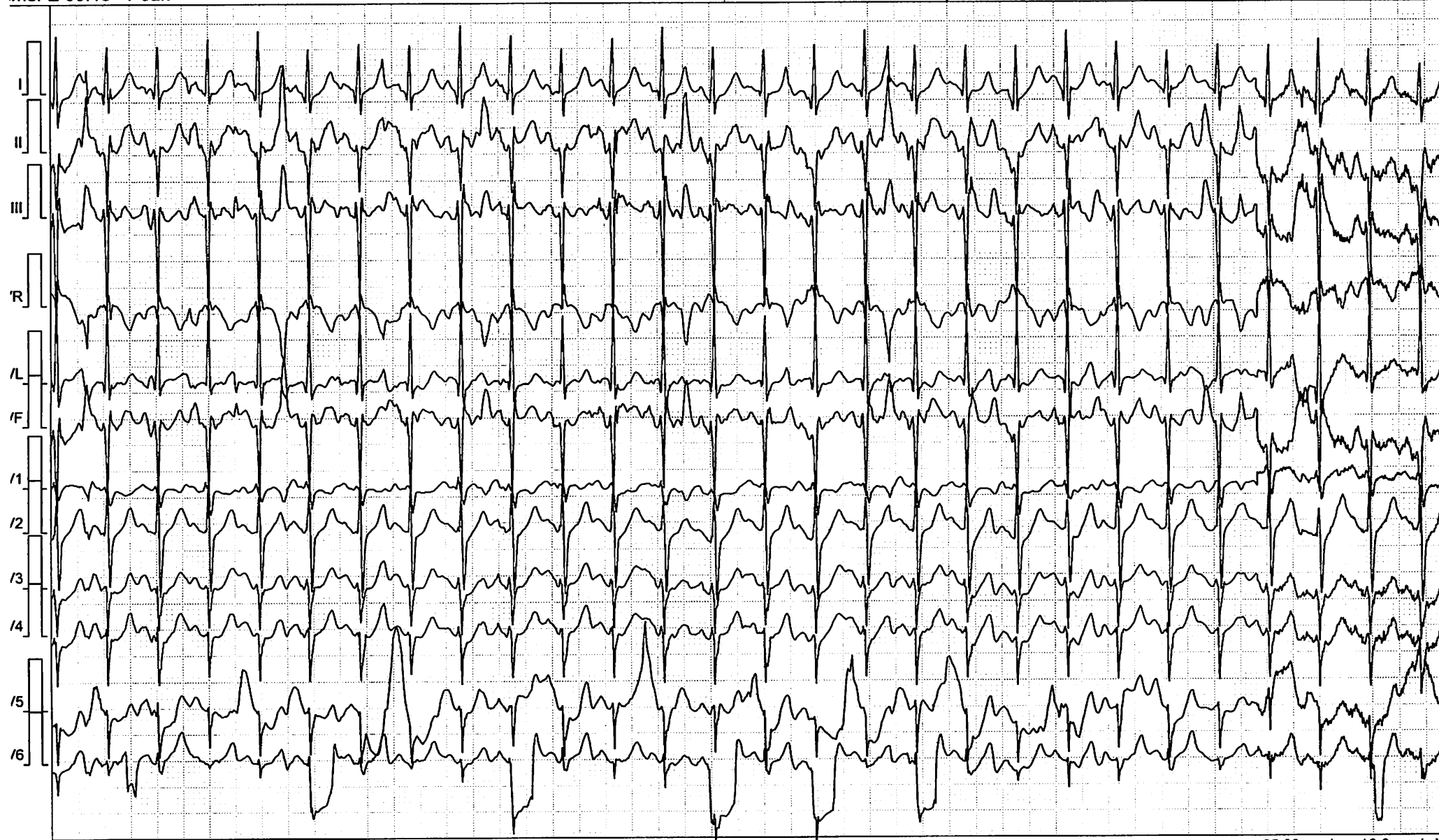
**ARI CAHYADI, MR**

ID: 01.00079742, Born: 4/9/1982 (Male 39), 84.6 kg, 163 cm  
Test Date: 8/24/2021 9:02:18 AM

MEDIKA PLAZA

me: E 09:18 - Peak

Load: 13.4MET, HR: 157bpm, BP: -



Filter: 0.07 Spline - 90 Adapt, ~50 [Hz]

25.00 mm/sec 10.0 mm/mV

**ARI CAHYADI, MR**ID: 01.00079742, Born: 4/9/1982 (Male 39), 84.6 kg, 163 cm  
Test Date: 8/24/2021 9:02:18 AM

MEDIKA PLAZA

Stage	Time	Load			HR bpm	BP mmHg	SpO2 %	ST Level [ mV ], J+: 1/8RR											
		km/h	%	MET				I	II	III	aVR	aVL	aVF	V1	V2	V3	V4	V5	V6
Reference	P 00:15	0.8	0.0	1.4	<b>89</b>	110/80	-	0.22	0.04	-0.18	-0.13	0.21	-0.08	0.02	0.24	0.03	-0.17	0.03	0.00
E 1 stage	E 03:01	2.7	10.0	4.6	<b>116</b>	130/80	-	0.13	0.06	-0.07	-0.10	0.10	-0.01	0.05	0.22	0.08	0.10	0.08	0.08
E 2 stage	E 06:03	4.0	12.0	7.0	<b>136</b>	130/80	-	0.12	0.06	-0.07	-0.09	0.10	-0.01	0.04	0.23	0.08	0.09	0.07	-1.26
E 3 stage	E 09:04	5.4	14.0	10.1	<b>155</b>	130/80	-	0.10	0.04	-0.05	-0.05	0.07	-0.01	0.03	0.18	0.11	0.14	0.34	0.16
E 4 peak	E 09:23	6.7	16.0	13.4	<b>161</b>	-	-	0.06	0.20	0.14	-0.13	-0.04	0.17	-0.05	0.07	0.05	0.08	-0.21	-0.11



# DENTAL EXAMINATION

Name: Ari Cahyadi

Sex: M / F

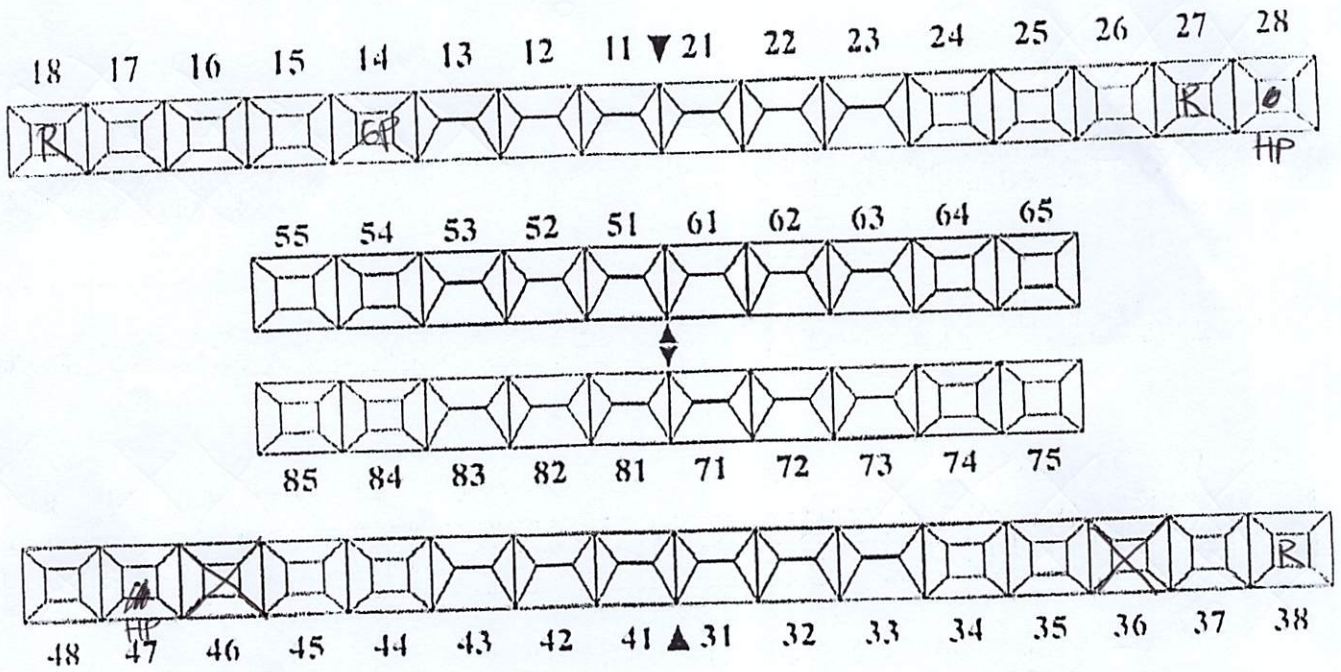
MR :

Visit : 24/8/21

Comp.: Inspektindo Sinergi

DOB : .....

## ODONTOGRAM



### DIAGNOSA

1. Calculus + 3
2. Gangren pulpa : 14.
3. Gangren Radik : 18, 27, 38.
4. Caries : 28, 47.

### TREATMENT PLANNING

1. pro scaling
2. pro review : 14.
3. pro extraxi : 18, 27, 38
4. pro filling : 28, 47

Verified by: drg. Ilona Amalia/ drg. Fajar Sulawati/ drg. Siti Darjah/ drg. Hertina

**MP**  
 PT. KARTIKA BINA MEDIKATAMA  
 24/8/21

PATIENT NAME : Th. Ari Cahyadi  
 No. RM : 01.00079792  
 Klinik/MCU/HCU : Co-ENT

To. Dokter :  
 (Counsel)

Kindly please counsel for patient who has take cares of

Diagnose :  
 Klinik Summary :

Counsel Request :

Ear discharge 2000

Ear Cerument Right ear

COUNSEL ADVISE

Nose Towel empty, septum deviated dexter

Finding :

Throat T3T4 with keratin.

Audiometry : Sinistral heavy threshold normal limit.

Diagnosis :

Moderate hearing loss dextra 47 dB @

Cerument dextra, Moderate hearing loss, hyperthyroidism, septum dev

Recomendation :

Date

: 24 Agustus 2021

Time

EP

- Ear Toiled at ENT

- Audiometry with masky

- Use ear protection

When work in noisy area

- Avoid eating fast food

- Avoid salty drinks to much

Signature

**MP+**  
 dr. KRISTIANA CHRISTIANE, Sp.THT-KL  
 SIP 156/31.74.041-1.779.3/c/2018  
 KARTIKA, BINA MEDIKATAMA  
 Complete Name

Formulir Number : FM - DR - 008 - 02  
 Revisi Number : 00  
 Date : 07 Juli 2017