



Certificate Of Health Assessment

| Name | Age | Position | Department |
|------------------|-------|-----------------|------------|
| TOMMIE R MALONDA | 51 yo | ASST. INSPECTOR | - |

| COMPANY : |
|--|
| INSPEKTINDO SINERGI PERSADA, PT |

| CONCLUSION | | |
|-----------------------|--|---|
| FIT TO WORK | | |
| FIT WITH MEDICAL NOTE | | ✓ |
| TEMPORARY UNFIT | | |
| UNFIT | | |
| Issued Date | Doctors Name | Prepared By |
| 14 July 2022 | Puteri Melati, MD <small>PKTK : KEP.264/BINWASK3-PNK3/KK/VI/2019 SIP : 23/B.15a/31.74.04.1004/-1.779.3/e/2019</small> |  |
| Expired Date | | Verified By |
| 14 July 2023 | dr. Muhammad Ilyas, Sp.Ok <small>SIP : 29/B.15b/31.74.04.1004.02.009.K.1/3/-1.779.3/e/2019</small> |  <small>PT. KARTIKA BINA MEDIKATAMA</small> |

No. Formulir : FM-DR-008-05
 No. Revisi : 00
 Tanggal Terbit : 2 Mei 2011

Certificate Number : MP-BOP/1-20220714/138724
 MCU Validity Check
<https://mcu-validasi.medikaplaza.com>

PT. KARTIKA BINA MEDIKATAMA

TO WHOM IT MAY CONCERN

Kepada yang berkepentingan

This is certify that today Thursday, 14 July 2022 Medika Plaza Clinic has performed urine drug screening and/or breath alcohol test to :


Dengan ini menyatakan bahwa, pada hari ini Kamis, 14 Juli 2022 Medika Plaza Clinic telah melakukan urine drug screening dan/atau breath alcohol test kepada :

TOMMIE R MALONDA

With the results are as follows :
Dengan hasil sebagai berikut :

| Drugs Test <i>Uji Obat</i> | Result <i>Hasil</i> | | |
|-------------------------------|---------------------------------------|--|---|
| URINE DRUGS SCREENING | | | |
| - Amphetamine | <input type="checkbox"/> Non-Negative | <input checked="" type="checkbox"/> Negative | <input type="checkbox"/> N/A |
| - Met-Amphetamine | <input type="checkbox"/> Non-Negative | <input checked="" type="checkbox"/> Negative | <input type="checkbox"/> N/A |
| - Cocain | <input type="checkbox"/> Non-Negative | <input checked="" type="checkbox"/> Negative | <input type="checkbox"/> N/A |
| - THC/Canabis/Marijuana | <input type="checkbox"/> Non-Negative | <input checked="" type="checkbox"/> Negative | <input type="checkbox"/> N/A |
| - Morphine/Opiates | <input type="checkbox"/> Non-Negative | <input checked="" type="checkbox"/> Negative | <input type="checkbox"/> N/A |
| - P C P/Phencyclidine | <input type="checkbox"/> Non-Negative | <input checked="" type="checkbox"/> Negative | <input type="checkbox"/> N/A |
| - Barbiturate | <input type="checkbox"/> Non-Negative | <input type="checkbox"/> Negative | <input checked="" type="checkbox"/> N/A |
| - Benzodiazepin | <input type="checkbox"/> Non-Negative | <input checked="" type="checkbox"/> Negative | <input type="checkbox"/> N/A |
| - Methadone | <input type="checkbox"/> Non-Negative | <input checked="" type="checkbox"/> Negative | <input type="checkbox"/> N/A |
| - Propoxyphene | <input type="checkbox"/> Non-Negative | <input type="checkbox"/> Negative | <input checked="" type="checkbox"/> N/A |
| - Oxycodone | <input type="checkbox"/> Non-Negative | <input type="checkbox"/> Negative | <input checked="" type="checkbox"/> N/A |
| - MDMA | <input type="checkbox"/> Non-Negative | <input type="checkbox"/> Negative | <input checked="" type="checkbox"/> N/A |
| - 6-MAM | <input type="checkbox"/> Non-Negative | <input type="checkbox"/> Negative | <input checked="" type="checkbox"/> N/A |
| BREATH ALCOHOL TEST | | | |
| - Alcohol | <input type="checkbox"/> Non-Negative | <input checked="" type="checkbox"/> Negative | <input type="checkbox"/> N/A |

Jakarta, July 14, 2022



PT. KARTIKA BINA MEDIKATAMA
(dr. Petty Atmadja, Sp.PK)
Clinical Patologist

PT. KARTIKA BINA MEDIKATAMA

HEAD OFFICE : BELTWAY OFFICE PARK, TOWER C, 2nd Floor, Jl. TB. Simatupang Kav 41. Jakarta Selatan 12550, Phone : +62 21 808 66 088, Fax : +62 21 808 66 089

BELTWAY CLINIC : BELTWAY OFFICE PARK, ANNEX BUILDING, Ground Floor, Jl. TB. Simatupang Kav 41. Jakarta Selatan 12550, Phone : +62 21 808 66 099, Fax : +62 21 808 66 098

WTC 2 CLINIC : World Trade Center 2, Lower Ground Floor, Jl. Jend. Sudirman Kav 29. Jakarta Selatan 12920, Phone : +62 21 295 22 611, Fax : +62 21 295 22 610

www.medikaplaza.com

HEALTH ASSESSMENT REPORT

Of

TOMMIE R MALONDA

01.00085150

Thursday, 14 July 2022

MP BELTWAY CLINIC

Beltway Office Park, Annex Building, Ground Floor

Jl. TB. Simatupang Kav.41, Jakarta Selatan 12550

Tlp : (62-21) 808 66 099, Fax : (62-21) 808 66 098

www.medikaplaza.com

MP BELTWAY CLINIC

Beltway Office Park, Annex Building, Ground Floor
Jl. TB. Simatupang Kav.41, Jakarta Selatan 12550
Tlp : (62-21) 808 66 099, Fax : (62-21) 808 66 098
www.medikaplaza.com

PATIENT DATA

| | | | |
|--------------|-----------------------------------|----------------|----------------|
| MedRec. | : 01.00085150 | EMPLOY. STATUS | : Employee |
| NAME | : TOMMIE R MALONDA | BIRTHDATE | : 07 June 1971 |
| EMPLOYEE No. | : - | SEX | : Male |
| JOB TITLE | : ASST. INSPECTOR | STATUS | : Married |
| COMP. NAME | : INSPEKTINDO SINERGI PERSADA, PT | NASIONALITY | : INDONESIA |

SUMMARY

MEDICAL FINDING :

1. Hypertriglyceridemia
2. Non reactive Anti Hbs
3. Prothesa, radix, and missing teeth
4. Decreasing of visual acuity of both eyes
5. USG Abdomen: Fatty liver, Minimally complex cyst right kidney
6. Mild hearing disorder of right ear and Mild conductive hearing loss of left ear

PERCEPTIONS OF EXPOSURE BY WORKERS :

- Noise
- Vibration
- Involving height
- Others (Ast inspector (offshore/onshore))
- Manual Handling


Your fitness status is fit with medical note:

1. Decreasing of visual acuity of both eyes
2. USG Abdomen: Minimally complex cyst right kidney

SUGGESTION :

1. Low fat and carbohydrate diet, exercise regularly minimal 3 times a week
2. Need to get Hepatitis B vaccination (booster)
3. Consultation with a Dentist for dental care, minimal once a year or better once in six month
4. You need to wear the glasses for both vision and consultation with an Ophthalmologist for further evaluation of decreasing of visual acuity of both eyes
5. Low fat diet and exercise regularly minimum 3x/week. Repeat abdominal USG 6 months later and consultation with an Internist to evaluate fatty liver. Consultation with an Urologist for further evaluation of USG Abdomen: Minimally complex cyst right kidney
6. Avoid noisy environment and use earplug properly while working at noisy work environment to prevent further hearing impairment

Responsible Doctor



Puteri Melati, MD

Notes:

If you need the further information or consultation, please contact us via :

Email : - enjelita@medikaplaza.com
- Rezkha.Amalia@medikaplaza.com
- Puteri.Melati@medikaplaza.com

Telepon Klinik : (62-21) 8086 6099

PRIVATE

Printed by : murhasanah

CLINICAL EVALUATION

| Name : TOMMIE R MALONDA | Sex : Male | MR : 01.00085150 | Visit : 14/07/2022 |
|--|------------|--------------------|--------------------|
| Comp.: INSPEKTINDO SINERGI PERSADA, PT | | DOB : 07 June 1971 | |
| EXAMINATION | RESULT | NOTES | |

ANAMNESIS**PRESENT COMPLAINT AND HISTORY OF PRESENT****ILLNESS**

Present complaint

No complaint

MEDICAL HISTORY

| | |
|-----------------|-----|
| Alergy | No |
| Imunisasi | Yes |
| Surgery | No |
| Hospitalization | No |
| Disease | No |

LIFE STYLE

| | | |
|----------------|-----|-----------------------|
| Alcohol intake | No | |
| Smoking | Yes | Stop smoking 3 months |
| Exercise | Yes | Running 1x/week |

FAMILY MEDICAL HISTORY

| | |
|------------------|----|
| Diabetes Melitus | No |
| Hypertension | No |
| Heart disease | No |
| Lung TB | No |
| Kidney disease | No |
| Astma | No |
| Mental disease | No |
| Epilepsy | No |
| Cancer | No |
| Color blind | No |
| Stroke | No |
| Liver disease | No |
| Bone & joint | No |
| Others disease | No |

WORK EXPOSURE

| | |
|------------------|-----|
| Noise | Yes |
| Heat Stress | No |
| Cold Stress | No |
| Vibration | Yes |
| Involving height | Yes |
| Radiation | No |
| Dust | No |

CLINICAL EVALUATION

| | | | |
|--|------------|--------------------|--------------------|
| Name : TOMMIE R MALONDA | Sex : Male | MR : 01.00085150 | Visit : 14/07/2022 |
| Comp.: INSPEKTINDO SINERGI PERSADA, PT | | DOB : 07 June 1971 | |

| EXAMINATION | RESULT | NOTES |
|--|-------------------------|----------------------------------|
| Toxic chemical | No | |
| Irritating fluid | No | |
| Smoke | No | |
| Bacterium/Virus/Parasite | No | |
| Blood | No | |
| Animal | No | |
| Operating heavy mobile equipment | No | |
| Manual Handling | Yes | |
| Sitting continuously over 4 hours | No | |
| Stand continuously over 4 hours | No | |
| Using monitor screen more than 4 hours per day | No | |
| Exposure | No | |
| Unergonomic body positions | No | |
| Shift work | No | |
| Work is not accordance with skills and knowledge | No | |
| Workload does not accordance with time | No | |
| Work conflict | No | |
| Inappropriate task | No | |
| Career barriers | No | |
| Family conflict | No | |
| Working arround rotating machinery | No | |
| Administration work | No | |
| Handling food product | No | |
| Others | Yes | Ast inspector (offshore/onshore) |
| PHYSICAL EXAMINATION | | |
| General Appearance | Good | |
| Body shape | Athleticus | |
| VITAL SIGN | | |
| Body Weight | 65.9 Kg | |
| Body Height | 167 Cm | |
| BMI | 23.62 Kg/m ² | |
| Normal Weight | 51.59 - 69.72 Kg | |
| BMI Conclusion | Normal | |
| Blood Pressure | 120/80 mmHg | |
| Pulse | 74 x/minute | |
| Body Temperature | 36.2 °C | |
| RR | 18 | |

CLINICAL EVALUATION

| | | | |
|---|------------|--------------------|--------------------|
| Name : TOMMIE R MALONDA | Sex : Male | MR : 01.00085150 | Visit : 14/07/2022 |
| Comp. : INSPEKTINDO SINERGI PERSADA, PT | | DOB : 07 June 1971 | |

| EXAMINATION | RESULT | NOTES |
|-------------------------|---------------|------------------------------------|
| Neck Circumference | 38 Cm | |
| Arm Circumference | 34 Cm | |
| Chest size | 93 Cm | |
| Abdominal Circumference | 87 Cm | |
| SKIN | | |
| Skin | Normal | |
| EYE | | |
| Left | Normal | |
| Right | Normal | |
| ENT | | |
| Auricle | Normal | |
| Ear canal | Normal | |
| Drums | Normal | |
| Septum/Conchae | Normal | |
| Sinuses | Normal | |
| Pharynx | Normal | |
| Tonsil | Normal | |
| MOUTH | | |
| Gum | Normal | |
| Dental | Abnormal | Prothesa, radix, and missing teeth |
| NECK | | |
| General | Normal | |
| Thyroid Gland | Normal | |
| CHEST | | |
| Form | Normal | |
| Lung | Normal | |
| Heart | Normal | |
| Breast | Normal | |
| ABDOMEN | | |
| Form | Flat | |
| Palpation | Supple | |
| Liver | Not Palpable | |
| Spleen | Not Palpable | |
| Kidney | No Ballotment | |
| Nyeri Ketok (CVA) | No | |
| Hernia inguinal | No | |
| EXTRIMITIES | | |

CLINICAL EVALUATION

| | | | |
|--|-------------------|-------------------------|---------------------------|
| Name : TOMMIE R MALONDA | Sex : Male | MR : 01.00085150 | Visit : 14/07/2022 |
| Comp. : INSPEKTINDO SINERGI PERSADA, PT | | | DOB : 07 June 1971 |

| EXAMINATION | RESULT | NOTES |
|-----------------------------------|----------|-------|
| Bones,joint | Normal | |
| Muscles,tonus | Normal | |
| Fingernails | Normal | |
| Hand | Normal | |
| Foot | Normal | |
| RECTAL EXAMINATION | | |
| Hemorrhoid | Negative | |
| Rectum | Normal | |
| SENSORIK EXAMINATION | | |
| Tes Raba | Normal | |
| MOTORIK EXAMINATION | | |
| Tes Grip | Normal | |
| REFLEX EXAMINATION | | |
| Physiologic reflex | Normal | |
| Patologic reflex | Normal | |
| OTHERS EXAMINATION | | |
| Coordination | Normal | |
| LIMPHE SYSTEM | | |
| Submandibula | Normal | |
| Neck Gland | Normal | |
| Armpit gland | Normal | |
| Inguinal | Normal | |
| MUSKULOSKLETAL EXAMINATION | | |
| Lhermitte Test | Negative | |
| Spurling Test | Negative | |
| Neers Test | Negative | |
| Yergason Test | Negative | |
| Phalen Test | Negative | |
| Tinel Test | Negative | |
| Finkelstein Test | Negative | |
| Straight Leg Raise Test | Negative | |

OPHTHALMOLOGY DIAGNOSTIC

| | | | |
|-------------------------|------------|------------------|--------------------|
| Name : TOMMIE R MALONDA | Sex : Male | MR : 01.00085150 | Visit : 14/07/2022 |
|-------------------------|------------|------------------|--------------------|

| | |
|---|--------------------|
| Comp. : INSPEKTINDO SINERGI PERSADA, PT | DOB : 07 June 1971 |
|---|--------------------|

| EXAMINATION | | Right | Left |
|-------------------|---------|-------------------------|------------------------|
| Reading | | - | |
| Previous Glasses | | - | - |
| Without Glasses | Distant | 20/100 | 20/70 |
| | Near | J3 | J3 |
| Correction | Distant | S-0.75 C-1.50X140 20/25 | S-1.00 C-0.50X30 20/20 |
| | Near | S+2.25 J1 | S+2.25 J1 |
| Depth Perception | | - | |
| Tonometry | | 18.0 mmHg | 19.0 mmHg |
| Funduscopy | | NORMAL | NORMAL |
| Visual Fields | | Normal | |
| Colour Blind Test | | Normal | |

Impression : Astigmatismus myopicus kompositus ODS
 Presbyopia

RADIOLOGY DIAGNOSTIC

| | | | |
|---|------------|--------------------|--------------------|
| Name : TOMMIE R MALONDA | Sex : Male | MR : 01.00085150 | Visit : 14/07/2022 |
| Comp. : INSPEKTINDO SINERGI PERSADA, PT | | DOB : 07 June 1971 | |

| EXAMINATION | RESULT |
|-------------|--------|
|-------------|--------|

USG ABDOMEN

LIVER:

Normal in size and contour, smooth surface, echoes structure parenchyme which are homogenous increase. No sign of SOL.

Intrahepatic vascularity and billiary tract are normal.

GALL BLADDER:

Normal in size, contour and surface. No sign of SOL/ sludge/ stone.

BOTH KIDNEYS:

Normal in size, contour and surface. No sign of obstruction/ stone. There is round anechoic lesion, posterior enhancement and calcification (+), size +/- 1,91 cm at upper pole right kidney.

PANCREAS:

Normal in size, contour and surface. No sign of SOL.

LIEN:

Normal in size and contour, the echoes are homogenous. No sign of SOL.

URINARY BLADDER:

Normal in size, contour and surface. No sign of stone/ SOL.

PROSTATE AND VESICULA SEMINALIS:

Normal in size and contour which are homogenous echoes and no sign of focal lesion/ SOL.

Impression

Fatty liver

Minimally complex cyst right kidney

Other intra abdominal organs are normal

RADIOLOGY DIAGNOSTIC

| | | | |
|--|-------------------|---------------------------|---------------------------|
| Name : TOMMIE R MALONDA | Sex : Male | MR : 01.00085150 | Visit : 14/07/2022 |
| Comp. : INSPEKTINDO SINERGI PERSADA, PT | | DOB : 07 June 1971 | |

| EXAMINATION | RESULT |
|-------------|--------|
|-------------|--------|

THORAX PA

No abnormality seen in both lungs.
Normal bronchovascular markings in both hili.
The heart is normal in size and shape.
The mediastinum is not widened.
Both sinus and diaphragms are good.
No evidence of pleural effusion.

Impression

Normal heart and lungs.

LABORATORY RESULT

| Name : TOMMIE R MALONDA | MR : 01.00085150 | Visit : 14/07/2022 | #Lab : IN783529421724 |
|---|------------------|--------------------|-----------------------|
| Comp. : INSPEKTINDO SINERGI PERSADA, PT | Sex : Male | DOB : 07 June 1971 | |
| EXAMINATION | RESULT | NORMAL RANGE | |

HEMATOLOGI

ABO/Rh Typing "O" Rh(+) positive

Automated Blood Count

| | | |
|------------------------|--------|-------------|
| White Blood Cell (WBC) | 9.4 | 3.8 - 11.0 |
| Erythrocyte (RBC) | 5.8 | 4.4 - 5.9 |
| Haemoglobin | 17.5 * | 13.2 - 17.3 |
| Hematocrit | 50 | 40 - 52 |
| Thrombocytes | 276 | 150 - 440 |

MCV, MCH, MCHC

| | | |
|------|------|----------|
| MCV | 85 | 80 - 100 |
| MCH | 30 | 26 - 34 |
| MCHC | 35.1 | 32 - 36 |
| ESR | 2 | 0 - 10 |

Differential Count

| | | |
|--------------|------|---------|
| Basophils | 1 | 0 - 1 |
| Eosinophil | 8 * | 2 - 4 |
| Bands / Stab | 4 | 3 - 5 |
| Neutrophils | 58 | 50 - 70 |
| Lymphocytes | 22 * | 25 - 40 |
| Monocytes | 7 | 2 - 8 |

BLD CHEMISTRY/LIPID PROFILE

| | | |
|-------------------|-------|---|
| Total Cholesterol | 184 | Normal/Desireable: <200 Borderline High: 200-239 High: >=240 |
| HDL Cholesterol | 54.5 | Normal : >40 - <60 Low HDL : <40 Desireable : >=60 |
| LDL Cholesterol | 91 | Optimal: <100 Near/Above Optimal: 100-129 Borderline High: 130-159 High: 160-189 Very High: >=190 |
| Triglycerides | 191 * | Normal : <150 Borderline High: 150-199 High : 200-499 Very High : >=500 |

BLD CHEMISTRY/KIDNEY FUNCTION

LABORATORY RESULT

| | | | |
|--|------------------|--------------------|-----------------------|
| Name : TOMMIE R MALONDA | MR : 01.00085150 | Visit : 14/07/2022 | #Lab : IN783529421724 |
| Comp.: INSPEKTINDO SINERGI PERSADA, PT | Sex : Male | DOB : 07 June 1971 | |

| EXAMINATION | RESULT | NORMAL RANGE |
|-------------|--------|--------------|
| Ureum | 23.6 | 10.0 - 50.0 |
| Creatinine | 0.67 | 0.60 - 1.30 |
| Uric Acid | 6.26 | 3.50 - 7.20 |

BLD CHEMISTRY/LIVER FUNCTION

| | | |
|----------------------|------|-----------|
| Total Bilirubin | 0.80 | 0.1 - 1.0 |
| Direct Bilirubin | 0.12 | 0.0 - 0.2 |
| Indirect Bilirubin | 0.68 | 0.0 - 0.8 |
| SGOT(AST) | 29 | 13 - 45 |
| SGPT (ALT) | 42 | 13 - 50 |
| Alkaline Phosphatase | 77 | 30 - 120 |
| Gamma GT | 31 | 0 - 50 |
| Albumin | 4.6 | 3.5 - 5.5 |
| Globulin | 3.20 | 2.3 - 3.5 |
| Total Protein | 7.8 | 6.6 - 8.7 |

BLD CHEMISTRY/DIABETES

| | | |
|-----------------|----------|----------|
| Glucose Fasting | 98 | < 100 |
| Glucose Urine | Negative | Negative |
| Keton Urine | Negative | Negative |

Blood Glucose 2 PP

| | | |
|------------------------|----------|----------|
| Blood Sugar 2 Hours PP | 85 | < 140 |
| Glucose Urine | Negative | Negative |
| Keton Urine | Negative | Negative |

SEROLOGI / IMUNOLOGI

| | | |
|-------------------------|-------|-------------|
| HBsAg (Quantitative) | 0.00 | 0.00 - 0.03 |
| Anti Hbs (Quantitative) | 0.4 * | >= 5.0 |

TOXICOLOGY - DRUGS SCREENING

| | | |
|-----------------|----------|----------|
| Methadone | Negative | Negative |
| Phencyclidine | Negative | Negative |
| THC/Marijuana | Negative | Negative |
| Amphetamine | Negative | Negative |
| Benzodiazepines | Negative | Negative |
| Opiat | Negative | Negative |
| Cocain | Negative | Negative |
| Metamphetamine | Negative | Negative |
| Alcohol | Negative | Negative |

URINALYSIS

Complete Urine Analysis

LABORATORY RESULT

| Name : TOMMIE R MALONDA | MR : 01.00085150 | Visit : 14/07/2022 | #Lab : IN783529421724 |
|--|------------------|--------------------|-----------------------|
| Comp.: INSPEKTINDO SINERGI PERSADA, PT | Sex : Male | DOB : 07 June 1971 | |
| EXAMINATION | RESULT | NORMAL RANGE | |

Macroscopic

| | | |
|------------------|----------|---------------|
| Color | Yellow | |
| Turbidity | Clear | Clear |
| Specific Gravity | 1.007 | 1.000 - 1.030 |
| pH | 7.0 | 4.5 - 8.0 |
| Leucocyte | Negative | Negative |
| Glucose | Negative | Negative |
| Nitrit | Negative | Negative |
| Bilirubin | Negative | Negative |
| Blood | Negative | Negative |
| Urobilinogen | Normal | Normal |
| Protein | Negative | Negative |
| Keton | Negative | Negative |

Microscopic

| | | |
|-------------------|----------|----------|
| RBC | 0-1 | 0 - 1 |
| WBC | 0-2 | 0 - 4 |
| Cylinder | Negative | |
| Epithels Squamous | 0-3 | 5 - 15 |
| Crystals | Negative | |
| Bacteria | Negative | Negative |
| Others | Negative | |

STOOL / RECTAL SWAP

Faeces Complete

Macroscopic

| | | |
|-------------|----------|----------|
| Color | Brown | |
| Consistency | Smooth | |
| Mucus | Negative | Negative |
| Blood | Negative | Negative |
| Pus | Negative | Negative |
| Parasit | Negative | Negative |
| Lipid | Negative | Negative |

Microscopic

| | | |
|-----------|----------|----------|
| RBC | 0-1 | 0 - 1 |
| WBC | 0-1 | 0 - 5 |
| Amoeba | Negative | |
| Ephitels | Positive | Positive |
| Worm Eggs | Negative | Negative |

LABORATORY RESULT

| | | | |
|-------------------------|------------------|--------------------|-----------------------|
| Name : TOMMIE R MALONDA | MR : 01.00085150 | Visit : 14/07/2022 | #Lab : IN783529421724 |
|-------------------------|------------------|--------------------|-----------------------|

| | | |
|--|------------|--------------------|
| Comp.: INSPEKTINDO SINERGI PERSADA, PT | Sex : Male | DOB : 07 June 1971 |
|--|------------|--------------------|

| EXAMINATION | RESULT | NORMAL RANGE |
|------------------|----------|--------------|
| Yeast | Negative | Negative |
| Muscle Fiber | Negative | Negative |
| Others | Negative | Negative |
| Digestive | | |
| Amylum | Negative | Negative |
| Fat | Negative | |
| Fibers | Positive | Positive |

SPIROMETRY DIAGNOSTIC

| | | | |
|---|------------|--------------------|--------------------|
| Name : TOMMIE R MALONDA | Sex : Male | MR : 01.00085150 | Visit : 14/07/2022 |
| Comp. : INSPEKTINDO SINERGI PERSADA, PT | | DOB : 07 June 1971 | |

| EXAMINATION | RESULT |
|-------------|--------|
|-------------|--------|


| | |
|----------------------------|-----------------------|
| FVC Result | : 3.38 L---> 92.3 % |
| FEV1 Result | : 2.66 L---> 86.9 % |
| FEV1/FVC Result | : 78.70 %---> 108.1 % |
| PEF Result | : 4.92 L/S---> 49 % |
| Indonesian Standart Result | : |
| Index | : |
| Spirometry Result | : Normal |

Impression : Normal Spirometric Functions

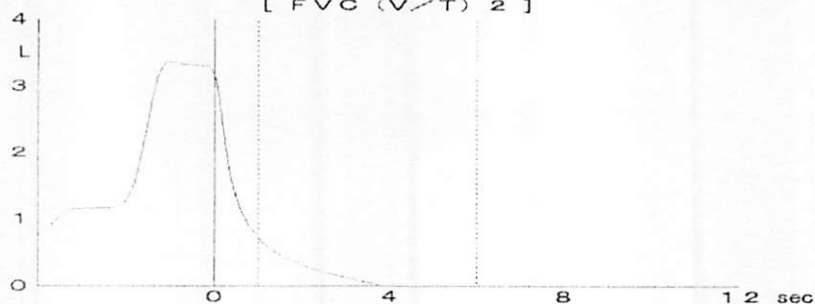
[COPD CLASSIFICATION]

| | |
|-------------------------------|---------|
| FEV1/FVC | 78.70 % |
| %FEV1.0 | 86.90 % |
| Stage | Normal |
| Recommended treatment by GOLD | |

[FVC (F/V)]



[FVC (V/T) 2]

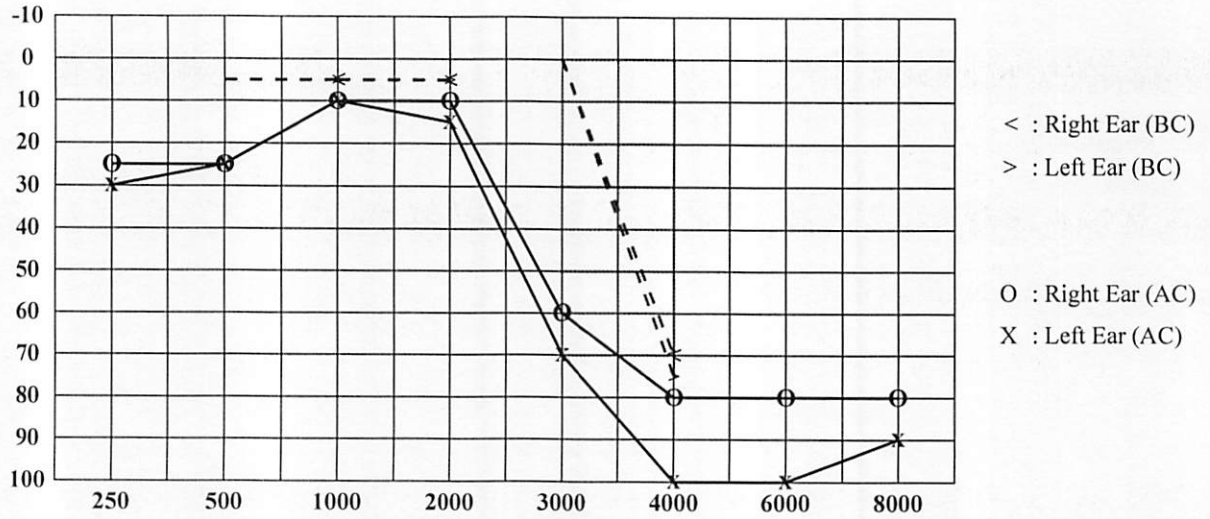


AUDIOMETRY DIAGNOSTIC

| | | | |
|---|------------|--------------------|--------------------|
| Name : TOMMIE R MALONDA | Sex : Male | MR : 01.00085150 | Visit : 14/07/2022 |
| Comp. : INSPEKTINDO SINERGI PERSADA, PT | | DOB : 07 June 1971 | |

RESULT

| Left Ear | 250 | 500 | 1000 | 2000 | 3000 | 4000 | 6000 | 8000 | Right Ear | 250 | 500 | 1000 | 2000 | 3000 | 4000 | 6000 | 8000 |
|----------|-----|-----|------|------|------|------|------|------|-----------|-----|-----|------|------|------|------|------|------|
| AC | 30 | 25 | 10 | 15 | 70 | 100 | 100 | 90 | AC | 25 | 25 | 10 | 10 | 60 | 80 | 80 | 80 |
| BC | - | 5 | 5 | 5 | - | 75 | - | - | BC | - | 5 | 5 | 5 | - | 70 | - | - |



Conclusion Right Ear : Mild hearing disorder = 31.25 dB
 With decreasing on frequency 4000Hz - 8000Hz

Conclusion Left Ear : Mild conductive hearing loss = 37.5 dB
 With decreasing on frequency
 250Hz, 4000Hz, 6000Hz, 8000Hz

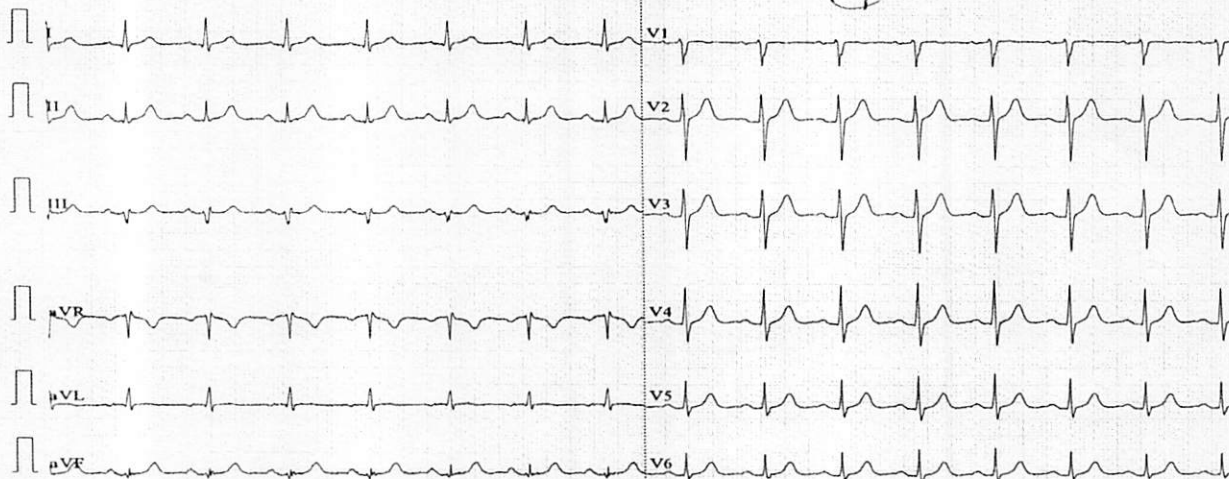
CARDIOLOGY DIAGNOSTIC

| | | | |
|--|------------|--------------------|--------------------|
| Name : TOMMIE R MALONDA | Sex : Male | MR : 01.00085150 | Visit : 14/07/2022 |
| Comp.: INSPEKTINDO SINERGI PERSADA, PT | | DOB : 07 June 1971 | |

| EXAMINATION | RESULT | Comments : |
|---------------------|---|---|
| TREADMILL | Sinus Rythm axis (N), P wave (N), PR int 0.16" ST - T segment (N), aritmia (-) | Treadmill Exercise Test : Negative Cardiopulmonary Fitness Classification : Good METs : 13.4 |
| ELECTROCARDIOGRAPHY | Sinus Rythm axis (N), P wave (N), PR int 0.16" ST - T segment (N), aritmia (-) | Normal ECG |

ID: 28 14-07-2022 09:04:06 SONGMED
 TOMMIE R MALONDA HR : 91 bpm **Diagnosis Information:**
 Male 51Years P : 110 ms Sinus rhythm
 PR : 168 ms Small inferior Q waves; infarct cannot be excluded
 QRS : 82 ms **Borderline ECG**
 QT/QTc : 334/411 ms
 P/QRS/T : 54/13/57 mV
 RV5/SV1 : 0.855/0.732 mV

Report Confirmed by:



0.67-100Hz AC50 25mm/s 10mm/mV 2*5.0s ♡91 SE-1200Express V2.21 Glasgow V28.6.0 Klinik Medika Plaza BOP



TOMMIE R MALONDA, MR

ID: 01.00085150, Born: 6/7/1971 (Male 51), 65 kg, 167 cm
Test Date: 7/14/2022 10:28:27 AM

MEDIKA PLAZA

Patient info

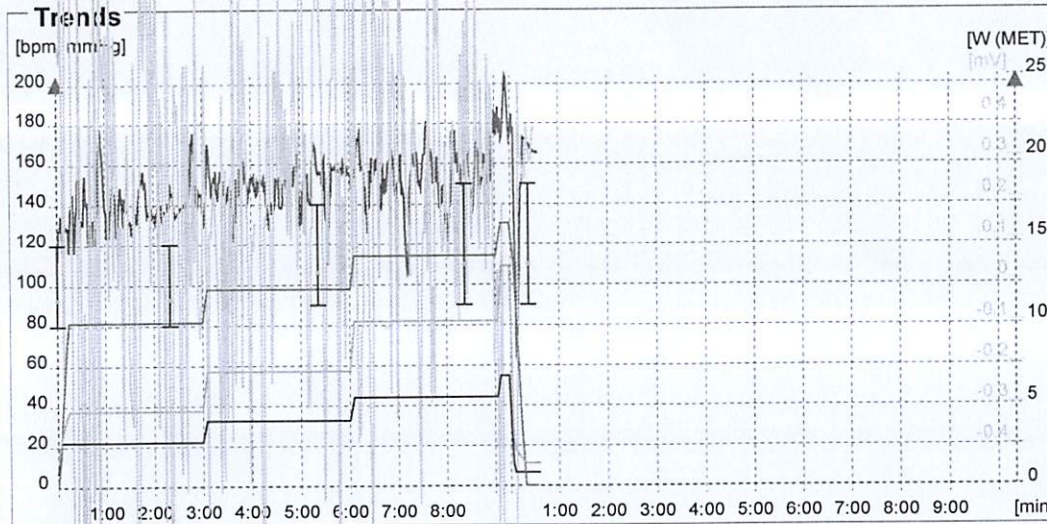
Born: 6/7/1971
Age: 51
Sex: Male
Weight: 65 kg
Height: 167 cm
Smoker:
Pacemaker:

Medical history

Medications

Reason for admission

Reason for Stop



Conclusion

Tom Malonda
 good / well / over
 MPT
 PT. X. Y. Z. MALONDA, MR

Staff

Physician: user
Technician:

Test info

Test date: 7/14/2022
Test time: 10:28 AM

Stress device: BTL Treadmill
Protocol: Bruce

Total duration: 09:19
Stress achieved: 6.7km/h, 16.0% (~13.4MET) = 137% predicted (~10.3MET) - for 16 sec

HR rest: 105
HR peak: 203 = 121% predicted (168) --- 09:19 Exercise (13.4MET)

Handgrip test:
BP rest: 120/80
BP peak: 150/90 --- 09:19 Exercise (13.4MET)
BP recovery: 150/90

DP rest: 12600
DP peak: 23136 = 1.8x DP at rest

ST depression max: I -3.23mV 00:03 Recovery 3.1MET
ST elevation max: aVR 3.11mV 00:03 Recovery 3.1MET

ST/HR index: 34.6 μ V/bpm (abnormal)



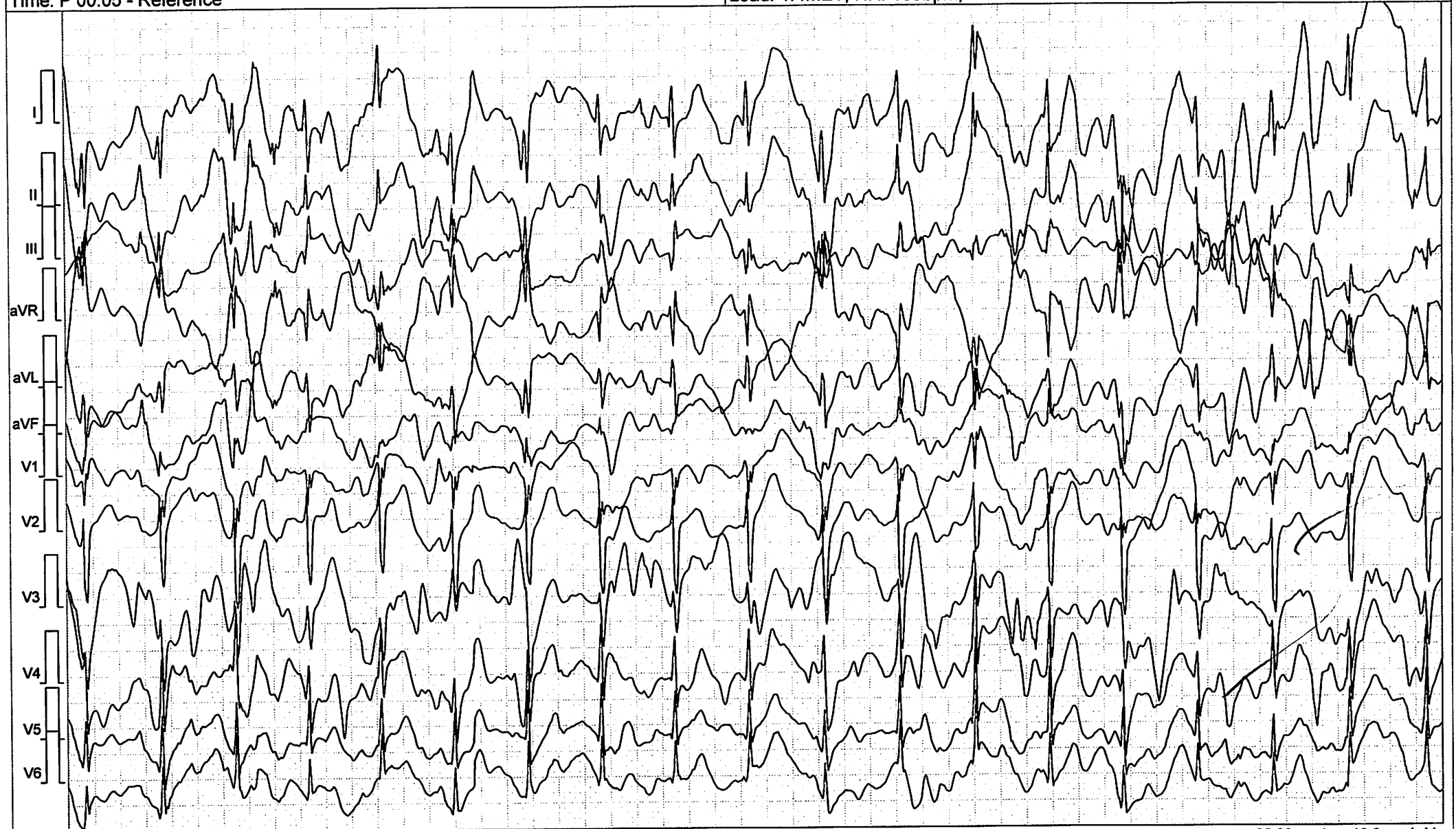
TOMMIE R MALONDA, MR

ID: 01.00085150, Born: 6/7/1971 (Male 51), 65 kg, 167 cm
Test Date: 7/14/2022 10:28:27 AM

MEDIKA PLAZA

Time: P 00:05 - Reference

Load: 1.4MET, HR: 105bpm, BP: 120/80



Filter: 0.07 Spline - 90 Adapt, ~50 [Hz]

25.00 mm/sec 10.0 mm/mV



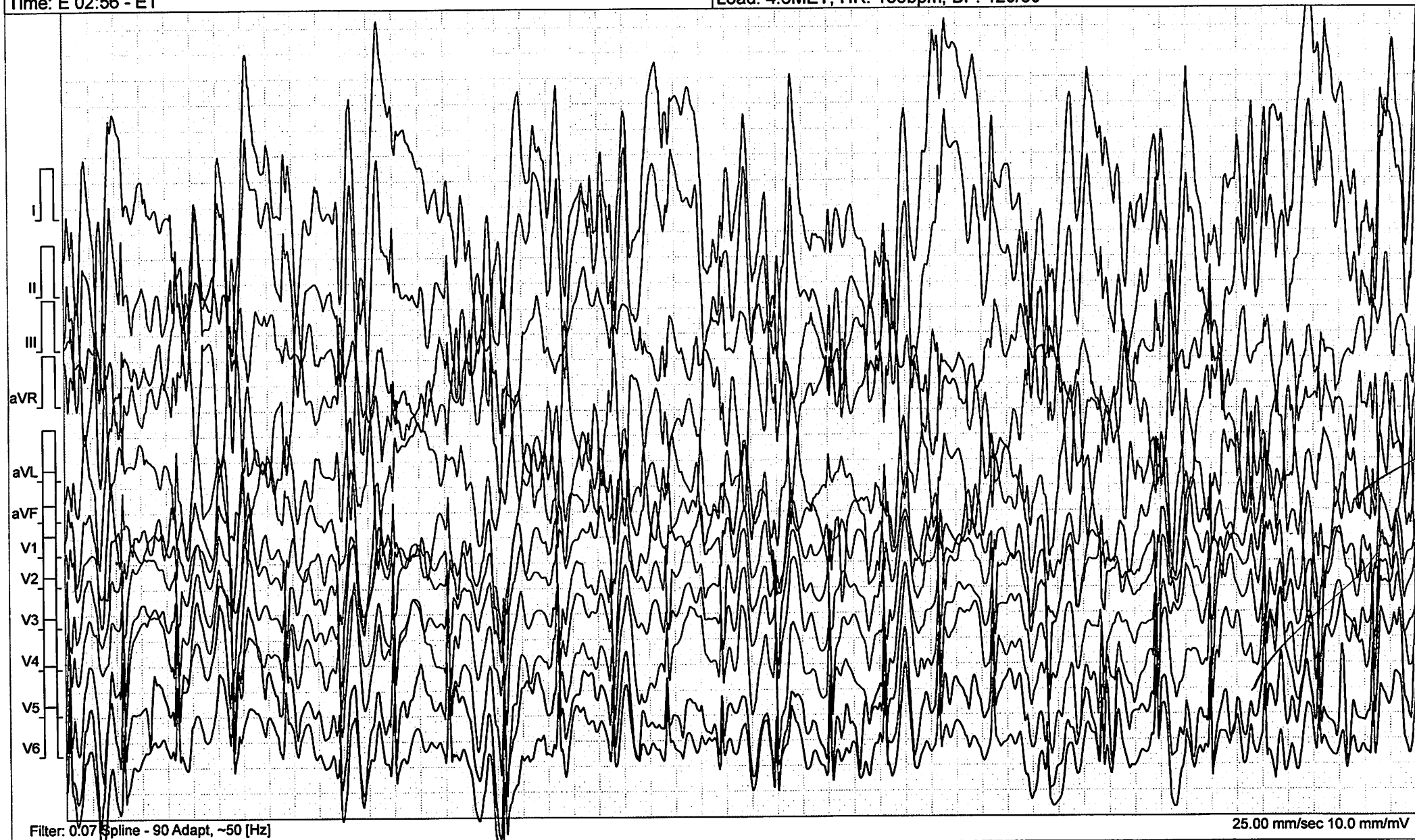
TOMMIE R MALONDA, MR

ID: 01.00085150, Born: 6/7/1971 (Male 51), 65 kg, 167 cm
Test Date: 7/14/2022 10:28:27 AM

MEDIKA PLAZA

Time: E 02:56 - E1

Load: 4.6MET, HR: 135bpm, BP: 120/80



Filter: 0.07 Spline - 90 Adapt, ~50 [Hz]

25.00 mm/sec 10.0 mm/mV



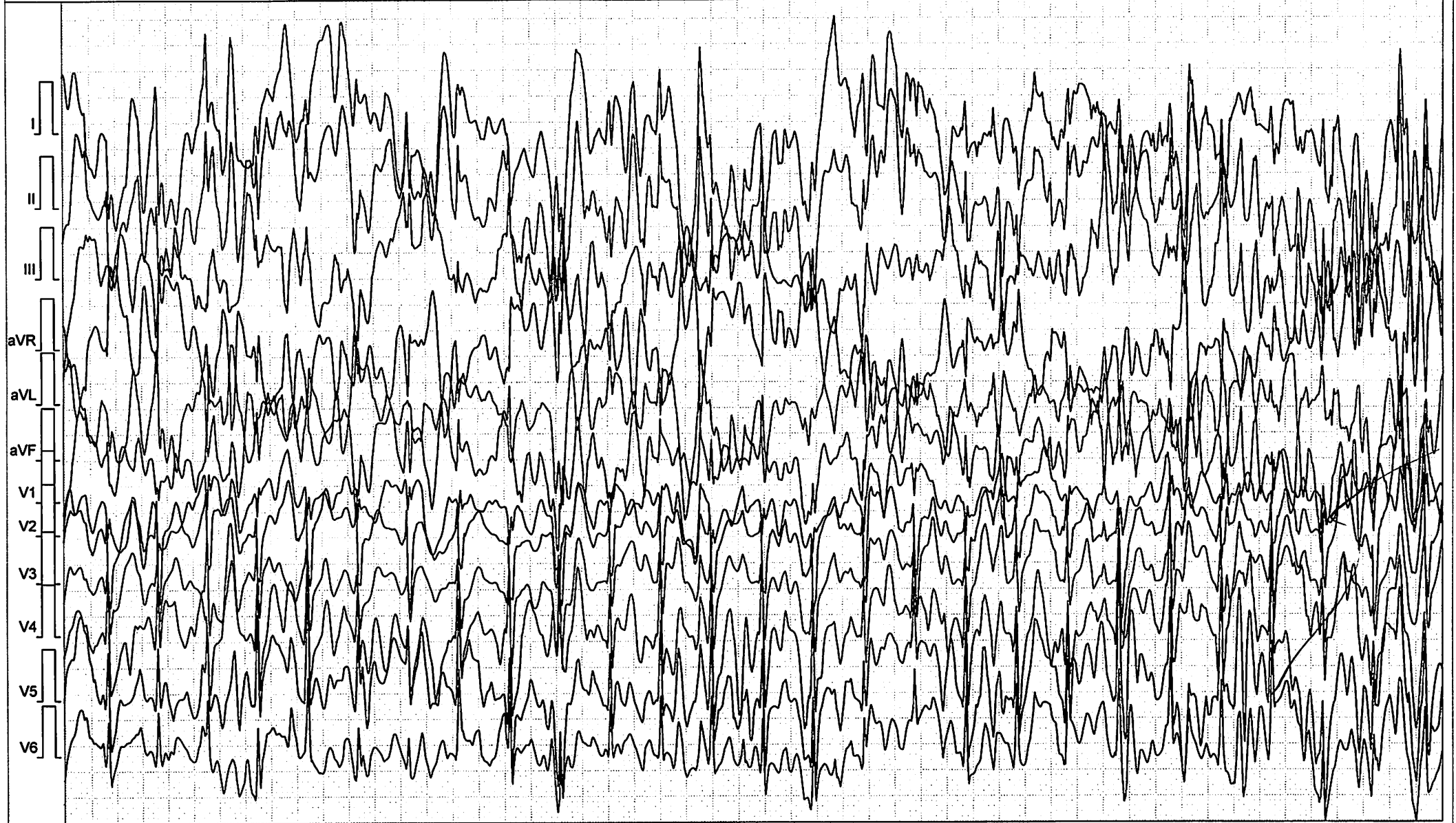
TOMMIE R MALONDA, MR

ID: 01.00085150, Born: 6/7/1971 (Male 51), 65 kg, 167 cm
Test Date: 7/14/2022 10:28:27 AM

MEDIKA PLAZA

Time: E 05:57 - E2

Load: 7.0MET, HR: 155bpm, BP: 140/90



Filter: 0.07 Spline - 90 Adapt, ~50 [Hz]

25.00 mm/sec 10.0 mm/mV



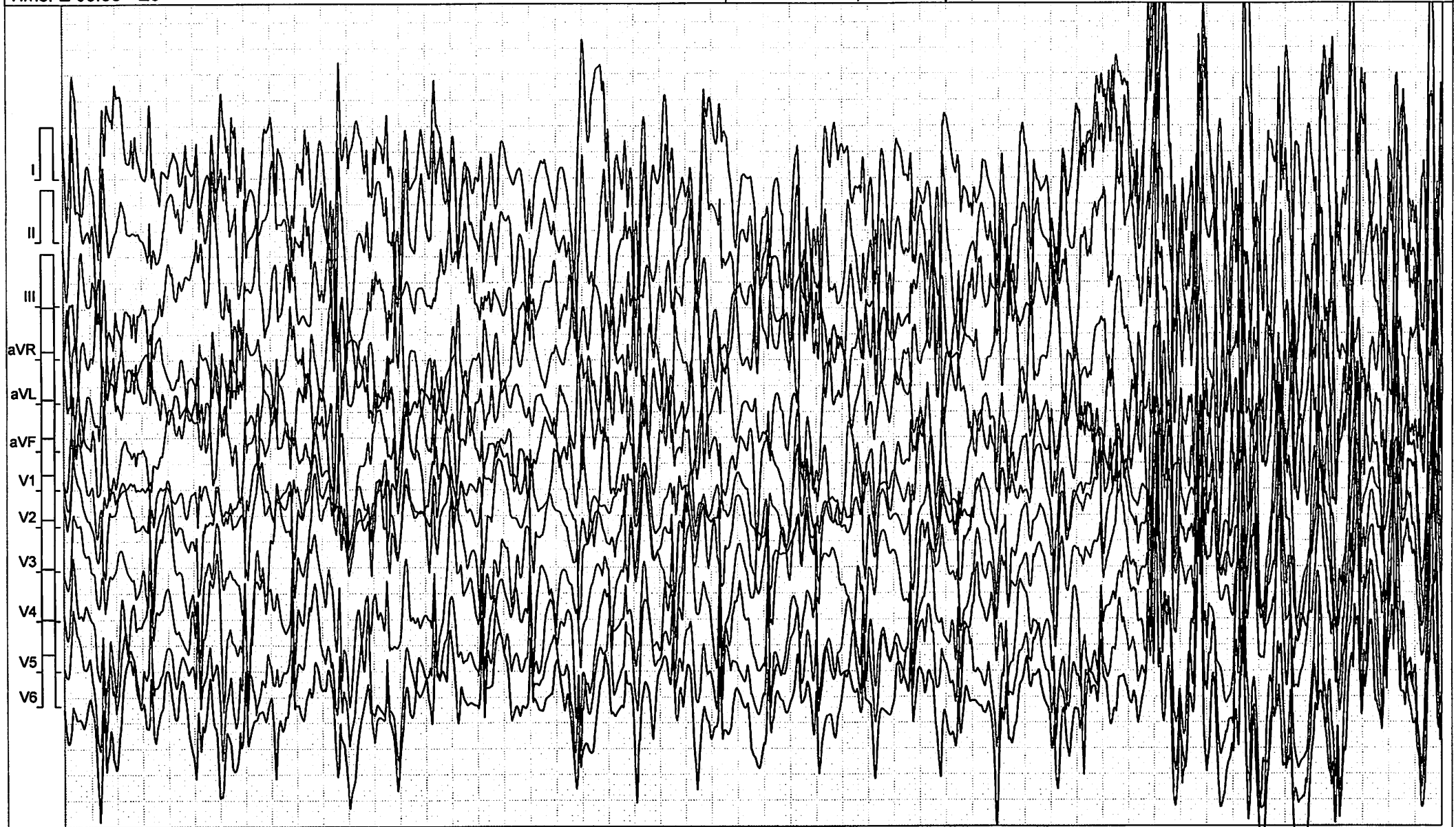
TOMMIE R MALONDA, MR

ID: 01.00085150, Born: 6/7/1971 (Male 51), 65 kg, 167 cm
Test Date: 7/14/2022 10:28:27 AM

MEDIKA PLAZA

Time: E 08:58 - E3

Load: 10.1MET, HR: 181bpm, BP: 150/90



Filter: 0.07 Spline - 90 Adapt, ~50 [Hz]

25.00 mm/sec 10.0 mm/mV



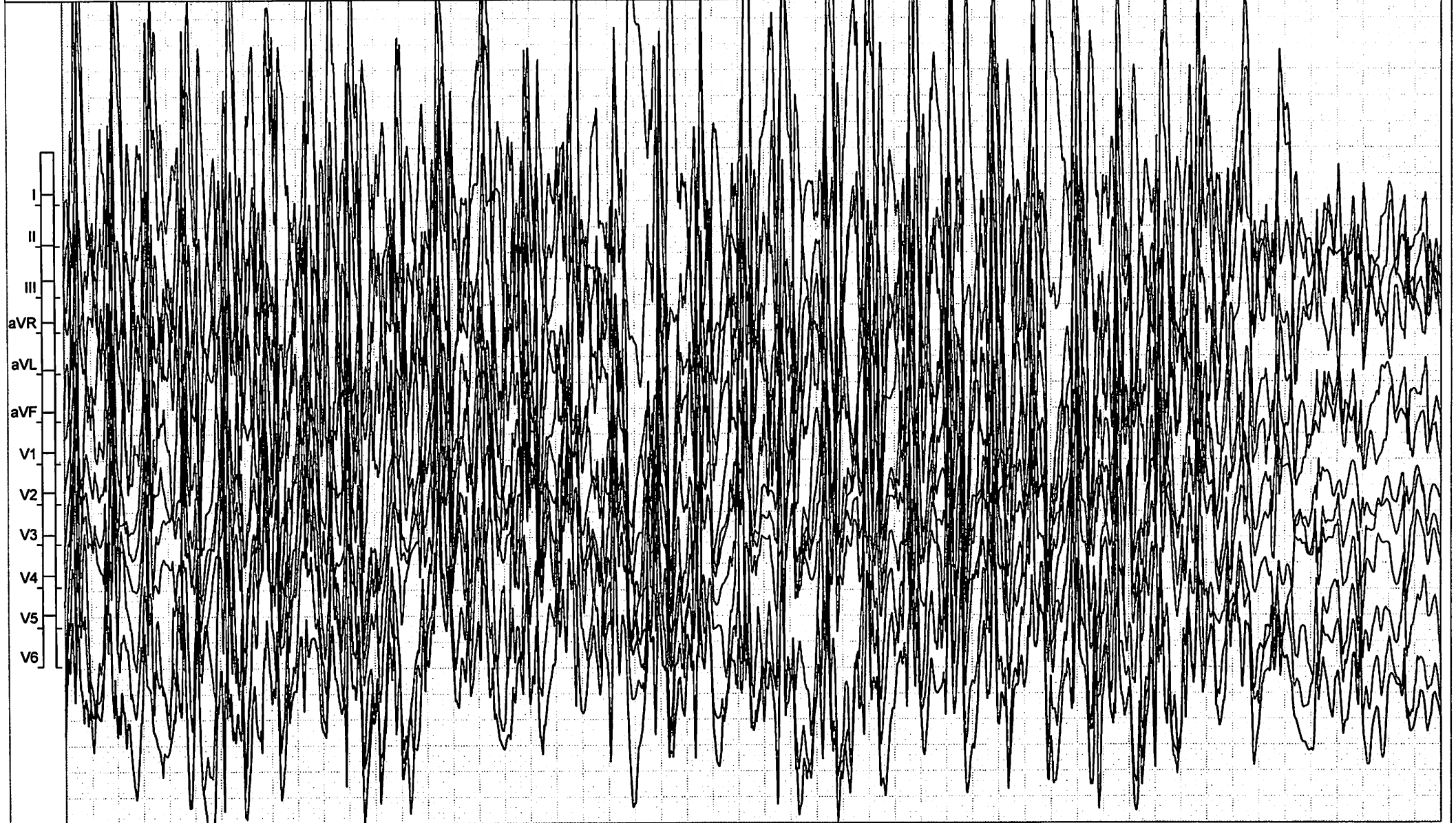
TOMMIE R MALONDA, MR

ID: 01.00085150, Born: 6/7/1971 (Male 51), 65 kg, 167 cm
Test Date: 7/14/2022 10:28:27 AM

MEDIKA PLAZA

Time: E 09:14 - Peak

Load: 13.4MET, HR: 175bpm, BP: -



Filter: 0.07 Spline - 90 Adapt. ~50 [Hz]

25.00 mm/sec 10.0 mm/mV



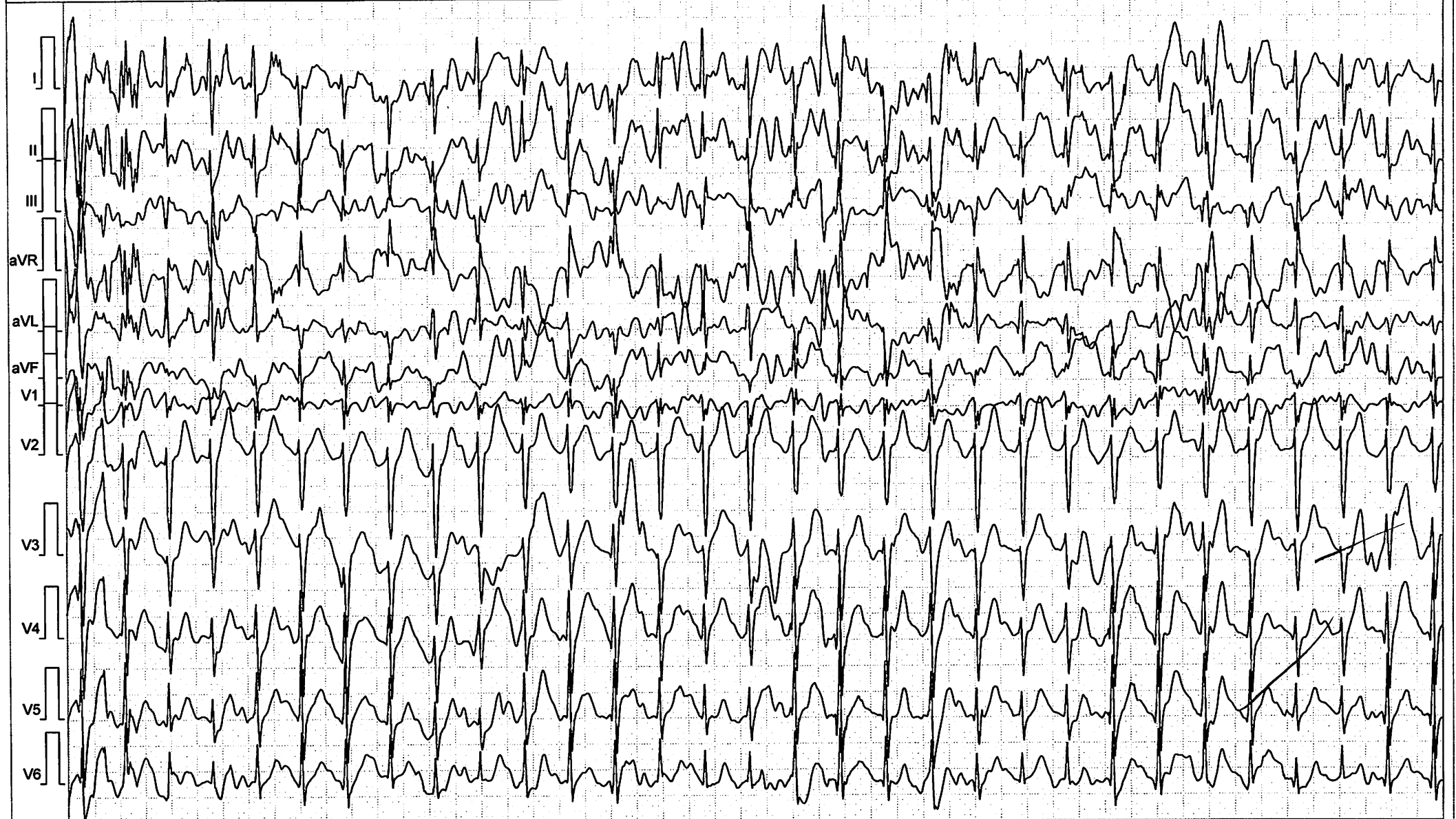TOMMIE R MALONDA, MR

ID: 01.00085150, Born: 6/7/1971 (Male 51), 65 kg, 167 cm
Test Date: 7/14/2022 10:28:27 AM

MEDIKA PLAZA

Time: R 00:10 - Recovery

Load: 1.7MET, HR: 151bpm, BP: 150/90



Filter: 0.07 Spline - 90 Adapt, ~50 [Hz]

25.00 mm/sec 10.0 mm/mV

**TOMMIE R MALONDA, MR**ID: 01.00085150, Born: 6/7/1971 (Male 51), 65 kg, 167 cm
Test Date: 7/14/2022 10:28:27 AM

MEDIKA PLAZA

| Stage | Time | Load | | | HR bpm | BP mmHg | SpO2 % | ST Level [mV], J+: 1/8RR | | | | | | | | | | | |
|-----------|---------|------|------|------|------------|------------|-----------|----------------------------|-------|-------|-------|-------|-------|-------|-------|-------|-------|-------|-------|
| | | km/h | % | MET | | | | I | II | III | aVR | aVL | aVF | V1 | V2 | V3 | V4 | V5 | V6 |
| Reference | E 00:03 | 0.8 | 0.0 | 1.4 | 105 | 120/80 | - | 0.53 | 0.89 | 0.37 | -0.70 | 0.09 | 0.69 | 0.11 | 0.55 | 0.94 | -0.01 | 0.33 | 0.09 |
| E 1 stage | E 03:01 | 2.7 | 10.0 | 4.6 | 146 | 120/80 | - | -0.97 | -0.98 | -0.06 | 0.02 | -0.40 | -0.75 | 0.01 | 0.35 | -0.17 | -0.28 | 0.14 | 0.08 |
| E 2 stage | E 06:02 | 4.0 | 12.0 | 7.0 | 155 | 140/90 | - | -0.62 | -0.48 | 0.20 | 0.54 | -0.32 | -0.03 | 0.10 | 0.43 | 0.29 | 0.27 | 1.48 | 0.32 |
| E 3 stage | E 09:03 | 5.4 | 14.0 | 10.1 | 180 | 150/90 | - | -0.27 | -0.37 | -0.09 | 0.20 | -0.04 | -0.28 | 0.08 | 0.07 | 0.00 | 0.20 | 0.03 | -0.34 |
| E 4 peak | E 09:19 | 6.7 | 16.0 | 13.4 | 203 | 150/90 | - | 0.37 | -1.54 | -1.33 | 0.15 | 0.80 | -1.41 | -0.59 | -0.57 | -0.54 | -0.50 | -0.94 | -0.34 |
| Recovery | R 00:20 | 0.8 | 16.0 | 2.5 | 151 | 150/90 | - | -3.23 | -2.93 | -1.24 | 3.11 | -1.63 | -1.71 | -0.76 | -0.67 | -0.55 | -0.77 | -0.71 | -0.72 |

Tanggal Kunjungan : 14/07/2022
Rekam Medis : 01.00085150
Nama : TOMMIE R MALONDA
Jenis Kelamin : Male

No. Registrasi : 20220714-138724

Tanggal Lahir : 07 June 1971

S : MCU

O :

| | | | | | | | | | | | | | | | |
|----|----|----|----|----|----|----|----|----|----|----|----|----|----|----|----|
| 18 | 17 | 16 | 15 | 14 | 13 | 12 | 11 | 21 | 22 | 23 | 24 | 25 | 26 | 27 | 28 |
| | X | R | X | X | X | X | X | X | X | R | X | X | X | X | |

| | | | | | | | | | | | | | | | |
|----|----|----|----|----|----|----|----|----|----|----|----|----|----|----|----|
| | X | X | X | R | R | R | | | | R | X | X | X | X | |
| 48 | 47 | 46 | 45 | 44 | 43 | 42 | 41 | 31 | 32 | 33 | 34 | 35 | 36 | 37 | 38 |

A : 16, 23, 33, 42, 43, 44 = RADIX

RA & RB = FULL PROTESA

P : 16, 23, 33, 42, 43, 44 = PRO EXO

Diperiksa Oleh,

 PT. KARTIKA BINA MEDIKATAMA

Dokter
Rinati Adrin, Sp. KGA

NAMA PASIEN : Tommie R M
No. RM : 01.00085150
Klinik/MCU/HCU : CO. ENT

Yth. Ts. Dokter :
(Konsulen)

Mohon konsul Pasien yang kami rawat
dengan,

Diagnosis Kerja :
Ikhtisar Klinik :

Konsul yang diminta :

PENDAPAT KONSULEN

Penemuan :

Ardianeky = Mild Hy dscr Bilateral.

Diagnosis :

Nasehat/Anjuran :

- Stop smoke
- Hy ear protection.
- Wh way in any hr
- Consult to dentist

Eac: Tympanic membrane

Case: acute hypotony, minor ear

Find: T.I., granular purp, pharynx gran

Diagnosis: Otitis media with effusion, Chronic pharyngitis, Mild hy loss bilat

Tanggal : 14/7/2022

Jam :

Dokter :

Tanda tangan

Dr. MEGISTIANA CHRISTIANE Sp.THT-KL
SIP 118/2014 A 04/01.7/2018
Nama Jelas

PT. KARTIKA BINA MEDIKATAMA