

## Certificate Of Health Assessment




Name	Age	Position	Department
ALI MUSA SIAGIAN	44 yo	INSPECTOR	INSPECTION

### COMPANY :

**INSPEKTINDO SINERGI PERSADA, PT**

### CONCLUSION

FIT TO WORK	
FIT WITH MEDICAL NOTE	✓
TEMPORARY UNFIT	
UNFIT	

Issued Date	Doctors Name	Prepared By
09 February 2021	<b>Rezkha Amalia, MD</b> <small>PKTK : KEP.476/BINWASK3-PNK3/KK/XII/2018</small> <small>SIP : 54/B.15a/31.74.04.1004/-1.779.3/e/2018</small>	 
Expired Date		Verified By
09 February 2022	<b>dr. Muhammad Ilyas, Sp.Ok</b> <small>SIP : 29/B.15b/31.74.04.1004.02.009.K.1/3/-1.779.3/e/2019</small>	 <b>PT. KARTIKA BINA MEDIKATAMA</b>

No. Formulir : FM-DR-008-05  
 No. Revisi : 00  
 Tanggal Terbit : 2 Mei 2011

Certificate Number : MP-BOP/1-20210209/127859  
 MCU Validity Check  
<https://mcu-validasi.medikaplaza.com>

#### PT. KARTIKA BINA MEDIKATAMA

## TO WHOM IT MAY CONCERN

### *Kepada yang berkepentingan*

This is certify that today Tuesday, 09 February 2021 Medika Plaza Clinic has performed urine drug screening and/or breath alcohol test to :

*Dengan ini menyatakan bahwa, pada hari ini Selasa, 09 Februari 2021 Medika Plaza Clinic telah melakukan urine drug screening dan/atau breath alcohol test kepada :*

### *ALI MUSA SIAGIAN*

With the results are as follows :

*Dengan hasil sebagai berikut :*

<u>Drugs Test</u> <i>Uji Obat</i>	<u>Result</u> <i>Hasil</i>		
<b>URINE DRUGS SCREENING</b>			
- Amphetamine	<input type="checkbox"/> Non-Negative	<input checked="" type="checkbox"/> Negative	<input type="checkbox"/> N/A
- Met-Amphetamine	<input type="checkbox"/> Non-Negative	<input checked="" type="checkbox"/> Negative	<input type="checkbox"/> N/A
- Cocain	<input type="checkbox"/> Non-Negative	<input checked="" type="checkbox"/> Negative	<input type="checkbox"/> N/A
- THC/Canabis/Marijuana	<input type="checkbox"/> Non-Negative	<input checked="" type="checkbox"/> Negative	<input type="checkbox"/> N/A
- Morphine/Opiates	<input type="checkbox"/> Non-Negative	<input checked="" type="checkbox"/> Negative	<input type="checkbox"/> N/A
- P C P/Phencyclidine	<input type="checkbox"/> Non-Negative	<input checked="" type="checkbox"/> Negative	<input type="checkbox"/> N/A
- Barbiturate	<input type="checkbox"/> Non-Negative	<input type="checkbox"/> Negative	<input checked="" type="checkbox"/> N/A
- Benzodiazepin	<input type="checkbox"/> Non-Negative	<input checked="" type="checkbox"/> Negative	<input type="checkbox"/> N/A
- Methadone	<input type="checkbox"/> Non-Negative	<input checked="" type="checkbox"/> Negative	<input type="checkbox"/> N/A
- Propoxyphene	<input type="checkbox"/> Non-Negative	<input type="checkbox"/> Negative	<input checked="" type="checkbox"/> N/A
- Oxycodone	<input type="checkbox"/> Non-Negative	<input type="checkbox"/> Negative	<input checked="" type="checkbox"/> N/A
- MDMA	<input type="checkbox"/> Non-Negative	<input type="checkbox"/> Negative	<input checked="" type="checkbox"/> N/A
- 6-MAM	<input type="checkbox"/> Non-Negative	<input type="checkbox"/> Negative	<input checked="" type="checkbox"/> N/A
<b>BREATH ALCOHOL TEST</b>			
- Alcohol	<input type="checkbox"/> Non-Negative	<input checked="" type="checkbox"/> Negative	<input type="checkbox"/> N/A

Jakarta, February 09, 2021



**PT. KARTIKA BINA MEDIKATAMA**  
( dr. Dian Wahyu Tanjungsari, Sp.PK )  
Clinical Patologist

# **HEALTH ASSESSMENT REPORT**

*Of*

**ALI MUSA SIAGIAN**

**01015394**

**Tuesday, 09 February 2021**

**MP BELTWAY CLINIC**

Beltway Office Park, Annex Building, Ground Floor

Jl. TB. Simatupang Kav.41, Jakarta Selatan 12550

Tlp : (62-21) 808 66 099, Fax : (62-21) 808 66 098

[www.medikaplaza.com](http://www.medikaplaza.com)

## MP BELTWAY CLINIC

Beltway Office Park, Annex Building, Ground Floor  
Jl. TB. Simatupang Kav.41, Jakarta Selatan 12550  
Tlp : (62-21) 808 66 099, Fax : (62-21) 808 66 098  
www.medikaplaza.com

### PATIENT DATA

MedRec.	: 01015394	EMPLOY. STATUS	: Employee
NAME	: ALI MUSA SIAGIAN	BIRTHDATE	: 15 October 1976
EMPLOYEE No.	: -	SEX	: Male
JOB TITLE	: INSPECTOR	STATUS	: Married
COMP. NAME	: INSPEKTINDO SINERGI PERSADA, PT	NASIONALITY	: Indonesia

### SUMMARY

#### MEDICAL FINDING :

1. Dyslipidemia
2. Hyperuricemia
3. Increase fasting blood sugar
4. Non reactive Anti HBs
5. Overweight
6. Prehypertension
7. Calculus, radix, missing , necrosis pulpa and decayed teeth
8. Decreasing of visual acuity of both eyes
9. USG Abdomen: Mild fatty liver, Multiple small polyps of gall bladder


Your fitness status is fit with medical note:

1. Dyslipidemia
2. Necrosis pulpa
3. USG Abdomen: Multiple small polyps of gall bladder

#### SUGGESTION :

1. Low fat and carbohydrate diet and exercise regularly minimal 3 times a week. Consultation with an Internist for further evaluation of dyslipidemia
2. Low purine diet such as meats including organ meats, alcoholic beverages, beans, shrimp, scallops, some vegetables in limited amount such as: spinach, cauliflower, asparagus and mushroom
3. Low sugar diet and repeat blood glucose examination 1 month later. Consultation with an Internist if blood glucose still increase
4. Need to get Hepatitis B vaccination (booster)
5. Reduce body weight gradually 0.5 Kgs/week, by doing regular exercise (aerobic/jogging), 3-4x/week, 30-45 minutes and reduce high calorie diet until maximal body weight is 66.42 Kgs (present body weight is 75.9 Kgs). Consultation with a Nutritionist for evaluation of overweight
6. Low salt diet and monitor your blood pressure regularly minimal once in two weeks. Consultation with a Cardiologist, if your blood pressure tends to increase
7. Consultation with a Dentist for dental care, minimal once a year or better once in six month. Consultation with a Dentist for further evaluation of Necrosis pulpa
8. You need to wear the glasses for near vision
9. Low fat diet and exercise regularly minimum 3x/week. Repeat abdominal USG 6 months later and consultation with an Internist to evaluate mild fatty liver. Consultation with a Surgeon for further evaluation of USG Abdomen: Multiple small polyps of gall bladder

#### Responsible Doctor



Rezkha Amalia, MD

#### Notes:

If you need the further information or consultation, please contact us via :

Email : - beltway.doctor@medikaplaza.com  
- beltway.doctor2@medikaplaza.com  
Telepon Klinik : (62-21) 8086 6099

PRIVATE

Printed by : nurhasanah

**CLINICAL EVALUATION**

Name : ALI MUSA SIAGIAN

Sex : Male

MR : 01015394

Visit : 09/02/2021

Comp.: INSPEKTINDO SINERGI PERSADA, PT

DOB : 15 October 1976

**EXAMINATION****RESULT****NOTES****ANAMNESA****PRESENT COMPLAINT AND HISTORY OF PRESENT****ILLNESS**

Present complaint

No complaint

**MEDICAL HISTORY**

Alergy

No

Imunisasi

Yes

Surgery

Yes

Lyphoma excision

Hospitalization

No

Disease

No

**LIFE STYLE**

Alcohol intake

No

Smoking

No

Exercise

Yes

Running

**FAMILY MEDICAL HISTORY**

Diabetes Melitus

No

Hypertension

No

Heart disease

No

Lung TB

No

Kidney disease

No

Astma

No

Mental disease

No

Epilepsy

No

Cancer

No

Color blind

No

Stroke

No

Liver disease

No

Bone &amp; joint

No

Others disease

No

**WORK EXPOSURE**

Noise

Yes

Heat Stress

No

Cold Stress

No

Vibration

No

Involving height

Yes

Radiation

No

Dust

Yes



## CLINICAL EVALUATION

<b>Name</b> : ALI MUSA SIAGIAN	<b>Sex</b> : Male	<b>MR</b> : 01015394	<b>Visit</b> : 09/02/2021
<b>Comp.</b> : INSPEKTINDO SINERGI PERSADA, PT		<b>DOB</b> : 15 October 1976	

EXAMINATION	RESULT	NOTES
Toxic chemical	No	
Irritating fluid	No	
Smoke	No	
Bacterium/Virus/Parasite	No	
Blood	No	
Animal	No	
Operating heavy mobile equipment	No	
Manual Handling	No	
Sitting continuously over 4 hours	No	
Stand continuously over 4 hours	No	
Using monitor screen more than 4 hours per day	No	
Exposure	No	
Unergonomic body positions	No	
Shift work	No	
Work is not accordance with skills and knowledge	No	
Workload does not accordance with time	No	
Work conflict	No	
Inappropriate task	No	
Career barriers	No	
Family conflict	No	
Working arround rotating machinery	No	
Administration work	No	
Handling food product	No	
Others	Yes	Inspector (offshore/onshore)
<b>PHYSICAL EXAMINATION</b>		
General Appearance	Good	
Body shape	Picnicus	
<b>VITAL SIGN</b>		
Body Weight	75.9 Kg	
Body Height	163 Cm	
BMI	28.56 Kg/m <sup>2</sup>	
Normal Weight	49.15 - 66.42 Kg	
BMI Conclusion	Overweight	
Blood Pressure	130/80 mmHg	
Pulse	83 x/minute	
Body Temperature	36.1 °C	
RR	16	

## CLINICAL EVALUATION

Name : ALI MUSA SIAGIAN	Sex : Male	MR : 01015394	Visit : 09/02/2021
Comp.: INSPEKTINDO SINERGI PERSADA, PT		DOB : 15 October 1976	

EXAMINATION	RESULT	NOTES
Neck Circumference	38 Cm	
Arm Circumference	32 Cm	
Chest size	98 Cm	
Abdominal Circumference	92 Cm	
<b>SKIN</b>		
Skin	Normal	
<b>EYE</b>		
Left	Normal	
Right	Normal	
<b>ENT</b>		
Auricle	Normal	
Ear canal	Normal	
Drums	Normal	
Septum/Conchae	Normal	
Sinuses	Normal	
Pharynx	Normal	
Tonsil	Normal	
<b>MOUTH</b>		
Gum	Normal	
Dental	Abnormal	Calculus, radix, missing , necrosis pulpa and decayed teeth
<b>NECK</b>		
General	Normal	
Thyroid Gland	Normal	
<b>CHEST</b>		
Form	Normal	
Lung	Normal	
Heart	Normal	
Breast	Normal	
<b>ABDOMEN</b>		
Form	Flat	
Palpation	Supple	
Liver	Not Palpable	
Spleen	Not Palpable	
Kidney	No Ballotment	
-	No	
Hernia inguinal	No	

## CLINICAL EVALUATION

Name : ALI MUSA SIAGIAN

Sex : Male

MR : 01015394

Visit : 09/02/2021

Comp. : INSPEKTINDO SINERGI PERSADA, PT

DOB : 15 October 1976

EXAMINATION	RESULT	NOTES
<b>EXTRIMITIES</b>		
Bones, joint	Normal	
Muscles, tonus	Normal	
Fingernails	Normal	
Hand	Normal	
Foot	Normal	
<b>RECTAL EXAMINATION</b>		
Hemorrhoid	Negative	
Rectum	Normal	
<b>SENSORIK EXAMINATION</b>		
Tes Raba	Normal	
<b>MOTORIK EXAMINATION</b>		
Tes Grip	Normal	
<b>REFLEX EXAMINATION</b>		
Physiologic reflex	Normal	
Patologic reflex	Normal	
<b>OTHERS EXAMINATION</b>		
Coordination	Normal	
<b>LYMPHE SYSTEM</b>		
Submandibula	Normal	
Neck Gland	Normal	
Armpit gland	Normal	
Inguinal	Normal	



## OPHTHALMOLOGY DIAGNOSTIC

Name : ALI MUSA SIAGIAN	Sex : Male	MR : 01015394	Visit : 09/02/2021
Comp. : INSPEKTINDO SINERGI PERSADA, PT		DOB : 15 October 1976	

EXAMINATION		Right	Left
Reading		-	
Previous Glasses		-	-
Without Glasses	Distant	20/20	20/20
	Near	J3	J3
Correction	Distant	-	-
	Near	S+1.50 J1	S+1.50 J1
Depth Perception		-	
Tonometry		20.0 mmHg	20.0 mmHg
Funduscopy		NORMAL	NORMAL
Visual Fields		Normal	
Colour Blind Test		Normal	

Impression : Presbyopia

## RADIOLOGY DIAGNOSTIC

Name : ALI MUSA SIAGIAN

Sex : Male

MR : 01015394

Visit : 09/02/2021

Comp. : INSPEKTINDO SINERGI PERSADA, PT

DOB : 15 October 1976

### EXAMINATION

### RESULT

THORAX PA

No abnormality seen in both lungs.  
Normal bronchovascular markings in both hili.  
The heart is normal in size and shape.  
The mediastinum is not widened.  
Both sinus and diaphragms are good.  
No evidence of pleural effusion.

Impression

Normal heart and lungs.

## RADIOLOGY DIAGNOSTIC

Name : ALI MUSA SIAGIAN	Sex : Male	MR : 01015394	Visit : 09/02/2021
Comp.: INSPEKTINDO SINERGI PERSADA, PT	DOB : 15 October 1976		

### EXAMINATION

### RESULT

USG ABDOMEN

LIVER:

Normal in size and contour, smooth surface, parenchyme echoes structures increased inhomogenously, with preserved area at left lobe. No sign of SOL.

Intrahepatic vascularity and billiary tract are normal.

GALL BLADDER:

Normal in size. Multiple small polyps at gallbladder wall ( 2-3 mm in diameter ).

BOTH KIDNEYS:

Normal in size, contour and surface. No sign of obstruction/ stone/ SOL.

PANCREAS:

Normal in size, contour and surface. No sign of SOL.

LIEN:

Normal in size and contour, the echoes are homogenous. No sign of SOL.

URINARY BLADDER:

Normal in size, contour and surface. No sign of stone/ SOL.

PROSTATE AND VESICULA SEMINALIS:

Normal in size and contour which are homogenous echoes and no sign of focal lesion/ SOL.

Impression

Mild fatty liver.

Multiple small polyps of gallbladder.

Other abdominal organs are normal.

## LABORATORY RESULT

Name : ALI MUSA SIAGIAN	MR : 01015394	Visit : 09/02/2021	#Lab : IN73142779784
Comp.: INSPEKTINDO SINERGI PERSADA, PT	Sex : Male	DOB : 15 October 1976	

EXAMINATION	RESULT	NORMAL RANGE
-------------	--------	--------------

### HEMATOLOGI

ABO/Rh Typing "A" Rh(+) positive

#### Automated Blood Count

White Blood Cell (WBC)	6.4	3.8 - 11.0
Erythrocyte (RBC)	5.4	4.4 - 5.9
Haemoglobin	16.1	13.2 - 17.3
Hematocrit	46	40 - 52
Thrombocytes	263	150 - 440

#### MCV, MCH, MCHC

MCV	84	80 - 100
MCH	30	26 - 34
MCHC	35.3	32 - 36
ESR	3	0 - 10

### BLD CHEMISTRY/LIPID PROFILE

Total Cholesterol	208 *	Normal/Desireable: <200 Borderline High: 200-239 High: >=240
HDL Cholesterol	52.3	Normal : >40 - <60 Low HDL : <40 Desireable : >=60
LDL Cholesterol	111	Optimal: <100 Near/Above Optimal: 100-129 Borderline High: 130-159 High: 160-189 Very High: >=190
Triglycerides	225 *	Normal : <150 Borderline High: 150-199 High : 200-499 Very High : >=500

### BLD CHEMISTRY/KIDNEY FUNCTION

Ureum	21.0	10.0 - 50.0
Creatinine	1.0	0.6- 1.3
Uric Acid	8.61 *	3.50 - 7.20

### BLD CHEMISTRY/LIVER FUNCTION

Total Bilirubin	0.50	0.1 - 1.0
Direct Bilirubin	0.11	0.0 - 0.2
Indirect Bilirubin	0.39	0.0 - 0.8

## LABORATORY RESULT

Name : ALI MUSA SIAGIAN	MR : 01015394	Visit : 09/02/2021	#Lab : IN73142779784
Comp.: INSPEKTINDO SINERGI PERSADA, PT	Sex : Male	DOB : 15 October 1976	

EXAMINATION	RESULT	NORMAL RANGE
SGOT(AST)	25	13 - 45
SGPT (ALT)	40	13 - 50
Alkaline Phosphatase	49	30 - 120
Gamma GT	38	0 - 50
Albumin	4.8	3.5 - 5.5
Globulin	2.80	2.3 - 3.5
Total Protein	7.6	6.6 - 8.7

### BLD CHEMISTRY/DIABETES

Glucose Fasting	113 *	< 100
Glucose Urine	Negative	Negative
Keton Urine	Negative	Negative

#### Blood Glucose 2 PP

Blood Sugar 2 Hours PP	111	< 140
Glucose Urine	Negative	Negative
Keton Urine	Negative	Negative

### SEROLOGI / IMUNOLOGI

HBsAg (Quantitative)	0.00	0.00 - 0.03
Anti Hbs (Quantitative)	0.9 *	>= 5.0

### TOXICOLOGY - DRUGS SCREENING

Methadone	Negative	Negative
Phencyclidine	Negative	Negative
THC/Marijuana	Negative	Negative
Amphetamine	Negative	Negative
Benzodiazepines	Negative	Negative
Opiat	Negative	Negative
Cocain	Negative	Negative
Metamphetamine	Negative	Negative
Alcohol	Negative	Negative

### URINALYSIS

#### Complete Urine Analysis

##### Macroscopic

Color	Light Yellow	
Turbidity	Clear	Clear
Specific Gravity	1.016	1.000 - 1.030
pH	6.0	4.5 - 8.0
Leucocyte	Negative	Negative
Glucose	Negative	Negative

**LABORATORY RESULT**

Name : ALI MUSA SIAGIAN	MR : 01015394	Visit : 09/02/2021	#Lab : IN73142779785
Comp.: INSPEKTINDO SINERGI PERSADA, PT	Sex : Male	DOB : 15 October 1976	

EXAMINATION	RESULT	NORMAL RANGE
Nitrit	Negative	Negative
Bilirubin	Negative	Negative
Blood	Negative	Negative
Urobilinogen	Normal	Normal
Protein	Negative	Negative
Keton	Negative	Negative

**Microscopic**

RBC	0-1	0 - 1
WBC	0-1	0 - 4
Cylinder	Negative	
Epithels Squamous	0-1	5 - 15
Crystals	Negative	
Bacteria	Negative	Negative
Others	Negative	

**STOOL / RECTAL SWAP****Faeces Complete****Macroscopic**

Color	Brown	
Consistency	Smooth	
Mucus	Negative	Negative
Blood	Negative	Negative
Pus	Negative	Negative
Parasit	Negative	Negative
Lipid	Negative	Negative

**Microscopic**

RBC	0-1	0 - 1
WBC	0-1	0 - 5
Amoeba	Negative	
Ephitels	Positive	Positive
Worm Eggs	Negative	Negative
Yeast	Negative	Negative
Muscle Fiber	Negative	Negative
Others	Negative	Negative

**Digestive**

Amylum	Negative	Negative
Fat	Negative	
Fibers	Positive	Positive



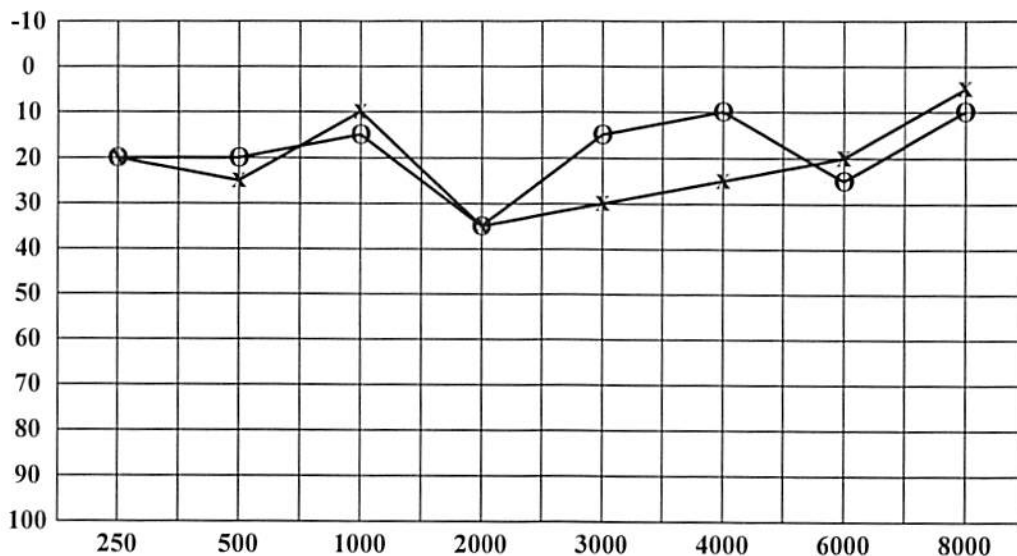
# AUDIOMETRY DIAGNOSTIC

Name : ALI MUSA SIAGIAN	Sex : Male	MR : 01015394	Visit : 09/02/2021
Comp.: INSPEKTINDO SINERGI PERSADA, PT		DOB : 15 October 1976	

## RESULT

Left Ear	250	500	1000	2000	3000	4000	6000	8000
AC	20	25	10	35	30	25	20	5
BC	-	-	-	-	-	-	-	-

Right Ear	250	500	1000	2000	3000	4000	6000	8000
AC	20	20	15	35	15	10	25	10
BC	-	-	-	-	-	-	-	-



< : Right Ear (BC)  
 > : Left Ear (BC)  
  
 O : Right Ear (AC)  
 X : Left Ear (AC)

Conclusion Right Ear : Hearing threshold = 20 dB  
(Within normal limit)

Conclusion Left Ear : Hearing threshold = 23.75 dB  
(Within normal limit)

# CARDIOLOGY DIAGNOSTIC

Name : ALI MUSA SIAGIAN	Sex : Male	MR : 01015394	Visit : 09/02/2021
Comp.: INSPEKTINDO SINERGI PERSADA, PT		DOB : 15 October 1976	

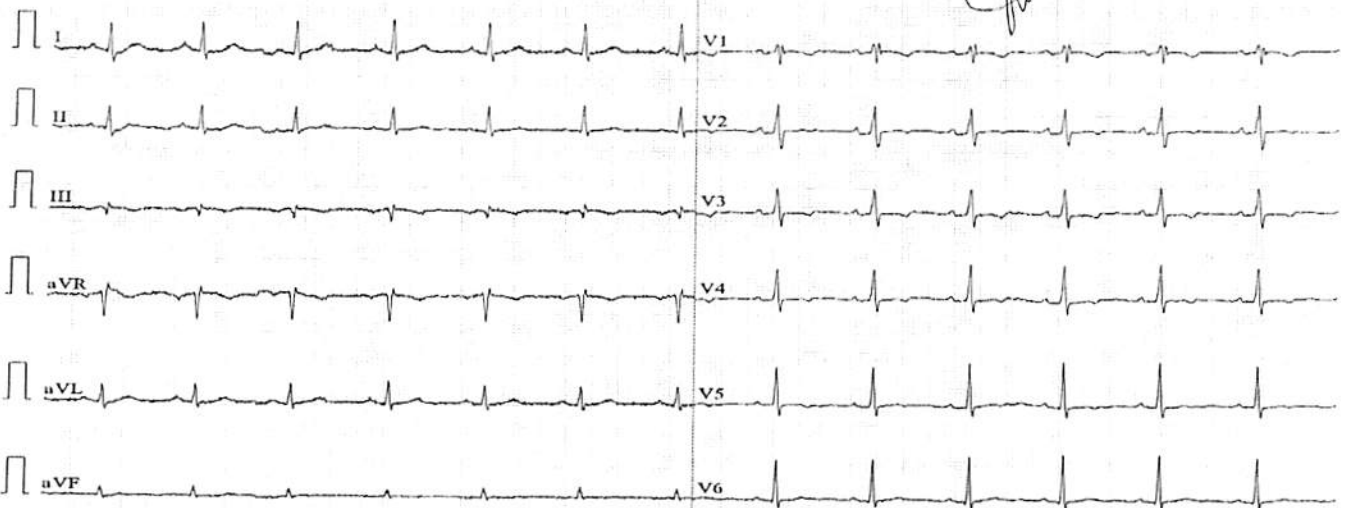
EXAMINATION	RESULT	Comments :
ELECTROCARDIOGRAPHY	Sinus Rythm axis ( N ), P wave ( N ), PR int 0.16" ST - T segment ( N ), aritmia (-)	Normal ECG
TREADMILL	Sinus Rythm axis ( N ), P wave ( N ), PR int 0.16" ST - T segment ( N ), aritmia (-)	Treadmill Exercise Test : Negative Cardiopulmonary Fitness Classification : Good METs : 13.4

ID: 9  
ALI MUSA SIAGIAN  
Male 44Years

09-02-2021 09:43:58  
HR : 80 bpm  
P : 68 ms  
PR : 144 ms  
QRS : 86 ms  
QT/QTc : 342/395 ms  
P/QRS/T : -3/18/-3  
RV5/SV1 : 1.108/0.300 mV

Diagnosis Information:  
Sinus rhythm  
Inferior and anterior T wave abnormality is nonspecific  
Borderline ECG

Report Confirmed by:



0.67-100Hz AC50 25mm/s 10mm/mV 2\*5.0s ♥80 SE-1200Express V2.21 Glasgow V28.6.0



# ALI MUSA SIAGIAN, MR

ID: 01015394, Born: 10/15/1976 (Male 44), 75 kg, 163 cm  
Test Date: 2/9/2021 8:54:58 AM

MEDIKA PLAZA

### Patient info

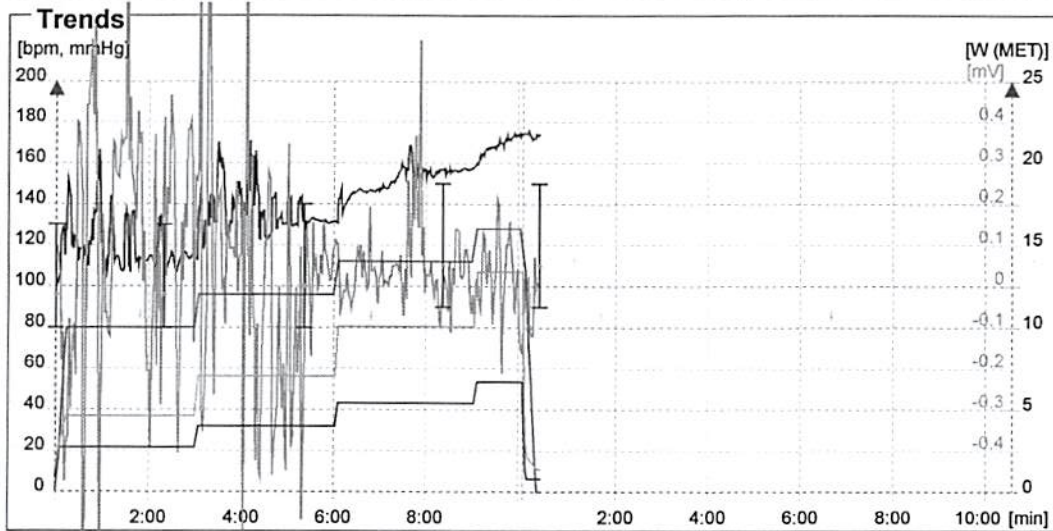
born: 10/15/1976  
age: 44  
sex: Male  
weight: 75 kg  
height: 163 cm  
maker:  
acemaker:

### Medical history

### Medications

### Reason for admission

### Reason for Stop



### Conclusion

*Yalo*  
  
*Gocek*

### Staff

Physician: user  
Technician:

### Test info

Test date: 2/9/2021  
 Test time: 8:54 AM  
 Stress device: BTL Treadmill  
 Protocol: Bruce  
 Total duration: 10:05  
 Stress achieved: 6.7km/h, 16.0% (~13.4MET) = 121% predicted (~11.4MET) - for 6 sec  
 HR rest: 104  
 HR peak: 173 = 99% predicted (175) — 10:0 Exercise (13.4MET)  
 Handgrip test: —  
 BP rest: 130/80  
 BP peak: —  
 BP recovery: 150/90  
 DP rest: 13520  
 DP peak: 23499 = 1.7x DP at rest  
 ST depression max: V4 -1.26mV 00:35 Exercise 4.6ME  
 ST elevation max: V4 1.64mV 00:39 Exercise 4.6ME  
 ST/HR index: 8.4 μV/bpm (abnormal)




**ALI MUSA SIAGIAN, MR**

ID: 01015394, Born: 10/15/1976 (Male 44), 75 kg, 163 cm  
Test Date: 2/9/2021 8:54:58 AM

MEDIKA PLAZA

Time: P 00:05 - Reference

Load: 1.4MET, HR: 104bpm, BP: 130/80



Filter: 0.07 Spline - 90 Adapt, -50 [Hz]

25.00 mm/sec 10.0 mm/mV




**ALI MUSA SIAGIAN, MR**

ID: 01015394, Born: 10/15/1976 (Male 44), 75 kg, 163 cm  
Test Date: 2/9/2021 8:54:58 AM

MEDIKA PLAZA

Time: E 02:56 - E1

Load: 4.6MET, HR: 113bpm, BP: 130/80



Filter: 0.07 Spline - 90 Adapt. ~50 [Hz]

25.00 mm/sec 10.0 mm/mV





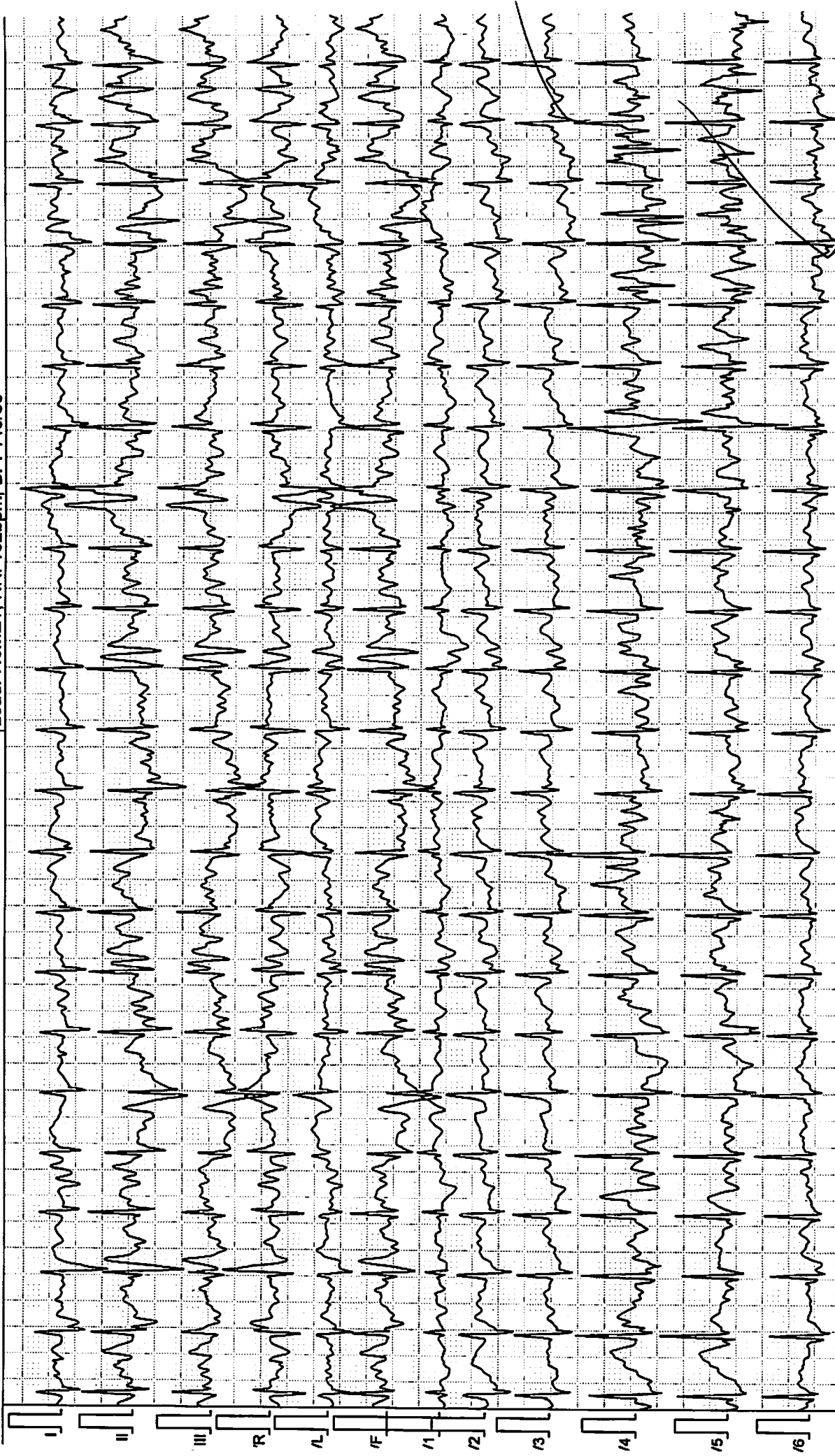
**ALI MUSA SIAGIAN, MR**

ID: 01015394, Born: 10/15/1976 (Male 44), 75 kg, 163 cm  
Test Date: 2/9/2021 8:54:58 AM

MEDIKA PLAZA

Time: E 05:57 - E2

Load: 7.0MET, HR: 132bpm, BP: 140/80



Filter: 0.07 Spine - 90 Adapt, ~50 [Hz]

25.00 mm/sec 10.0 mm/mV





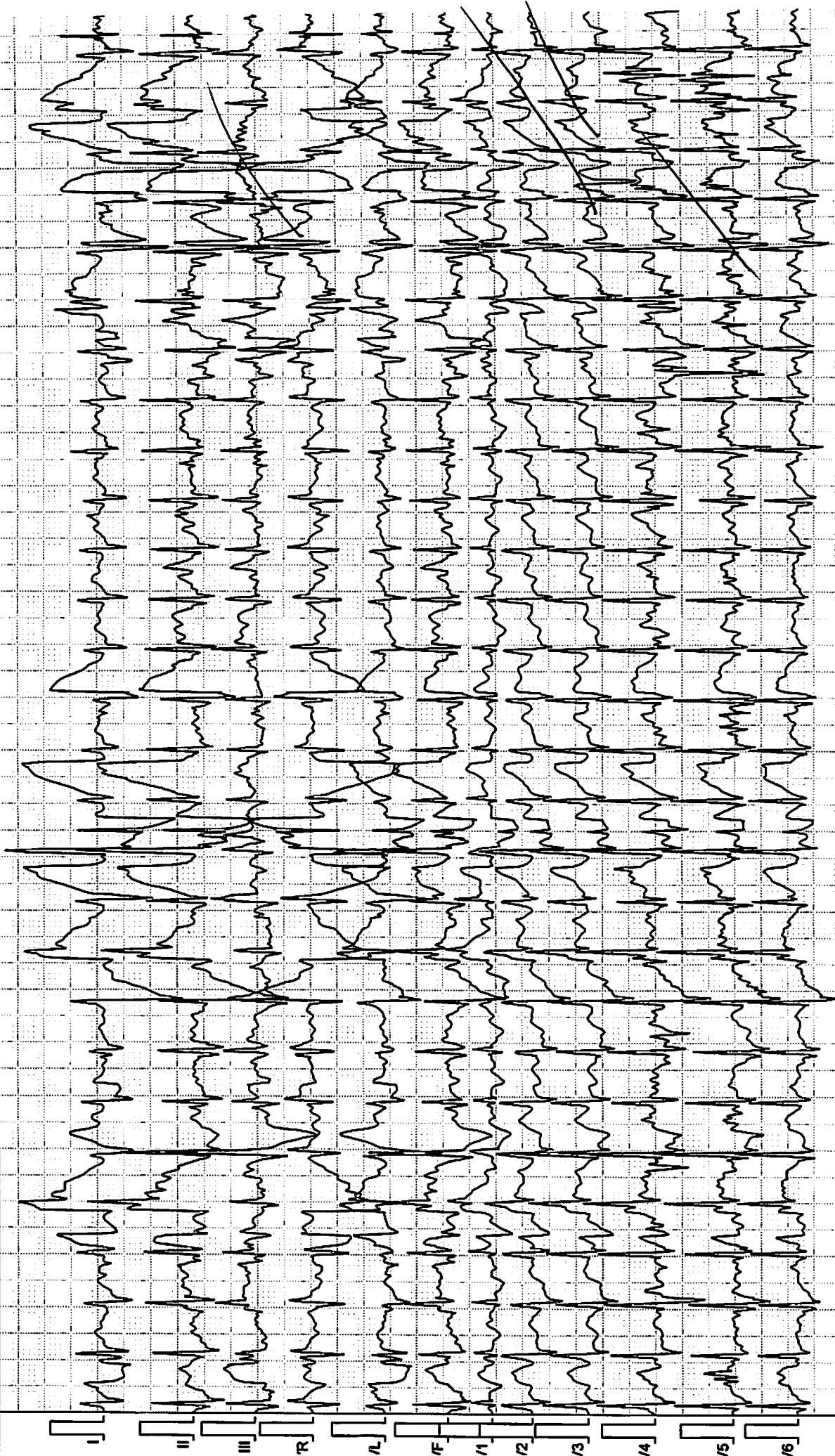
**ALI MUSA SIAGIAN, MR**

ID: 01015394, Born: 10/15/1976 (Male 44), 75 kg, 163 cm  
Test Date: 2/9/2021 8:54:58 AM

MEDIKA PLAZA

Time: E 08:58 - E3

Load: 10.1MET, HR: 158bpm, BP: 150/90



Filter: 0.07 Spine - 90 Adapt, ~50 [Hz]

25.00 mm/sec 10.0 mm/mV



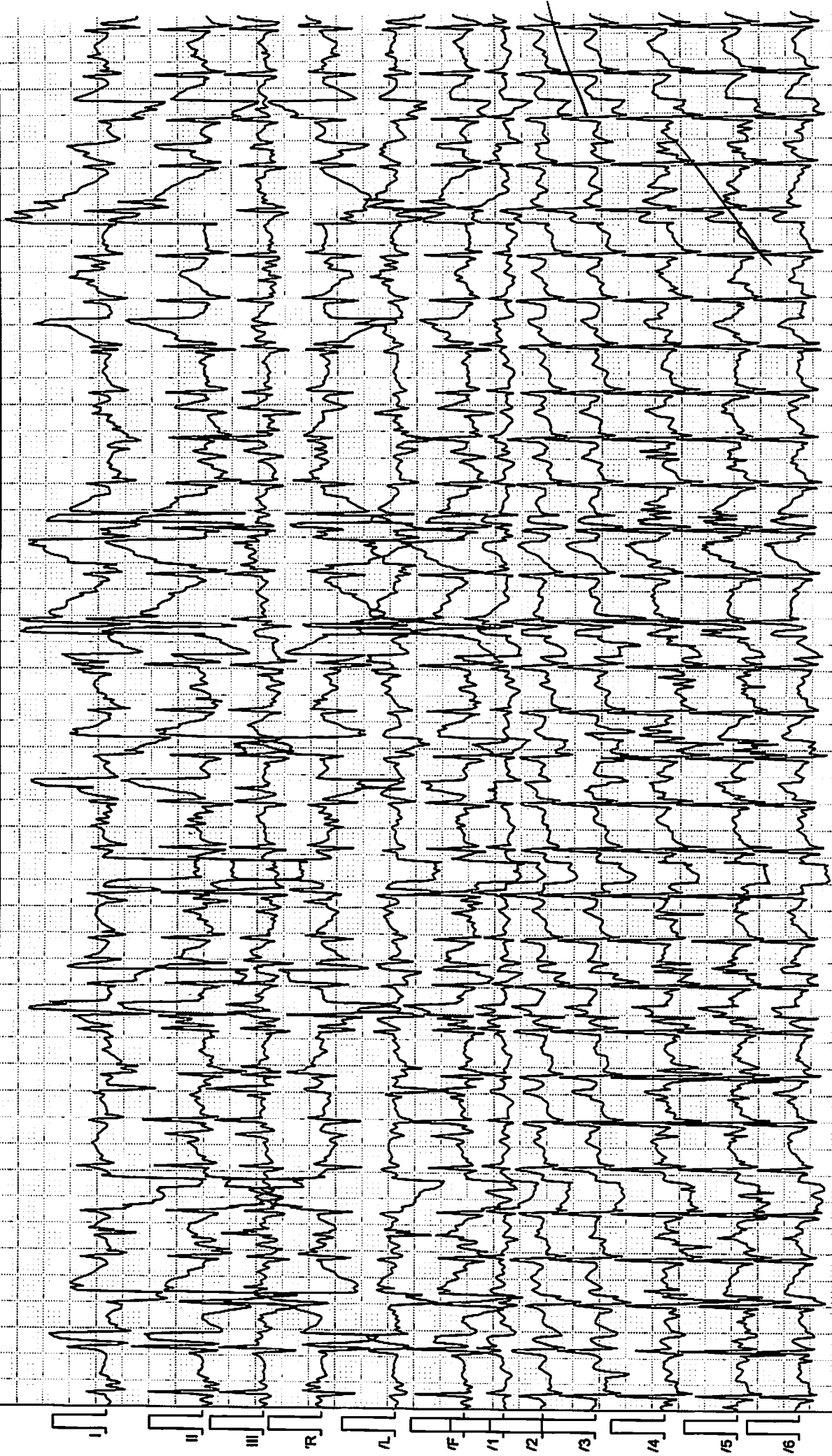
**ALI MUSA SIAGIAN, MR**

ID: 01015394, Born: 10/15/1976 (Male 44), 75 kg, 163 cm  
Test Date: 2/9/2021 8:54:58 AM

MEDIKA PLAZA

Time: E 10:01 - Peak

Load: 13.4MET, HR: 174bpm, BP: -



Filter: 0.07 Spine - 90 Adapt, -50 [Hz]

25.00 mm/sec 10.0 mm/mV



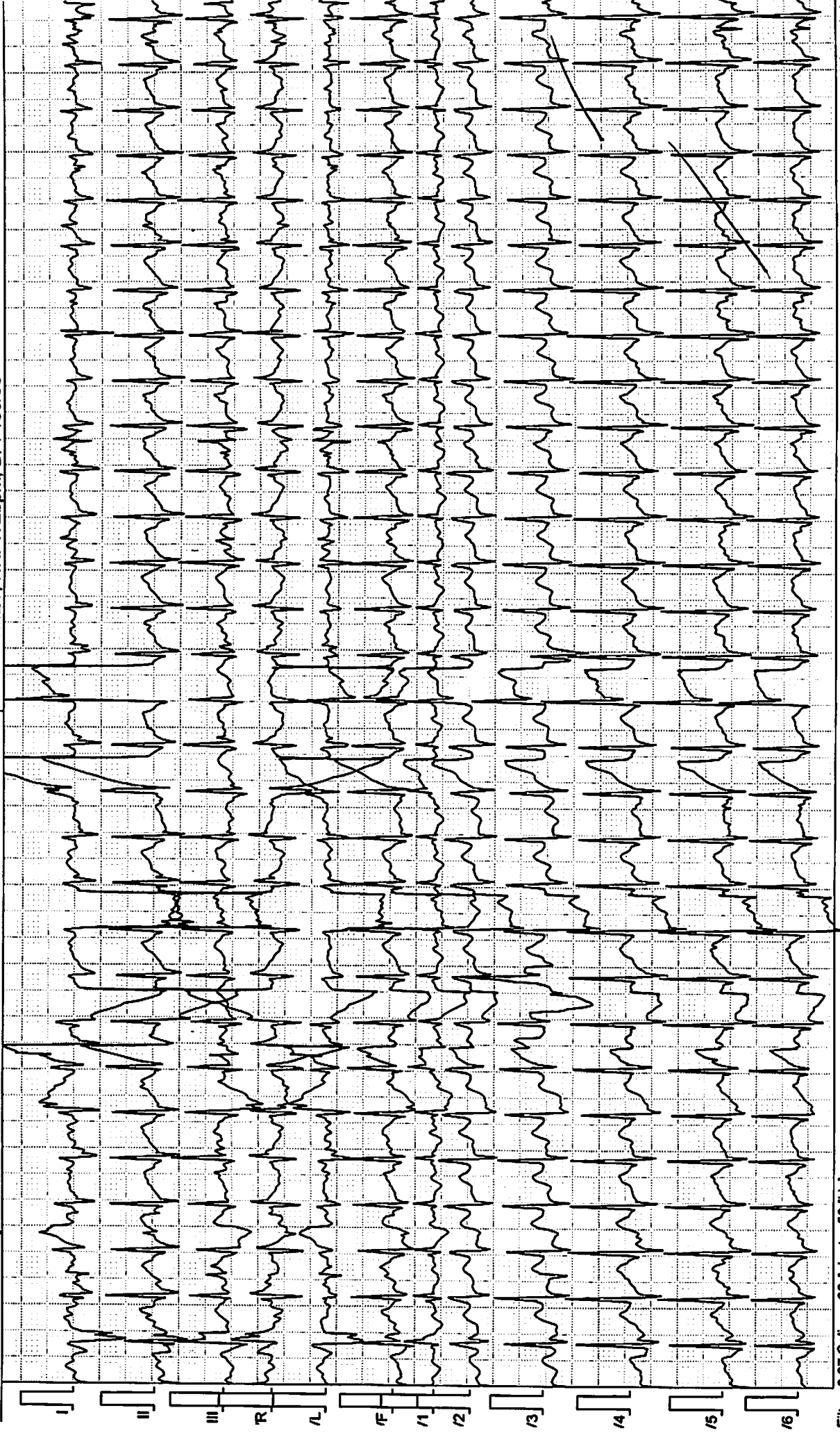
**ALI MUSA SIAGIAN, MR**

ID: 01015394, Born: 10/15/1976 (Male 44), 75 kg, 163 cm  
Test Date: 2/9/2021 8:54:58 AM

MEDIKA PLAZA

Time: R 00:10 - Recovery

Load: 1.8MET, HR: 172bpm, BP: 150/90



Filter: 0.07 Spline - 90 Adapt, -50 [Hz]

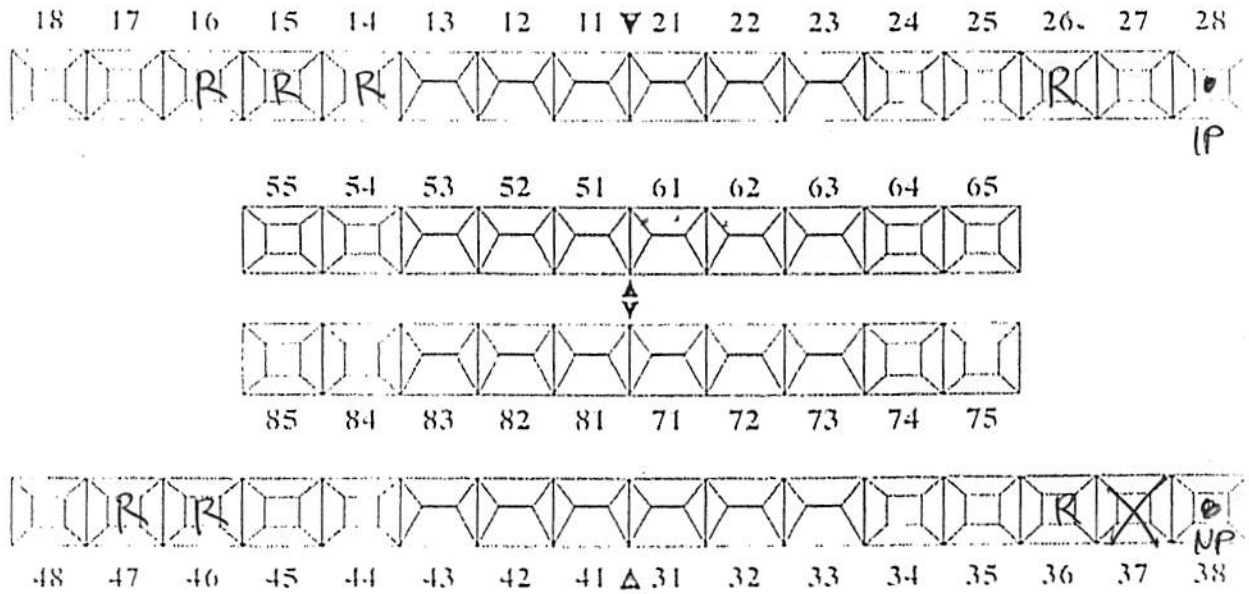
25.00 mm/sec 10.0 mm/mV

**ALI MUSA SIAGIAN, MR**ID: 01015394, Born: 10/15/1976 (Male 44), 75 kg, 163 cm  
Test Date: 2/9/2021 8:54:58 AM

MEDIKA PLAZA

Stage	Time	Load			HR bpm	BP mmHg	SpO2 %	ST Level [ mV ], J+: 1/8RR											
		km/h	%	MET				I	II	III	aVR	aVL	aVF	V1	V2	V3	V4	V5	V6
Reference	E 00:03	0.8	0.0	1.4	104	130/80	-	0.04	-0.07	-0.12	0.07	0.13	-0.10	0.02	0.03	0.02	0.02	-0.25	0.10
E 1 stage	E 03:01	2.7	10.0	4.6	115	130/80	-	-0.14	-0.66	-0.53	0.02	0.15	-0.67	0.02	-0.05	-0.21	-1.26	-0.69	0.03
E 2 stage	E 06:02	4.0	12.0	7.0	131	140/80	-	0.09	0.07	-0.05	-0.08	0.07	0.01	-0.02	0.01	-0.03	-0.01	0.10	0.06
E 3 stage	E 09:03	5.4	14.0	10.1	157	150/90	-	0.06	-0.04	-0.11	-0.01	0.08	-0.09	-0.10	-0.09	-0.13	-0.07	-0.07	0.01
E 4 peak	E 10:06	6.7	16.0	13.4	173	-	-	-0.47	-0.36	-0.02	0.43	-0.10	-0.19	-0.56	-0.46	-0.18	-0.20	-0.16	-0.49
Recovery	R 00:20	0.8	16.0	2.5	172	150/90	-	0.05	0.07	0.03	-0.05	0.03	0.05	-0.07	-0.06	-0.08	-0.03	0.01	0.04

DENTAL EXAMINATION			
Name : Ali Musa Siaoran	Sex : M / F	MR :	Visit $\frac{9}{2} 21$
Comp. : Inspektindo Sineres	DOB : .....		
ODONTOGRAM			



Calculus + 2


DIAGNOSA

kalkulus sedang  
 16, 15, 14, 26, 36, 46, 47 ⇒ GR  
 28 ⇒ IP  
 38 ⇒ NP

TREATMENT PLANNING

pro scaling RA + RB  
 16, 15, 14, 26, 36, 46, 47 ⇒ pro exo  
 28 ⇒ pro LC  
 38 ⇒ pro PSA crown

Verified by: drg. Ilona Amalia/ drg. Fajar Sulawati/drg. Siti Darjah/ drg. Herlina





PATIENT NAME : MR. ACI MUSA SIASIAN  
No. RM : 01015394  
Clinik/MCU/HCU : CO. ENT

To. Dokter :  
(Counsel)

Kindly please counsel for patient who has take cares of

Diagnose :  
Clinik Summary :

Counsel Request :

**COUNSEL ADVISE**

Finding :

Audibly :

Diagnosis :

Recomendation :

- Stop smoky

- Use ear protection  
When work in noisy area.

Ear: Tympanic membrane Intact  
Nose: Clear edgy, septum deviated  
Throat: T, T, gray pulp, pharynx good  
Hazy threshold with normal hearing

Septum deviated, gray pulp.

Date : FEBRUARY, 9, 2021

Time :

EP :

**MP+**

PT. KARTIKA BINA MEDIKATAMA

Dr. MERNISTIANA CHRISTIANE, Sp.THT.K

SIP: 13/B.156/2019/04/17793/e/2019

Complete Name

Formulir Number : FM - DR - 008 - 02

Revisi Number : 00

Date : 07 Juli 2017