

Certificate Of Health Assessment



Name	Age	Position	Department
TAMBOK PARSAULIAN NAPITUPULU	43 yo	INSPECTOR	LIFTING INSPECTION

COMPANY :

INSPEKTINDO SINERGI PERSADA

CONCLUSION

Fit for work to the job described	✓
Fit with Medical Note (Restriction and/or Limitation)	
Unfit for work to the job described	

Date	Doctors Name	Signature
24 May 2018	Alya Putri Khairani, MD	  PT. KARTIKA BINA MEDIKATAMA

No. Formulir : FM-DR-008-05
 No. Revisi : 00
 Tanggal Terbit : 2 Mei 2011

PT. KARTIKA BINA MEDIKATAMA

HEALTH ASSESSMENT REPORT

Of

TAMBOK PARSAULIAN NAPITUPULU
01022516

Thursday, 24 May 2018

MP BELTWAY CLINIC

Beltway Office Park, Annex Building, Ground Floor

Jl. TB. Simatupang Kav.41, Jakarta Selatan 12550

Tlp : (62-21) 808 66 099, Fax : (62-21) 808 66 098

www.medikaplaza.com

MP BELTWAY CLINIC

Beltway Office Park, Annex Building, Ground Floor
Jl. TB. Simatupang Kav.41, Jakarta Selatan 12550
Tlp : (62-21) 808 66 099, Fax : (62-21) 808 66 098
www.medikaplaza.com

PATIENT DATA

MedRec.	: 01022516	EMPLOY. STATUS	: Employee
NAME	: TAMBOK PARSAULIAN NAPITUPULU	BIRTHDATE	: 27 July 1974
EMPLOYEE No.	:	SEX	: Male
JOB TITLE	: INSPECTOR	STATUS	: Married
COMP. NAME	: INSPEKTINDO SINERGI PERSADA	NASIONALITY	: Indonesia

SUMMARY

MEDICAL FINDING :

1. Dyslipidemia
 2. Overweight
 3. Missing, radix, decayed, calculus teeth
- Your fitness status is fit for work to the job described

SUGGESTION :

1. Low fat and carbohydrate diet, exercise regularly minimal 3x/week
2. Reduce body weight gradually 0.5 Kgs/week, by doing regular exercise (aerobic/jogging), 3-4x/week, 30-45 minutes and reduce high calorie diet until maximal body weight is 72.25 Kgs (present body weight is 83.20 Kgs). See a Clinical Nutrition Specialist for evaluation of Overweight with Dyslipidemia
3. See a dentist for dental care minimal once a year or better once in 6 months

Responsible Doctor



Alya Putri Shantani, MD

Notes:

If you need the further information or consultation, please contact us via :

Email : - beltway.doctor@medikaplaza.com
- beltway.doctor2@medikaplaza.com
Telepon Klinik : (62-21) 8086 6000

CLINICAL EVALUATION

Name : TAMBOK PARSAULIAN NAPITUPULU

Sex : Male

MR : 01022516

Visit : 24/05/2018

Comp. : INSPEKTINDO SINERGI PERSADA

DOB : 27 July 1974

EXAMINATION

RESULT

NOTES

ANAMNESA

PRESENT COMPLAINT AND HISTORY OF PRESENT

ILLNESS

Present complaint

No complaint

MEDICAL HISTORY

Allergy

No

Imunisasi

Yes

Surgery

No

Hospitalization

No

Disease

No

LIFE STYLE

Alcohol intake

No

Smoking

Yes

Moderate smoker

Exercise

Yes

Swimming, jogging 1x/week

FAMILY MEDICAL HISTORY

Diabetes Melitus

No

Hypertension

No

Heart disease

No

Lung TB

No

Kidney disease

No

Astma

No

Mental disease

No

Epilepsy

No

Cancer

No

Color blind

No

Stroke

No

Liver disease

No

Bone & joint

No

Others disease

No

WORK EXPOSURE

Noise

Yes

Heat Stress

Yes

Cold Stress

No

Vibration

Yes

Involving height

Yes

Radiation

Yes

Dust

Yes

CLINICAL EVALUATION

Name : TAMBOK PARSAULIAN NAPITUPULU	Sex : Male	MR : 01022516	Visit : 24/05/2018
Comp. : INSPEKTINDO SINERGI PERSADA		DOB : 27 July 1974	

EXAMINATION	RESULT	NOTES
Toxic chemical	Yes	
Irritating fluid	Yes	
Smoke	No	
Bacterium/Virus/Parasite	No	
Blood	No	
Animal	No	
Operating heavy mobile equipment	No	
Manual Handling	No	
Sitting continuously over 4 hours	No	
Stand continuously over 4 hours	No	
Using monitor screen more than 4 hours per day	No	
Exposure	No	
Unergonomic body positions	No	
Shift work	No	
Work is not accordance with skills and knowledge	No	
Workload does not accordance with time	No	
Work conflict	No	
Inappropriate task	No	
Career barriers	No	
Family conflict	No	
Working around rotating machinery	No	
Administration work	No	
Handling food product	No	
Others	Yes	Offshore/Onshore

PHYSICAL EXAMINATION

General Appearance	Good
Body shape	Athleticus

VITAL SIGN

Body Weight	83.2 Kg
Body Height	170 Cm
BMI	28.78 Kg/m ²
Normal Weight	53.47 - 72.25 Kg
BMI Conclusion	Overweight
Blood Pressure	110/70 mmHg
Pulse	76 x/minute
Body Temperature	36 °C
RR	20

CLINICAL EVALUATION

Name : TAMBOK PARSAULIAN NAPITUPULU

Sex : Male

MR : 01022516

Visit : 24/05/2018

Comp. : INSPEKTINDO SINERGI PERSADA

DOB : 27 July 1974

EXAMINATION	RESULT	NOTES
Neck Circumference	-	
Arm Circumference	-	
Chest size	-	
Abdominal Circumference	-	
SKIN		
Skin	Normal	
EYE		
Left	Normal	
Right	Normal	
ENT		
Auricle	Normal	
Ear canal	Normal	
Drums	Normal	
Septum/Conchae	Normal	
Sinuses	Normal	
Pharynx	Normal	
Tonsil	Normal	
MOUTH		
Gum	Normal	
Dental	Abnormal	Missing, radix, decayed, calculus teeth
NECK		
General	Normal	
Thyroid Gland	Normal	
CHEST		
Form	Normal	
Lung	Normal	
Heart	Normal	
Breast	Normal	
ABDOMEN		
Form	Flat	
Palpation	Supple	
Liver	Not Palpable	
Spleen	Not Palpable	
Kidney	No Ballotment	
-	No	
Hernia inguinal	No	
EXTRIMITIES		

CLINICAL EVALUATION

Name : TAMBOK PARSAULIAN NAPITUPULU

Sex : Male

MR : 01022516

Visit : 24/05/2018

Comp. : INSPEKTINDO SINERGI PERSADA

DOB : 27 July 1974

EXAMINATION	RESULT	NOTES
Bones, joint	Normal	
Muscles, tonus	Normal	
Fingernails	Normal	
Hand	Normal	
Foot	Normal	
RECTAL EXAMINATION		
Hemorrhoid	Negative	
Rectum	Normal	
SENSORIK EXAMINATION		
Tes Raba	Normal	
MOTORIK EXAMINATION		
Tes Grip	Normal	
REFLEX EXAMINATION		
Physiologic reflex	Normal	
Patologic reflex	Normal	
OTHERS EXAMINATION		
Coordination	Normal	
LYMPHE SYSTEM		
Submandibula	Normal	
Neck Gland	Normal	
Armpit gland	Normal	
Inguinal	Normal	

RADIOLOGY DIAGNOSTIC

Name : TAMBOK PARSAULIAN NAPITUPULU	Sex : Male	MR : 01022516	Visit : 24/05/2018
Comp. : INSPEKTINDO SINERGI PERSADA		DOB : 27 July 1974	

EXAMINATION	RESULT
-------------	--------

THORAX PA

No abnormality seen in both lungs.
Normal bronchovascular markings in both hili.
The heart is normal in size and shape.
The mediastinum is not widened.
Both sinus and diaphragms are good.
No evidence of pleural effusion.

Impression

Normal chest.
No evidence of specific process in both lungs.

X-RAY FILM

Name : TAMBOK PARSAULIAN NAPITUPULU

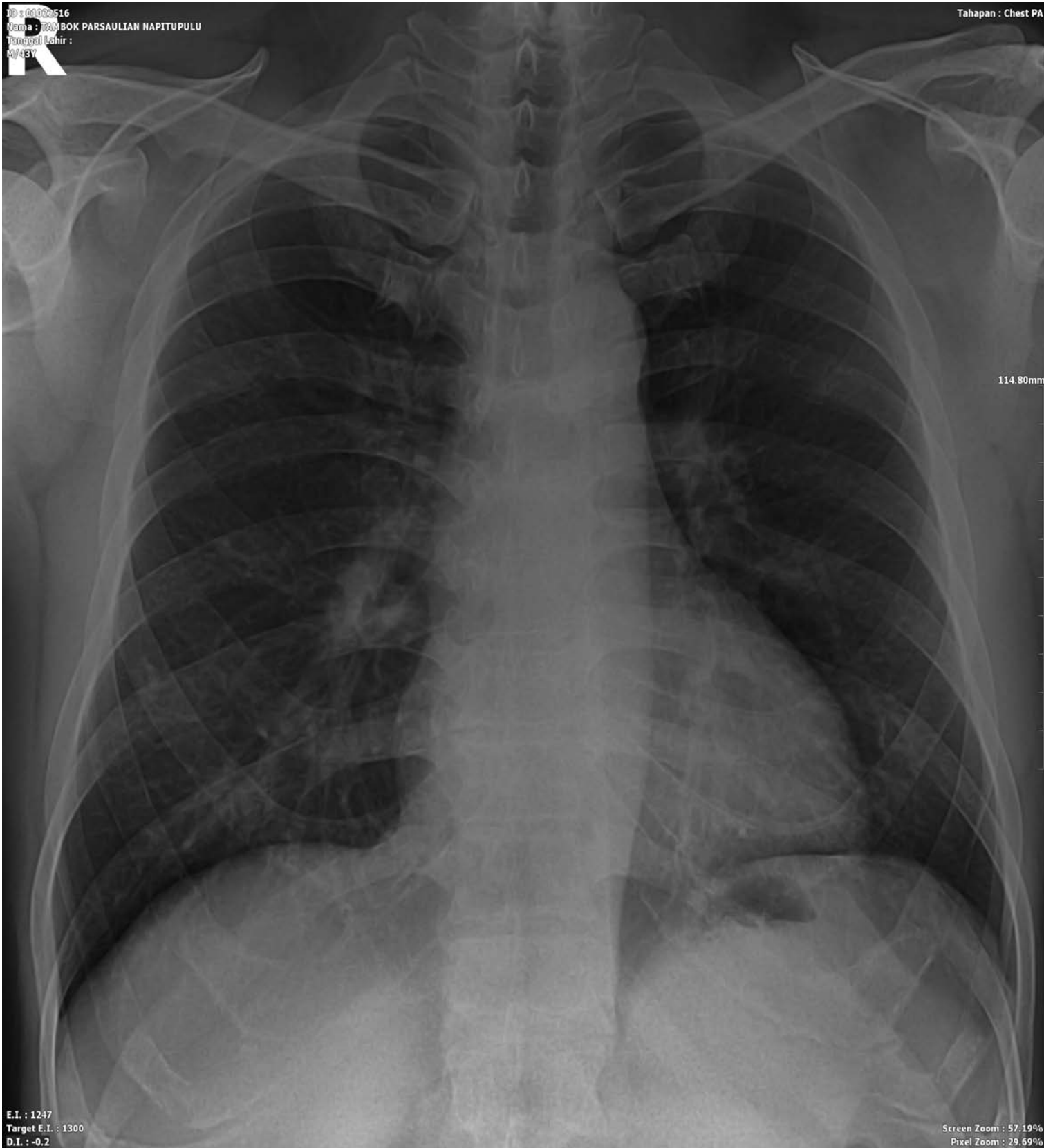
Sex : Male

MR : 01022516

Visit : 24/05/2018

Comp. : INSPEKTINDO SINERGI PERSADA

DOB : 27 July 1974



RADIOLOGY DIAGNOSTIC

Name : TAMBOK PARSAULIAN NAPITUPULU

Sex : Male

MR : 01022516

Visit : 24/05/2018

Comp. : INSPEKTINDO SINERGI PERSADA

DOB : 27 July 1974

EXAMINATION

RESULT

USG ABDOMEN

LIVER:

Normal in size and contour, smooth surface, echoes structure parenchyme which are homogenous. No sign of SOL.

Intrahepatic vascularity and billiary tract are normal.

GALL BLADDER:

Normal in size, contour and surface. No sign of SOL/ sludge/ stone.

RIGHT KIDNEY :

Normal in size, contour and surface. No sign of obstruction/ stone/SOL.

LEFT KIDNEY:

Normal in size, contour and surface. No sign of obstruction/ stone/ SOL.

PANCREAS:

Normal in size, contour and surface. No sign of SOL.

LIEN:

Normal in size and contour, the echoes are homogenous. No sign of SOL.

URINARY BLADDER:

Normal in size, contour and surface. No sign of stone/ SOL.

PROSTATE AND VESICULA SEMINALIS:

Normal in size and contour which are homogenous echoes and no sign of focal lesion/ SOL.

Impression

Normal Sonography

LABORATORY RESULT

Name : TAMBOK PARSAULIAN NAPITUPULU	MR : 01022516	Visit : 24/05/2018	#Lab : IN632328618291
Comp. : INSPEKTINDO SINERGI PERSADA	Sex : Male	DOB : 27 July 1974	

EXAMINATION	RESULT	NORMAL RANGE
-------------	--------	--------------

HEMATOLOGI

Automated Blood Count

White Blood Cell (WBC)	8.1	3.8 - 11.0
Erythrocyte (RBC)	4.8	4.4 - 5.9
Haemoglobin	15.5	13.2 - 17.3
Hematocrit	43	40 - 52
Thrombocytes	256	150 - 440

MCV, MCH, MCHC

MCV	90	80 - 100
MCH	33	26 - 34
MCHC	36.4 *	32 - 36
ESR	22 *	0 - 10

Differential Count

Basophils	0	0 - 1
Eosinophil	4	2 - 4
Bands / Stab	3	3 - 5
Neutrophils	48 *	50 - 70
Lymphocytes	37	25 - 40
Monocytes	8	2 - 8

BLD CHEMISTRY/LIPID PROFILE

Total Cholesterol	205 *	Normal/Desireable: <200 Borderline High: 200-239 High: >=240
HDL Cholesterol	42.5	Normal : >40 - <60 Low HDL : <40 Desireable : >=60
LDL Cholesterol	128	Optimal: <100 Near/Above Optimal: 100-129 Borderline High: 130-159 High: 160-189 Very High: >=190
Tryglicerides	171 *	Normal : <150 Borderline High: 150-199 High : 200-499 Very High : >=500

BLD CHEMISTRY/KIDNEY FUNCTION

Ureum	25.4	10.0 - 50.0
-------	------	-------------

LABORATORY RESULT

Name : TAMBOK PARSAULIAN NAPITUPULU	MR : 01022516	Visit : 24/05/2018	#Lab : IN632328618291
Comp. : INSPEKTINDO SINERGI PERSADA	Sex : Male	DOB : 27 July 1974	

EXAMINATION	RESULT	NORMAL RANGE
Creatinine	1.3	0.6- 1.3
Uric Acid	6.9	3.5 - 7.2

BLD CHEMISTRY/LIVER FUNCTION

SGOT(AST)	21	13 - 45
SGPT (ALT)	30	13 - 50
Gamma GT	43	0 - 50

BLD CHEMISTRY/DIABETES

Glucose Fasting	90	< 100
Glucose Urine	Negative	Negative
Keton Urine	Negative	Negative

URINALYSIS**Complete Urine Analysis****Macroscopic**

Color	Yellow	
Turbidity	Clear	Clear
Specific Gravity	1.025	1.000 - 1.030
pH	6.0	4.5 - 8.0
Leucocyte	Negative	Negative
Glucose	Negative	Negative
Nitrit	Negative	Negative
Bilirubin	Negative	Negative
Blood	Negative	Negative
Urobilinogen	Normal	Normal
Protein	Negative	Negative
Keton	Negative	Negative

Microscopic

RBC	0-1	0 - 1
WBC	0-1	0 - 4
Cylinder	Negative	
Epithels Squamous	0-1	5 - 15
Crystals	Negative	
Bacteria	Negative	Negative
Others	Negative	

SPIROMETRY DIAGNOSTIC

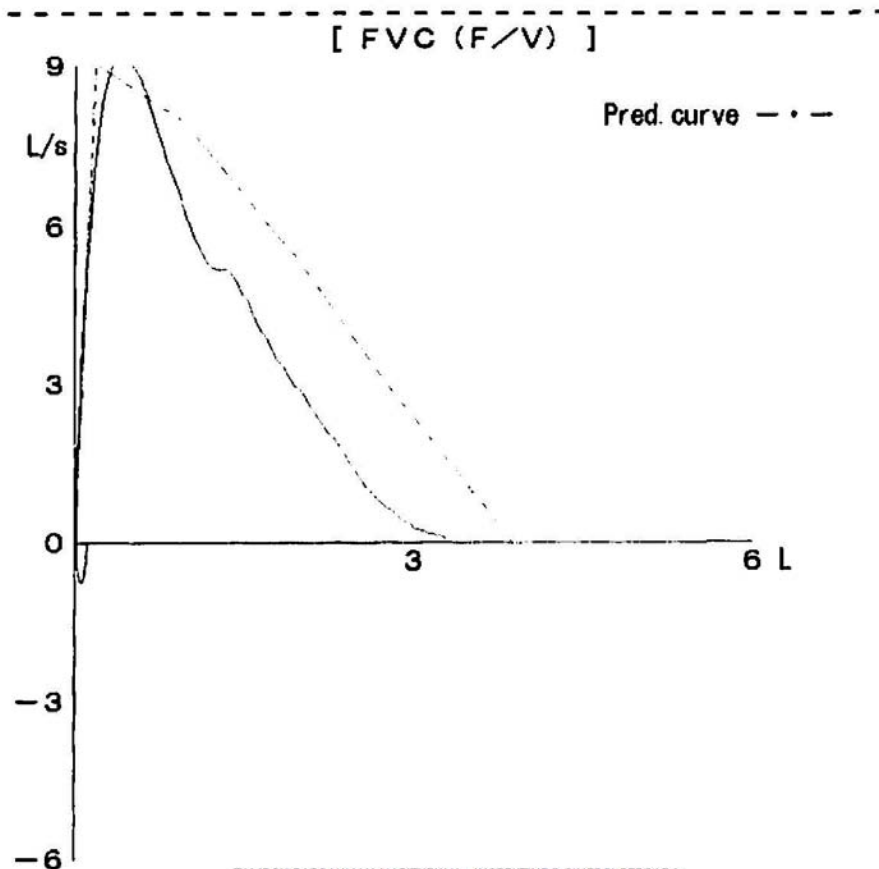
Name : TAMBOK PARSAULIAN NAPITUPULU	Sex : Male	MR : 01022516	Visit : 24/05/2018
Comp. : INSPEKTINDO SINERGI PERSADA		DOB : 27 July 1974	

EXAMINATION	RESULT
FVC Result	: 3.28 L---> 84.5 %
FEV1 Result	: 2.82 L---> 82.2 %
FEV1/FVC Result	: 85.98 %---> 113.5 %
PEF Result	: 9.15 L/S---> 87.9 %
Indonesian Standart Result	:
Index	:
Spirometry Result	: Normal

Impression : Normal Spirometric Functions

[COPD CLASSIFICATION]

FEV1/FVC : 85.98 %
 %FEV1.0 : 82.20 %
 Stage : Normal
 Recommended treatment by GOLD:

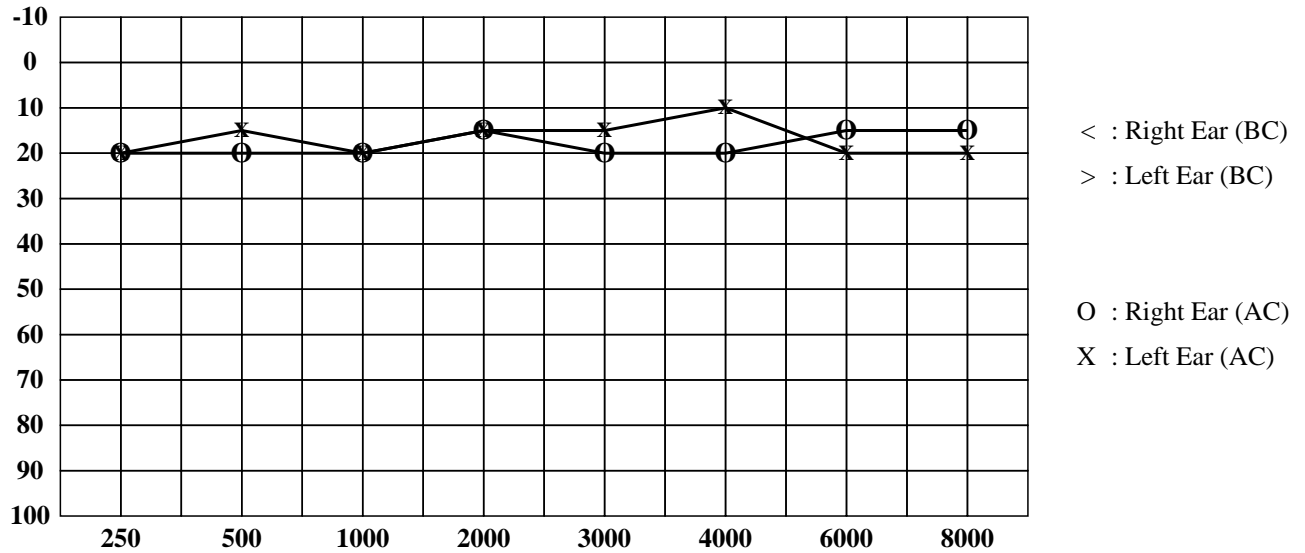


AUDIOMETRY DIAGNOSTIC

Name : TAMBOK PARSAULIAN NAPITUPULU	Sex : Male	MR : 01022516	Visit : 24/05/2018
Comp. : INSPEKTINDO SINERGI PERSADA		DOB : 27 July 1974	

RESULT

	Left Ear									Right Ear							
	250	500	1000	2000	3000	4000	6000	8000		250	500	1000	2000	3000	4000	6000	8000
AC	20	15	20	15	15	10	20	20		20	20	20	15	20	20	15	15
BC	-	-	-	-	-	-	-	-		-	-	-	-	-	-	-	-



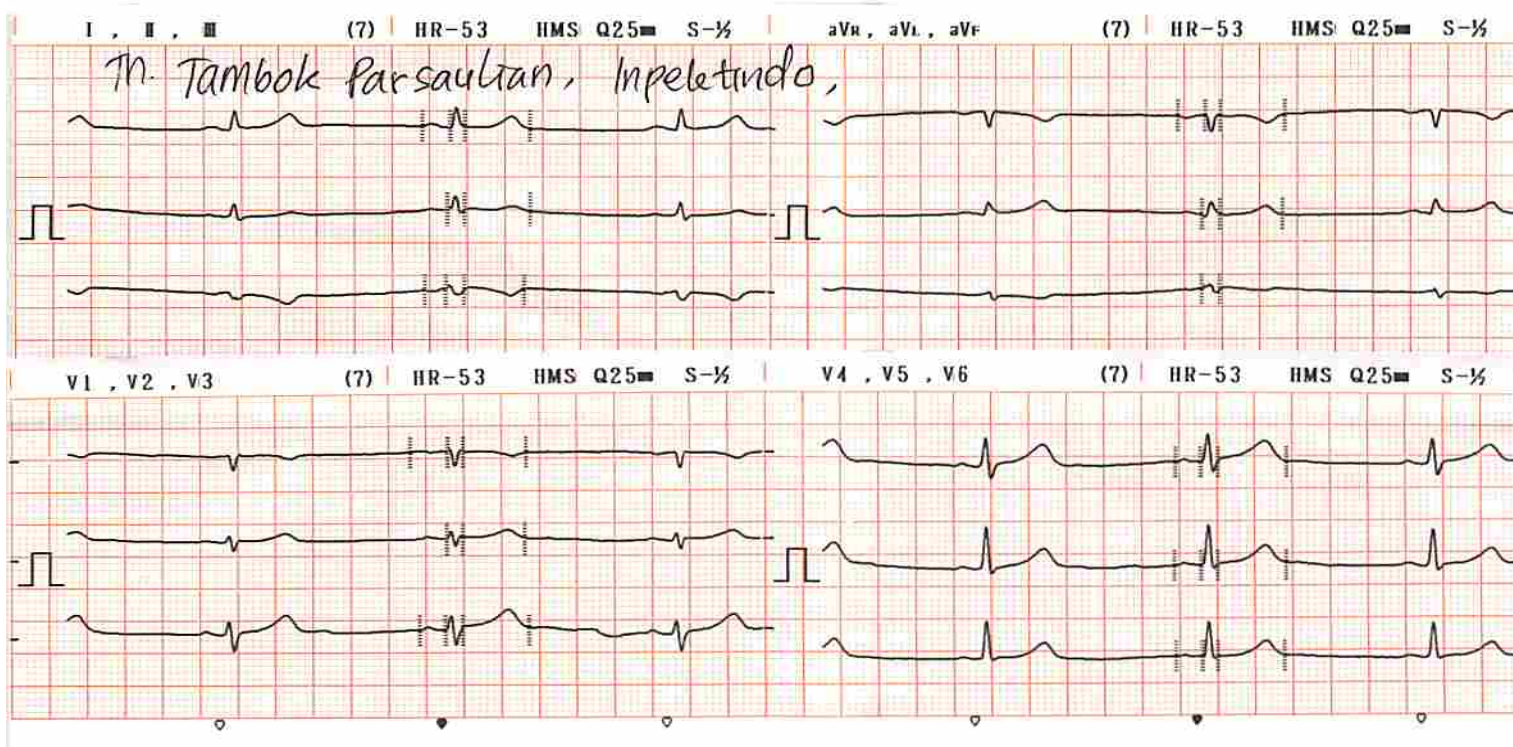
Conclusion Right Ear : Hearing threshold = 18.75 dB
(Within normal limit)

Conclusion Left Ear : Hearing threshold = 15 dB
(Within normal limit)

CARDIOLOGY DIAGNOSTIC

Name : TAMBOK PARSAULIAN NAPITUPULU	Sex : Male	MR : 01022516	Visit : 24/05/2018
Comp.: INSPEKTINDO SINERGI PERSADA		DOB : 27 July 1974	

EXAMINATION	RESULT	Comments :
ELECTROCARDIOGRAPHY	Sinus Rythm axis (N), P wave (N), PR int 0.16" ST - T segment (N), aritmia (-)	Normal ECG
TREADMILL	Sinus Rythm axis (N), P wave (N), PR int 0.16" ST - T segment (N), aritmia (-)	Treadmill Exercise Test : Negative Cardiopulmonary Fitness Classification : Good METs : 12.1



Name: YAMOCK FARMULIAN N

ID: I009901030

5/24/2018 07:34:36

HR: 58

Clin. Class: Normal

Medication(s): No Medication

BP: 110/78

: Normal

: No Medication

Age: 43 Years

Department: MEDIKA PLAZA

Gender: Male

Technician: Mr. Jemi

Race: Oriental

Physician: Dr. Adolf D64P

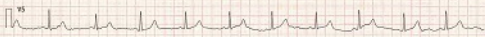
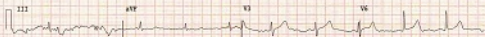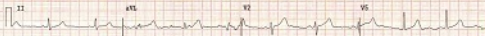
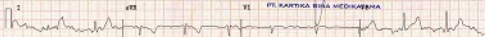
Height: 170 cm

Weight: 83 Kg

SUPINE R00

MP+

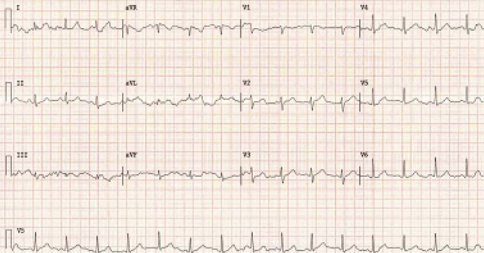
PT. KARTIKA BINA MEDIKAPLAZA



HR: 91 Phase: Exercise
EF: 110/70 Exercise Time: 02:50
RPE: Stage/Time: 1/02:50
METs: 4.5 Workload: 2.7 kmh 9.9 % grade
Protocol: Bruce

Baseline

Current

L +
S +L +
S +

Name: YANKEE JAGGEMILLER N

ID: IMPDETDDO

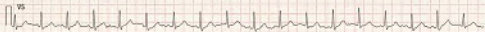
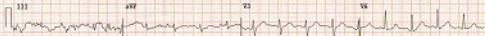

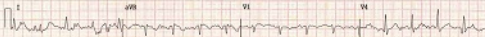
5/24/2018 07:46:37

Worst Case S-T Depression

HR: 100	Phase:	Exercise
EF: 126/88	Exercise Time:	03:50
EF2:	Stop/Time:	2/02:50
HRs: 7.0	Workload:	4.0 kwh 12.0 % grade
	Protocol:	Exercise

Baseline

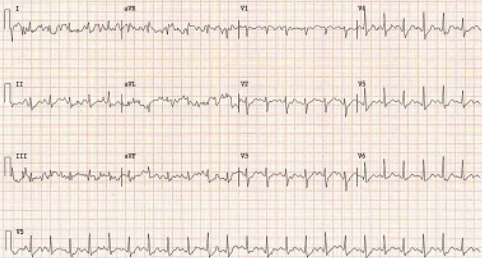Current

L *
S *L *
S *

HR: 142 Phase: Exercise
BP: 125/85 Exercise Time: 08:50
RPE: Stop/Time: 3/02:50
METs: 10.1 Workload: 5.4 kmh 15.5 % grade
Protocol: Bruce

Baseline

Current

L +
S +L +
S +

Name: THOMAS PARAGUILLEN N

ID: INSERVINDO

5/24/2018 07:44:47

Worst Case S-T Depression

ER: 164

Maximum Exercise

EF: 116/88

Exercise Time: 10:00

RPE: 12.4

Stop/Time: 4/01:00

METs: 12.4

Workload: 6.7 kmh 15.9 % grade

Protocol: Bruce

Baseline

Current

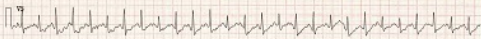
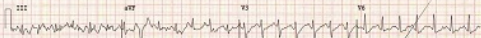
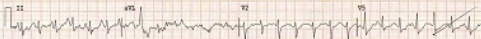
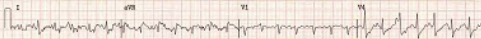
L *

S *

L *

S *

MAXIMUM EXERCISE ECG



Medication(s): No Medication
 : No Medication
 Age: 43 Years Clin. Class: Normal
 Gender: Male : Normal
 Race: Oriental Department: MEDIKA PLAZA
 Height: 170 cm Technician: Mr. Joni
 Weight: 82 Kg Physician: Dr. Adolf DGD

SUMMARY:
 - The Bruce test ran for 10:00 mins. Peak METs was 12.1.
 - A peak heart rate of 169 bpm was achieved at 09:59 mins in exercise.
 - 92% of the 177 bpm max was reached.
 - The peak BP was 138/88 (during Exercise). Baseline was 110/70.

Protocol: Bruce

TIME	STAGE	HR	GRASS	HR	BP	STP METS	ECG/ECG RHYTHM EVENTS	COMMENTS
00:00	Exercise	1.3	0.0	82		1.0	Bruce	
01:00	Exercise	2.7	0.9	88	110/70	96		
02:00	Exercise	2.7	0.9	93		4.1		
03:00	Exercise	2.7	0.9	93	110/70	102		
04:00	Exercise	4.0	10.3	102	120/80	122		
05:00	Exercise	4.0	12.6	105		7.0		
06:00	Exercise	4.0	12.0	108	120/80	129		
07:00	Exercise	5.4	15.0	120	120/80	151		
08:00	Exercise	5.4	13.9	137	120/80	164		
09:00	Exercise	5.4	15.9	144	120/80	172		
10:00	Max Exer.	6.7	19.5	163	120/80	195		
00:30	Recovery	2.3	0.0	155	120/80	106		

Adolf DGD
Paul Paul
MP+
 PT. KARTIKA DINAS MEDIKATA