

Certificate Of Health Assessment



Name	Age	Position	Department
VICTOR HOTMAN LUKMAN SIBUEA	27 Years Old	SUPERVISOR	

COMPANY :

INSPEKTINDO SINERGI PERSADA

CONCLUSION

Fit for work to the job described	
Fit with Medical Note (Restriction and/or Limitation)	✓
Unfit for work to the job described	

Date	Doctors Name	Signature
04 August 2016	Amiruddin, MD	 

No. Formulir : FM-DR-008-05
No. Revisi : 00
Tanggal Terbit : 2 Mei 2011

HEALTH ASSESSMENT REPORT

Of

VICTOR HOTMAN LUKMAN SIBUEA
01051796

Thursday, 04 August 2016

MEDIKA PLAZA CLINIC

Kartika Chandra - Office Tower 3rd Floor
Jl. Jend. Gatot Subroto, Kav. 18-20 Jakarta Selatan 12940
Tlp : (62-21) 525 1207, Fax : (62-21) 521 0815
Appointment Hotline (62-21) 528 80088
www.medikaplaza.com

MEDIKA PLAZA CLINIC

Kartika Chandra - Office Tower 3rd Floor
Jl. Jend. Gatot Subroto, Kav. 18-20 Jakarta Selatan 12940
Tlp : (62-21) 525 1207, Fax : (62-21) 521 0815
Appointment Hotline (62-21) 528 80088
www.medikaplaza.com

PATIENT DATA

MedRec.	: 01051796	EMPLOY. STATUS	: Employee
NAME	: VICTOR HOTMAN LUKMAN SIBUEA	BIRTHDATE	: 14 January 1989
EMPLOYEE No.	: 14049	SEX	: Male
JOB TITLE	: SUPERVISOR	STATUS	: Married
COMP. NAME	: INSPEKTINDO SINERGI PERSADA	NASIONALITY	: Indonesia

SUMMARY

MEDICAL FINDING :

1. Dislipidemia
2. Hyperuricemia
3. Increase SGPT level
4. Increase ESR count
5. Overweight
6. Impacted, calculus teeth

Your fitness status is fit with medical note :

1. Dislipidemia
2. Hyperuricemia

SUGGESTION :

1. Low fat and carbohydrate diet, exercise regularly minimal 3x/week
2. Low purine diet such as meats including organ meats, alcoholic beverages, beans, shrimp, scallops, some vegetables in limited amount such as: spinach, cauliflower, asparagus and mushroom
3. Consult to an internist for evaluation of dislipidemia and hyperuricemia
4. Take a time to rest minimal 8 hours/day
5. Repeat ESR examination 1 month later
6. Reduce body weight gradually 0.5 Kgs/week, by doing regular exercise (aerobic/jogging), 3-4x/week, 30-45 minutes and reduce high calorie diet until maximal body weight is 75.69 Kgs (present body weight is 85.3 Kgs)
7. See a dentist for dental care minimal once a year or better once in 6 month

Responsible Doctor


Amiruddin, MD

Notes:

If you need the further information or consultation, please contact us via :

Email : - kcdoctor01@medikaplaza.com
- kcdoctor03@medikaplaza.com

Clinic Number : (021) 5251207

CLINICAL EVALUATION

Name : VICTOR HOTMAN LUKMAN SIBUEA	Sex : Male	MR : 01051796	Visit : 04/08/2016
Comp. : INSPEKTINDO SINERGI PERSADA		DOB : 14 January 1989	
EXAMINATION	RESULT	NOTES	

PHYSICAL EXAMINATION**PRESENT COMPLAINT**

Present complaint

No complaint

MEDICAL HISTORY

Alergy

No

Imunisasi

Yes

Surgery

No

Hospitalization

No

Disease

Yes

Suspect DHF

LIFE STYLE

Alcohol intake

No

Smoking

Yes

Electric smoke

Exercise

No

Appetite

Good

FAMILY MEDICAL HISTORY

Diabetes Melitus

No

Hypertension

No

Heart disease

No

Lung TB

No

Kidney disease

No

Astma

No

Mental disease

No

Epilepsy

No

Chronic skin disease

No

Cancer

No

Color blind

No

Stroke

No

Liver disease

No

Bone & joint

No

Pulmonary disease

No

Others disease

No

WORK EXPOSURE

Noise

No

Heat Stress

No

Cold Stress

No

Vibration

No

Dust

No

CLINICAL EVALUATION

Name : VICTOR HOTMAN LUKMAN SIBUEA	Sex : Male	MR : 01051796	Visit : 04/08/2016
Comp. : INSPEKTINDO SINERGI PERSADA		DOB : 14 January 1989	

EXAMINATION	RESULT	NOTES
Toxic chemical	No	
Irritating fluid	No	
Heat Stress	No	
Operating heavy mobile equipment	No	
Working arround rotating machinery	No	
Requires color vision	No	
Involving height	No	
Administration work	Yes	
Handling food product	No	
Others	No	
GENERAL		
General Appearance	Good	
Nutrition Status	Normal	
VITAL SIGN		
Body Weight	85.3 Kg	
Body Height	174 Cm	
BMI	28.17 Kg/m2	
Normal Weight	56.01 - 75.69 Kg	
BMI Conclusion	Overweight	
Blood Pressure	120/80 mmHg	
Pulse	82 x/minute	
Body Temperature	36.1 °C	
RR	18	
Neck Circumference	-	
Arm Circumference	-	
Chest size	-	
Abdominal Circumference	-	
SKIN		
Skin	Normal	
Pale	No	
Jaundice	No	
EYE		
Left	Normal	
Right	Normal	
ENT		
Auricle	Normal	
Ear canal	Normal	

CLINICAL EVALUATION

Name : VICTOR HOTMAN LUKMAN SIBUEA Sex : Male MR : 01051796 Visit : 04/08/2016

Comp. : INSPEKTINDO SINERGI PERSADA DOB : 14 January 1989

EXAMINATION	RESULT	NOTES
Drums	Normal	
Septum/Conchae	Normal	
Sinuses	Normal	
Pharynx	Normal	
Tonsil	Normal	
MOUTH		
Gum	Normal	
Dental	Abnormal	Impacted, calculus teeth
NECK		
General	Normal	
Thyroid Gland	Normal	
CHEST		
Form	Normal	
Expansion	Normal	
Lung	Normal	
Heart	Normal	
Breast	Normal	
Heart sound	Normal	
Murmurs	Normal	
ABDOMEN		
Form	Flat	
Palpation	Supple	
Liver	Not Palpable	
Spleen	Not Palpable	
Kidney	No Ballotment	
Hernia inguinal	No	
EXTRIMITIES		
Bones,joint	Normal	
Muscles,tonus	Normal	
Fingernails	Normal	
Hand	Normal	
Foot	Normal	
RECTAL EXAMINATION		
Hemorrhoid	Negative	
Rectum	Normal	
NEUROLOGICAL EXAMINATION		
Motoric function	Normal	

CLINICAL EVALUATION

Name : VICTOR HOTMAN LUKMAN SIBUEA

Sex : Male

MR : 01051796

Visit : 04/08/2016

Comp. : INSPEKTINDO SINERGI PERSADA

DOB : 14 January 1989

EXAMINATION	RESULT	NOTES
Sensoric function	Normal	
Coordination	Normal	
Physiologic reflex	Normal	
Extra piramidal function	Normal	
LYMPHE SYSTEM		
Neck Gland	Normal	
Armpit gland	Normal	
Inguinal	Normal	

OPHTHALMOLOGY DIAGNOSTIC

Name : VICTOR HOTMAN LUKMAN SIBUEA Sex : Male MR : 01051796 Visit : 04/08/2016

Comp. : INSPEKTINDO SINERGI PERSADA DOB : 14 January 1989

EXAMINATION		Right	Left
Reading		-	-
Previous Glasses		-	-
Without Glasses	Distant	20/20	20/20
	Near	-	-
Correction	Distant	-	-
	Near	-	-
Tonometry		-	-
Funduscopy		-	-
Colour Blind Test		Normal	

Impression :

RADIOLOGY DIAGNOSTIC**Name** : VICTOR HOTMAN LUKMAN SIBUEA **Sex** : Male **MR** : 01051796 **Visit** : 04/08/2016**Comp.** : INSPEKTINDO SINERGI PERSADA **DOB** : 14 January 1989

EXAMINATION	RESULT
--------------------	---------------

Thorax PA	No abnormality seen in both lungs. Normal bronchovascular markings in both hili. The heart is normal in size and shape. The mediastinum is not widened. Both sinus and diaphragms are good. No evidence of pleural effusion.
-----------	---

Impression	Normal chest. No evidence of specific process in both lungs.
------------	---

LABORATORY	
Name :	VICTOR HOTMAN LUKMAN SIBUEA
Comp. :	INSPEKTINDO SINERGI PERSADA
EXAMINATION	

LAB NO: 16002882

Nama :
Umur :
Alamat :

VICTOR HOTMAN LUKMAN SIBUEA
01081796-L
14-01-88
INSPEKTINDO SINERGI PERSADA

GOL DARAH
AB
Rh **+POS**

anti : A anti : B anti : AB anti : Rh

HEMATOLOGI

ABO/Rh Typing

Automated Blood Count

White Blood Cell (WBC)	7.9	3.8 - 11.0
Erythrocyte (RBC)	5.4	4.4 - 5.9
Haemoglobin	15.8	13.2 - 17.3
Hematocrit	46	40 - 52
Thrombocytes	337	150 - 440

MCV, MCH, MCHC

MCV	86	80 - 100
MCH	29	26 - 34
MCHC	34.1	32 - 36
ESR	45 *	0 - 10

Differential Count

Basophils	1	0 - 1
Eosinophil	3	2 - 4
Bands / Stab	1 *	3 - 5
Neutrophils	52	50 - 70
Lymphocytes	34	25 - 40
Monocytes	9 *	2 - 8

BLD CHEMISTRY/LIPID PROFILE

Total Cholesterol	249 *	Normal/Desireable: <200 Borderline High: 200-239 High: >=240
HDL Cholesterol	48.9	Normal : >40 - <60 Low HDL : <40 Desireable : >=60
LDL Cholesterol	157 *	Optimal: <100 Near/Above Optimal: 100-129 Borderline High: 120-159 High: 160-189 Very High: >=190
T.Cholesterol/HDL Ratio	5.09 *	Low risk : < 3.5 Medium risk : 3.5 - 5.0 High risk : > 5.0

LABORATORY RESULT

Name : VICTOR HOTMAN LUKMAN SIBUEA	MR : 01051796	Visit : 04/08/2016	#Lab : IN566429797022
Comp. : INSPEKTINDO SINERGI PERSADA	Sex : Male	DOB : 14 January 1989	

EXAMINATION	RESULT	NORMAL RANGE
Tryglicerides	215 *	Normal : <150 Borderline High: 150-199 High : 200-499 Very High : >=500

BLD CHEMISTRY/KIDNEY FUNCTION

Ureum	18.8	10.0 - 50.0
Creatinine	0.9	0.6- 1.3
Uric Acid	11.1 *	3.5 - 7.2

BLD CHEMISTRY/LIVER FUNCTION

SGOT(AST)	28	13 - 45
SGPT (ALT)	60 *	13 - 50

BLD CHEMISTRY/DIABETES

Fasting Glucose

Glucose Fasting	94	< 100
Glucose Urine	NEG	Negative
Keton Urine	NEG	Negative

URINALYSIS

Complete Urine Analysis

Macroscopic

Color	YELLOW	
Turbidity	CLEAR	Clear
Specific Gravity	1.024	1.000 - 1.030
pH	5.5	4.5 - 8.0
Leucocyte	NEG	Negative
Glucose	NEG	Negative
Nitrit	NEG	Negative
Bilirubin	NEG	Negative
Blood	NEG	Negative
Urobilinogen	NORM	Negative
Protein	NEG	Negative
Keton	NEG	Negative

Microscopic

RBC	0-1	0 - 1
WBC	0-2	0 - 4
Cylinder	Negative	
Epithels Squamous	0-1	5 - 15
Crystals	Negative	

LABORATORY RESULT

Name : VICTOR HOTMAN LUKMAN SIBUEA	MR : 01051796	Visit : 04/08/2016	#Lab : IN566429797022
------------------------------------	---------------	--------------------	-----------------------

Comp. : INSPEKTINDO SINERGI PERSADA	Sex : Male	DOB : 14 January 1989
-------------------------------------	------------	-----------------------

EXAMINATION	RESULT	NORMAL RANGE
Bacteria	NEG	Negative
Others	Negative	

SPIROMETRY DIAGNOSTIC

Name : VICTOR HOTMAN LUKMAN SIBUEA	Sex : Male	MR : 01051796	Visit : 04/08/2016
Comp. : INSPEKTINDO SINERGI PERSADA	DOB : 14 January 1989		

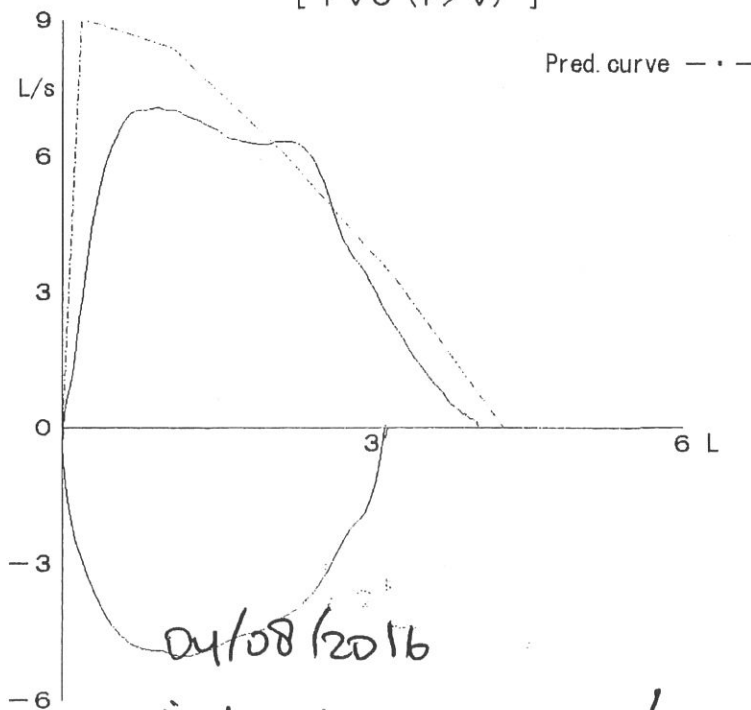
EXAMINATION	RESULT
FVC Result	: 4.03 L---> 94.2 %
FEV1 Result	: 3.73 L---> 91.2 %
FEV1/FVC Result	: 92.56 %---> 113.3 %
PEF Result	: 7.07 L/S---> 68.0 %
Indonesian Standart Result	:
Index	:
Spirometry Result	: Normal

Impression : Normal Spirometric Functions

[COPD CLASSIFICATION]

FEV1/FVC : 92.56 %
 %FEV1.0 : 91.20 %
 Stage : Normal
 Recommended treatment by GOLD:

[FVC (F/V)]



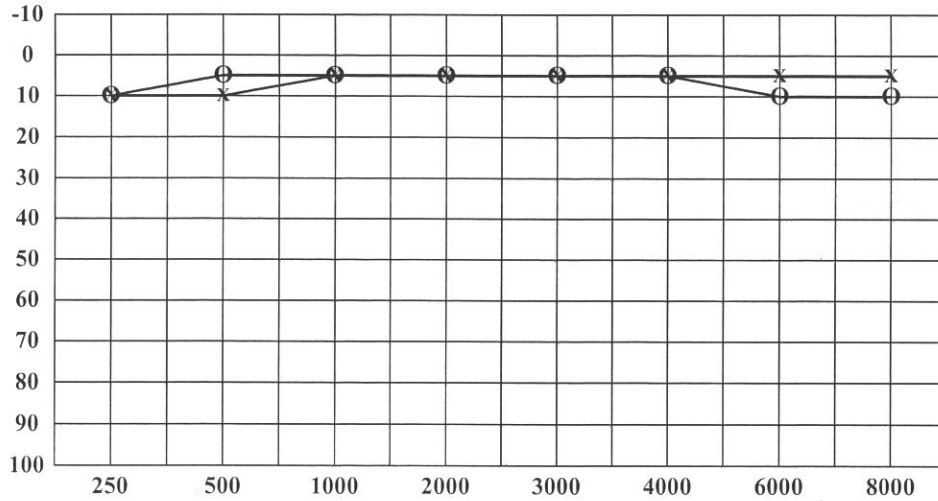
AUDIOMETRY DIAGNOSTIC

Name : VICTOR HOTMAN LUKMAN SIBUEA	Sex : Male	MR : 01051796	Visit : 04/08/2016
Comp. : INSPEKTINDO SINERGI PERSADA		DOB : 14 January 1989	

RESULT

Left Ear	250	500	1000	2000	3000	4000	6000	8000
AC	10	10	5	5	5	5	5	5
BC	-	-	-	-	-	-	-	-

Right Ear	250	500	1000	2000	3000	4000	6000	8000
AC	10	5	5	5	5	5	10	10
BC	-	-	-	-	-	-	-	-



< : Right Ear (BC)
 > : Left Ear (BC)

 O : Right Ear (AC)
 X : Left Ear (AC)

Conclusion Right Ear : Hearing threshold = 5 dB
(Within normal limit)

Conclusion Left Ear : Hearing threshold = 6.25 dB
(Within normal limit)

CARDIOLOGY DIAGNOSTIC

Name : VICTOR HOTMAN LUKMAN SIBUEA	Sex : Male	MR : 01051796	Visit : 04/08/2016
Comp. : INSPEKTINDO SINERGI PERSADA		DOB : 14 January 1989	
EXAMINATION	RESULT	Comments :	

ELECTROCARDIOGRAPHY Sinus Rythm axis (N), P wave (N), PR int 0.16" Normal ECG
 ST - T segment (N), aritmia (-)

