

HEALTH ASSESSMENT REPORT

Of

ALFONSUS LIQUORI
01.00064128

Friday, 03 August 2018

MP BELTWAY CLINIC

Beltway Office Park, Annex Building, Ground Floor
Jl. TB. Simatupang Kav.41, Jakarta Selatan 12550
Tlp : (62-21) 808 66 099, Fax : (62-21) 808 66 098
www.medikaplaza.com

MP BELTWAY CLINIC

Beltway Office Park, Annex Building, Ground Floor
Jl. TB. Simatupang Kav.41, Jakarta Selatan 12550
Tlp : (62-21) 808 66 099, Fax : (62-21) 808 66 098
www.medikaplaza.com

PATIENT DATA

MedRec.	: 01.00064128	EMPLOY. STATUS	: Employee
NAME	: ALFONSUS LIQUORI	BIRTHDATE	: 01 August 1992
EMPLOYEE No.	: -	SEX	: Male
JOB TITLE	: INSPECTOR	STATUS	: Single
COMP. NAME	: INSPEKTINDO SINERGI PERSADA	NASIONALITY	: INDONESIA

SUMMARY

MEDICAL FINDING :


1. Hypertriglyceridemia
 2. Obesity
 3. Decayed, calculus teeth
 4. Decreasing of visual acuity of left eye
 5. Spirometry : mild restrictive and moderate obstructive
- Your fitness status is fit with medical note :

1. Hypertriglyceridemia
2. Spirometry : mild restrictive and moderate obstructive

SUGGESTION :

1. Low fat and carbohydrate diet, exercise regularly minimal 3 times a week. Consult to an internist for further evaluation of hypertriglyceridemia
2. Reduce body weight gradually 0.5 Kgs/week, by doing regular exercise (aerobic/jogging), 3-4x/week, 30-45 minutes and reduce high calorie diet until maximal body weight is 71.40 Kgs (present body weight is 86.4 Kgs). See a Clinical Nutrition Specialist for evaluation of Obesity
3. See a dentist for dental care, minimal once a year or better once in six month
4. You need to wear the glasses for distant vision
5. Repeat spirometry examination. Avoid fumes and dust and use face mask while working at dusty area. Consult to a pulmonologist afterwards for evaluation of Spirometry : mild restrictive & moderate obstructive

Responsible Doctor



Maria Erlin, MD

Notes:

If you need the further information or consultation, please contact us via :

Email : - beltway.doctor@medikaplaza.com
- beltway.doctor2@medikaplaza.com
Telepon Klinik : (62-21) 8086 6000

CLINICAL EVALUATION

Name : ALFONSUS LIQUORI	Sex : Male	MR : 01.00064128	Visit : 03/08/2018
Comp. : INSPEKTINDO SINERGI PERSADA		DOB : 01 August 1992	

EXAMINATION	RESULT	NOTES
-------------	--------	-------

ANAMNESA

PRESENT COMPLAINT AND HISTORY OF PRESENT

ILLNESS

Present complaint

No complaint

MEDICAL HISTORY

Allergy

Yes

Seafood

Imunisasi

Yes

Surgery

Yes

Tonsilectomy, Hand fracture on 2008

Hospitalization

Yes

Disease

No

LIFE STYLE

Alcohol intake

No

Smoking

Yes

Exercise

No

FAMILY MEDICAL HISTORY

Diabetes Melitus

No

Hypertension

Yes

Mother

Heart disease

No

Lung TB

No

Kidney disease

No

Astma

No

Mental disease

No

Epilepsy

No

Cancer

No

Color blind

No

Stroke

No

Liver disease

No

Bone & joint

No

Others disease

No

WORK EXPOSURE

Noise

Yes

Heat Stress

Yes

Cold Stress

No

Vibration

Yes

Involving height

Yes

Radiation

No

Dust

Yes

CLINICAL EVALUATION

Name : ALFONSUS LIQUORI	Sex : Male	MR : 01.00064128	Visit : 03/08/2018
Comp. : INSPEKTINDO SINERGI PERSADA		DOB : 01 August 1992	

EXAMINATION	RESULT	NOTES
Toxic chemical	No	
Irritating fluid	No	
Smoke	Yes	
Bacterium/Virus/Parasite	No	
Blood	No	
Animal	No	
Operating heavy mobile equipment	No	
Manual Handling	Yes	
Sitting continuously over 4 hours	No	
Stand continuously over 4 hours	No	
Using monitor screen more than 4 hours per day	No	
Exposure	No	
Unergonomic body positions	No	
Shift work	No	
Work is not accordance with skills and knowledge	No	
Workload does not accordance with time	No	
Work conflict	No	
Inappropriate task	No	
Career barriers	No	
Family conflict	No	
Working around rotating machinery	No	
Administration work	No	
Handling food product	No	
Others	Yes	Offshore/Onshore

PHYSICAL EXAMINATION

General Appearance	Good
Body shape	Athleticus

VITAL SIGN

Body Weight	86.4 Kg
Body Height	169 Cm
BMI	30.25 Kg/m2
Normal Weight	52.84 - 71.40 Kg
BMI Conclusion	Obesity
Blood Pressure	110/70 mmHg
Pulse	86 x/minute
Body Temperature	36 °C
RR	20

CLINICAL EVALUATION

Name : ALFONSUS LIQUORI	Sex : Male	MR : 01.00064128	Visit : 03/08/2018
Comp. : INSPEKTINDO SINERGI PERSADA		DOB : 01 August 1992	

EXAMINATION	RESULT	NOTES
Neck Circumference	41 Cm	
Arm Circumference	17 Cm	
Chest size	98 Cm	
Abdominal Circumference	101 Cm	
SKIN		
Skin	Abnormal	Permanent tattoo at the centre of chest
EYE		
Left	Normal	
Right	Normal	
ENT		
Auricle	Normal	
Ear canal	Normal	
Drums	Normal	
Septum/Conchae	Normal	
Sinuses	Normal	
Pharynx	Normal	
Tonsil	Normal	
MOUTH		
Gum	Normal	
Dental	Abnormal	Decayed, calculus teeth
NECK		
General	Normal	
Thyroid Gland	Normal	
CHEST		
Form	Normal	
Lung	Normal	
Heart	Normal	
Breast	Normal	
ABDOMEN		
Form	Flat	
Palpation	Supple	
Liver	Not Palpable	
Spleen	Not Palpable	
Kidney	No Ballotment	
-	No	
Hernia inguinal	No	
EXTRIMITIES		

CLINICAL EVALUATION

Name : ALFONSUS LIQUORI

Sex : Male

MR : 01.00064128

Visit : 03/08/2018

Comp. : INSPEKTINDO SINERGI PERSADA

DOB : 01 August 1992

EXAMINATION	RESULT	NOTES
Bones,joint	Normal	
Muscles,tonus	Normal	
Fingernails	Normal	
Hand	Normal	
Foot	Normal	
RECTAL EXAMINATION		
Hemorrhoid	Negative	
Rectum	Normal	
SENSORIK EXAMINATION		
Tes Raba	Normal	
MOTORIK EXAMINATION		
Tes Grip	Normal	
REFLEX EXAMINATION		
Physiologic reflex	Normal	
Patologic reflex	Normal	
OTHERS EXAMINATION		
Coordination	Normal	
LYMPHE SYSTEM		
Submandibula	Normal	
Neck Gland	Normal	
Armpit gland	Normal	
Inguinal	Normal	

OPHTHALMOLOGY DIAGNOSTIC

Name : ALFONSUS LIQUORI	Sex : Male	MR : 01.00064128	Visit : 03/08/2018
Comp. : INSPEKTINDO SINERGI PERSADA		DOB : 01 August 1992	

EXAMINATION		Right	Left
Reading		-	-
Previous Glasses		-	-
Without Glasses	Distant	20/20	20/25
	Near	J1	J1
Correction	Distant	-	-
	Near	-	-
		-	-
Tonometry		-	-
Funduscopy		-	-
Visual Fields		-	-
Colour Blind Test		Normal	

Impression : Decreasing of visual acuity of left eye

RADIOLOGY DIAGNOSTIC

Name : ALFONSUS LIQUORI	Sex : Male	MR : 01.00064128	Visit : 03/08/2018
Comp. : INSPEKTINDO SINERGI PERSADA		DOB : 01 August 1992	

EXAMINATION	RESULT
-------------	--------

THORAX PA

No abnormality seen in both lungs.
Normal bronchovascular markings in both hili.
The heart is normal in size and shape.
The mediastinum is not widened.
Both sinus and diaphragms are good.
No evidence of pleural effusion.

Impression

Normal chest.
No evidence of specific process in both lungs.

LABORATORY RESULT

Name : ALFONSUS LIQUORI	MR : 01.00064128	Visit : 03/08/2018	#Lab : IN639325459456
Comp. : INSPEKTINDO SINERGI PERSADA	Sex : Male	DOB : 01 August 1992	

EXAMINATION	RESULT	NORMAL RANGE
-------------	--------	--------------

HEMATOLOGI

ABO/Rh Typing "B" Rh(+) positive

Automated Blood Count

White Blood Cell (WBC)	10.0	3.8 - 11.0
Erythrocyte (RBC)	5.6	4.4 - 5.9
Haemoglobin	17.3	13.2 - 17.3
Hematocrit	49	40 - 52
Thrombocytes	265	150 - 440

MCV, MCH, MCHC

MCV	87	80 - 100
MCH	31	26 - 34
MCHC	35.2	32 - 36
ESR	4	0 - 10

Differential Count

Basophils	0	0 - 1
Eosinophil	3	2 - 4
Bands / Stab	2 *	3 - 5
Neutrophils	39 *	50 - 70
Lymphocytes	46 *	25 - 40
Monocytes	10 *	2 - 8

BLD CHEMISTRY/LIPID PROFILE

Total Cholesterol	176	Normal/Desireable: <200 Borderline High: 200-239 High: >=240
HDL Cholesterol	34.7 *	Normal : >40 - <60 Low HDL : <40 Desireable : >=60
LDL Cholesterol	67	Optimal: <100 Near/Above Optimal: 100-129 Borderline High: 130-159 High: 160-189 Very High: >=190
Tryglicerides	372 *	Normal : <150 Borderline High: 150-199 High : 200-499 Very High : >=500

BLD CHEMISTRY/KIDNEY FUNCTION

LABORATORY RESULT

Name : ALFONSUS LIQUORI	MR : 01.00064128	Visit : 03/08/2018	#Lab : IN639325459456
Comp. : INSPEKTINDO SINERGI PERSADA	Sex : Male	DOB : 01 August 1992	

EXAMINATION	RESULT	NORMAL RANGE
Ureum	22.4	10.0 - 50.0
Creatinine	1.0	0.6- 1.3
Uric Acid	4.9	3.5 - 7.2

BLD CHEMISTRY/LIVER FUNCTION

SGOT(AST)	23	13 - 45
SGPT (ALT)	46	13 - 50
Alkaline Phosphatase	85	30 - 120
Gamma GT	34	0 - 50

BLD CHEMISTRY/DIABETES

Glucose Fasting	73	< 100
Glucose Urine	Negative	Negative
Keton Urine	Negative	Negative

Blood Glucose 2 PP

Blood Sugar 2 Hours PP	88	< 140
Glucose Urine	Negative	Negative
Keton Urine	Negative	Negative

TOXICOLOGY - DRUGS SCREENING

Methadone	Negative	Negative
THC/Marijuana	Negative	Negative
Amphetamine	Negative	Negative
Benzodiazepines	Negative	Negative
Opiat	Negative	Negative
Cocain	Negative	Negative
Metamphetamine	Negative	Negative
Alcohol	Negative	Negative

URINALYSIS**Complete Urine Analysis****Macroscopic**

Color	Yellow	
Turbidity	Clear	Clear
Specific Gravity	1.026	1.000 - 1.030
pH	6.0	4.5 - 8.0
Leucocyte	Negative	Negative
Glucose	Negative	Negative
Nitrit	Negative	Negative
Bilirubin	Negative	Negative
Blood	Negative	Negative

LABORATORY RESULT

Name : ALFONSUS LIQUORI	MR : 01.00064128	Visit : 03/08/2018	#Lab : IN639325459456
Comp. : INSPEKTINDO SINERGI PERSADA	Sex : Male	DOB : 01 August 1992	

EXAMINATION	RESULT	NORMAL RANGE
Urobilinogen	Normal	Normal
Protein	Negative	Negative
Keton	Negative	Negative
Microscopic		
RBC	0-1	0 - 1
WBC	0-1	0 - 4
Cylinder	Negative	
Epithels Squamous	0-1	5 - 15
Crystals	Negative	
Bacteria	Negative	Negative
Others	Negative	

STOOL / RECTAL SWAP**Faeces Complete****Macroscopic**

Color	Brown	
Consistency	Smooth	
Mucus	Negative	Negative
Blood	Negative	Negative
Pus	Negative	Negative
Parasitologi Faeces	Negative	Negative
Lipid	Negative	Negative

Microscopic

RBC	0-1	0 - 1
WBC	0-1	0 - 5
Amoeba	Negative	
Ephitels	Positive	Positive
Worm Eggs	Negative	Negative
Yeast	Negative	Negative
Muscle Fiber	Negative	Negative
Others	Negative	Negative

Digestive

Amylum	Negative	Negative
Fat	Negative	
Fibers	Positive	Positive

SPIROMETRY DIAGNOSTIC

Name : ALFONSUS LIQUORI	Sex : Male	MR : 01.00064128	Visit : 03/08/2018
Comp. : INSPEKTINDO SINERGI PERSADA		DOB : 01 August 1992	

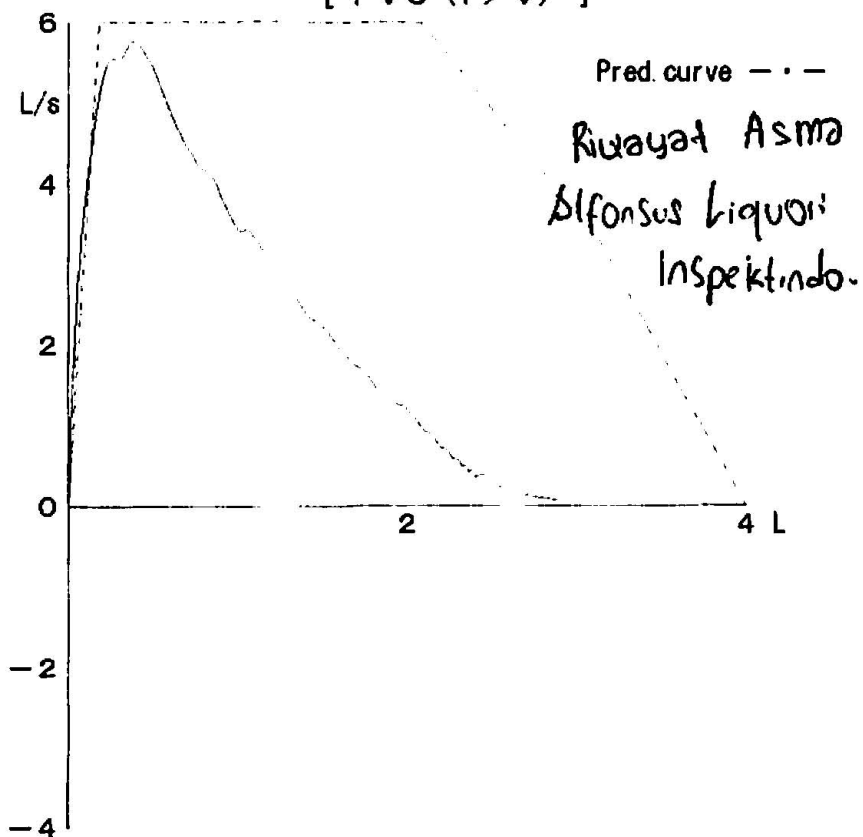
EXAMINATION	RESULT
FVC Result	: 2.89 L---> 69.1 %
FEV1 Result	: 2.26 L---> 57.1 %
FEV1/FVC Result	: 78.20 %---> 95.3 %
PEF Result	: 5.75 L/S---> 56.3 %
Indonesian Standart Result	:
Index	:
Spirometry Result	: Abnormal

Impression : Mild Restrictive & Moderate Obstructive

[COPD CLASSIFICATION]

FEV1/FVC : 78.20 %
 %FEV1.0 : 57.10 %
 Stage : Normal
 Recommended treatment by GOLD:

[FVC (F/V)]

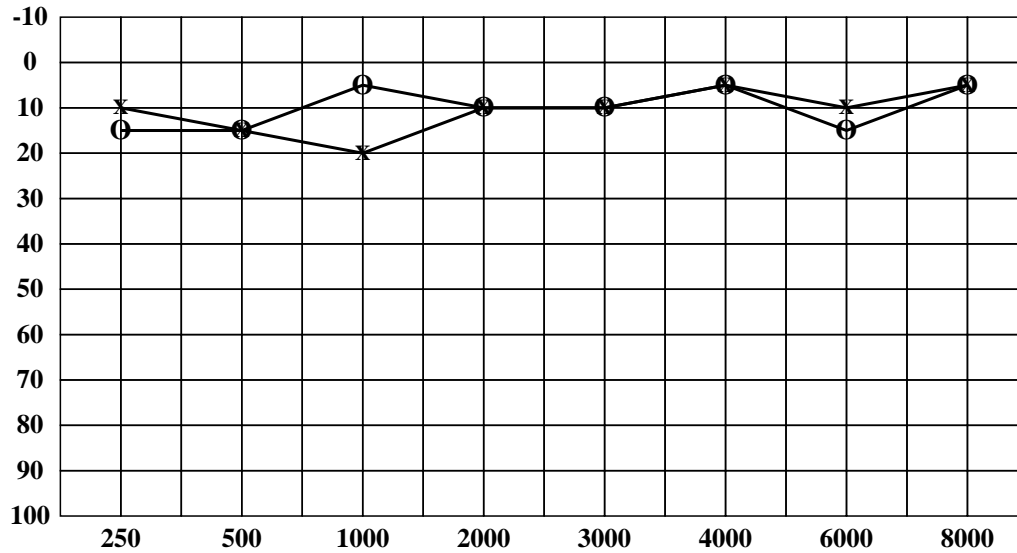


AUDIOMETRY DIAGNOSTIC

Name : ALFONSUS LIQUORI	Sex : Male	MR : 01.00064128	Visit : 03/08/2018
Comp. : INSPEKTINDO SINERGI PERSADA		DOB : 01 August 1992	

RESULT

	Left Ear									Right Ear							
	250	500	1000	2000	3000	4000	6000	8000		250	500	1000	2000	3000	4000	6000	8000
AC	10	15	20	10	10	5	10	5	AC	15	15	5	10	10	5	15	5
BC	-	-	-	-	-	-	-	-	BC	-	-	-	-	-	-	-	-



< : Right Ear (BC)
 > : Left Ear (BC)
 O : Right Ear (AC)
 X : Left Ear (AC)

Conclusion Right Ear : Hearing threshold = 8.75 dB
(Within normal limit)

Conclusion Left Ear : Hearing threshold = 12.5 dB
(Within normal limit)

CARDIOLOGY DIAGNOSTIC

Name : ALFONSUS LIQUORI	Sex : Male	MR : 01.00064128	Visit : 03/08/2018
Comp.: INSPEKTINDO SINERGI PERSADA		DOB : 01 August 1992	

EXAMINATION	RESULT	Comments :
ELECTROCARDIOGRAPHY	Sinus Rythm axis (N), P wave (N), PR int 0.16" ST - T segment (N), aritmia (-)	Normal ECG
TREADMILL	Sinus Rythm axis (N), P wave (N), PR int 0.16" ST - T segment (N), aritmia (-)	Treadmill Exercise Test : Negative Cardiopulmonary Fitness Classification : Good METs : 13.4

