

## Certificate Of Health Assessment

Name	Age	Position	Department
SYAIFUL	38 yo	INSPECTOR	-

### COMPANY :

**INSPEKTINDO SINERGI PERSADA, PT**



### CONCLUSION

FIT TO WORK

FIT WITH MEDICAL NOTE

TEMPORARY UNFIT

UNFIT

Issued Date	Doctors Name	Prepared By
10 January 2022	<b>Yosephine Simanungkalit, MD</b> PKTK : KEP.043/BINWASK3-PNK3/KK/II/2018	
Expired Date		Verified By
10 January 2023	<b>dr. Muhammad Ilyas, Sp.Ok</b> SIP : 29/B.156/31.74.04.1004.02.009.K.1/3/-1.779.3/e/2019	 PT. KARTIKA BINA MEDIKATAMA

No. Formulir : FM-DR-008-05  
 No. Revisi : 00  
 Tanggal Terbit : 2 Mei 2011

Certificate Number : **MP-BOP/1-20220110/134474**

MCU Validity Check  
<https://mcu-validasi.medikaplaza.com>

**TO WHOM IT MAY CONCERN**  
*Kepada yang berkepentingan*

This is certify that today Monday, 10 January 2022 Medika Plaza Clinic has performed urine drug screening and/or breath alcohol test to :


*Dengan ini menyatakan bahwa, pada hari ini Senin, 10 Januari 2022 Medika Plaza Clinic telah melakukan urine drug screening dan/atau breath alcohol test kepada :*

**SYAIFUL**

With the results are as follows :  
 Dengan hasil sebagai berikut :

Drugs Test Uji Obat	Result Hasil		
<b>URINE DRUGS SCREENING</b>			
- Amphetamine	<input type="checkbox"/> Non-Negative	<input checked="" type="checkbox"/> Negative	<input type="checkbox"/> N/A
- Met-Amphetamine	<input type="checkbox"/> Non-Negative	<input checked="" type="checkbox"/> Negative	<input type="checkbox"/> N/A
- Cocain	<input type="checkbox"/> Non-Negative	<input checked="" type="checkbox"/> Negative	<input type="checkbox"/> N/A
- THC/Canabis/Marijuana	<input type="checkbox"/> Non-Negative	<input checked="" type="checkbox"/> Negative	<input type="checkbox"/> N/A
- Morphine/Opiates	<input type="checkbox"/> Non-Negative	<input checked="" type="checkbox"/> Negative	<input type="checkbox"/> N/A
- P C P/Phencyclidine	<input type="checkbox"/> Non-Negative	<input checked="" type="checkbox"/> Negative	<input type="checkbox"/> N/A
- Barbiturate	<input type="checkbox"/> Non-Negative	<input type="checkbox"/> Negative	<input checked="" type="checkbox"/> N/A
- Benzodiazepin	<input type="checkbox"/> Non-Negative	<input checked="" type="checkbox"/> Negative	<input type="checkbox"/> N/A
- Methadone	<input type="checkbox"/> Non-Negative	<input checked="" type="checkbox"/> Negative	<input type="checkbox"/> N/A
- Propoxyphene	<input type="checkbox"/> Non-Negative	<input type="checkbox"/> Negative	<input checked="" type="checkbox"/> N/A
- Oxycodone	<input type="checkbox"/> Non-Negative	<input type="checkbox"/> Negative	<input checked="" type="checkbox"/> N/A
- MDMA	<input type="checkbox"/> Non-Negative	<input type="checkbox"/> Negative	<input checked="" type="checkbox"/> N/A
- 6-MAM	<input type="checkbox"/> Non-Negative	<input type="checkbox"/> Negative	<input checked="" type="checkbox"/> N/A
<b>BREATH ALCOHOL TEST</b>			
- Alcohol	<input type="checkbox"/> Non-Negative	<input checked="" type="checkbox"/> Negative	<input type="checkbox"/> N/A

Jakarta, January 10, 2022

  
**PT. KARTIKA BINA MEDIKATAMA**  
 ( dr. Petty Atmadja, Sp.PK )  
 Clinical Patologist

**PT. KARTIKA BINA MEDIKATAMA**

# HEALTH ASSESSMENT REPORT

*Of*

**SYAIFUL**  
**01031455**

**Monday, 10 January 2022**

## **MP BELTWAY CLINIC**

Beltway Office Park, Annex Building, Ground Floor

Jl. TB. Simatupang Kav.41, Jakarta Selatan 12550

Tlp : (62-21) 808 66 099, Fax : (62-21) 808 66 098

[www.medikaplaza.com](http://www.medikaplaza.com)



## MP BELTWAY CLINIC

Beltway Office Park, Annex Building, Ground Floor  
Jl. TB. Simatupang Kav.41, Jakarta Selatan 12550  
Tlp : (62-21) 808 66 099, Fax : (62-21) 808 66 098  
www.medikaplaza.com

### PATIENT DATA

MedRec.	: 01031455	EMPLOY. STATUS	: Employee
NAME	: SYAIFUL	BIRTHDATE	: 03 February 1983
EMPLOYEE No.	: -	SEX	: Male
JOB TITLE	: INSPECTOR	STATUS	: Married
COMP. NAME	: INSPEKTINDO SINERGI PERSADA, PT	NASIONALITY	: Indonesia

### SUMMARY

#### MEDICAL FINDING :

1. Hypertriglyceridemia with Fatty liver
2. Increase fasting blood sugar
3. Non reactive Anti HBs
4. Decreasing of visual acuity of both eyes
5. Abdominal USG : Multiple intraluminal cholelithiasis
6. Overweight
7. Calculus, stain, gangren pulpa, decayed, radix and missing teeth

Your fitness status is fit with medical note:

1. Hypertriglyceridemia
2. Abdominal USG : Multiple intraluminal cholelithiasis

#### SUGGESTION :

1. Low fat and carbohydrate diet, exercise regularly minimal 3 times a week. Consultation with an Internist for further evaluation of hypertriglyceridemia. Repeat abdominal USG 6 months later and consultation with an Internist to evaluate fatty liver
2. Low sugar diet and repeat blood glucose examination 1 month later. Consultation with an Internist if blood glucose still increase
3. Need to get Hepatitis B vaccination (booster)
4. You need to wear the glasses for distant vision
5. Consultation with an Internist for further evaluation of Abdominal USG : Multiple intraluminal cholelithiasis
6. Reduce body weight gradually 0.5 Kgs/week, by doing regular exercise (aerobic/jogging), 3-4x/week, 30-45 minutes and reduce high calorie diet until maximal body weight is 68.06 Kgs (present body weight is 71.1 Kgs). Consultation with a Nutritionist for evaluation of overweight
7. Consultation with a Dentist for dental care, minimal once a year or better once in six month

#### Responsible Doctor



Yosephine Smanungkalit, MD

#### Notes:

If you need the further information or consultation, please contact us via :

- Email : - beltway.doctor@medikaplaza.com  
- Rezkha.Amalia@medikaplaza.com  
- Puteri.Melati@medikaplaza.com

Telepon Klinik : (62-21) 8086 6099



## CLINICAL EVALUATION

Name : SYAIFUL	Sex : Male	MR : 01031455	Visit : 10/01/2022
Comp. : INSPEKTINDO SINERGI PERSADA, PT		DOB : 03 February 1983	

EXAMINATION	RESULT	NOTES
-------------	--------	-------

### ANAMNESIS

#### PRESENT COMPLAINT AND HISTORY OF PRESENT

#### ILLNESS

Present complaint

No complaint

#### MEDICAL HISTORY

Alergy	No
Imunisasi	Yes
Surgery	No
Hospitalization	No
Disease	No

#### LIFE STYLE

Alcohol intake	No
Smoking	Yes Mild smoker
Exercise	Yes Futsal, badminton 2x/week

#### FAMILY MEDICAL HISTORY

Diabetes Melitus	No
Hypertension	No
Heart disease	No
Lung TB	No
Kidney disease	No
Astma	No
Mental disease	No
Epilepsy	No
Cancer	No
Color blind	No
Stroke	No
Liver disease	No
Bone & joint	No
Others disease	No

#### WORK EXPOSURE

Noise	Yes	2010, using PPE
Heat Stress	No	
Cold Stress	No	
Vibration	Yes	2010
Involving height	No	
Radiation	No	
Dust	Yes	

## CLINICAL EVALUATION

Name : SYAIFUL	Sex : Male	MR : 01031455	Visit : 10/01/2022
Comp. : INSPEKTINDO SINERGI PERSADA, PT		DOB : 03 February 1983	

EXAMINATION	RESULT	NOTES
Toxic chemical	No	
Irritating fluid	No	
Smoke	No	
Bacterium/Virus/Parasite	No	
Blood	No	
Animal	No	
Operating heavy mobile equipment	No	
Manual Handling	No	
Sitting continuously over 4 hours	No	
Stand continuously over 4 hours	No	
Using monitor screen more than 4 hours per day	No	
Exposure	No	
Unergonomic body positions	No	
Shift work	No	12 hours/shift
Work is not accordance with skills and knowledge	No	
Workload does not accordance with time	No	
Work conflict	No	
Inappropriate task	No	
Career barriers	No	
Family conflict	No	
Working around rotating machinery	Yes	
Administration work	No	
Handling food product	No	
Others	Yes	Offshore/onshore
<b>PHYSICAL EXAMINATION</b>		
General Appearance	Good	
Body shape	Picnicus	
<b>VITAL SIGN</b>		
Body Weight	71.1 Kg	
Body Height	165 Cm	
BMI	26.11 Kg/m <sup>2</sup>	
Normal Weight	50.37 - 68.06 Kg	
BMI Conclusion	Overweight	
Blood Pressure	110/70 mmHg	
Pulse	69 x/minute	
Body Temperature	36.5 °C	
RR	18	

## CLINICAL EVALUATION

Name : SYAIFUL	Sex : Male	MR : 01031455	Visit : 10/01/2022
Comp. : INSPEKTINDO SINERGI PERSADA, PT		DOB : 03 February 1983	

EXAMINATION	RESULT	NOTES
Neck Circumference	34 Cm	
Arm Circumference	32 Cm	
Chest size	92 Cm	
Abdominal Circumference	91 Cm	
<b>SKIN</b>		
Skin	Normal	
<b>EYE</b>		
Left	Normal	
Right	Normal	
<b>ENT</b>		
Auricle	Normal	
Ear canal	Normal	
Drums	Normal	
Septum/Conchae	Not Examined	
Sinuses	Not Examined	
Pharynx	Not Examined	
Tonsil	Not Examined	
<b>MOUTH</b>		
Gum	Normal	
Dental	Abnormal	Calculus, stain, gangren pulpa, decayed, radix and missing teeth
<b>NECK</b>		
General	Normal	
Thyroid Gland	Normal	
<b>CHEST</b>		
Form	Normal	
Lung	Normal	
Heart	Normal	
Breast	Normal	
<b>ABDOMEN</b>		
Form	Flat	
Palpation	Supple	
Liver	Not Palpable	
Spleen	Not Palpable	
Kidney	No Ballotment	
-	No	
Hernia inguinal	No	



## CLINICAL EVALUATION

Name : SYAIFUL	Sex : Male	MR : 01031455	Visit : 10/01/2022
Comp.: INSPEKTINDO SINERGI PERSADA, PT		DOB : 03 February 1983	

EXAMINATION	RESULT	NOTES
<b>EXTRIMITIES</b>		
Bones,joint	Normal	
Muscles,tonus	Normal	
Fingernails	Normal	
Hand	Normal	
Foot	Normal	
<b>RECTAL EXAMINATION</b>		
Hemorrhoid	Negative	
Rectum	Not Examined	
<b>SENSORIK EXAMINATION</b>		
Tes Raba	Normal	
<b>MOTORIK EXAMINATION</b>		
Tes Grip	Normal	
<b>REFLEX EXAMINATION</b>		
Physiologic reflex	Normal	
Patologic reflex	Normal	
<b>OTHERS EXAMINATION</b>		
Coordination	Normal	
<b>LYMPHE SYSTEM</b>		
Submandibula	Normal	
Neck Gland	Normal	
Armpit gland	Normal	
Inguinal	Normal	
<b>MUSKULOSKLETAL EXAMINATION</b>		
Lhermitte Test	Negative	
Spurling Test	Negative	
Neers Test	Negative	
Yergason Test	Negative	
Phalen Test	Negative	
Tinel Test	Negative	
Finkelstein Test	Negative	
Straight Leg Raise Test	Negative	

## OPHTHALMOLOGY DIAGNOSTIC

Name : SYAIFUL		Sex : Male	MR : 01031455	Visit : 10/01/2022
Comp. : INSPEKTINDO SINERGI PERSADA, PT			DOB : 03 February 1983	
EXAMINATION		Right	Left	
Reading		-		
Previous Glasses		-		
Without Glasses	Distant	20/30	20/30	
	Near	J1	J1	
Correction	Distant	S-0.50 C-0.50X90 20/20	S-0.50 C-0.75X90 20/20	
	Near	-	-	
Depth Perception		-		
Tonometry		18.0 mmHg	20.0 mmHg	
Funduscopy		NORMAL	NORMAL	
Visual Fields		Normal		
Colour Blind Test		Normal		

Impression : Astigmatismus myopicus kompositus ODS

## RADIOLOGY DIAGNOSTIC

Name : SYAIFUL

Sex : Male

MR : 01031455

Visit : 10/01/2022

Comp.: INSPEKTINDO SINERGI PERSADA, PT

DOB : 03 February 1983

### EXAMINATION

### RESULT

THORAX PA

No abnormality seen in both lungs.  
Normal bronchovascular markings in both hili.  
The heart is normal in size and shape.  
The mediastinum is not widened.  
Both sinus and diaphragms are good.  
No evidence of pleural effusion.

Impression

Normal heart and lungs.



## RADIOLOGY DIAGNOSTIC

Name : SYAIFUL	Sex : Male	MR : 01031455	Visit : 10/01/2022
Comp.: INSPEKTINDO SINERGI PERSADA, PT		DOB : 03 February 1983	

EXAMINATION	RESULT
-------------	--------

USG ABDOMEN

**LIVER:**  
Normal in size and contour, smooth surface, parenchyme echoes structures increased. No sign of SOL.  
Intrahepatic vascularity and billiary tract are normal.

**GALL BLADDER:**  
Normal in size, contour and surface. Multiple intraluminal hyperechoic lesions ( 2-3 mm in diameter ) with posterior acoustic shadow.

**BOTH KIDNEYS:**  
Normal in size, contour and surface. No sign of obstruction/ stone/ SOL.

**PANCREAS:**  
Normal in size, contour and surface. No sign of SOL.

**LIEN:**  
Normal in size and contour, the echoes are homogenous. No sign of SOL.

**URINARY BLADDER:**  
Normal in size, contour and surface. No sign of stone/ SOL.

**PROSTATE AND VESICULA SEMINALIS:**  
Normal in size and contour which are homogenous echoes and no sign of focal lesion/ SOL.

Impression

Fatty liver.  
Multiple intraluminal cholelithiasis.  
Other abdominal organs are normal.

Name : SYAIFUL  
 Comp.: INSPEKTINDO SINERGI PERSADA, PT  
 EXAMINATION

LAB NO: 22000426  
 Nama :  
 Umur :  
 Alamat :  
 SYAIFUL  
 01081466 - L  
 03-02-88  
 INSPEKTINDO SINERGI PERSADA  
 GOL DARAH  
 A  
 Rh : +POS  
 anti : A  
 anti : B  
 anti : AB  
 anti : Rh

#Lab : IN768028254  
 983  
 RANGE

**HEMATOLOGI**

ABO/Rh Typing

**Automated Blood Count**

White Blood Cell (WBC)	10.5	3.8 - 11.0
Erythrocyte (RBC)	5.6	4.4 - 5.9
Haemoglobin	16.5	13.2 - 17.3
Hematocrit	49	40 - 52
Thrombocytes	381	150 - 440

**MCV, MCH, MCHC**

MCV	89	80 - 100
MCH	30	26 - 34
MCHC	33.5	32 - 36
ESR	14 *	0 - 10

**Differential Count**

Basophils	0	0 - 1
Eosinophil	2	2 - 4
Bands / Stab	3	3 - 5
Neutrophils	53	50 - 70
Lymphocytes	34	25 - 40
Monocytes	8	2 - 8

**BLD CHEMISTRY/LIPID PROFILE**

Total Cholesterol	145	Normal/Desireable: <200 Borderline High: 200-239 High: >=240
HDL Cholesterol	39.3 *	Normal : >40 - <60 Low HDL : <40 Desireable : >=60
LDL Cholesterol	59	Optimal: <100 Near/Above Optimal: 100-129 Borderline High: 130-159 High: 160-189 Very High: >=190
Triglycerides	235 *	Normal : <150 Borderline High: 150-199 High : 200-499 Very High : >=500

**BLD CHEMISTRY/KIDNEY FUNCTION**

## LABORATORY RESULT

Name : SYAIFUL	MR : 01031455	Visit : 10/01/2022	#Lab : IN7680282544
Comp. : INSPEKTINDO SINERGI PERSADA, PT	Sex : Male	DOB : 03 February 1983	

EXAMINATION	RESULT	NORMAL RANGE
Ureum	16.6	10.0 - 50.0
Creatinine	0.92	0.60 - 1.30
Uric Acid	7.73 *	3.50 - 7.20

### BLD CHEMISTRY/LIVER FUNCTION

Total Bilirubin	0.70	0.1 - 1.0
Direct Bilirubin	0.05	0.0 - 0.2
Indirect Bilirubin	0.65	0.0 - 0.8
SGOT(AST)	22	13 - 45
SGPT (ALT)	26	13 - 50
Alkaline Phosphatase	93	30 - 120
Gamma GT	28	0 - 50
Albumin	4.6	3.5 - 5.5
Globulin	2.30	2.3 - 3.5
Total Protein	6.9	6.6 - 8.7

### BLD CHEMISTRY/DIABETES

Glucose Fasting	109 *	< 100
Glucose Urine	Negative	Negative
Keton Urine	Negative	Negative

#### Blood Glucose 2 PP

Blood Sugar 2 Hours PP	109	< 140
Glucose Urine	Negative	Negative
Keton Urine	Negative	Negative

### SEROLOGI / IMUNOLOGI

HBsAg (Quantitative)	0.00	0.00 - 0.03
Anti Hbs (Quantitative)	0.1 *	>= 5.0

### TOXICOLOGY - DRUGS SCREENING

Methadone	Negative	Negative
Phencyclidine	Negative	Negative
THC/Marijuana	Negative	Negative
Amphetamine	Negative	Negative
Benzodiazepines	Negative	Negative
Opiat	Negative	Negative
Cocain	Negative	Negative
Metamphetamine	Negative	Negative
Alcohol	Negative	Negative

### URINALYSIS

#### Complete Urine Analysis



## LABORATORY RESULT

Name : SYAIFUL	MR : 01031455	Visit : 10/01/2022	#Lab : IN7680282544
Comp.: INSPEKTINDO SINERGI PERSADA, PT	Sex : Male	DOB : 03 February 1983	
EXAMINATION	RESULT	NORMAL RANGE	

### Macroscopic

Color	Light Yellow	
Turbidity	Clear	Clear
Specific Gravity	1.010	1.000 - 1.030
pH	5.5	4.5 - 8.0
Leucocyte	Negative	Negative
Glucose	Negative	Negative
Nitrit	Negative	Negative
Bilirubin	Negative	Negative
Blood	Negative	Negative
Urobilinogen	Normal	Normal
Protein	Negative	Negative
Keton	Negative	Negative

### Microscopic

RBC	0-1	0 - 1
WBC	0-1	0 - 4
Cylinder	Negative	
Epithels Squamous	0-1	5 - 15
Crystals	Negative	
Bacteria	Negative	Negative
Others	Negative	

## STOOL / RECTAL SWAP

### Faeces Complete

#### Macroscopic

Color	Brown	
Consistency	Smooth	
Mucus	Negative	Negative
Blood	Negative	Negative
Pus	Negative	Negative
Parasit	Negative	Negative
Lipid	Negative	Negative

#### Microscopic

RBC	0-1	0 - 1
WBC	0-1	0 - 5
Amoeba	Negative	
Ephitels	Positive	Positive
Worm Eggs	Negative	Negative

## LABORATORY RESULT

Name : SYAIFUL	MR : 01031455	Visit : 10/01/2022	#Lab : IN7680282544
Comp. : INSPEKTINDO SINERGI PERSADA, PT	Sex : Male	DOB : 03 February 1983	

EXAMINATION	RESULT	NORMAL RANGE
Yeast	Negative	Negative
Muscle Fiber	Negative	Negative
Others	Negative	Negative
<b>Digestive</b>		
Amylum	Negative	Negative
Fat	Negative	
Fibers	Positive	Positive

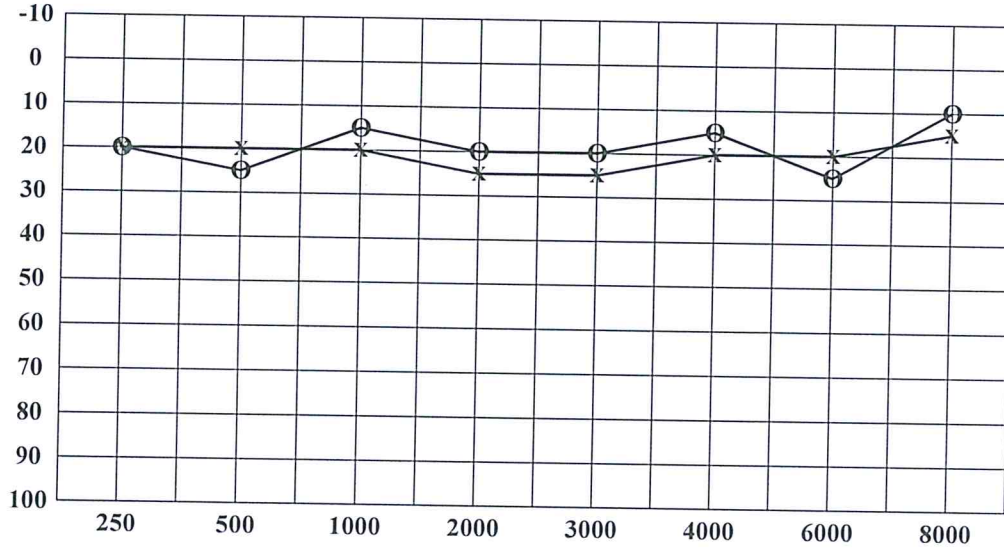
# AUDIOMETRY DIAGNOSTIC

Name : SYAIFUL	Sex : Male	MR : 01031455	Visit : 10/01/2022
Comp. : INSPEKTINDO SINERGI PERSADA, PT		DOB : 03 February 1983	

## RESULT

Left Ear	250	500	1000	2000	3000	4000	6000	8000
AC	20	20	20	25	25	20	20	15
BC	-	-	-	-	-	-	-	-

Right Ear	250	500	1000	2000	3000	4000	6000	8000
AC	20	25	15	20	20	15	25	10
BC	-	-	-	-	-	-	-	-



< : Right Ear (BC)  
 > : Left Ear (BC)  
  
 O : Right Ear (AC)  
 X : Left Ear (AC)

Conclusion Right Ear : Hearing threshold = 18.75 dB  
(Within normal limit)

Conclusion Left Ear : Hearing threshold = 21.25 dB  
(Within normal limit)



## CARDIOLOGY DIAGNOSTIC

Name : SYAIFUL	Sex : Male	MR : 01031455	Visit : 10/01/2022
Comp.: INSPEKTINDO SINERGI PERSADA, PT		DOB : 03 February 1983	

EXAMINATION	RESULT	Comments :
ELECTROCARDIOGRAPHY	Sinus Rythm axis ( N ), P wave ( N ), PR int 0.16" ST - T segment ( N ), aritmia (-)	Normal ECG
TREADMILL	Sinus Rythm axis ( N ), P wave ( N ), PR int 0.16" ST - T segment ( N ), aritmia (-)	Treadmill Exercise Test : Negative Cardiopulmonary Fitness Classification : Good METs : 13.3

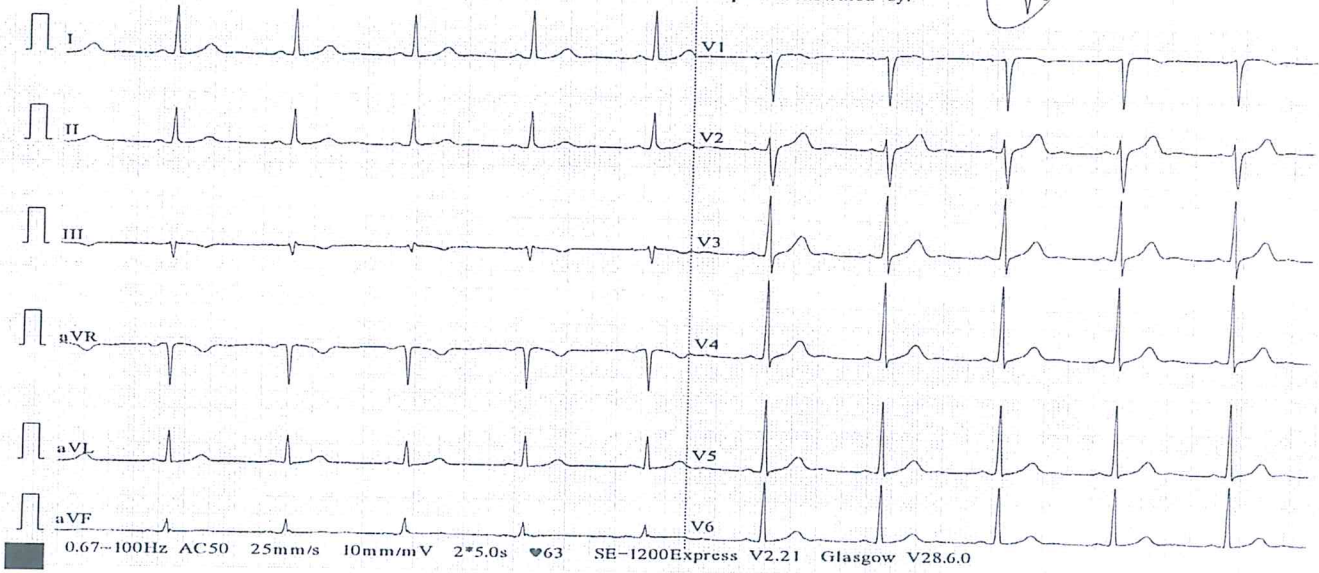
ID: 17  
SYAIFUL  
Male 38Years

File: Hollige-Mamm... 116-2201-06-22

10-01-2022 09:47:01  
HR : 63 bpm  
P : 104 ms  
PR : 140 ms  
QRS : 84 ms  
QT/QTc : 404/414 ms  
P/QRS/T : 21/21/9  
RV5/SV1 : 1.969/1.347 mV

Diagnosis Information:  
Sinus rhythm  
Normal ECG

Report Confirmed by:









**SYAIFUL MR**  
 Patient ID: 01031455  
 10.01.2022  
 10:02:51

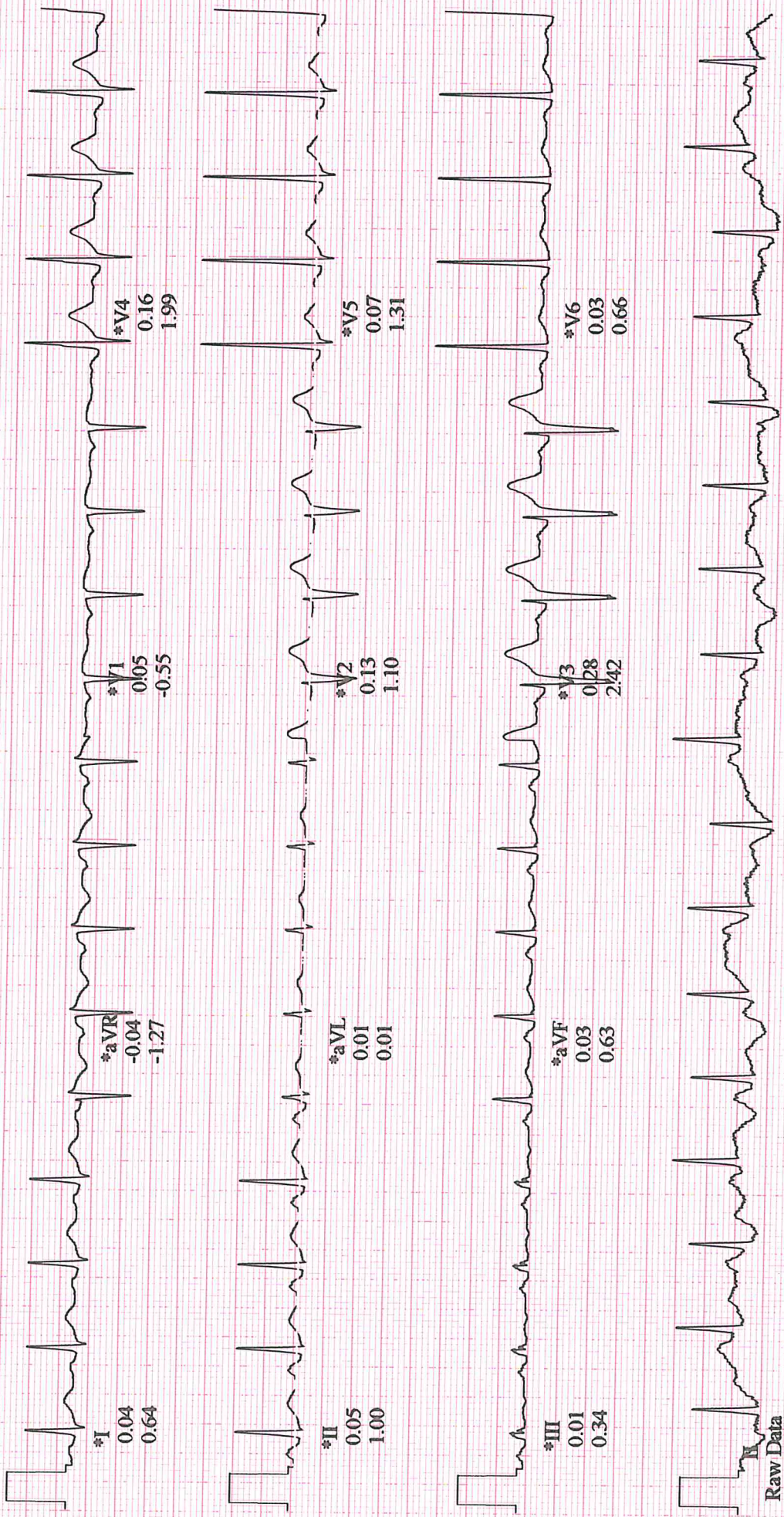
LINKED MEDIANS

MEDIKA PLAZA

EXERCISE  
 STAGE 1  
 02:50  
 104 bpm  
 110/70 mmHg

Lead  
 ST Level (mV)  
 ST Slope (mV/s)

60 ms post J



Raw Data

\*Computer Synthesized Rhythms



SYAIFUL MR  
Patient ID: 01031455  
10.01.2022  
10:05:51

LINKED MEDIANS

114 bpm  
130/90 mmHg

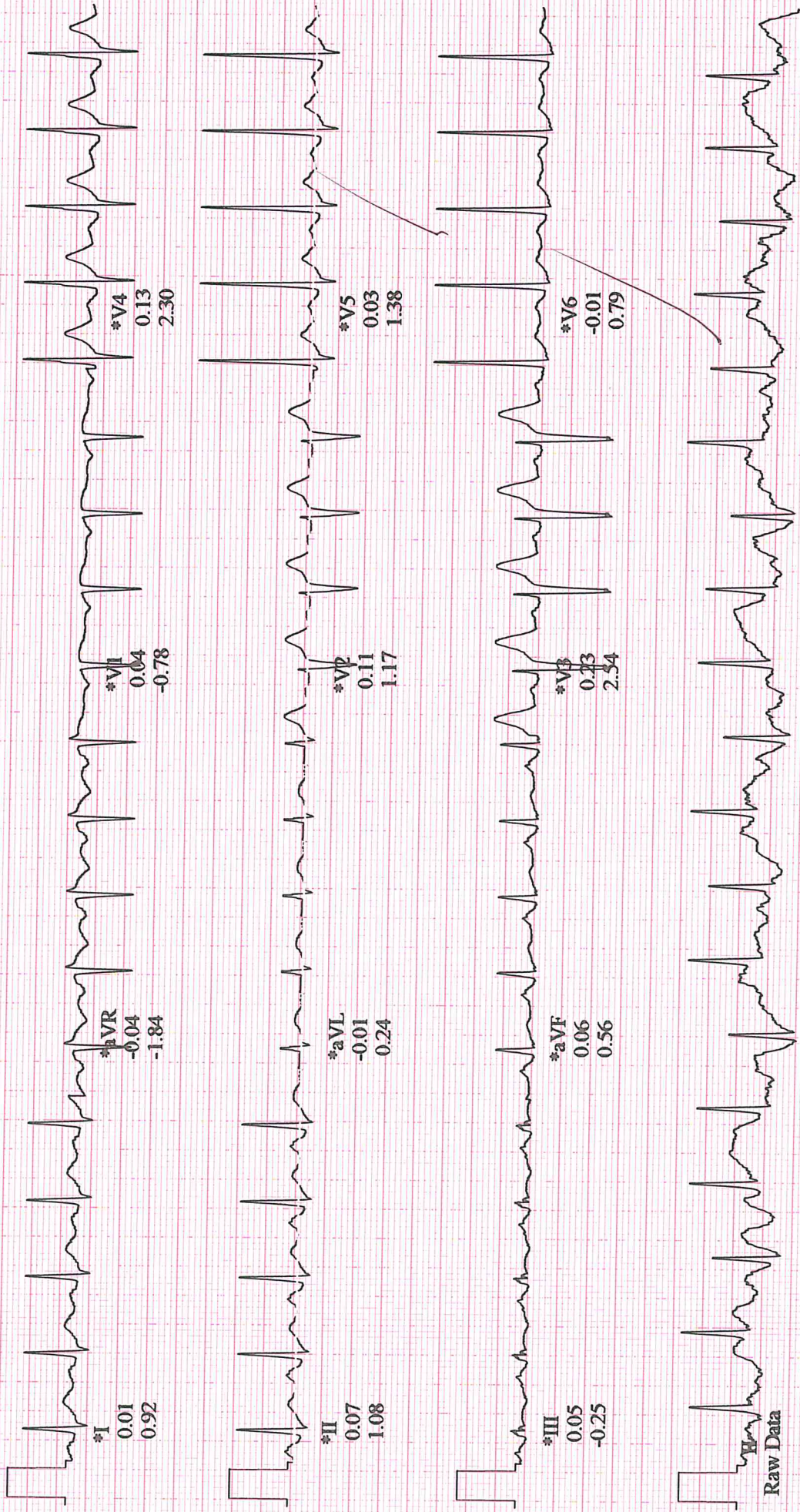
EXERCISE  
STAGE 2  
05:50

BRUCE  
4.0 km/h  
12.0%

MEDIKA PLAZA

Lead  
ST Level (mV)  
ST Slope (mV/s)

60 ms post-J



\*Computer Synthesized Rhythms



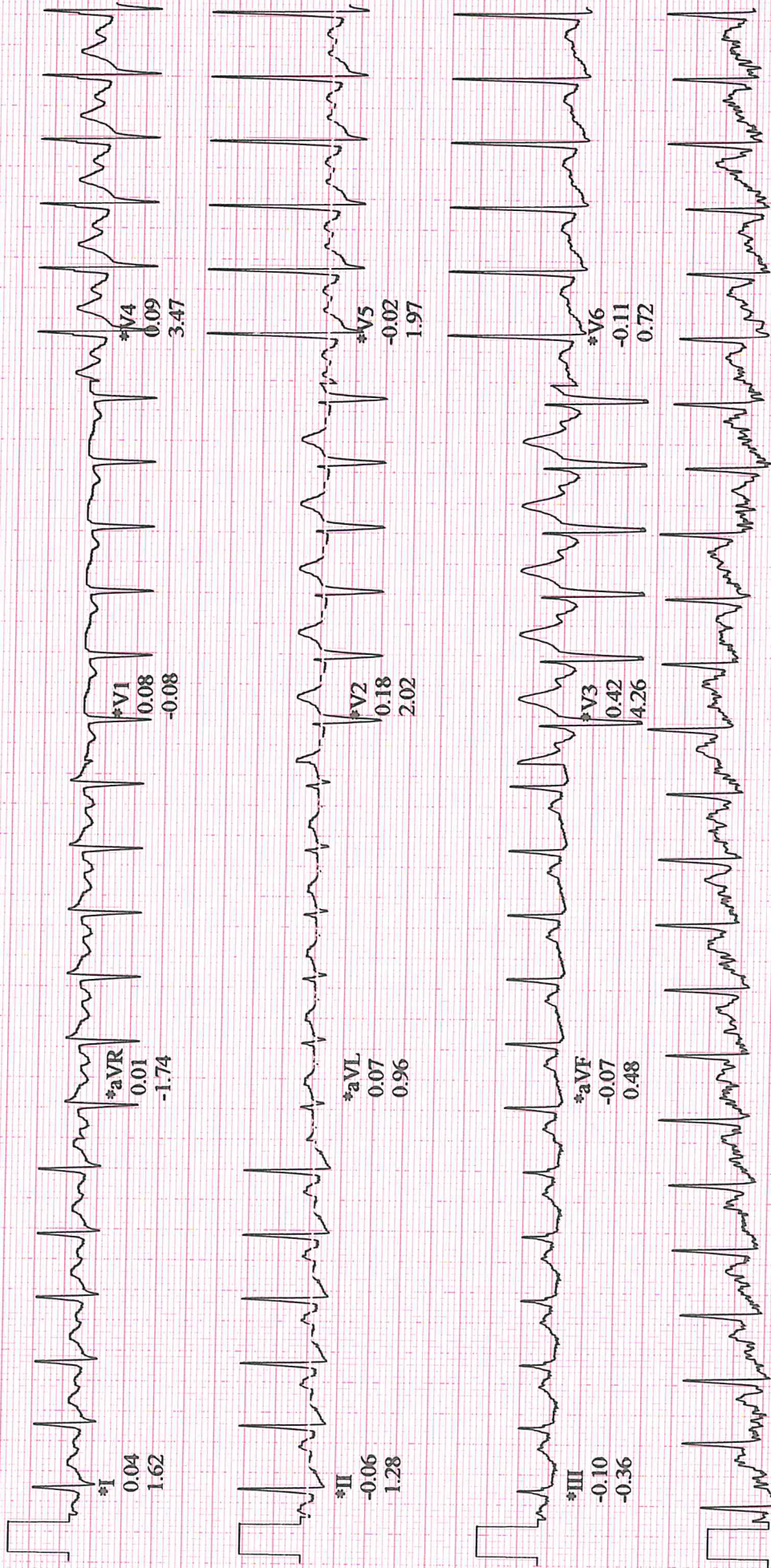
**SYAIFUL MR**  
 Patient ID: 01031455  
 10.01.2022  
 10:08:51

LINKED MEDIANS

**MEDIKA PLAZA**  
 EXERCISE  
 STAGE 3  
 08:50  
 141 bpm  
 140/90 mmHg

Lead  
 ST Level (mV)  
 ST Slope (mV/s)

60 ms post J



Raw Data

\*Computer Synthesized Rhythms



SYAIFUL MR  
Patient ID: 01031455  
10.01.2022  
10:09:59

LINKED MEDIANS (PEAK EXERCISE)

MEDIKA PLAZA

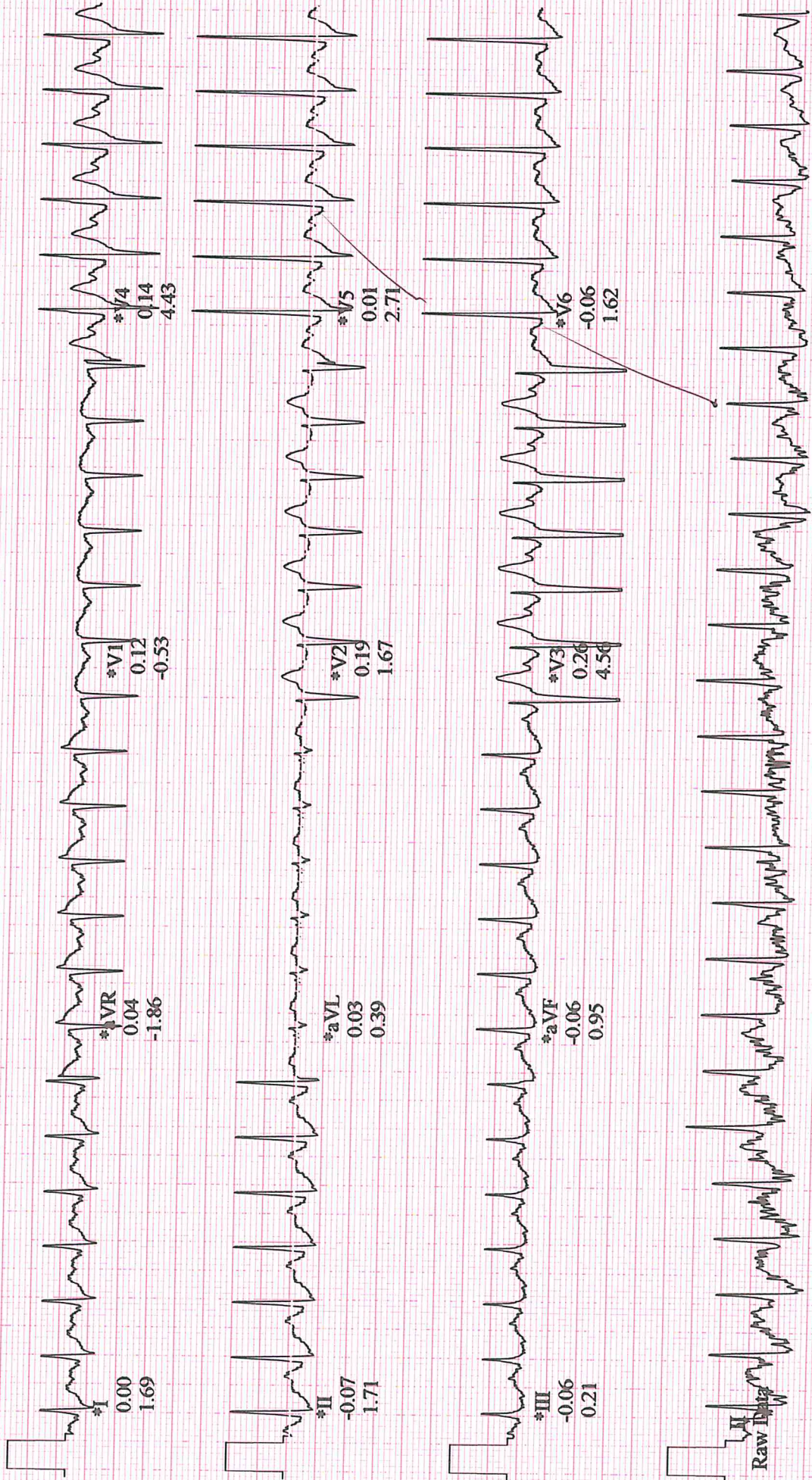
EXERCISE  
STAGE 4  
09:58

153 bpm

BRUCE  
6.8 km/h  
16.0 %

Lead  
ST Level (mV)  
ST Slope (mV/s)

60 ms post J



\*Computer Synthesized Rhythms



SYAIFUL MR  
Patient ID: 01031455  
10.01.2022  
10:10:18

LINKED MEDIANS

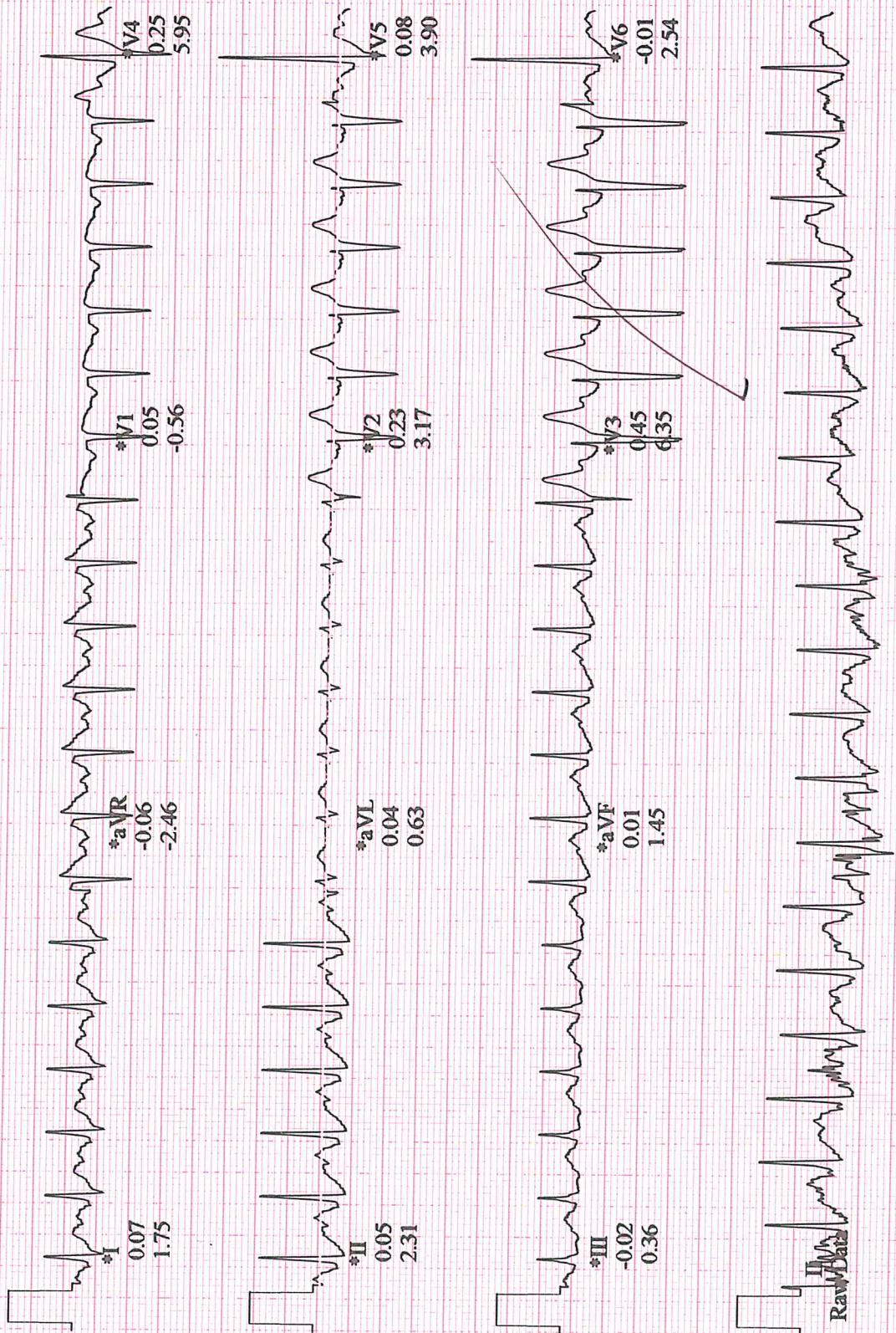
150 bpm

RECOVERY  
Recovery1  
00:20

LAJCE  
2.4 km/h  
0.0 %

MEDIKA

60 ms post J



\*Computer Synthesized R



SYAIFUL, MR  
 Patient ID: 01031455  
 10.01.2022 9:59:51

Male 165 cm 71.1 kg  
 38yrs Asian  
 Meds:

Test Reason:  
 Medical History:

Ref. MD: Ordering MD:  
 Technician: Nurse Test Type:  
 Comment:

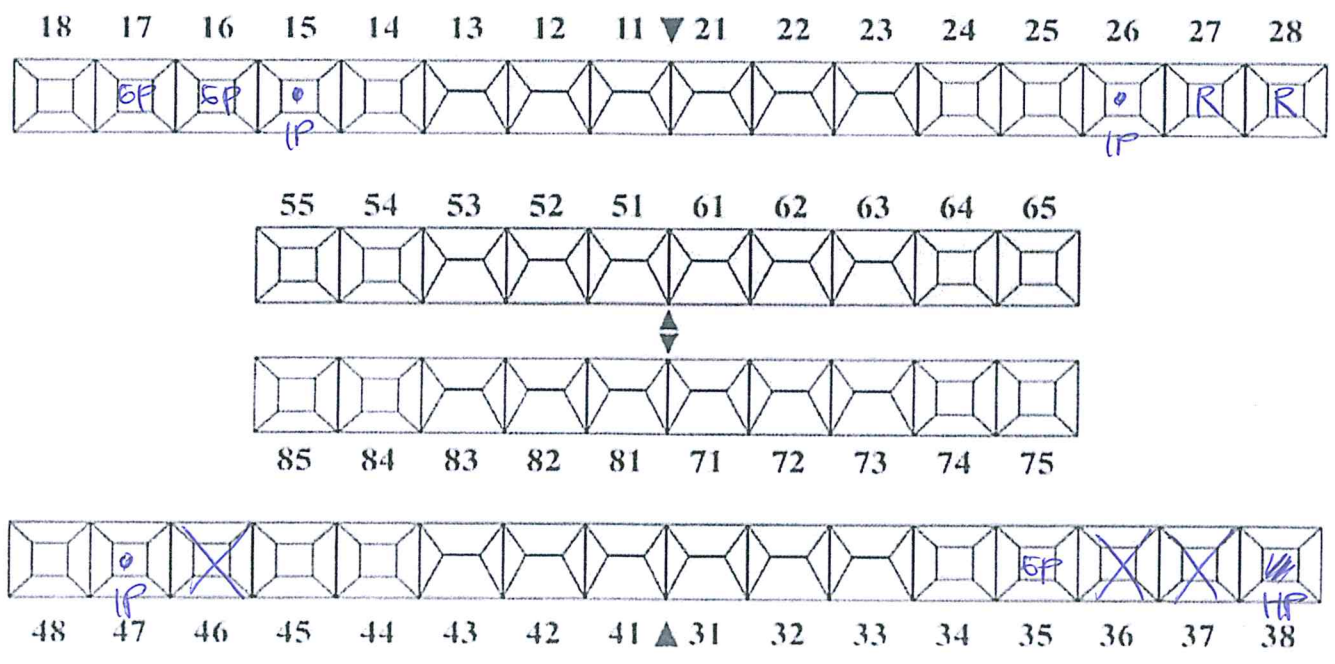
BRUCE: Total Exercise Time 09:57  
 Max HR: 155 bpm 85% of max predicted 182 bpm HR at rest: 71  
 Max BP: 140/90 mmHg BP at rest: 110/70 Max RPP: 18060 mmHg\*bpm  
 Maximum Workload: 13.30 METS  
 Max. ST: -0.11 mV, 0.00 mV/s in V6; EXERCISE STAGE 3 08:50  
 ST/HR index: 0.79  $\mu$ V/bpm  
 HR reserve used: 73 %  
 Freq. VE recovery: 0 VE/min  
 QRS duration: BASELINE: 82 ms, PEAK EX: 86 ms, REC: 86 ms  
 Location Number: \* 0 \*

Phase Name	Stage Name	Time in Stage	Speed (km/h)	Grade (%)	Workload (METS)	HR (bpm)	BP (mmHg)	RPP (mmHg*bpm)	VE (/min)	ST Level (V6 mV)	Comment
PRETEST	SUPINE	00:07	0.00	0.00	1.0		110/70		0	--	
	STANDING	00:02	0.00	0.00	1.0				0	--	
	HYPERV.	00:02	0.00	0.00	1.0				0	--	
	WARM-UP	00:04	0.00	0.00	1.0	71			0	0.03	
EXERCISE	STAGE 1	03:00	2.80	10.00	4.7	102	110/70	11220	0	0.02	
	STAGE 2	03:00	4.00	12.00	7.0	120	130/90	15600	0	-0.01	
	STAGE 3	03:00	5.50	14.00	10.2	141	140/90	19740	0	0.05	
	STAGE 4	00:58	6.80	16.00	13.3	153			0	-0.06	
RECOVERY	Recovery1	00:30	2.40	0.00	7.7	146			0	0.01	

*[Signature]*  
 PT. KARTIKA BINA MEDIKATAMA



DENTAL EXAMINATION			
Name : Syaiful	Sex : M / F	MR :	Visit : 10/22
Comp. : Inspektindo Sinergi		DOB : .....	
ODONTOGRAM			



DIAGNOSA

Calculus +2 dan stain +1  
 .....  
 16, 17, 35 = GP  
 .....  
 15, 26, 38, 47 = caries  
 .....  
 26, 28 = radix  
 .....  
 36, 37, 46 = missing

TREATMENT PLANNING

scaling all reff  
 .....  
 16, 17, 35 = exo  
 .....  
 15, 26, 38, 47 = filling  
 .....  
 26, 27 = exo  
 .....  
 36, 37, 46 = protesa

Verified by: drg. Ilona Amalia/ drg. Fajar Sulawati/ drg. Siti Darjah/ drg. Herlina

**PATIENT NAME** : Tn. Syaiful  
**No. RM** : 01031453  
**Clinik/MCU/HCU** : Co. ENT

To. Dokter :  
(Counsel)

Kindly please counsel for patient who has take cares of

Diagnose :  
Clinik Summary :

Counsel Request :

Ear : tympanic intact, post perforated. Ear eae  
**COUNSEL ADVISE** Mx: Ear ehyg, Seante. sems, Sephadriak.  
Finding : That = T, T, I, no hyperemic  
Ardianuly : Heavy discharge within and lint.

Diagnosis :

Rhinis, Septu deviated

Recomendation :

- Stop smoking
- Avoid Heavy

Date : 10 Januari 2012  
Time :  
EP :

Head set for lay period  
High Intensity  
- nasal washing

Signature  
dr. MERISTIANA CHRISTIANE, Sp.THT-KL  
SIP: 1375.155/31.74.04/1.779.319013

**MP+**  
Complete Name

PT. KARTIKA BINA MEDIKATAMA

Formulir Number : FM - DR - 008 - 02  
Revisi Number : 00  
Date : 07 Juli 2017