

## Certificate Of Health Assessment

Name	Age	Position	Department
AGUNG PUTRA LAKSONO	26 yo	PROJECT ADMINISTRATOR	-

**COMPANY :**

**INSPEKTINDO SINERGI PERSADA, PT**

### CONCLUSION



**FIT TO WORK**

✓

**FIT WITH MEDICAL NOTE**

**TEMPORARY UNFIT**

**UNFIT**

Issued Date	Doctors Name	Prepared By
05 March 2020	<b>Puteri Melati, MD</b> <i>PKTK : KEP.264/BINWASK3-PNK3/KK/VI/2019</i> <i>SIP : 23/B.15a/31.74.04.1004/-1.779.3/e/2019</i>	
Expired Date		Verified By
05 March 2021	<b>dr. Muhammad Ilyas, Sp.Ok</b> <i>SIP : 29/B.15b/31.74.04.1004.02.009.K.1/3/-1.779.3/e/2019</i>	 <b>PT. KARTIKA BINA MEDIKATAMA</b>

No. Formulir : FM-DR-008-05  
 No. Revisi : 00  
 Tanggal Terbit : 2 Mei 2011

Certificate Number : MP-BOP/1-20200305/122186  
 MCU Validity Check  
<https://mcu-validasi.medikaplaza.com>

**PT. KARTIKA BINA MEDIKATAMA**

# **HEALTH ASSESSMENT REPORT**

*Of*

**AGUNG PUTRA LAKSONO**

**01.00076375**

**Thursday, 05 March 2020**

## **MP BELTWAY CLINIC**

Beltway Office Park, Annex Building, Ground Floor

Jl. TB. Simatupang Kav.41, Jakarta Selatan 12550

Tlp : (62-21) 808 66 099, Fax : (62-21) 808 66 098

[www.medikaplaza.com](http://www.medikaplaza.com)

## MP BELTWAY CLINIC

Beltway Office Park, Annex Building, Ground Floor  
Jl. TB. Simatupang Kav.41, Jakarta Selatan 12550  
Tlp : (62-21) 808 66 099, Fax : (62-21) 808 66 098  
www.medikaplaza.com

### PATIENT DATA

MedRec.	: 01.00076375	EMPLOY. STATUS	: PreEmployee
NAME	: AGUNG PUTRA LAKSONO	BIRTHDATE	: 18 October 1993
EMPLOYEE No.	: -	SEX	: Male
JOB TITLE	: PROJECT ADMINISTRATOR	STATUS	: Single
COMP. NAME	: INSPEKTINDO SINERGI PERSADA, PT	NASIONALITY	: INDONESIA

### SUMMARY

#### MEDICAL FINDING :

Calculus, and impacted teeth  
Your fitness status is fit to work.

#### PERCEPTIONS OF EXPOSURE BY WORKERS :

- Administration work

#### SUGGESTION :

Consultation with a Dentist for dental care, minimal once a year or better once in six month

#### Responsible Doctor



Puteri Melati, MD

#### Notes:

If you need the further information or consultation, please contact us via :

Email : - beltway.doctor@medikaplaza.com  
- beltway.doctor2@medikaplaza.com  
Telepon Klinik : (62-21) 8086 6000

## CLINICAL EVALUATION

Name : AGUNG PUTRA LAKSONO	Sex : Male	MR : 01.00076375	Visit : 05/03/2020
Comp. : INSPEKTINDO SINERGI PERSADA, PT		DOB : 18 October 1993	
EXAMINATION	RESULT	NOTES	

### ANAMNESA

#### PRESENT COMPLAINT AND HISTORY OF PRESENT

#### ILLNESS

Present complaint

No complaint

#### MEDICAL HISTORY

Alergy	No
Imunisasi	Yes
Surgery	No
Hospitalization	No
Disease	No

#### LIFE STYLE

Alcohol intake	No	
Smoking	Yes	Mild smoker
Exercise	Yes	Running

#### FAMILY MEDICAL HISTORY

Diabetes Melitus	No
Hypertension	No
Heart disease	No
Lung TB	No
Kidney disease	No
Astma	No
Mental disease	No
Epilepsy	No
Cancer	No
Color blind	No
Stroke	No
Liver disease	No
Bone & joint	No
Others disease	No

#### WORK EXPOSURE

Noise	No
Heat Stress	No
Cold Stress	No
Vibration	No
Involving height	No
Radiation	No
Dust	No

## CLINICAL EVALUATION

Name : AGUNG PUTRA LAKSONO	Sex : Male	MR : 01.00076375	Visit : 05/03/2020
Comp.: INSPEKTINDO SINERGI PERSADA, PT		DOB : 18 October 1993	

EXAMINATION	RESULT	NOTES
Toxic chemical	No	
Irritating fluid	No	
Smoke	No	
Bacterium/Virus/Parasite	No	
Blood	No	
Animal	No	
Operating heavy mobile equipment	No	
Manual Handling	No	
Sitting continuously over 4 hours	No	
Stand continuously over 4 hours	No	
Using monitor screen more than 4 hours per day	No	
Exposure	No	
Unergonomic body positions	No	
Shift work	No	
Work is not accordance with skills and knowledge	No	
Workload does not accordance with time	No	
Work conflict	No	
Inappropriate task	No	
Career barriers	No	
Family conflict	No	
Working arround rotating machinery	No	
Administration work	Yes	
Handling food product	No	
Others	No	
<b>PHYSICAL EXAMINATION</b>		
General Appearance	Good	
Body shape	Athleticus	
<b>VITAL SIGN</b>		
Body Weight	56.7 Kg	
Body Height	165 Cm	
BMI	20.82 Kg/m2	
Normal Weight	50.37 - 68.06 Kg	
BMI Conclusion	Normal	
Blood Pressure	120/80 mmHg	
Pulse	98 x/minute	
Body Temperature	36.5 °C	
RR	18	

## CLINICAL EVALUATION

Name : AGUNG PUTRA LAKSONO	Sex : Male	MR : 01.00076375	Visit : 05/03/2020
Comp. : INSPEKTINDO SINERGI PERSADA, PT		DOB : 18 October 1993	

EXAMINATION	RESULT	NOTES
Neck Circumference	32 Cm	
Arm Circumference	26 Cm	
Chest size	79 Cm	
Abdominal Circumference	73 Cm	
<b>SKIN</b>		
Skin	Normal	
<b>EYE</b>		
Left	Normal	
Right	Normal	
<b>ENT</b>		
Auricle	Normal	
Ear canal	Normal	
Drums	Normal	
Septum/Conchae	Normal	
Sinuses	Normal	
Pharynx	Normal	
Tonsil	Normal	
<b>MOUTH</b>		
Gum	Normal	
Dental	Abnormal	Calculus, and impacted teeth
<b>NECK</b>		
General	Normal	
Thyroid Gland	Normal	
<b>CHEST</b>		
Form	Normal	
Lung	Normal	
Heart	Normal	
Breast	Normal	
<b>ABDOMEN</b>		
Form	Flat	
Palpation	Supple	
Liver	Not Palpable	
Spleen	Not Palpable	
Kidney	No Ballotment	
-	No	
Hernia inguinal	No	
<b>EXTRIMITIES</b>		

## CLINICAL EVALUATION

Name : AGUNG PUTRA LAKSONO

Sex : Male

MR : 01.00076375

Visit : 05/03/2020

Comp.: INSPEKTINDO SINERGI PERSADA, PT

DOB : 18 October 1993

EXAMINATION	RESULT	NOTES
Bones,joint	Normal	
Muscles,tonus	Normal	
Fingernails	Normal	
Hand	Normal	
Foot	Normal	
<b>RECTAL EXAMINATION</b>		
Hemorrhoid	Negative	
Rectum	Normal	
<b>SENSORIK EXAMINATION</b>		
Tes Raba	Normal	
<b>MOTORIK EXAMINATION</b>		
Tes Grip	Normal	
<b>REFLEX EXAMINATION</b>		
Physiologic reflex	Normal	
Patologic reflex	Normal	
<b>OTHERS EXAMINATION</b>		
Coordination	Normal	
<b>LYMPHE SYSTEM</b>		
Submandibula	Normal	
Neck Gland	Normal	
Armpit gland	Normal	
Inguinal	Normal	

## OPHTHALMOLOGY DIAGNOSTIC

Name : AGUNG PUTRA LAKSONO	Sex : Male	MR : 01.00076375	Visit : 05/03/2020
Comp.: INSPEKTINDO SINERGI PERSADA, PT		DOB : 18 October 1993	

EXAMINATION		Right	Left
Reading		-	
Previous Glasses		-	-
Without Glasses	Distant	20/20	20/20
	Near	J1	J1
Correction	Distant	-	-
	Near	-	-
Depth Perception		-	
Tonometry		16.0 mmHg	18.0 mmHg
Funduscopy		NORMAL	NORMAL
Visual Fields		Normal	
Colour Blind Test		Normal	

Impression :



## RADIOLOGY DIAGNOSTIC

Name : AGUNG PUTRA LAKSONO	Sex : Male	MR : 01.00076375	Visit : 05/03/2020
Comp. : INSPEKTINDO SINERGI PERSADA, PT	DOB : 18 October 1993		

### EXAMINATION

### RESULT

THORAX PA

No abnormality seen in both lungs.  
Normal bronchovascular markings in both hili.  
The heart is normal in size and shape.  
The mediastinum is not widened.  
Both sinus and diaphragms are good.  
No evidence of pleural effusion.

Impression

Normal chest.  
No evidence of specific process in both lungs.

## LABORATORY RESULT

Name : AGUNG PUTRA LAKSONO	MR : 01.00076375	Visit : 05/03/2020	#Lab : IN69752883918
Comp. : INSPEKTINDO SINERGI PERSADA, PT	Sex : Male	DOB : 18 October 1993	
EXAMINATION	RESULT	NORMAL RANGE	

### HEMATOLOGI

#### Automated Blood Count

White Blood Cell (WBC)	7.0	3.8 - 11.0
Erythrocyte (RBC)	5.2	4.4 - 5.9
Haemoglobin	15.6	13.2 - 17.3
Hematocrit	44	40 - 52
Thrombocytes	227	150 - 440

#### MCV, MCH, MCHC

MCV	85	80 - 100
MCH	30	26 - 34
MCHC	35.1	32 - 36
ESR	3	0 - 10

#### Differential Count

Basophils	1	0 - 1
Eosinophil	4	2 - 4
Bands / Stab	1 *	3 - 5
Neutrophils	60	50 - 70
Lymphocytes	26	25 - 40
Monocytes	8	2 - 8

### BLD CHEMISTRY/LIPID PROFILE

Total Cholesterol	141	Normal/Desireable: <200 Borderline High: 200-239 High: >=240
HDL Cholesterol	46.4	Normal : >40 - <60 Low HDL : <40 Desireable : >=60
LDL Cholesterol	82	Optimal: <100 Near/Above Optimal: 100-129 Borderline High: 130-159 High: 160-189 Very High: >=190
Triglycerides	65	Normal : <150 Borderline High: 150-199 High : 200-499 Very High : >=500

### BLD CHEMISTRY/KIDNEY FUNCTION

Ureum	12.1	10.0 - 50.0
-------	------	-------------

**LABORATORY RESULT**

Name : AGUNG PUTRA LAKSONO	MR : 01.00076375	Visit : 05/03/2020	#Lab : IN69752883918
Comp. : INSPEKTINDO SINERGI PERSADA, PT	Sex : Male	DOB : 18 October 1993	

EXAMINATION	RESULT	NORMAL RANGE
Creatinine	0.9	0.6- 1.3
Uric Acid	5.49	3.50 - 7.20

**BLD CHEMISTRY/LIVER FUNCTION**

SGOT(AST)	12 *	13 - 45
SGPT (ALT)	10 *	13 - 50

**BLD CHEMISTRY/DIABETES**

Glucose Fasting	88	< 100
Glucose Urine	Negative	Negative
Keton Urine	Negative	Negative

**URINALYSIS****Complete Urine Analysis****Macroscopic**

Color	Light Yellow	
Turbidity	Clear	Clear
Specific Gravity	1.012	1.000 - 1.030
pH	6.5	4.5 - 8.0
Leucocyte	Negative	Negative
Glucose	Negative	Negative
Nitrit	Negative	Negative
Bilirubin	Negative	Negative
Blood	Negative	Negative
Urobilinogen	Normal	Normal
Protein	Negative	Negative
Keton	Negative	Negative

**Microscopic**

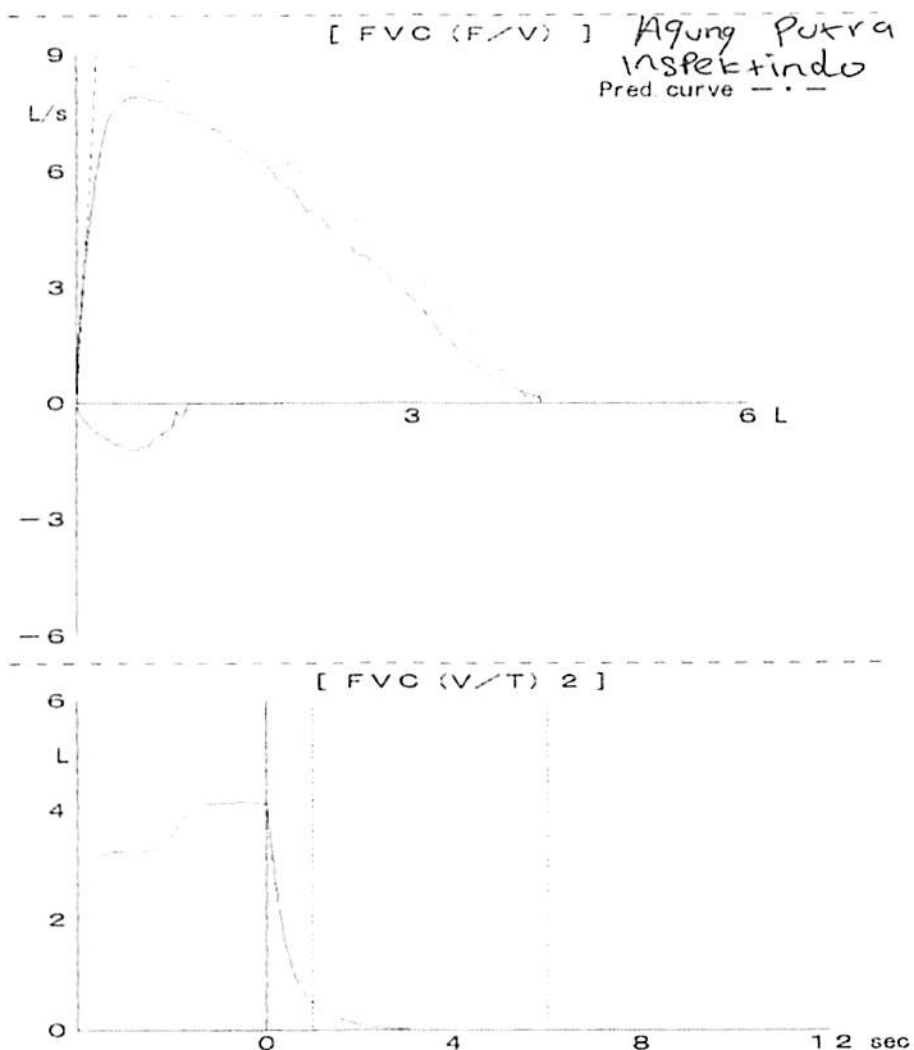
RBC	0-1	0 - 1
WBC	0-1	0 - 4
Cylinder	Negative	
Epithels Squamous	0-1	5 - 15
Crystals	Negative	
Bacteria	Negative	Negative
Others	Negative	

## SPIROMETRY DIAGNOSTIC

Name : AGUNG PUTRA LAKSONO	Sex : Male	MR : 01.00076375	Visit : 05/03/2020
Comp.: INSPEKTINDO SINERGI PERSADA, PT		DOB : 18 October 1993	

EXAMINATION	RESULT
FVC Result	: 4.16 L---> 102.0 %
FEV1 Result	: 3.66 L---> 95.8 %
FEV1/FVC Result	: 87.89 %---> 107.2 %
PEF Result	: 7.91 L/S---> 78.3 %
Indonesian Standart Result	:
Index	:
Spirometry Result	: Normal

Impression : Normal Spirometric Functions



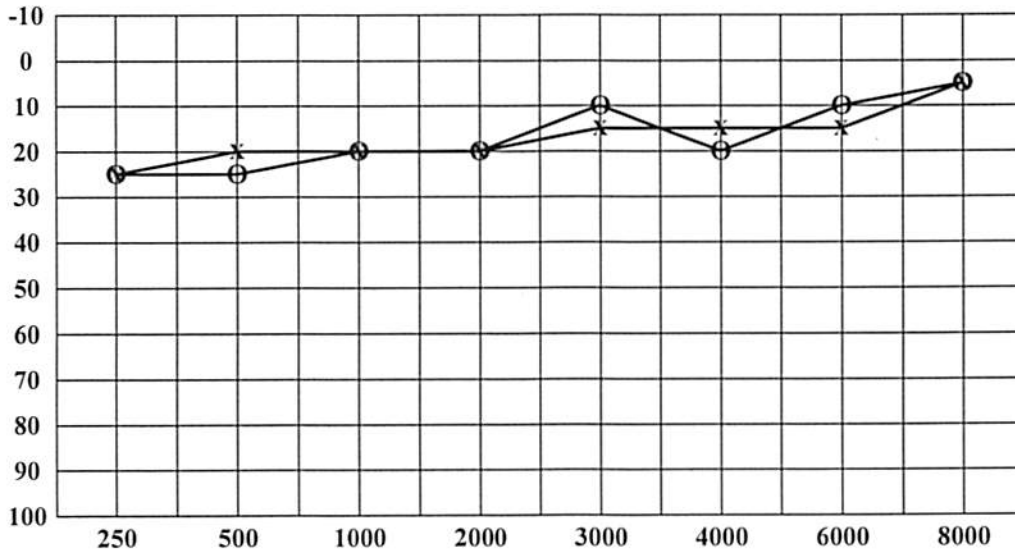
# AUDIOMETRY DIAGNOSTIC

Name : AGUNG PUTRA LAKSONO	Sex : Male	MR : 01.00076375	Visit : 05/03/2020
Comp. : INSPEKTINDO SINERGI PERSADA, PT		DOB : 18 October 1993	

## RESULT

Left Ear	250	500	1000	2000	3000	4000	6000	8000
AC	25	20	20	20	15	15	15	5
BC	-	-	-	-	-	-	-	-

Right Ear	250	500	1000	2000	3000	4000	6000	8000
AC	25	25	20	20	10	20	10	5
BC	-	-	-	-	-	-	-	-



< : Right Ear (BC)  
 > : Left Ear (BC)  
  
 O : Right Ear (AC)  
 X : Left Ear (AC)

Conclusion Right Ear : Hearing threshold = 21.25 dB  
(Within normal limit)

Conclusion Left Ear : Hearing threshold = 18.75 dB  
(Within normal limit)

# CARDIOLOGY DIAGNOSTIC

Name : AGUNG PUTRA LAKSONO      Sex : Male      MR : 01.00076375      Visit : 05/03/2020  
Comp. : INSPEKTINDO SINERGI PERSADA, PT      DOB : 18 October 1993

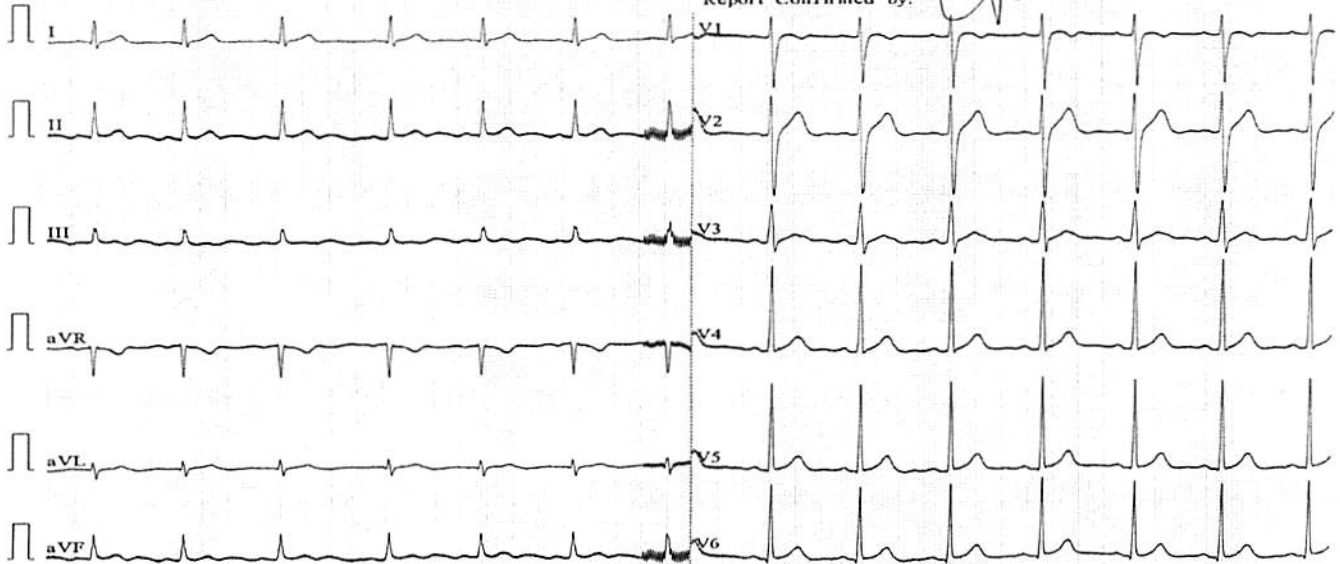
EXAMINATION	RESULT	Comments :
ELECTROCARDIOGRAPHY	Sinus Rythm axis ( N ), P wave ( N ), PR int 0.16" ST - T segment ( N ), aritmia (-)	Normal ECG

ID: 23  
AGUNG PUTRA  
Male 26Years

05-03-2020 10:25:58  
HR : 82 bpm  
P : 106 ms  
PR : 146 ms  
QRS : 100 ms  
QT/QTc : 354/414 ms  
P/QRS/T : 49/57/37  
RV5/SV1 : 2.446/1.415 mV

Diagnosis Information:  
Sinus arrhythmia  
Normal ECG

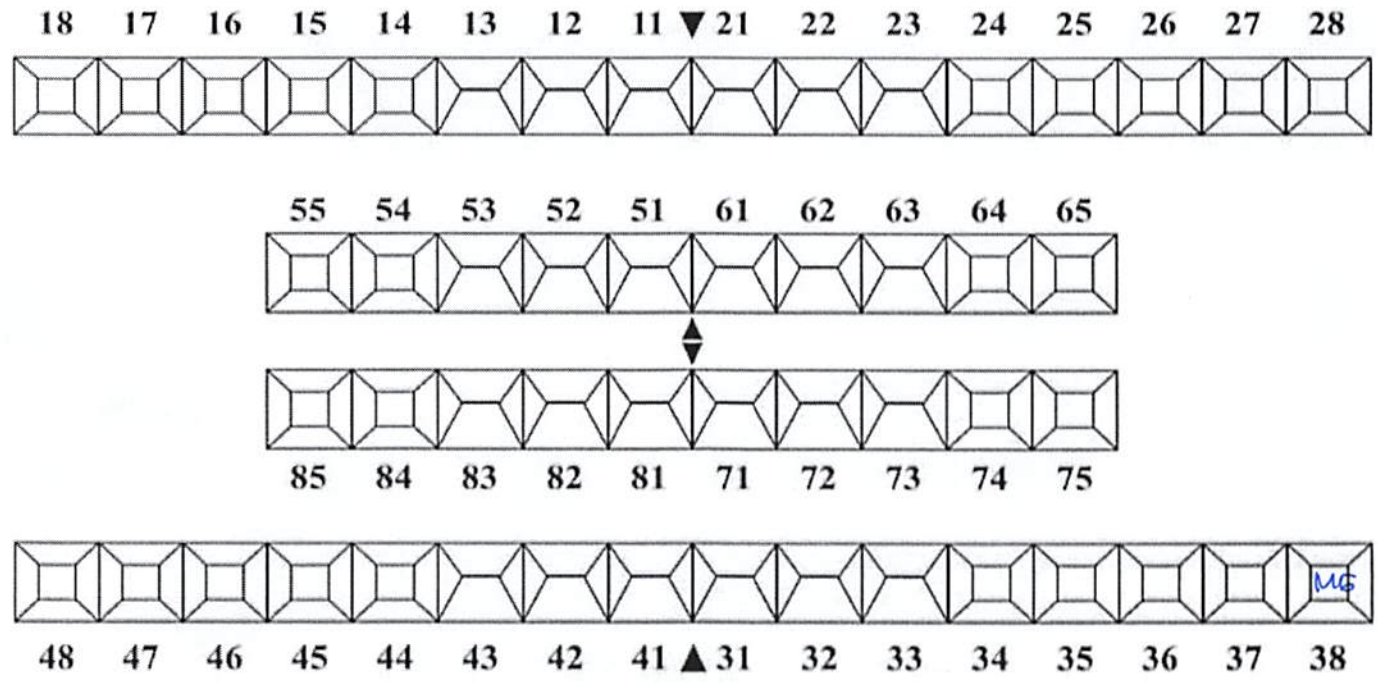
Report Confirmed by:



0.67-100Hz AC50 25mm/s 10mm/mV 2\*5.0s ♡82 SE-1200Express V2.21 Glasgow V28.6.0

### DENTAL EXAMINATION

Name : <i>Asung putra Laksono</i>	Sex : M / F	MR :	Visit :
Comp. : <i>Inspektindo Sinergi Persada</i>		DOB : .....	
ODONTOGRAM			



*calculus +*

#### DIAGNOSA

*OH baik*

*Gingivitis marginalis kronis*

*Impaksi 38*

#### TREATMENT PLANNING

*Pro Scaling PA RB*

*Pro Odontektomi 38*

Verified by: drg. Ilona Amalia/drg. Fajar Sulawati/drg. Siti Darjah/drg. Herlina

*Ilona Amalia* 5/3  
*Fajar Sulawati* 1/20