

CERTIFICATE OF HEALTH ASSESSMENT

TAMBOK PARSAULIAN NAPITUPULU
 INSPEKTINDO SINERGI PERSADA, PT

48 yo
 OTHER



Fit with Medical Note

CONCLUSION

Issued Date	Doctor Name	Prepared by
-------------	-------------	-------------

09 January
 2023

dr. Anastasia Febrianti

PKTK : 5/3738/AS.01.04/1V/2022

SIP: 26/B.15A/31.74.04.1004.02.009.K.1b/4/-1.779.3/e/2021

Expired Date	Doctor Name	Verified by
--------------	-------------	-------------

09 January
 2024

dr. Muhammad Ilyas, Sp.Ok

SIP: 29/B.15b/31.74.04.1004.02.009.K.1/3/-1.779.3/e/2019

No. Formulir : FM-DR-008-05
 No. Revisi : 00
 Tanggal Terbit : 2 Mei 2011

Patient Name	: TAMBOK PARSAULIAN NAPITUPULU	Clinic	: CLINIC BELTWAY OFFICE PARK
Medical Record No.	: 1022000690	Printed by	: Arlyn

HELPLINE
 24 / 7 **1500 918**

TO WHOM IT MAY CONCERN

Kepada yang berkepentingan

This is certify that today : Monday, 09 January 2023, Medika Plaza Clinic has performed urine drug screening and/or breath alcohol test to :

Dengan ini menyatakan bahwa, pada hari ini : Monday, 09 January 2023, Medika Plaza Clinic telah melakukan urine drug screening dan/atau breath alcohol test kepada :

TAMBOK PARSAULIAN NAPITUPULU

With the results are as follows :

Dengan hasil sebagai berikut :

<u>Drug Test</u> Uji Obat	<u>Result</u> Hasil
URINE DRUGS SCREENING	
- Amphetamine	<input type="checkbox"/> Non - Negative <input checked="" type="checkbox"/> Negative <input type="checkbox"/> N/A
- Met-Amphetamine	<input type="checkbox"/> Non - Negative <input checked="" type="checkbox"/> Negative <input type="checkbox"/> N/A
- Cocain	<input type="checkbox"/> Non - Negative <input checked="" type="checkbox"/> Negative <input type="checkbox"/> N/A
- THC/Canabis/Marijuana	<input type="checkbox"/> Non - Negative <input checked="" type="checkbox"/> Negative <input type="checkbox"/> N/A
- Morphine/Opiates	<input type="checkbox"/> Non - Negative <input checked="" type="checkbox"/> Negative <input type="checkbox"/> N/A
- P C P/Phencyclidine	<input type="checkbox"/> Non - Negative <input checked="" type="checkbox"/> Negative <input type="checkbox"/> N/A
- Barbiturate	<input type="checkbox"/> Non - Negative <input type="checkbox"/> Negative <input checked="" type="checkbox"/> N/A
- Benzodiazepin	<input type="checkbox"/> Non - Negative <input checked="" type="checkbox"/> Negative <input type="checkbox"/> N/A
- Methadone	<input type="checkbox"/> Non - Negative <input checked="" type="checkbox"/> Negative <input type="checkbox"/> N/A
- Propoxyphene	<input type="checkbox"/> Non - Negative <input type="checkbox"/> Negative <input checked="" type="checkbox"/> N/A
- Oxycodone	<input type="checkbox"/> Non - Negative <input type="checkbox"/> Negative <input checked="" type="checkbox"/> N/A
- MDMA	<input type="checkbox"/> Non - Negative <input type="checkbox"/> Negative <input checked="" type="checkbox"/> N/A
- 6-MAM	<input type="checkbox"/> Non - Negative <input type="checkbox"/> Negative <input checked="" type="checkbox"/> N/A
BREATH ALCOHOL TEST	
- Alcohol	<input type="checkbox"/> Non - Negative <input checked="" type="checkbox"/> Negative <input type="checkbox"/> N/A

Jakarta Selatan, January 09, 2023


MP+
 dr. Petty Atmadja, Sp.PK
 PT. KARTIKA BINA MEDIKATAMA

Clinical Patologist

Patient Name	: TAMBOK PARSAULIAN NAPITUPULU	Clinic	: CLINIC BELTWAY OFFICE PARK
Medical Record No.	: 1022000690	Printed by	: Arlyn

HELPLINE **1500 918**
 24 / 7

HEALTH ASSESSMENT REPORT

TAMBOK PARSAULIAN NAPITUPULU

1022000690

Monday, 09 January 2023

Noted:

- Medical Record is Private Document
- The results showing the health status base on the assessment on the date of incoming
- The patient had been signing a inform consent form before the examination

CLINIC BELTWAY OFFICE PARK

Beltway Office Park, ANNEX BUILDING, Ground Floor, Jl. TB Simatupang No.Kav. 41, RT.7/RW.2
Jakarta Selatan Jakarta Indonesia 12550 Tlp.:(62-21) 8086 6099

www.medikapla.com

No. Formulir : FM-DR-008-05
No. Revisi : 00
Tanggal Terbit : 2 Mei 2011

Patient Name	: TAMBOK PARSAULIAN NAPITUPULU	Clinic	: CLINIC BELTWAY OFFICE PARK
Medical Record No.	: 1022000690	Printed by	: Arlyn

HELPLINE **1500 918**
24/7

PATIENT DATA

Medical Record No. :	1022000690	Place of Birth :	JAKARTA
Name :	TAMBOK PARSAULIAN NAPITUPULU	Birthday :	27 July 1974
Employee No. :	-	Sex :	Male
Job Title :	INSPECTOR	Status :	Married
Company Name :	INSPEKTINDO SINERGI PERSADA, PT	Nationality :	WNI
Employee Status :	Active		

SUMMARY

MEDICAL FINDING

1. Dyslipidemia
2. Increase Creatinine level
3. Increase Gamma GT level
4. Non reactive Anti Hbs
5. Proteinuria (trace)
6. Decreasing of visual acuity of both eyes
7. Spirometry : Mild Obstructive
8. Chest x-ray : Elongated aorta
9. Abdominal USG : Multiple cholesterosis
10. Overweight
11. Calculus, stain, missing and radix teeth

Your fitness status is fit with medical note:

1. Dyslipidemia
2. Abdominal USG : Multiple cholesterosis

WORK EXPOSURE

1. Noise
2. Vibration
3. Dust
4. Other Disease

SUGGESTION

1. Low fat and carbohydrate diet and exercise regularly minimal 3 times a week. Consultation with an Internist for further evaluation of dyslipidemia
2. Repeat Creatinine level examination after 1 month and consultation with an Internist if still increase
3. Take enough rest minimal 8 hours/day. Repeat Gamma GT level examination 1 month later and consult to an Internist if still increase
4. Need to get Hepatitis B vaccination (booster)
5. Drink more water at least 2lt/day (8-10 glasses/day). Repeat urinalysis after 2 weeks
6. You need to wear the glasses for both vision
7. Avoid dust and fumes and use face mask while working at dusty area. Consult to a Pulmonologist if any complaint of spirometry result
8. Consultation with a Cardiologist if any complaint of Chest x-ray : Elongated aorta
9. Consultation with an Internist for further evaluation of Abdominal USG : Multiple cholesterosis
10. Reduce body weight gradually 0.5 Kgs/week, by doing regular exercise (aerobic/jogging), 3-4x/week, 30-45 minutes and reduce high calorie diet until maximal body weight is 73.93 Kgs (present body weight is 83.70 Kgs). Consultation with a Nutritionist for evaluation of overweight
11. Consultation with a Dentist for dental care, minimal once a year or better once in six month

Notes :

Responsible Doctor

Patient Name	: TAMBOK PARSAULIAN NAPITUPULU	Clinic	: CLINIC BELTWAY OFFICE PARK
Medical Record No.	: 1022000690	Printed by	: Arlyn

HELPLINE **1500 918**
 24 / 7

If you need the further information or
consultation, please contact us via Email
- Enjelita@medikaplaza.com
- Rezkha.Amalia@medikaplaza.com
Clinic Phone : (62-21) 8086 6099



dr. Anastasia Febrianti

Patient Name	: TAMBOK PARSAULIAN NAPITUPULU	Clinic	: CLINIC BELTWAY OFFICE PARK
Medical Record No.	: 1022000690	Printed by	: Arlyn

HELPLINE **1500 918**
24 / 7

CHEMICAL

Dust
 Toxic Chemical
 Irritating Fluid
 Heat Stress

Yes
 No
 No
 No

BIOLOGY

Bacterium/Virus/Parasite
 Blood
 Animal

No
 No
 No

ERGONOMICS

Operating Heavy Mobile Equipment
 Manual Handling
 Sitting Continuously Over 4 Hours
 Stand Continuously Over 4 Hours
 Menggunakan Layar Monitor > 4 Jam/Hari
 Exposure
 Posisi Tubuh Tidak Ergonomi

No
 No
 No
 No
 No
 No

PSYCHOLOGY

Shift Work
 Pekerjaan Tidak Sesuai Pengetahuan dan Keterampilan
 Beban Kerja Tidak Sesuai Waktu
 Konflik Kerja
 Ketidakjelasan Tugas
 Hambatan Jenjang Karir
 Konflik Keluarga

No
 No
 No
 No
 No
 No

OTHER

Working Arround Rotating Machinery
 Administration Work
 Handling Food product
 Other Disease

No
 No
 No
 Yes

Onshore/offshore

Patient Name	: TAMBOK PARSAULIAN NAPITUPULU	Clinic	: CLINIC BELTWAY OFFICE PARK
Medical Record No.	: 1022000690	Printed by	: Arlyn

HELPLINE 24/7 **1500 918**

Form	Normal	
LUNG		
Inspection	Normal	
Palpation	Normal	
Percussion	Normal	
Auscultation	Normal	
HEART		
Inspection	Normal	
Palpation	Normal	
Percussion	Normal	
Auscultation	Normal	
BREAST		
Inspection	Not Examined	
Palpation	Not Examined	
Percussion	Not Examined	
Auscultation	Not Examined	
ABDOMEN		
Form	Flat	
Palpation	Supel	
Liver	Not Palpable	
Spleen	Not Palpable	
Kidney	Not Ballotment	
HERNIA		
Inspection	Not Exist	
Palpation	Not Exist	
Percussion	Not Examined	
Auscultation	Not Examined	
EXTRIMITIES		
Bones, Joint	Normal	
Muscles, Tonus	Normal	
Fingernails	Normal	
Hand	Normal	
Foot	Normal	
RECTAL EXAMINATION		
Hemorrhoid	Not Exist	
Anus (Rectum)	Normal	Normal
MUSKULOSKLETAL EXAMINATION		
Lhermitte Test	Negative	
Spurling Test	Negative	
Neers Test	Negative	
Yergason Test	Negative	
Phalen Test	Negative	
Tinel Test	Negative	
Finklestein Test	Negative	
Straight Leg Raise Test	Negative	
SENSORIC EXAMINATION		
Tes Raba	Normal	
MOTORIC EXAMINATION		
Tes Grip	Normal	
REFLEX EXAMINATION		
Physiologic Reflex	Normal	
Patologic Reflex	Normal	

Patient Name	: TAMBOK PARSAULIAN NAPITUPULU	Clinic	: CLINIC BELTWAY OFFICE PARK
Medical Record No.	: 1022000690	Printed by	: Arlyn

OTHER EXAMINATION

Coordination Function

LYPHE SYSTEM

Submandibula

Neck Gland

Armpit Gland

Inguinal

Normal	
Normal	
Normal	
Not Examined	
Normal	

Patient Name	: TAMBOK PARSAULIAN NAPITUPULU	Clinic	: CLINIC BELTWAY OFFICE PARK
Medical Record No.	: 1022000690	Printed by	: Arlyn

HELPLINE **1500 918**
 24 / 7

OPHTHALMOLOGY DIAGNOSTIC

TAMBOK PARSAULIAN NAPITUPULU

INSPEKTINDO SINERGI PERSADA, PT
 MR : 1022000690

Male
 DOB : 27 July 1974

Visit : Monday, 09 January 2023

CLINICAL EVALUATION

VERIFIED BY

dr. Sandraningrum Tri Putranti, Sp.M

EXAMINATION	09 January 2023	
	RIGHT	LEFT
Reading		
Previous Glasses		
Without Glasses	Distant	20/30
	Near	J2
Correction	Distant	S-0.75 20/20
	Near	S+1.75 J1
Depth Perception		
Tonometri	19,00 mmHg	20,00 mmHg
Lensa	CLEAR	CLEAR
Funduscopy	NORMAL	NORMAL
Visual Fields	Normal	
Colour Blind Test	Normal	

Impression : Myopia simplex OD
 Astigmatism myopia simplex OS
 Presbyopia

Patient Name	: TAMBOK PARSAULIAN NAPITUPULU	Clinic	: CLINIC BELTWAY OFFICE PARK
Medical Record No.	: 1022000690	Printed by	: Aclyn

HELPLINE 1500 918
 24 / 7

THORAX DIAGNOSTIC

TAMBOK PARSAULIAN NAPITUPULU

INSPEKTINDO SINERGI PERSADA, PT
 MR : 1022000690

Male
 DOB : 27 July 1974

Visit : Monday, 09 January 2023

CLINICAL EVALUATION

VERIFIED BY

dr. Bulan Arini Eska, Sp.Rad (K) Tr

EXAMINATION

RESULTS
 09 January 2023

No abnormality seen in both lungs.
 Normal bronchovascular markings in both hili.
 The heart is normal in size and shape.
 Elongated aorta.
 The mediastinum is not widened.
 Both sinus and diaphragms are good.
 No evidence of pleural effusion.

Comments : Normal heart and lungs.
 Elongated aorta.

Patient Name	: TAMBOK PARSAULIAN NAPITUPULU	Clinic	: CLINIC BELTWAY OFFICE PARK
Medical Record No.	: 1022000690	Printed by	: Arlyn

HELPLINE **1500 918**
 24 / 7

ABDOMEN DIAGNOSTIC

TAMBOK PARSAULIAN NAPITUPULU

INSPEKTINDO SINERGI PERSADA, PT
 MR : 1022000690

Male
 DOB : 27 July 1974

Visit : Monday, 09 January 2023

CLINICAL EVALUATION

VERIFIED BY

dr. Ary Widia Atmoko, Sp.Rad

EXAMINATION

RESULTS
 09 January 2023

LIVER: Normal in size and contour, smooth surface, echoes structure parenchyme which are homogenous. No sign of SOL. Intrahepatic vascularity and biliary tract are normal.
 GALL BLADDER: Normal in size, contour and surface. There is hyperechoic lesion without posterior acoustic shadow, largest size +/- 0,19 cm.
 BOTH KIDNEYS: Normal in size, contour and surface. No sign of obstruction/ stone/ SOL.
 PANCREAS: Normal in size, contour and surface. No sign of SOL.
 LIEN: Normal in size and contour, the echoes are homogenous. No sign of SOL.
 URINARY BLADDER: Normal in contour and surface. No sign of stone/ SOL.
 PROSTATE AND VESICULA SEMINALIS: Normal in size and contour which are homogenous echoes and no sign of focal lesion/ SOL.

Comments : Multiple cholesterosis
 Other intrra abdominal organs are normal

Patient Name	: TAMBOK PARSAULIAN NAPITUPULU	Clinic	: CLINIC BELTWAY OFFICE PARK
Medical Record No.	: 1022000690	Printed by	: Arlyn

HELPLINE **1500 918**
 24 / 7

LABORATORY RESULTS

TAMBOK PARSAULIAN NAPITUPULU

INSPEKTINDO SINERGI PERSADA, PT
MR : 1022000690

Male
DOB : 27 July 1974

Visit : Monday, 09 January 2023

CLINICAL EVALUATION

VERIFIED BY

dr. Petty Atmadja, Sp.PK

HEMATOLOGI

ABO/Rh Typing

Automated Blood Count

White Blood Cell (WBC)

Erythrocyte (RBC)

Haemoglobin

Hematocrit

Thrombocytes

MCV, MCH, MCHC

MCV

MCH

MCHC

ESR

Differential Count

Basophils

Eosinophil

Neutrophils

Lymphocytes

Monocytes

BLD CHEMISTRY/LIPID PROFILE

Total Cholesterol

HDL Cholesterol

LDL Cholesterol

Triglycerides

BLD CHEMISTRY/KIDNEY FUNCTION

Ureum

Creatinine

Uric Acid

BLD CHEMISTRY/LIVER FUNCTION

RESULT 09 January 2023	NORMAL RANGE
"B" Rh(+) positive	
7.9	3.8 - 11.0 10 ³ /uL
4.8	4.4 - 5.9 10 ⁶ /uL
15.4	13.2 - 17.3 g/dL
44	40 - 52 %
259	150 - 440 10 ³ /uL
92	80 - 100 fL
32	26 - 34 pg
35.1	32 - 36 g/dL
15*	0 - 10 mm/hours
1	0 - 1 %
5*	2 - 4 %
47*	50 - 70 %
39	25 - 40 %
8	2 - 8 %
209*	Normal/Desireable: <200 Borderline High: 200-239 High: >=240 mg/dL
39.2*	Normal: >40 - <60 Low HDL: <40 Desireable: >=60 mg/dL
122	Optimal: <100 Near/Above Optimal: 100-129 Borderline High: 130-159 High: 160-189 Very High: >=190
241*	Normal: <150 Borderline High: 150-199 High: 200-499 Very High: >=500 mg/dL
27.2	10.0 - 50.0 mg/dL
1.37*	0.60 - 1.30 mg/dL
7.19	3.50 - 7.20 mg/dL

Patient Name	: TAMBOK PARSAULIAN NAPITUPULU	Clinic	: CLINIC BELTWAY OFFICE PARK
Medical Record No.	: 1022000690	Printed by	: Arlyn

HELPLINE **1500 918**
24 / 7

Total Bilirubin	0.90	0.1 - 1.0 mg/dL
Direct Bilirubin	0.17	0.0 - 0.2 mg/dL
Indirect Bilirubin	0.73	0.0 - 0.8
SGOT(AST)	18	13 - 45 IU/L
SGPT (ALT)	18	13 - 50 IU/L
Alkaline Phosphatase	108	30-120 U/L
Gamma GT	54*	0 - 50 U/L
Albumin	4.8	3.5 - 5.5 g/dL
Globulin	2.40	2.3 - 3.5
Total Protein	7.2	6.6-8.8 g/dL
BLD CHEMISTRY/DIABETES		
Fasting Glucose		
Glucose Fasting	80	< 100 mg/dL
Glucose Urine	Negative	Negative
Keton Urine	Negative	Negative
Blood Glucose 2 PP		
Blood Sugar 2 Hours PP	81	< 140 mg/dL
Glucose Urine	Negative	Negative
Keton Urine	Negative	Negative
SEROLOGI / IMUNOLOGI		
HBsAg (Profile)		
HBsAg (Quantitative)	0.00	0.00 - 0.03 IU/mL
Anti Hbs (Profile)		
Anti Hbs (Quantitative)	1.2*	>= 5.0 mIU/mL
VDRL		
	Negative	Negative
TOXICOLOGY - DRUGS SCREENING		
Methadone	Negative	Negative
Phencyclidine	Negative	Negative
THC/Marijuana	Negative	Negative
Amphetamine	Negative	Negative
Benzodiazepines	Negative	Negative
Opiat	Negative	Negative
Cocain	Negative	Negative
Metamphetamine	Negative	Negative
Alcohol	Negative	Negative
URINALYSIS		
Complete Urine Analysis		
Macroscopic		
Color	Yellow	
Turbidity	Clear	Clear
Specific Gravity	1.022	1.000 - 1.030
pH	5.5	4.5 - 8.0
Leucocyte	Negative	Negative
Glucose	Negative	Negative
Nitrit	Negative	Negative
Bilirubin	Negative	Negative
Blood	Negative	Negative
Urobilinogen	Normal	Normal
Protein	Trace	Negative
Keton	Negative	Negative
Microscopic		
RBC	0-1	0 - 1

Patient Name	: TAMBOK PARSAULIAN NAPITUPULU	Clinic	: CLINIC BELTWAY OFFICE PARK
Medical Record No.	: 1022000690	Printed by	: Arlyn

WBC	0-1	0-4
Cylinder	Negative	Negative
Epithels Squamous	0-1	5-15
Crystals	Negative	
Bacteria	Negative	Negative
Others	Negative	
STOOL / RECTAL SWAP		
Faeces Complete		
Macroscopic		
Color	Brown	
Consistency	Smooth	
Mucus	Negative	Negative
Blood	Negative	Negative
Pus	Negative	Negative
Parasit	Negative	Negative
Lipid	Negative	Negative
Microscopic		
RBC	0-1	0-1/HPF
WBC	0-1	0-5/HPF
Amoeba	Negative	
Ephitels	Positive	Positive
Worm Eggs	Negative	Negative
Yeast	Negative	Negative
Muscle Fiber	Negative	Negative
Others	Negative	Negative
Digestive		
Amylum	Negative	Negative
Fat	Negative	
Fibers	Positive	Positive

Notes : -

Patient Name	: TAMBOK PARSAULIAN NAPITUPULU	Clinic	: CLINIC BELTWAY OFFICE PARK
Medical Record No.	: 1022000690	Printed by	: Arlyn

HELPLINE **1500 918**
 24 / 7

SPIROMETRY RESULTS

TAMBOK PARSAULIAN NAPITUPULU

INSPEKTINDO SINERGI PERSADA, PT
 MR : 1022000690

Male
 DOB : 27 July 1974

Visit : Monday, 09 January 2023

CLINICAL EVALUATION

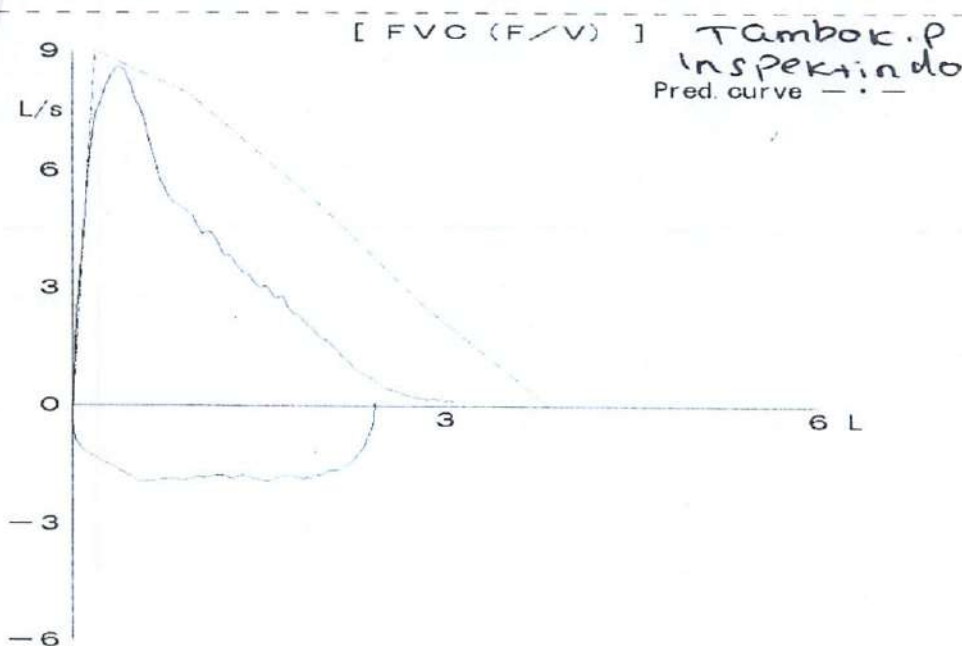
VERIFIED BY

dr. Temmasonge Radi Pakki, Sp.P

SPIROMETRY TEST - 09 January 2023		
FVC (Meas)	3,07L	80,20 %
FEV1	2,48L	74,50 %
FEV1/FVC	80,78 %	109,30 %
PEF	8,51 L/S	82,60 %
FVC Ind. Standart		
Index		
Impression	Mild Obstructive	
Suggestion	Exercise Regularly, Stop Smoking if you're smoking	
Conclusion	Abnormal / Tidak Normal	

[COPD CLASSIFICATION]

FEV1/FVC : 80.78 %
 %FEV1.0 : 74.50 %
 Stage : Normal
 Recommended treatment by GOLD



Patient Name	: TAMBOK PARSAULIAN NAPITUPULU	Clinic	: CLINIC BELTWAY OFFICE PARK
Medical Record No.	: 1022000690	Printed by	: Arlyn

HELPLINE **1500 918**
 24/7

THT CONSULTATION

TAMBOK PARSAULIAN NAPITUPULU

INSPEKTINDO SINERGI PERSADA, PT
 MR : 1022000690

Male
 DOB : 27 July 1974

Visit : Monday, 09 January 2023

CLINICAL EVALUATION

SUBJECTIVE No complain in ENT examination

OBJECTIVE
 Ear: right & left: tympanic membrane intact
 Nose: right: wide nasal cavity, inferior turbinate eutrophy, straight nasal septum
 Left: wide nasal cavity, inferior turbinate eutrophy, straight nasal septum
 Throat: tonsil T1-T1
 posterior pharyngeal wall normal
 Neck region: no lymph node on palpation
 Audiometry: normal

ASSESSMENT ENT examination within normal limit

PLAN -

Signature

MP+
 dr. Bondan Herwindo, SpTHT

PT. KARTIKA BINA MEDIKATAMA

Patient Name	: TAMBOK PARSAULIAN NAPITUPULU	Clinic	: CLINIC BELTWAY OFFICE PARK
Medical Record No.	: 1022000690	Printed by	: Arlyn

HELPLINE 1500 918
 24 / 7

AUDIOMETRY RESULTS

TAMBOK PARSAULIAN NAPITUPULU

INSPEKTINDO SINERGI PERSADA, PT
 MR : 1022000690

Male
 DOB : 27 July 1974

Visit : Monday, 09 January 2023

CLINICAL EVALUATION

VERIFIED BY

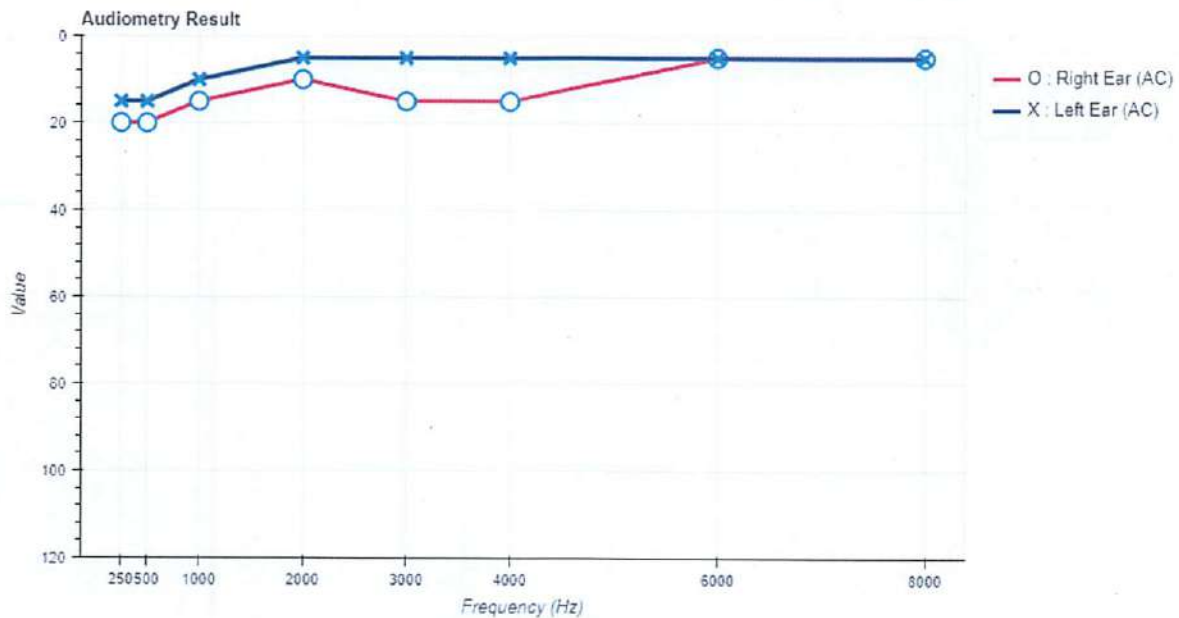
dr. Meristiana Christiane, Sp.THT

LEFT EAR

	250	500	1000	2000	3000	4000	6000	8000
AC	15	15	10	5	5	5	5	5
BC								

RIGHT EAR

	250	500	1000	2000	3000	4000	6000	8000
AC	20	20	15	10	15	15	5	5
BC								



Conclusion Right Ear : Hearing Threshold = 15.0 dB
 (Within Normal Limit)

Conclusion Left Ear : Hearing Threshold = 8.75 dB
 (Within Normal Limit)

Patient Name	: TAMBOK PARSAULIAN NAPITUPULU	Clinic	: CLINIC BELTWAY OFFICE PARK
Medical Record No.	: 1022000690	Printed by	: Arlyn

HELPLINE **1500 918**
 24 / 7

CARDIOLOGY DIAGNOSTIC

TAMBOK PARSAULIAN NAPITUPULU

INSPEKTINDO SINERGI PERSADA, PT
 MR : 1022000690

Male
 DOB : 27 July 1974

Visit : Monday, 09 January 2023

CLINICAL EVALUATION

VERIFIED BY

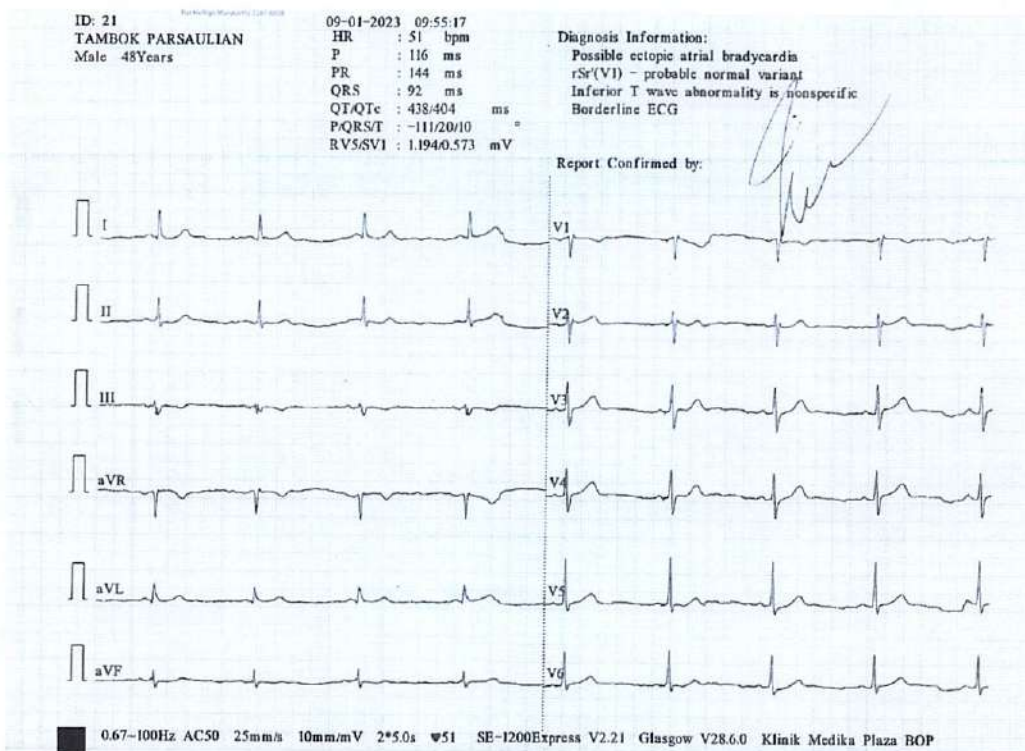
dr. Adolf Hubertus Amahorseja, Sp.JP

EXAMINATION

RESULTS
 09 January 2023

Sinus Rythm Axis (N), P Wave (N), PR Int 0.16, ST - T Segment (N), Aritmia (-)

Comments : Normal ECG



Patient Name	: TAMBOK PARSAULIAN NAPITUPULU	Clinic	: CLINIC BELTWAY OFFICE PARK
Medical Record No.	: 1022000690	Printed by	: Arlyn

HELPLINE 24/7 **1500 918**

TREADMILL DIAGNOSTIC

TAMBOK PARSAULIAN NAPITUPULU

INSPEKTINDO SINERGI PERSADA, PT

MR : 1022000690

Male

DOB : 27 July 1974

Visit : Monday, 09 January 2023

CLINICAL EVALUATION

VERIFIED BY

dr. Adolf Hubertus Amahorseja, Sp.JP

EXAMINATION

RESULTS
 09 January 2023

Sinus Rythm Axis (N), P Wave (N), PR Int 0.16, ST - T Segment (N), Aritmia (-)

Comments

: Treadmill Exercise Test : Negative
 Cardiopulmonary Fitness
 Classification : Good
 METs : 13.3

Patient Name	: TAMBOK PARSAULIAN NAPITUPULU	Clinic	: CLINIC BELTWAY OFFICE PARK
Medical Record No.	: 1022000690	Printed by	: Arlyn

HELPLINE 24 / 7 **1500 918**

TREADMILL RESULTS

TAMBOK PARSAULIAN NAPITUPULU
 INSPEKTINDO SINERGI PERSADA, PT
 MR : 1022000690
 Visit : Monday, 09 January 2023
 Male
 DOB : 27 July 1974
CLINICAL EVALUATION

Summary

1/9/2023 10:02:48 AM

et medical devices spa

via de zinis 6
 +39 02 9505181

Patient		Test information			
Last name	TAMBOK PARSAULIAN NAPITUPULU	Date	1/9/2023 10:02:48 AM	Max HR	151 (09:52)
First name	MR	Test Type	Treadmill	% on theor. HR	88% (171)
Sec. name		Protocol	bruce kmh	BP Max	110/70 (01:40)
Birthday	7/27/1974	Pre-Exercise	00:14	DP Max	166 (09:52)
Sex	Male	Exercise	09:30		
ID	1022000690	Recovery	00:24		
Reasons for test					
Medication					

Phase	Time	HR	BP	DP/100	METS	Speed	Elevation	J+X	V5
	mm:ss	bpm	mmHg			kmh	%	ms	mm
Pre-Exercise	00:14	60	---	--	0.7	1.6	0.0	60	1.80
Peak	09:44	147	110/70	161	13.3	6.7	16.0	60	-1.75
End Test	10:08	145	110/70	159	1.1	2.4	0.0	60	-1.75

Reasons for test termination

Conclusions

Sign MED1 MED1
 CARDIOLINE® - CUBE STRESS

TAMBOK PARSAULIAN NAPITUPULU MR

1/42

Patient Name	: TAMBOK PARSAULIAN NAPITUPULU	Clinic	: CLINIC BELTWAY OFFICE PARK
Medical Record No.	: 1022000690	Printed by	: Arlyn

HELPLINE 1500 918
 24 / 7

TREADMILL RESULTS

TAMBOK PARSAULIAN NAPITUPULU

INSPEKTINDO SINERGI PERSADA, PT
 MR : 1022000690

Male
 DOB : 27 July 1974

Visit : Monday, 09 January 2023

CLINICAL EVALUATION

et medical devices spa

1/9/2023 10:02:48 AM

Phase	Time mm:ss	HR bpm	BP mmHg	DP/100	METS	Speed kmh	Elevation %
SUPINE	00:09	60	---/---	---	0.0	0.0	0.0
STANDING	00:11	60	---/---	---	0.0	0.0	0.0
HYPERV	00:12	60	---/---	---	0.0	0.0	0.0
WARM-UP	00:14	60	---/---	---	0.7	1.6	0.0
1	03:14	98	110/70	105	4.0	2.7	10.0
2	08:14	113	110/70	124	6.6	4.0	12.0
3	09:14	138	110/70	151	10.0	5.5	14.0
Peak	09:44	147	110/70	161	13.3	6.7	16.0
1	10:08	145	110/70	159	1.1	2.4	0.0

CARDIOLINE® - CUBE STRESS

TAMBOK PARSAULIAN NAPITUPULU MR

2/42

Patient Name	: TAMBOK PARSAULIAN NAPITUPULU	Clinic	: CLINIC BELTWAY OFFICE PARK
Medical Record No.	: 1022000690	Printed by	: Arlyn

HELPLINE **1500 918**
 24/7

TREADMILL RESULTS

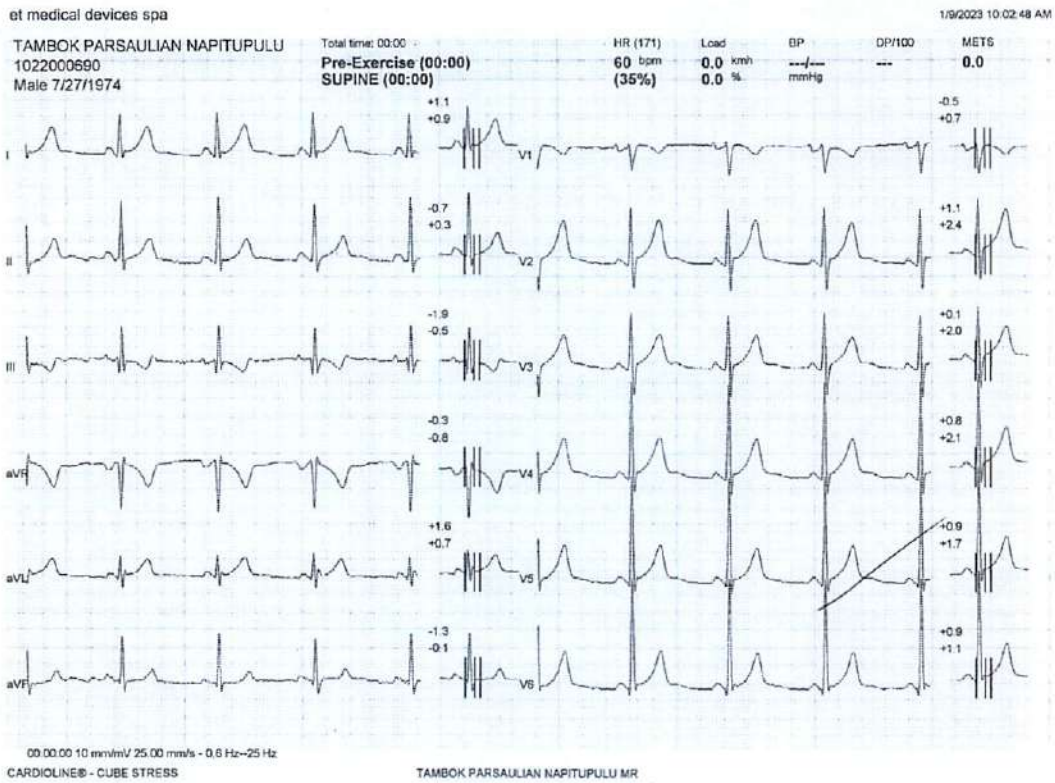
TAMBOK PARSAULIAN NAPITUPULU

INSPEKTINDO SINERGI PERSADA, PT
 MR : 1022000690

Male
 DOB : 27 July 1974

Visit : Monday, 09 January 2023

CLINICAL EVALUATION



Patient Name	: TAMBOK PARSAULIAN NAPITUPULU	Clinic	: CLINIC BELTWAY OFFICE PARK
Medical Record No.	: 1022000690	Printed by	: Arlyn

HELPLINE **1500 918**
 24 / 7

TREADMILL RESULTS

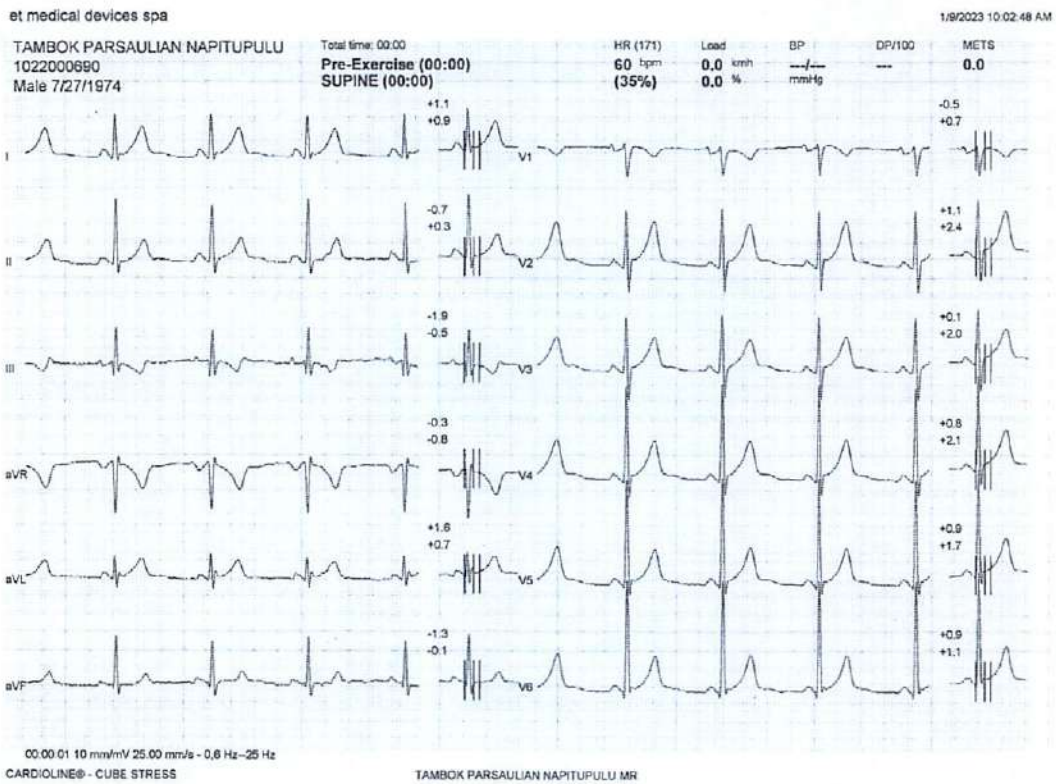
TAMBOK PARSAULIAN NAPITUPULU

INSPEKTINDO SINERGI PERSADA, PT
 MR : 1022000690

Male
 DOB : 27 July 1974

Visit : Monday, 09 January 2023

CLINICAL EVALUATION



Patient Name	: TAMBOK PARSAULIAN NAPITUPULU	Clinic	: CLINIC BELTWAY OFFICE PARK
Medical Record No.	: 1022000690	Printed by	: Arlyn

HELPLINE **1500 918**
 24 / 7

TREADMILL RESULTS

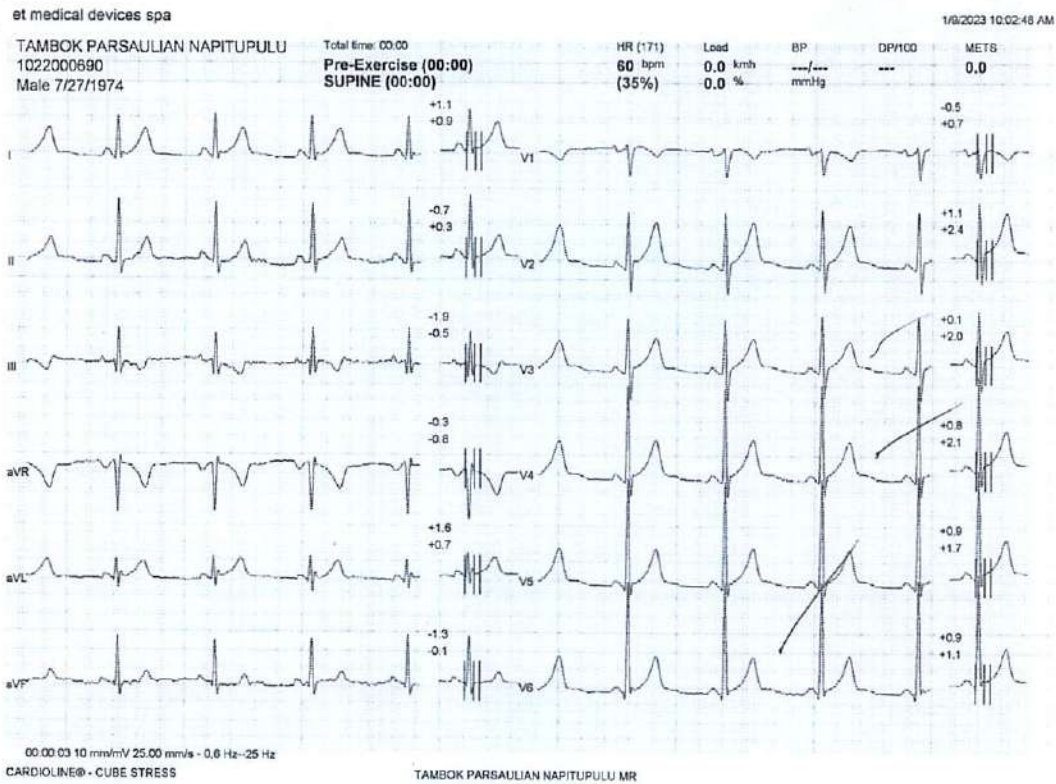
TAMBOK PARSAULIAN NAPITUPULU

INSPEKTINDO SINERGI PERSADA, PT
 MR : 1022000690

Male
 DOB : 27 July 1974

Visit : Monday, 09 January 2023

CLINICAL EVALUATION



Patient Name	: TAMBOK PARSAULIAN NAPITUPULU	Clinic	: CLINIC BELTWAY OFFICE PARK
Medical Record No.	: 1022000690	Printed by	: Arlyn

HELPLINE 1500 918
 24/7

TREADMILL RESULTS

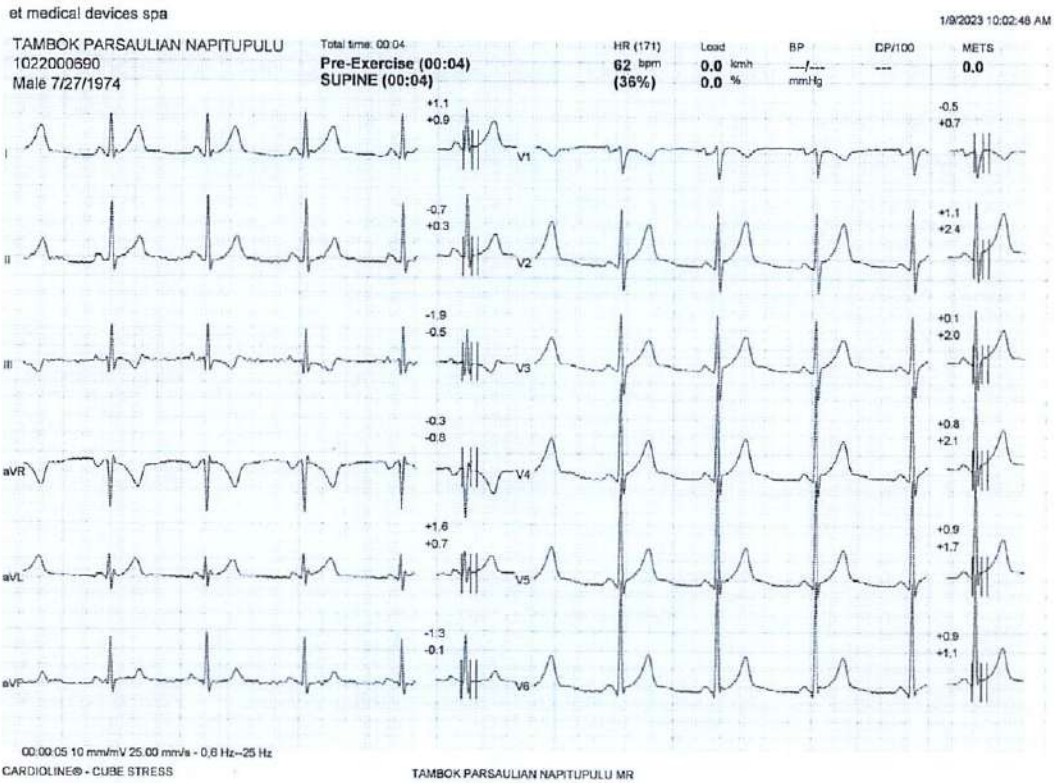
TAMBOK PARSAULIAN NAPITUPULU

INSPEKTINDO SINERGI PERSADA, PT
 MR : 1022000690

Male
 DOB : 27 July 1974

Visit : Monday, 09 January 2023

CLINICAL EVALUATION



Patient Name	: TAMBOK PARSAULIAN NAPITUPULU	Clinic	: CLINIC BELTWAY OFFICE PARK
Medical Record No.	: 1022000690	Printed by	: Arlyn

HELPLINE **1500 918**
 24 / 7

TREADMILL RESULTS

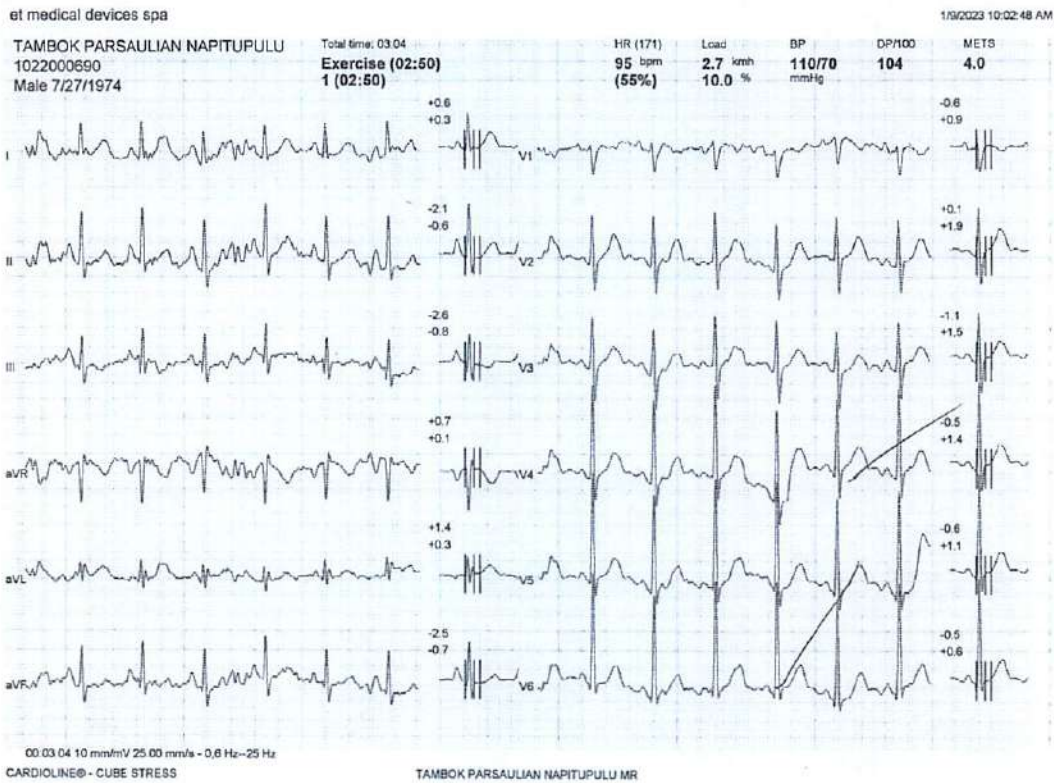
TAMBOK PARSAULIAN NAPITUPULU

INSPEKTINDO SINERGI PERSADA, PT
 MR : 1022000690

Male
 DOB : 27 July 1974

Visit : Monday, 09 January 2023

CLINICAL EVALUATION



Patient Name	: TAMBOK PARSAULIAN NAPITUPULU	Clinic	: CLINIC BELTWAY OFFICE PARK
Medical Record No.	: 1022000690	Printed by	: Arlyn

HELPLINE **1500 918**
 24/7

TREADMILL RESULTS

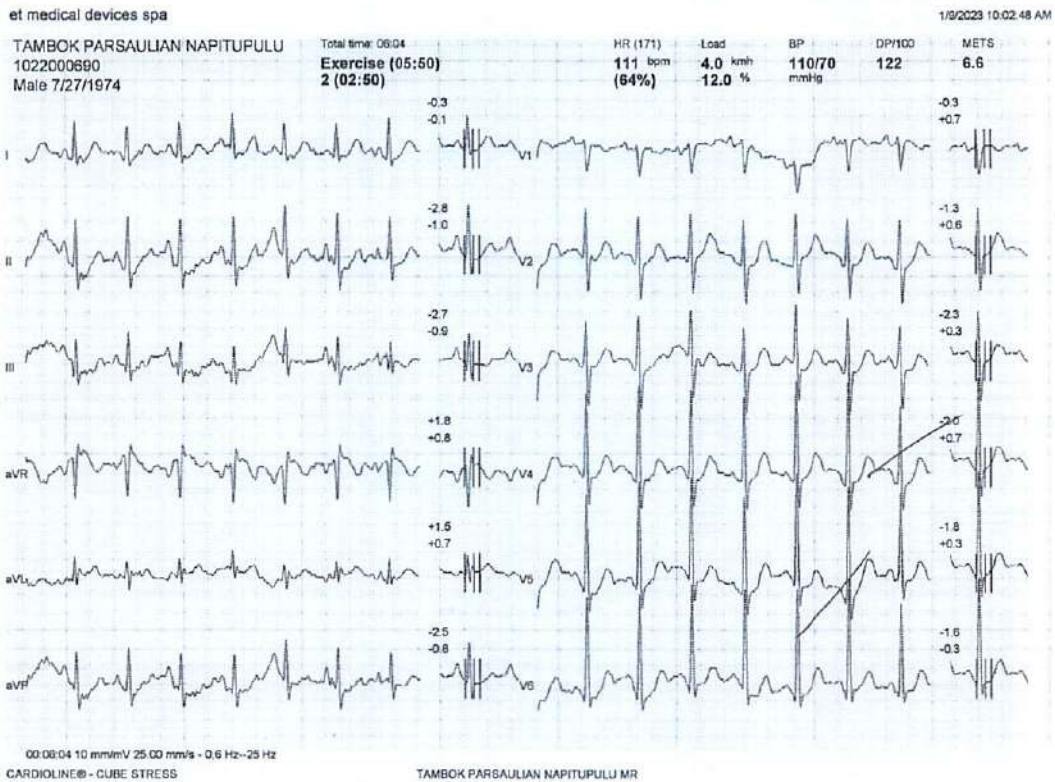
TAMBOK PARSAULIAN NAPITUPULU

INSPEKTINDO SINERGI PERSADA, PT
 MR : 1022000690

Male
 DOB : 27 July 1974

Visit : Monday, 09 January 2023

CLINICAL EVALUATION



Patient Name	: TAMBOK PARSAULIAN NAPITUPULU	Clinic	: CLINIC BELTWAY OFFICE PARK
Medical Record No.	: 1022000690	Printed by	: Arlyn

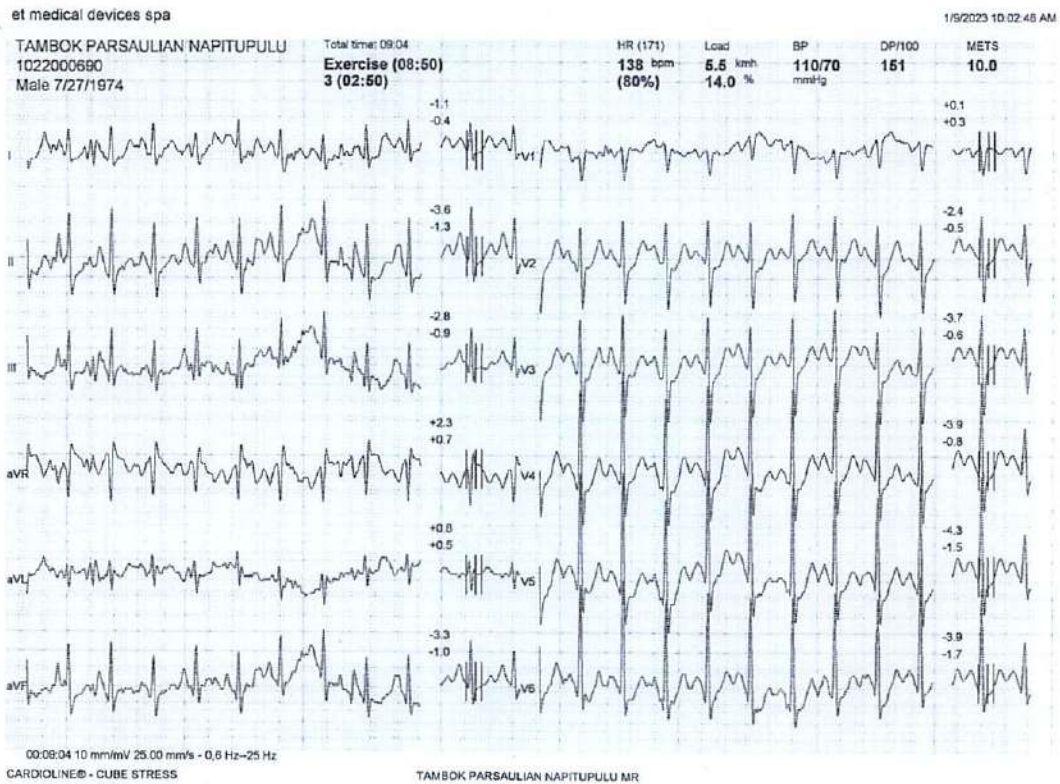
HELPLINE **1500 918**
 24 / 7

TREADMILL RESULTS

TAMBOK PARSAULIAN NAPITUPULU
 INSPEKTINDO SINERGI PERSADA. PT
 MR : 1022000690
 Visit : Monday, 09 January 2023

Male
 DOB : 27 July 1974

CLINICAL EVALUATION



Patient Name	: TAMBOK PARSAULIAN NAPITUPULU	Clinic	: CLINIC BELTWAY OFFICE PARK
Medical Record No.	: 1022000690	Printed by	: Arlyn

HELPLINE **1500 918**
 24/7

TREADMILL RESULTS

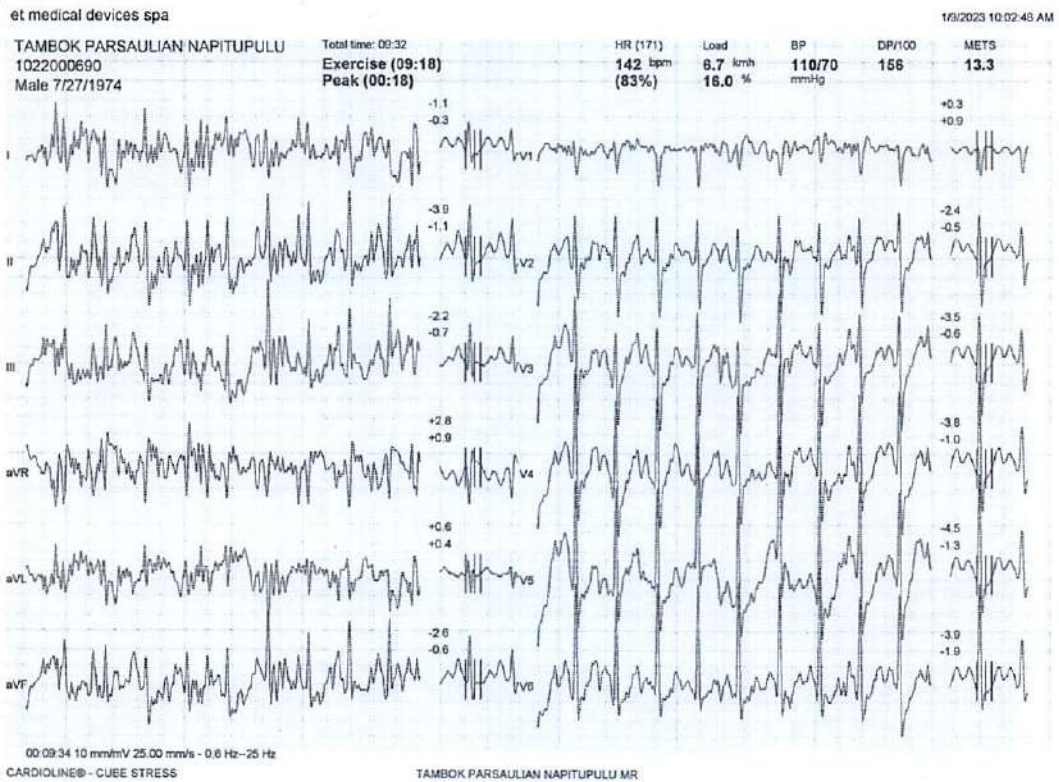
TAMBOK PARSAULIAN NAPITUPULU

INSPEKTINDO SINERGI PERSADA, PT
 MR : 1022000690

Male
 DOB : 27 July 1974

Visit : Monday, 09 January 2023

CLINICAL EVALUATION



Patient Name	: TAMBOK PARSAULIAN NAPITUPULU	Clinic	: CLINIC BELTWAY OFFICE PARK
Medical Record No.	: 1022000690	Printed by	: Arlyn

HELPLINE 1500 918
 24 / 7

et medical devices spa

via de zinis 6
+39 02 9505181

Patient

Test information

Last name	TAMBOK PARSAULIAN NAPITUPULU	Date/Time	1/9/2023 10:02:48 AM	Max HR	151 (09:52)
First name	MR	Test Type	Treadmill	% on theor. HR	88% (171)
Sec. name		Protocol	bruce kmh	BP Max	110/70 (01:40)
Birthday	7/27/1974	Pre-Exercise	00:14	DP Max	166 (09:52)
Sex	Male	Exercise	09:30		
ID	1022000690	Recovery	00:24		
Reasons for test					
Medication					

Phase	Time mm:ss	HR bpm	BP mmHg	DP/100	METS	Speed kmh	Elevation %	J+X ms	V5 mm
Pre-Exercise	00:14	60	---/---	---	0.7	1.6	0.0	60	1.80
Peak	09:44	147	110/70	161	13.3	6.7	16.0	60	-1.75
End Test	10:08	145	110/70	159	1.1	2.4	0.0	60	-1.75

Reasons for test termination

Conclusions

The image shows a handwritten signature in black ink over a blue circular stamp. The stamp contains the text 'MPT+' and 'MEDIKATAMA' around a central cross symbol.

Sign

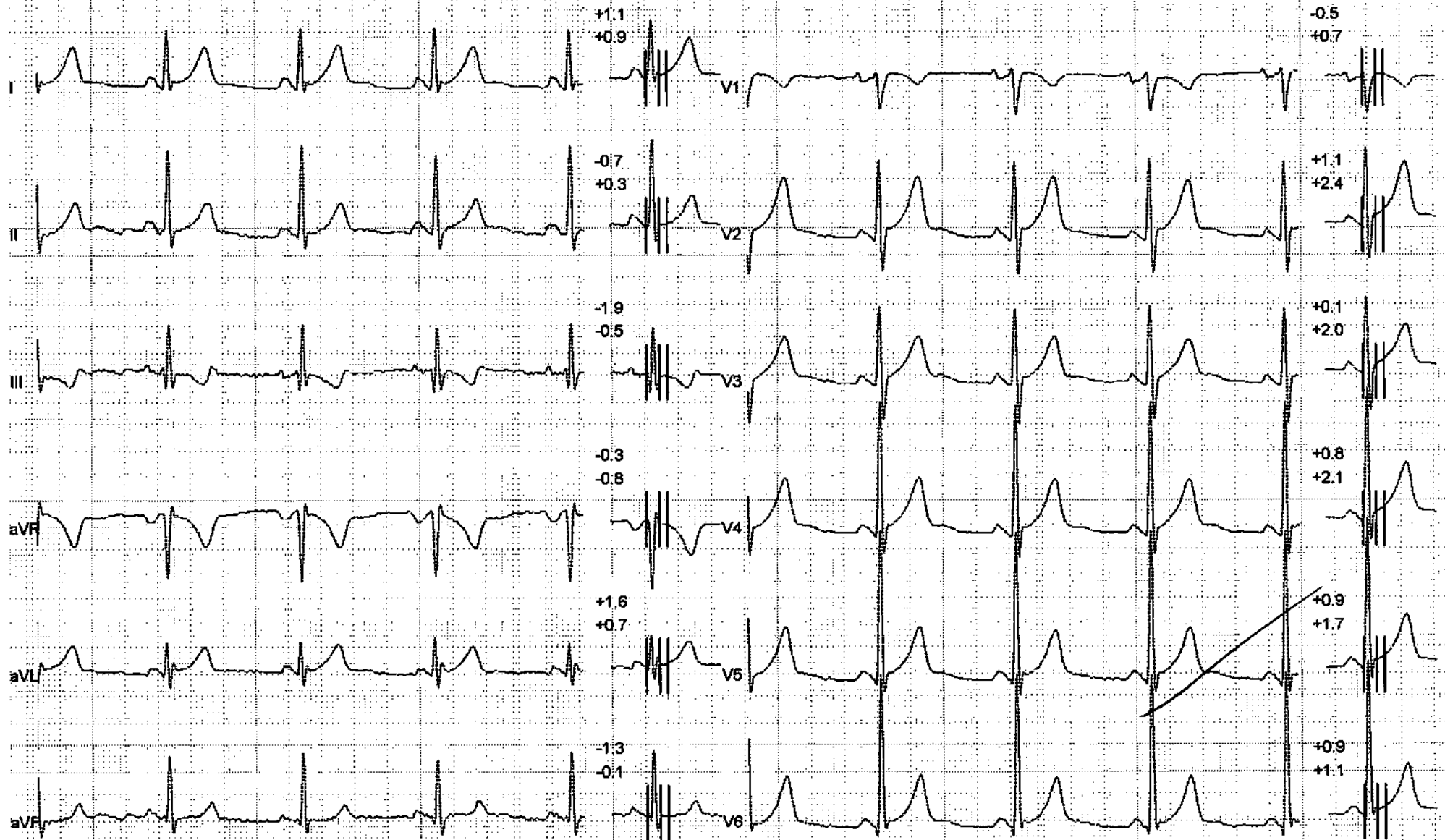
MED1 MED1

Phase	Time mm:ss	HR bpm	BP mmHg	DP/100	METS	Speed kmh	Elevation %
SUPINE	00:09	60	---/---	---	0.0	0.0	0.0
STANDING	00:11	60	---/---	---	0.0	0.0	0.0
HYPERV	00:12	60	---/---	---	0.0	0.0	0.0
WARM-UP	00:14	60	---/---	---	0.7	1.6	0.0
1	03:14	96	110/70	105	4.0	2.7	10.0
2	06:14	113	110/70	124	6.6	4.0	12.0
3	09:14	138	110/70	151	10.0	5.5	14.0
Peak	09:44	147	110/70	161	13.3	6.7	16.0
1	10:08	145	110/70	159	1.1	2.4	0.0

TAMBOK PARSAULIAN NAPITUPULU
1022000690
Male 7/27/1974

Total time: 00:00
Pre-Exercise (00:00)
SUPINE (00:00)

HR (171) 60 bpm (35%)
Load 0.0 kmh 0.0 %
BP ---/--- mmHg
DP/100 ---
METS 0.0

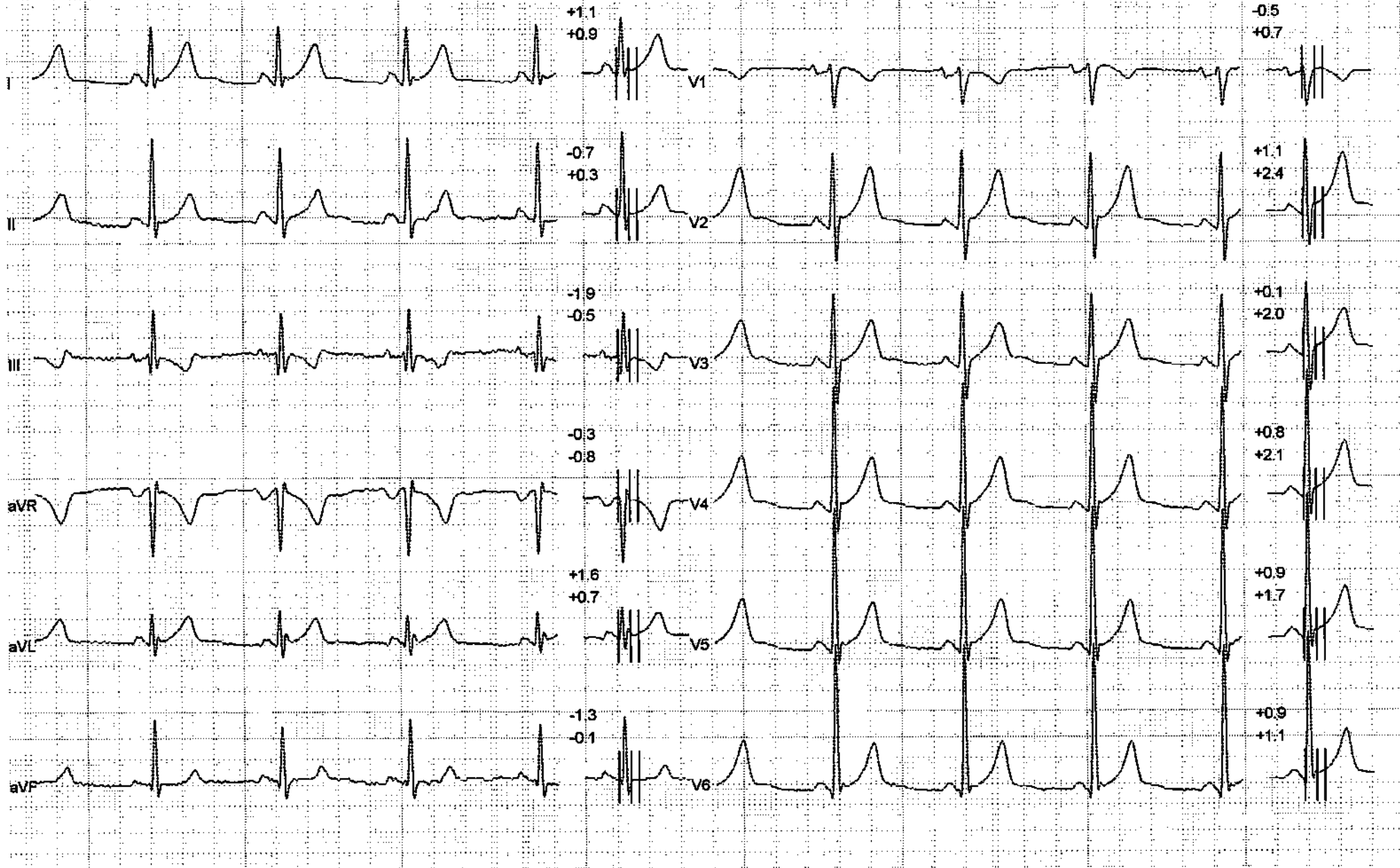


00:00:00 10 mm/mV 25.00 mm/s - 0.6 Hz-25 Hz

TAMBOK PARSAULIAN NAPITUPULU
1022000690
Male 7/27/1974

Total time: 00:00
Pre-Exercise (00:00)
SUPINE (00:00)

HR (171) 60 bpm (35%)
Load 0.0 kmh 0.0 %
BP ---/--- mmHg
DP/100 ---
METS 0.0

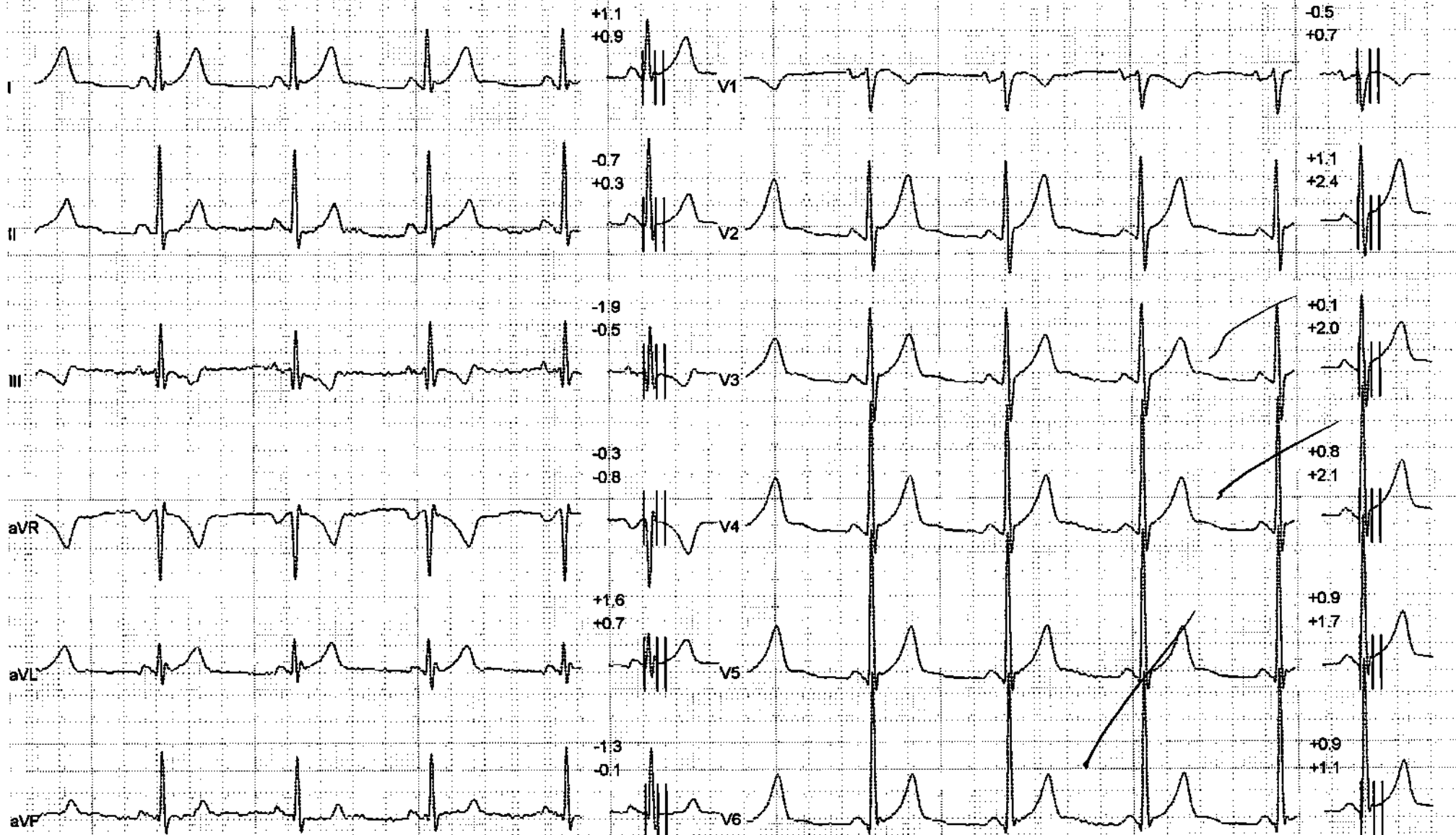


00:00:01 10 mm/mV 25.00 mm/s - 0,6 Hz--25 Hz

TAMBOK PARSAULIAN NAPITUPULU
1022000690
Male 7/27/1974

Total time: 00:00
Pre-Exercise (00:00)
SUPINE (00:00)

HR (171) 60 bpm (35%)
Load 0.0 kmh 0.0 %
BP ---/--- mmHg
DP/100 ---
METS 0.0

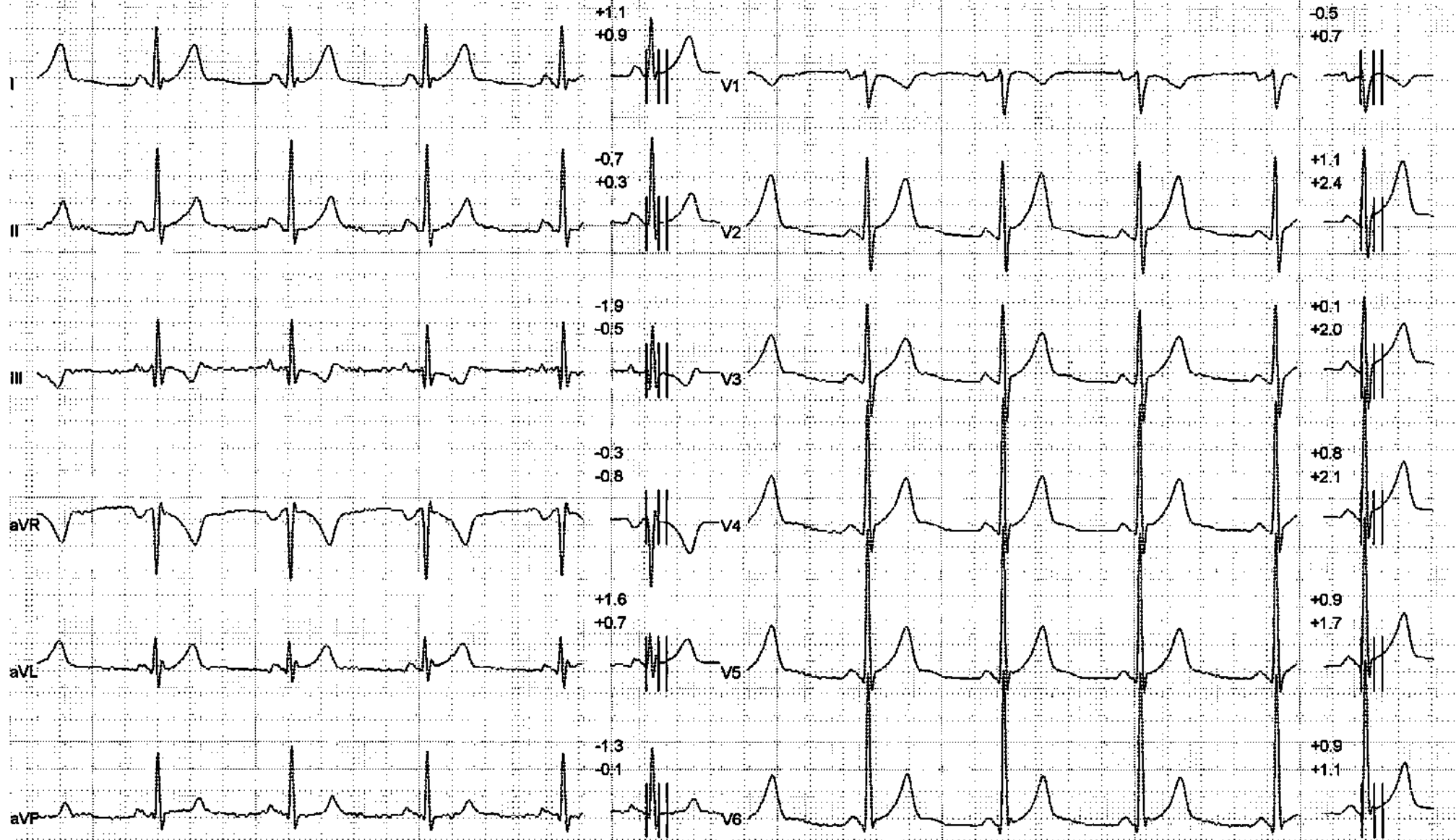


00:00:03 10 mm/mV 25.00 mm/s - 0,6 Hz--25 Hz

TAMBOK PARSAULIAN NAPITUPULU
1022000690
Male 7/27/1974

Total time: 00:04
Pre-Exercise (00:04)
SUPINE (00:04)

HR (171) 62 bpm
(36%)
Load 0.0 kmh
0.0 %
BP ---/--- mmHg
DP/100 ---
METS 0.0

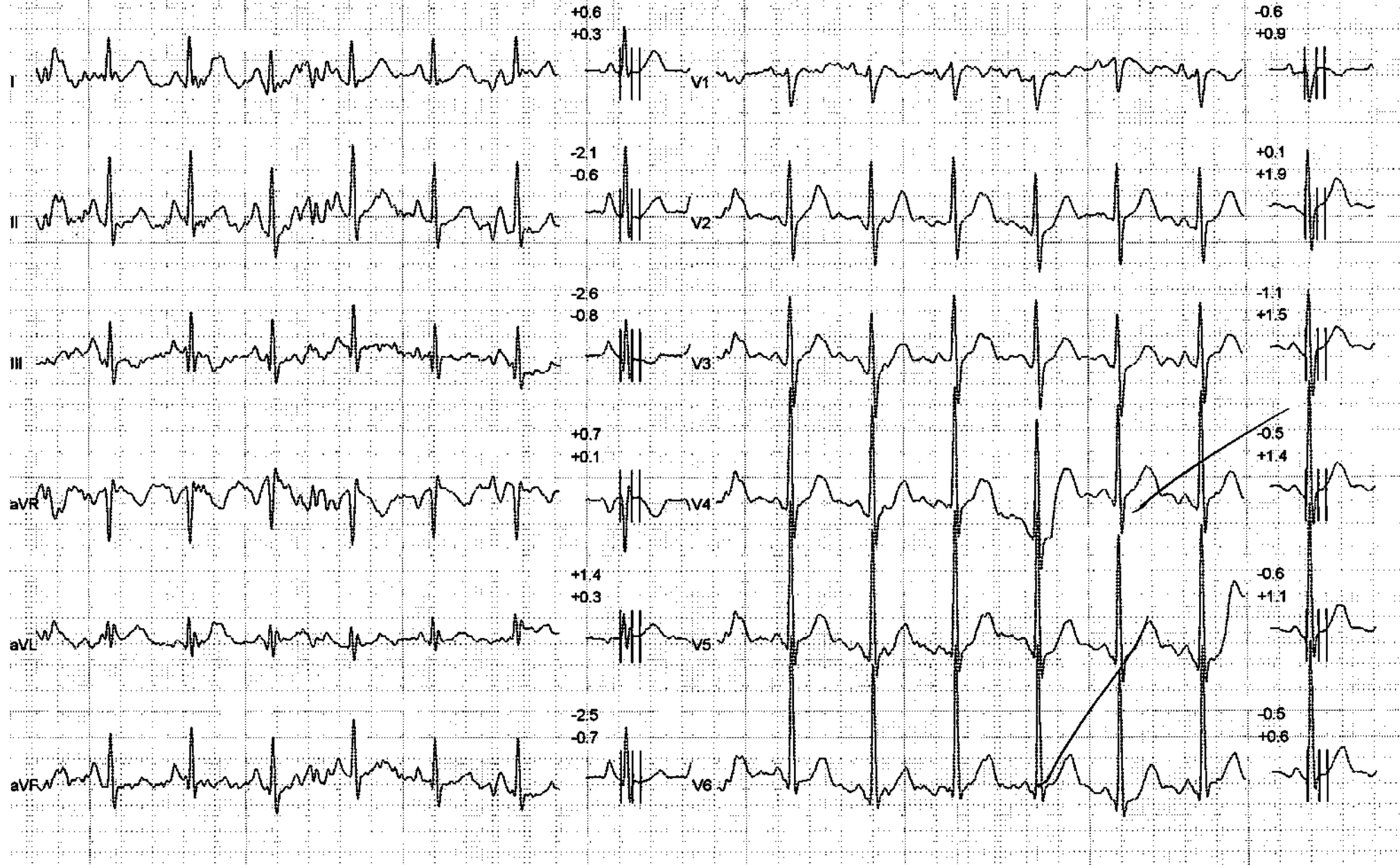


00:00:05 10 mm/mV 25.00 mm/s - 0.6 Hz--25 Hz

TAMBOK PARSAULIAN NAPITUPULU
1022000690
Male 7/27/1974

Total time: 03:04
Exercise (02:50)
1 (02:50)

HR (171) 95 bpm (55%)
Load 2.7 kmh 10.0 %
BP 110/70 mmHg
OP/100 104
METS 4.0

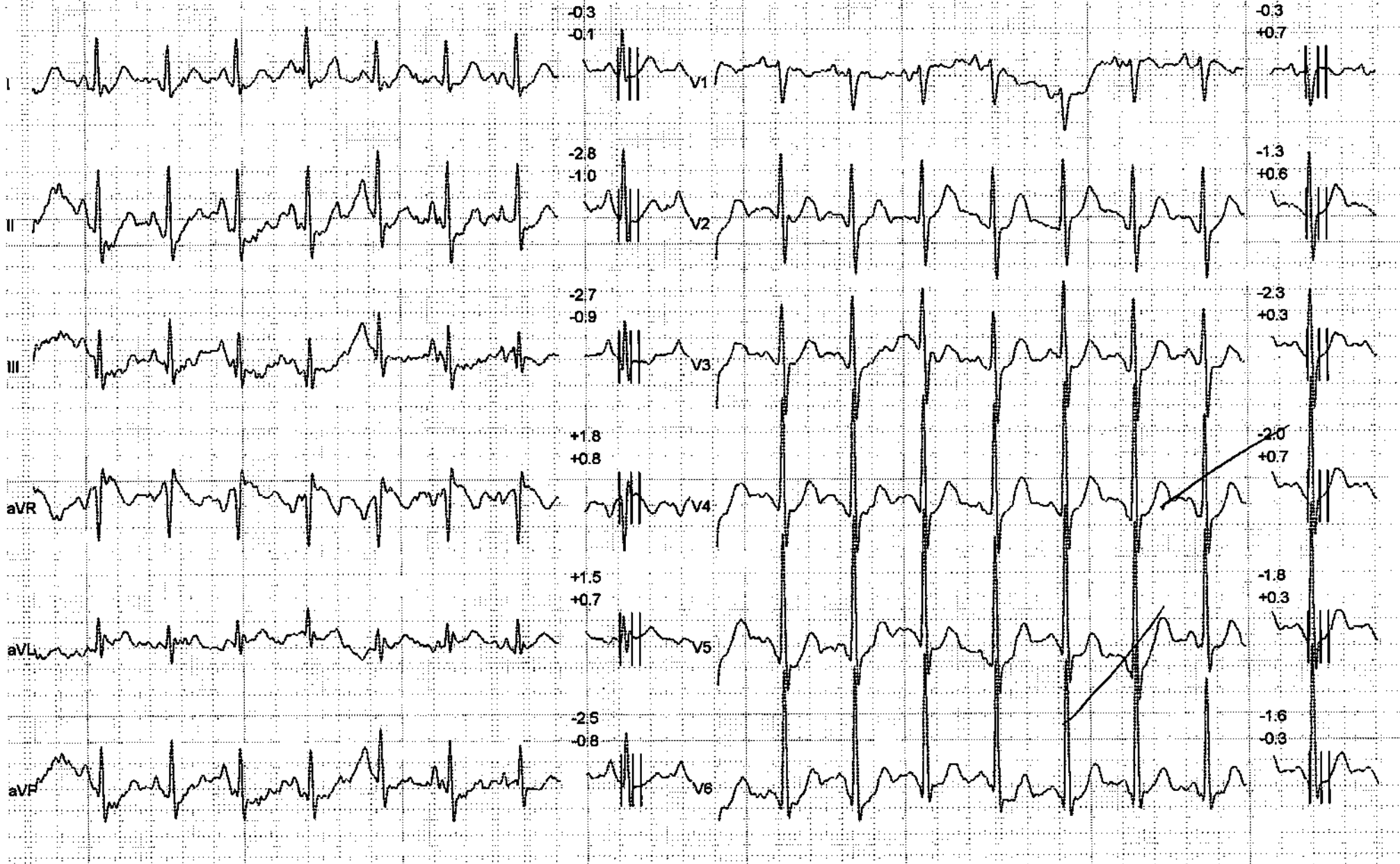


00:03:04 10 mm/mV 25.00 mm/s - 0,6 Hz--25 Hz

TAMBOK PARSAULIAN NAPITUPULU
1022000690
Male 7/27/1974

Total time: 06:04
Exercise (05:50)
2 (02:50)

HR (171) 111 bpm (64%)
Load 4.0 kmh 12.0 %
BP 110/70 mmHg
DP/100 122
METS 6.6

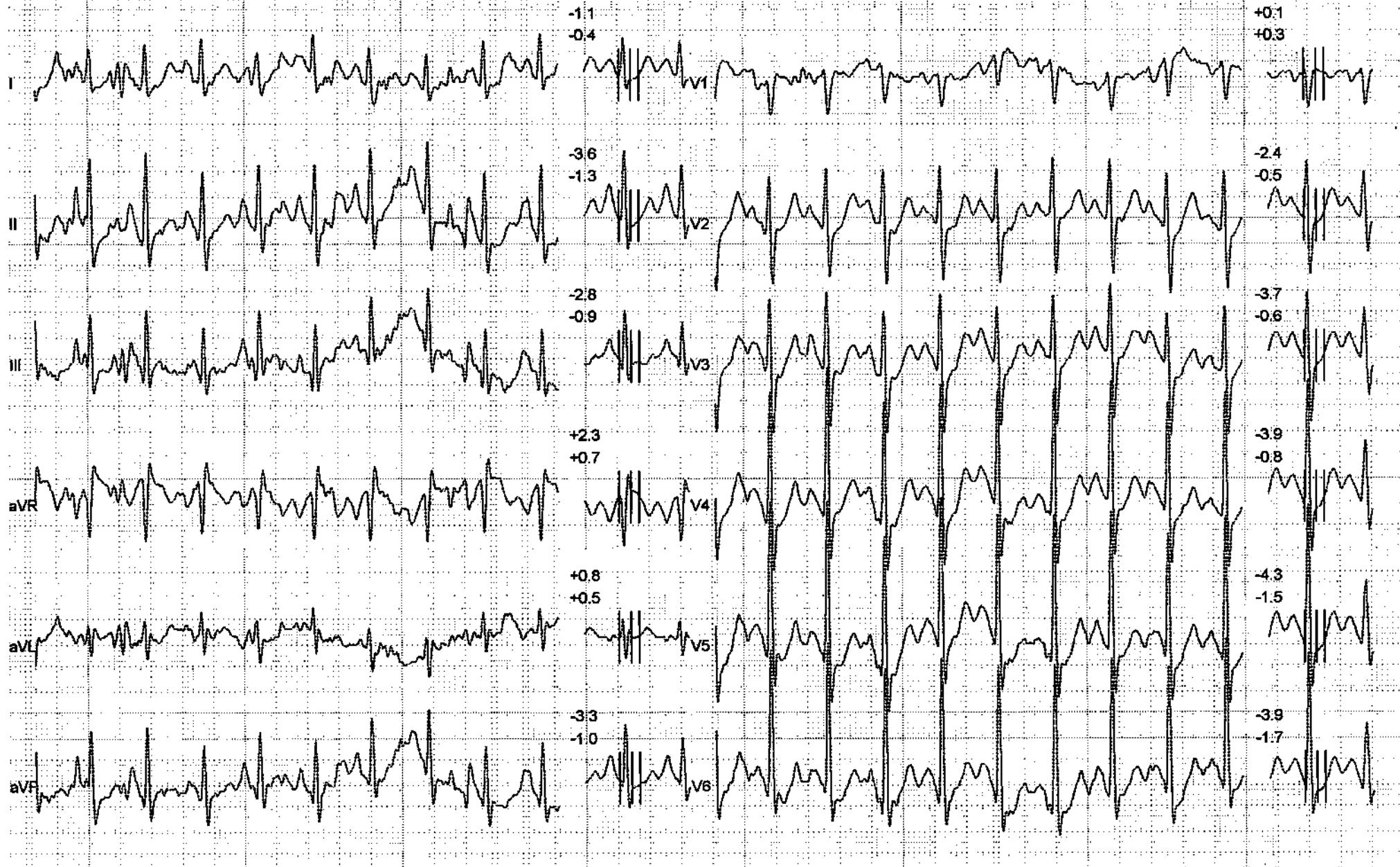

00:06:04 10 mm/mV 25.00 mm/s - 0,6 Hz-25 Hz

TAMBOK PARSAULIAN NAPITUPULU
1022000690
Male 7/27/1974

Total time: 09:04
Exercise (08:50)
3 (02:50)

HR (171)	Load	BP	DP/100	METS
138 bpm	5.5 kmh	110/70 mmHg	151	10.0
(80%)	14.0 %			

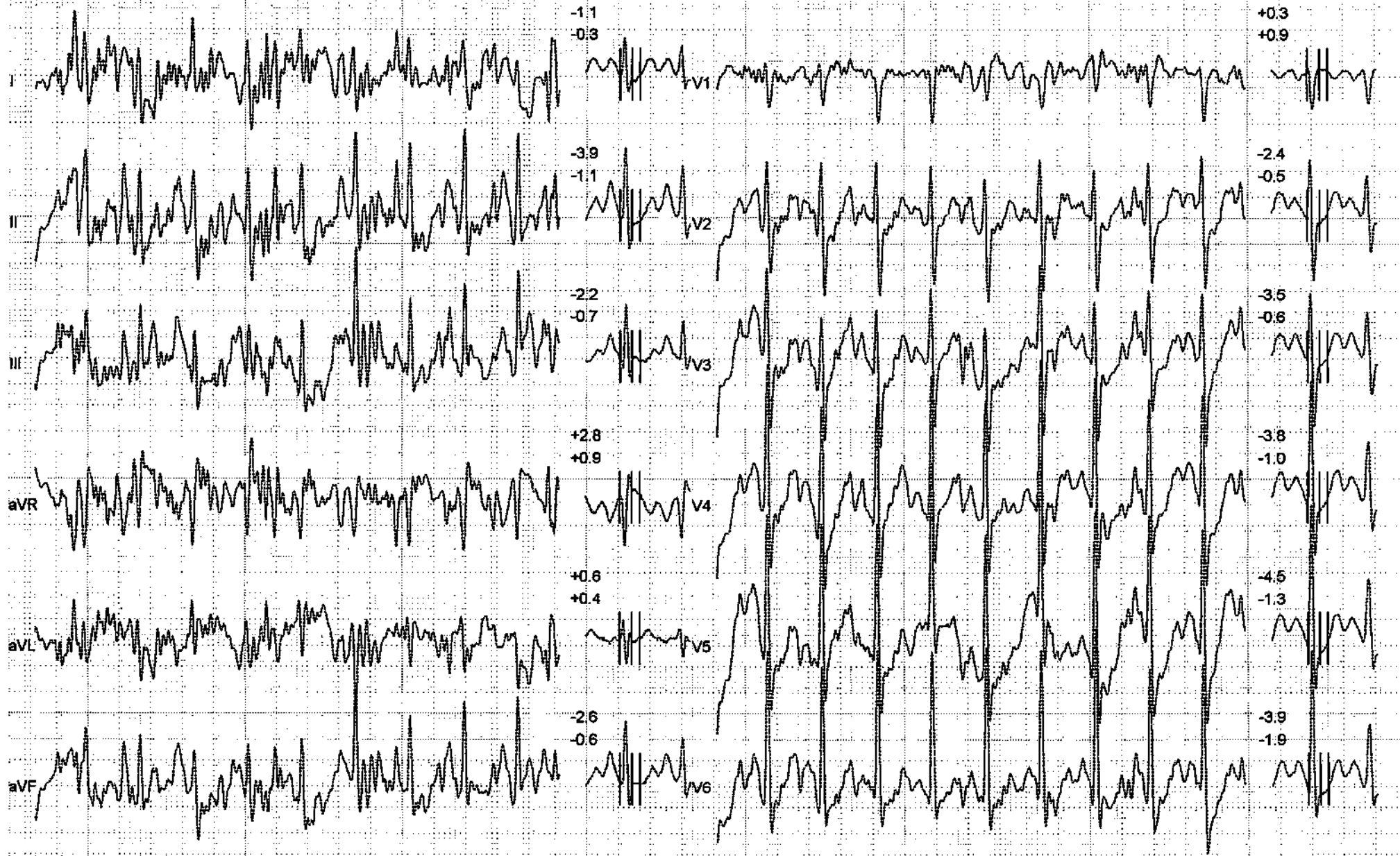

00:09:04 10 mm/mV 25.00 mm/s - 0,6 Hz-25 Hz

TAMBOK PARSAULIAN NAPITUPULU
1022000690
Male 7/27/1974

Total time: 09:32
Exercise (09:18)
Peak (00:18)

HR (171)	Load	BP	DP/100	METS
142 bpm	6.7 kmh	110/70	156	13.3
(83%)	16.0 %	mmHg		



00:09:34 10 mm/mV 25.00 mm/s - 0,6 Hz-25 Hz

DENTAL RESULTS

TAMBOK PARSAULIAN NAPITUPULU

INSPEKTINDO SINERGI PERSADA, PT
 MR : 1022000690

Male
 DOB : 27 July 1974

Visit : Monday, 09 January 2023

CLINICAL EVALUATION

DENTAL RECORD - 09 January 2023

SUBJECTIVE

MCU

OBJECTIVE

	X	X	R	X				-				R	R	R	R	
	X	X	X					-				R	R	X	X	

ASSESSMENT

CALCULUS DAN STAIN+3
 17,16,14,37,36,45,46,47=MISSING
 15,24,25,26,27,35,35=RADIX

PLAN

PRO SCALLING
 17,16,14,37,36,45,46,47=PRO GTS
 15,24,25,26,27,35,35=PRO EXO

Signature

PT. KARTIKA BINA MEDIKATAMA
 drg. Fajar Sulawati

Patient Name	: TAMBOK PARSAULIAN NAPITUPULU	Clinic	: CLINIC BELTWAY OFFICE PARK
Medical Record No.	: 1022000690	Printed by	: Arlyn

HELPLINE **1500 918**
 24/7

X-RAY FILM

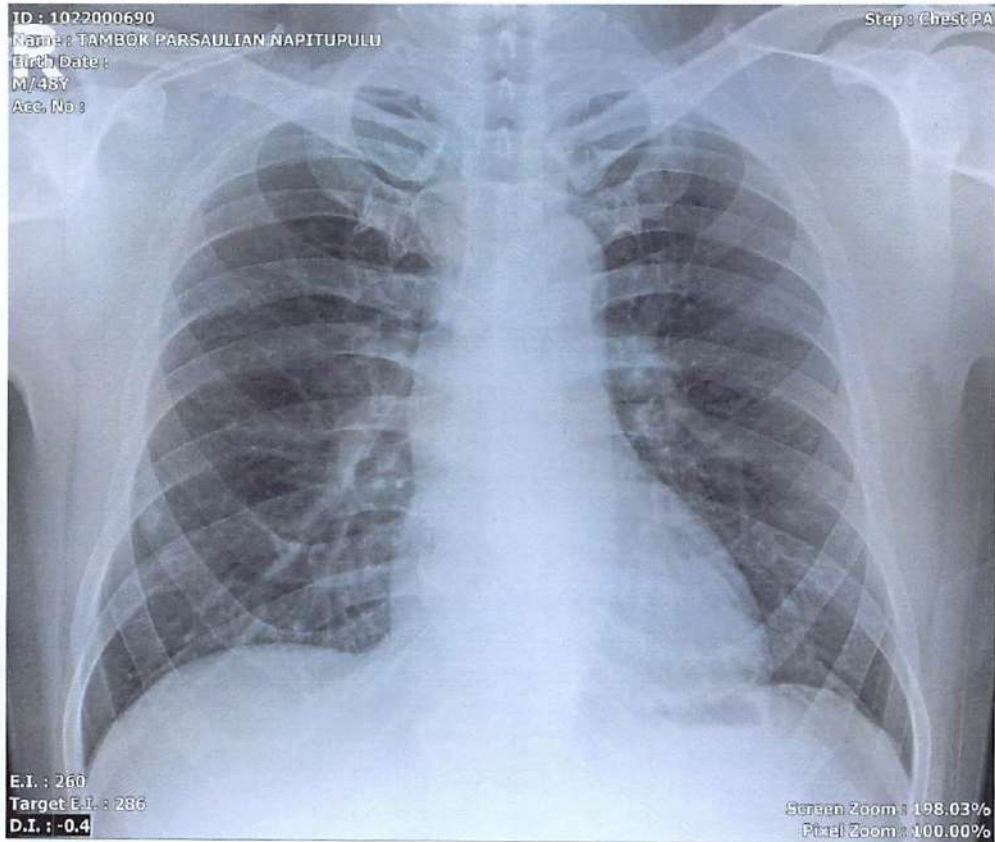
TAMBOK PARSAULIAN NAPITUPULU

INSPEKTINDO SINERGI PERSADA, PT
 MR : 1022000690

Male
 DOB : 27 July 1974

Visit : Monday, 09 January 2023

CLINICAL EVALUATION



Patient Name	: TAMBOK PARSAULIAN NAPITUPULU	Clinic	: CLINIC BELTWAY OFFICE PARK
Medical Record No.	: 1022000690	Printed by	: Arlyn

HELPLINE 1500 918
 24 / 7