

MEDICAL CHECK UP REPORT

HASIL MEDICAL CHECK UP

Patient Name :

Nama Pasien

SUHERI MAHFUD

Doctor Name :

Nama Dokter

dr. Julianto Kemala

Package :

Paket

PT. INSPEKTINDO SINERGI PERSADA

SILOAM HOSPITALS LIPPO CIKARANG

13 September 2022

SUHERI MAHFUD

Appointment ID: 148920

No. Appointment

Date of Birth : 23 Desember 1975

Tanggal Lahir

Gender : Male

Jenis Kelamin

Phone Number : +6281257760600

Nomor Telepon

E-mail : sarni@inspektindo.com

E-mail

Form Kuesioner Website

No Significant History

Riwayat Penyakit Dahulu

- Alergi : Ya, Alergi Makanan (Ikan)
- Operasi pembedahan : Ya, Operasi Tonsilectomy Tahun 2000

Riwayat Vaksinasi

- Hepatitis A : Tidak
- Hepatitis B : Tidak
- Influenza : Tidak
- Human Papilloma Virus : Tidak
- Varicella : Tidak
- Mumps Measles Rubella : Tidak
- Tifoid : Tidak
- Lain-lain : Tidak

Riwayat Penyakit Keluarga

Riwayat Kebiasaan

- Apakah Anda pernah merokok secara teratur? : Tidak

- Bila 'Ya', apakah Anda saat ini masih tetap merokok? : Tidak
- Apakah Anda berolahraga secara teratur? : Ya
- Apakah Anda mengonsumsi minuman beralkohol? : Tidak

Untuk wanita - Riwayat Kesehatan Reproduksi

No Significant History

Antropometri

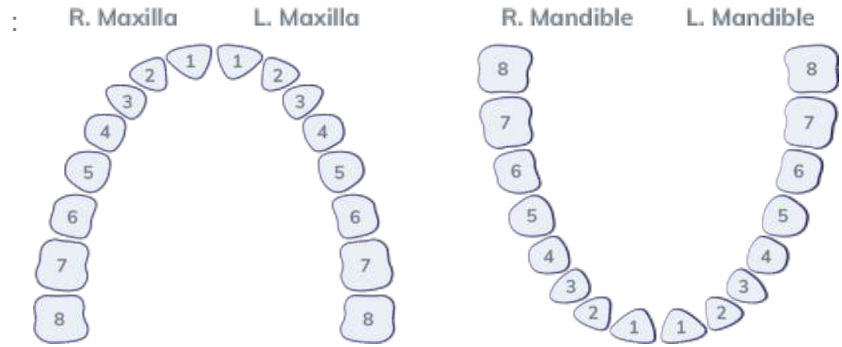
| | |
|------------------------------|---------------|
| ● Tekanan Darah Sistolik | : 110 |
| ● Tekanan Darah Diastolik | : 70 |
| ● Tekanan Darah | : 110/70 mmHg |
| ● Lingkar Perut | : - |
| ● Nadi | : 76x/menit |
| ● Lingkar Dada Inspirasi | : - |
| ● Lingkar Dada Ekspirasi | : - |
| ● Laju Napas | : 18x/menit |
| ● Berat Badan | : 66 kg |
| ● Tinggi Badan | : 153 cm |
| ● Indeks Massa Tubuh | : 28.19 |
| ● Lingkar Pergelangan Tangan | : - |
| ● Lingkar Leher | : - |
| ● Penampakan Umum | : Normal |
| ● Kulit | : Normal |
| ● Nodus Limfe | : Normal |

Status Generalis

| | |
|------------------------------|--|
| ● Ketajaman Visus Mata Kiri | : 20/60 |
| ● Lapang Pandang Mata Kiri | : Normal |
| ● Adisi Mata Kiri | : Normal |
| ● Koreksi Mata Kiri | : S-0.75, C-0.50x160, + 1.75 |
| ● Ketajaman Visus Mata Kanan | : 20/60 |
| ● Lapang Pandang Mata Kanan | : Normal |
| ● Adisi Mata Kanan | : Normal |
| ● Koreksi Mata Kanan | : S-0.75, C-0.75x30, +1.75 |
| ● Buta Warna | : Parsial |
| ● Telinga Kiri | : Membran Timpani Tidak Utuh Inaktif (OMP) |

- Telinga Kanan
- Hidung
- Mulut
- Gigi
- Gambar Gigi

: Normal
 : Tidak ada pemeriksaan selama pandemi
 : Tidak ada pemeriksaan selama pandemi
 : Tidak ada pemeriksaan selama pandemi



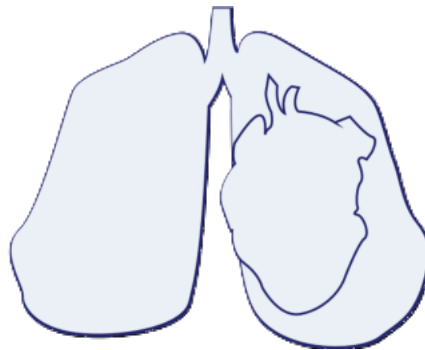
- Tiroid
- Tumor
- Lainnya

: Normal
 : Normal
 : Normal

Toraks

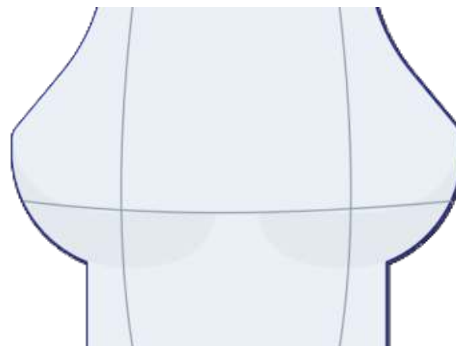
- Paru
- Gambar Toraks

: Normal
 :



- Payudara
- Gambar Payudara

: Normal
 :

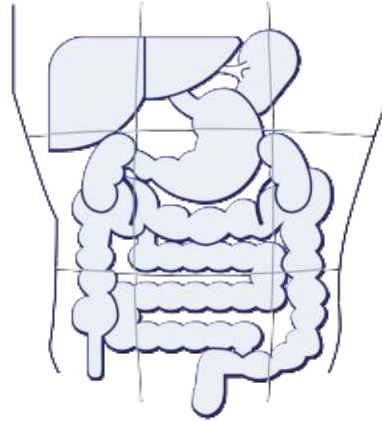


● Jantung : Normal

Abdomen

● Abdomen : Normal

● Gambar Abdomen :



● Lambung : Normal

● Liver : Normal

● Usus : Normal

● Lien : Normal

● Rektum : Tidak dilakukan pemeriksaan

● Ginjal : Normal

● Tes Hernia : Tidak dilakukan pemeriksaan

Ekstremitas

● Ekstremitas Atas Kanan : Normal

● Ekstremitas Atas Kiri : Normal

● Ekstremitas Bawah Kanan : Normal

● Ekstremitas Bawah Kiri : Normal

Saraf

● Motorik : Normal

● Koordinasi : Normal

● Sensorik : Normal

● Refleks : Normal

Pemeriksaan Dokter Spesialis

- DOKTER UMUM : Jaeger Test : Jaeger I
- MATA : Astigmatisme ODS + Presbiopia

Pemeriksaan Laboratorium

| JENIS PEMERIKSAAN | HASIL | NILAI NORMAL |
|----------------------------------|--------------------------|------------------|
| ● Darah Lengkap | | |
| ● Hemoglobin | 14.5 g/dL | 13.0 - 18.0 |
| ● Jumlah Lekosit | 5.9 10 ³ /ul | 5.0 - 10.0 |
| ● Hitung Jenis | | |
| ● Basofil | 0 % | 0 - 1 |
| ● Eosinofil | 2 % | 1 - 3 |
| ● Batang (L) | 0 % | 2 - 6 |
| ● Segmen | 69 % | 50 - 70 |
| ● Limfosit | 22 % | 20 - 40 |
| ● Absolute Lymphocyte Count | 1.30 10 ³ /ul | |
| ● Neutrophyl Lymphocyte Rat | 3.1 | |
| ● Monosit | 7 % | 2 - 8 |
| ● Jumlah Eritrosit | 4.78 10 ⁶ /uL | 4.60 - 6.20 |
| ● Hematokrit | 42.9 % | 40.0 - 54.0 |
| ● MCV | 89.7 fL | 80.0 - 96.0 |
| ● MCH | 30.3 pg | 27.0 - 31.0 |
| ● MCHC | 33.8 g/dL | 32.0 - 36.0 |
| ● Jumlah Trombosit | 249 10 ³ /ul | 150 - 400 |
| ● Laju Endap Darah | 10 mm/jam | 0 - 15 |
| ● Golongan Darah + Rhesus | | |
| ● Golongan Darah | A | |
| ● Rhesus | Positif | |
| ● ALT (SGPT) | 15 U/L | 0 - 45 |
| ● AST (SGOT) | 16 U/L | 13 - 33 |
| ● Gamma GT | 14 U/L | 5 - 86 |
| ● Trigliserida | 121 mg/dL | 50 - 150 |
| ● Kolesterol Total (H) | 215 mg/dL | 100 - 200 |
| ● HDL Direk | 49 mg/dL | >= 40 |
| ● LDL Direk (H) | 154 mg/dL | 0 - 130 |
| ● Glukosa Puasa | | |
| ● Glukosa Darah Puasa | 87 mg/dL | 60 - 100 |

| | | |
|--------------------------|---------------------------------|---|
| ● Kreatinin Darah | | |
| ● Kreatinin Darah | 0.92 mg/dL | 0.8 - 1.3 |
| ● eGFR | 99.4 mL/mnt/1.73 m ² | CKD EPI GFR Comment >= 60 Normal kidney function Reff : National Kidney Foundation, 2006 |
| ● Asam Urat | 6.4 mg/dL | 3.5 - 7.2 |
| ● Lengkap | | |
| ● Warna | kuning | Kuning |
| ● Kejernihan | jernih | Jernih |
| ● Berat Jenis | 1.015 | 1.005 - 1.030 |
| ● pH | 6.5 | 5.0 - 7.0 |
| ● Lekosit Esterase | Negatif /uL | Negatif |
| ● Nitrit | Negatif | Negatif |
| ● Protein | Negatif mg/dL | Negatif |
| ● Glukosa | Negatif mg/dL | Negatif |
| ● Keton | Negatif | Negatif |
| ● Urobilinogen | 0.6 mg/dL | 0.1 - 0.9 |
| ● Bilirubin | Negatif | Negatif |
| ● Darah Samar | Negatif /uL | Negatif |
| ● Sedimen | | |
| ● Eritrosit | 1 cells/uL | <3 |
| ● Lekosit | 4 cells/uL | <10 |
| ● Silinder | Negatif /lpk | |
| ● Sel Epitel | (+) | (+) |
| ● Kristal | Negatif | Negatif |
| ● Lain-lain | Negatif | |
| ● Analisa Faeces Lengkap | | |
| ● Warna | coklat | Coklat |
| ● Konsistensi | lembek | Lembek |
| ● Lendir | Negatif | Negatif |
| ● Darah | Negatif | Negatif |
| ● Mikroskopik | | |
| ● Eritrosit | 1 -3 /lpb | |

| | | |
|------------------|------------------------------------|---------|
| ● Leukosit | 2 - 5 /lpb | |
| ● Epitel | Positif /lpb | |
| ● Telur Cacing | Negatif | Negatif |
| ● Amoeba | Negatif | Negatif |
| ● Sisa Makanan | | |
| ● Amilum | Negatif | Negatif |
| ● Lemak | Negatif | Negatif |
| ● Serat Tumbuhan | Positif | Negatif |
| ● Darah Samar | Negatif | Negatif |
| ● pH | 7.0 | |
| ● Glukosa | Negatif | |
| ● Pewarnaan Gram | Ditemukan batang gram negatif | |
| ● Lain - lain | Negatif | |
| ● Keterangan | Tidak ditemukan kelaianan spesifik | |

Pemeriksaan Penunjang

| | |
|-------------------|--|
| ● Rontgen Thoraks | : Tidak tampak kelainan signifikan cor dan pulmo pada pemeriksaan saat ini |
| ● USG Abdomen | : Tidak tampak kelainan pada organ - organ intraabdomen yang tervisualisasi saat ini |
| ● Audiometri | : ADS Dalam Batas Normal |
| ● EKG | : Sinus Rythm Suspek Old Myocardial Infarction Anteroseptal |
| ● Treadmill | : Negative Ischemic Response |

Diagnosa

- Obesitas grade I
- Penurunan visus mata
- Buta warna parsial
- Perforasi membran timpani AS
- Kolesterol total dan LDL meningkat
- Abnormal EKG

Saran

- Olahraga rutin 5 kali seminggu dengan durasi masing-masing minimal 30 menit
- Periksa Mata Rutin
- Hindari pekerjaan yang membutuhkan ketelitian warna
- Diet rendah lemak atau kolesterol
- Treadmill test, Echocardiography, DSCT Cardiac

Konsultasi

- Konsultasi dokter Spesialis Mata
- Konsultasi dokter Spesialis THT
- Konsultasi dokter Spesialis Penyakit Dalam
- Konsultasi dokter Spesialis Jantung

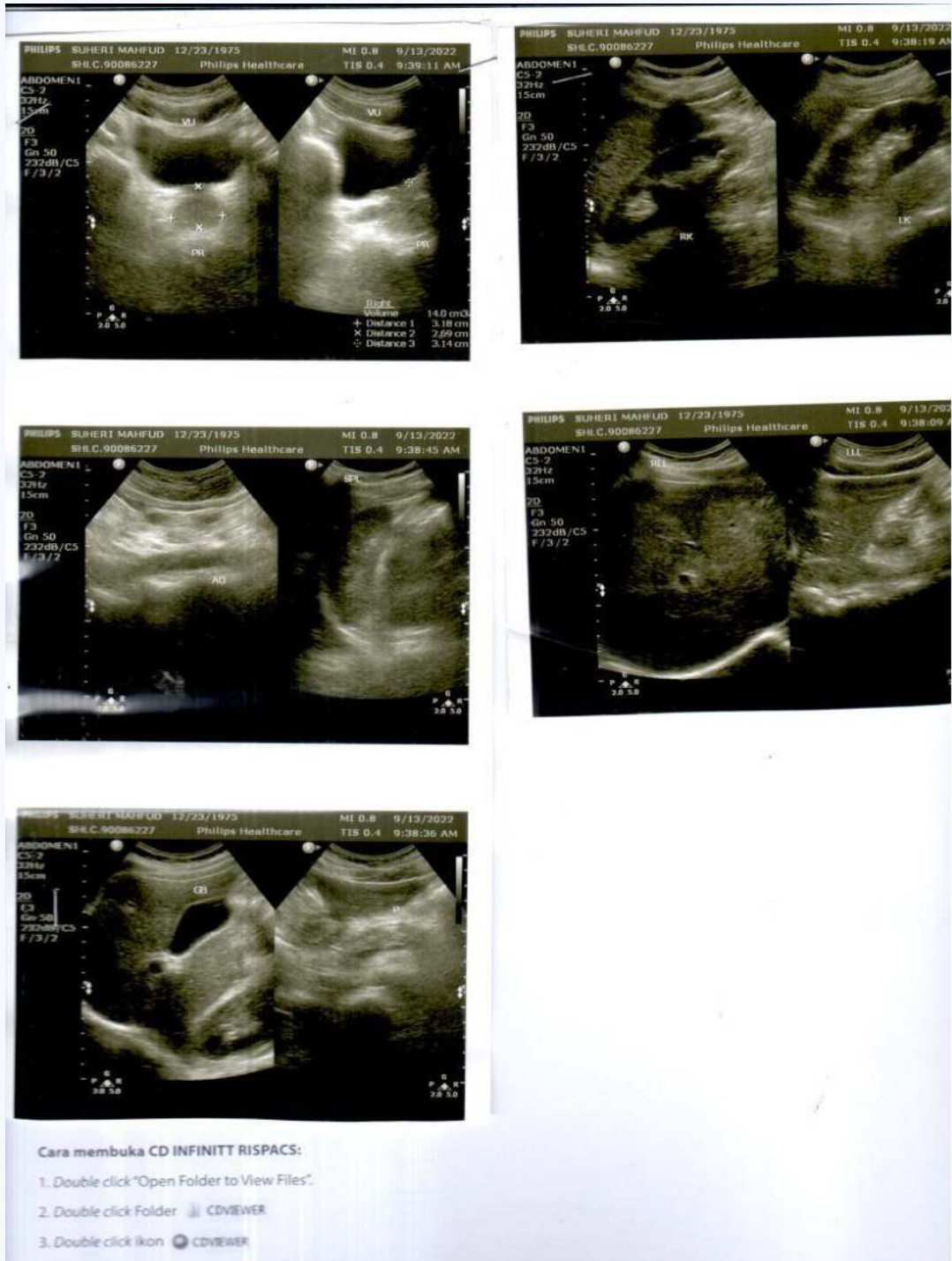
Kesimpulan

- Sementara Tidak Fit



dr. Julianto Kemala

USG Abdomen



Audiometri

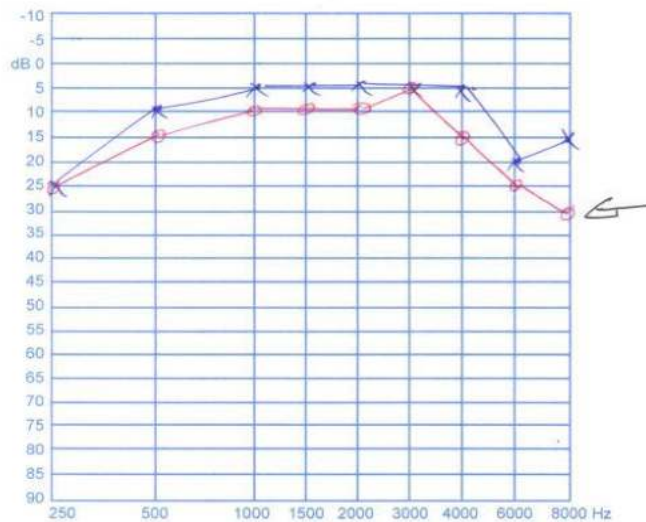


HASIL PEMERIKSAAN
AUDIOMETRI

SUHERI MAHFUD / Male / Ph: 081257760800
MR No: SHLC.90-08-82-27 / DOB: 23-Dec-1978 (48y 8m 21d)
CPA2209130024 / 13-Sep-2022 09:01

No: dr. Julianto Kamala / INSPEKTINDO SINERGI PERSADA PT

Name:



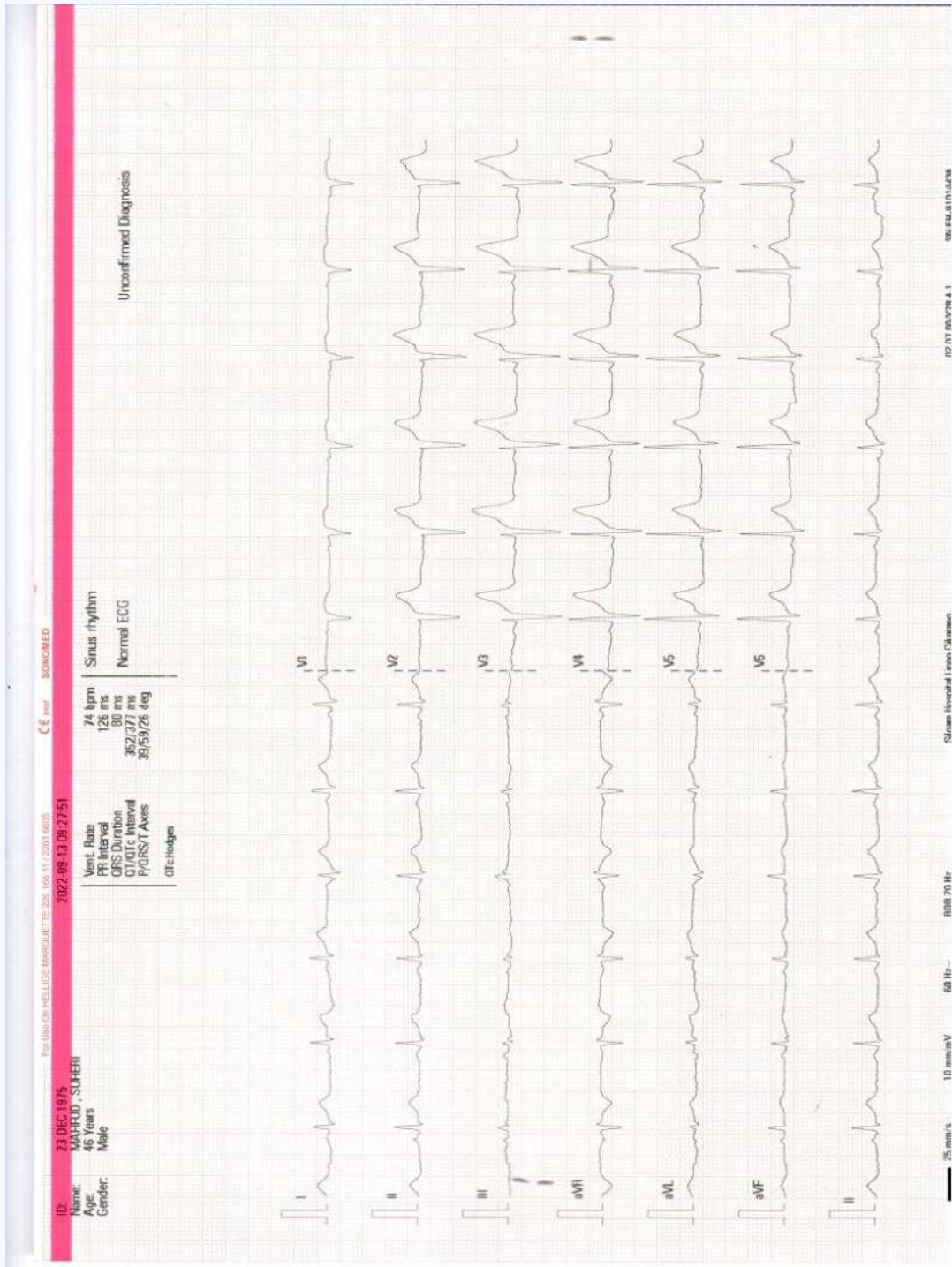
Handwritten signature

dr. Bambang Isti Santosa Sp. THT

LIPPO CIKARANG
Jl. M.H. Thamrin Kav. 105, Lippo Cikarang, Bekasi 17550
Telp. +6221 296-96-900, Fax +6221 296-96-969

AMA 33-0509

EKG 1



Treadmill 1

Page 1 / 1

Siloam Hospital Lippo Cikarang **Station**
Telephone: --

EXERCISE STRESS TEST REPORT

Patient Name: MAHFUD, SUHERI DOB: 23.12.1975
 Patient ID: 90086227 Age: 46 yrs
 Height: 155 cm Gender: Male
 Weight: 66 kg Race: Asian

Study Date: 13.09.2022 Referring Physician: dr. Christine Anita Sp,JP
 Test Type: Treadmill Stress Test Attending Physician: dr. Christine Anita Sp,JP
 Protocol: BRUCE Technician: Eko Susanto

Medications: --

Medical History: MCU

Reason for Exercise Test: MCU

Exercise Test Summary

| Phase Name | Stage Name | Time in Stage | Speed [km/h] | Grade [%] | HR [bpm] | BP [mmHg] | Comment |
|------------|------------|---------------|--------------|-----------|----------|-----------|---------|
| PRETEST | SUPINE | 01:51 | 0.00 | 0.00 | 103 | 110/70 | |
| | STANDING | 00:17 | 0.00 | 0.00 | 91 | 110/70 | |
| | HYPERV. | 00:03 | 0.00 | 0.00 | 90 | | |
| | WARM-UP | 00:39 | 1.60 | 0.00 | 94 | | |
| | STAGE 1 | 03:00 | 2.70 | 10.00 | 126 | 120/70 | |
| EXERCISE | STAGE 2 | 03:00 | 4.00 | 12.00 | 144 | 130/80 | |
| | STAGE 3 | 01:02 | 5.50 | 14.00 | 153 | 130/80 | |
| RECOVERY | | 00:59 | 1.40 | 0.00 | 134 | 130/80 | |


The patient exercised according to the BRUCE for 7:01 min:s, achieving a work level of Max. METS: 10.20. The resting heart rate of 82 bpm rose to a maximal heart rate of 155 bpm. This value represents 89% of the maximal, age-predicted heart rate. The resting blood pressure of 110/70 mmHg, rose to a maximum blood pressure of 130/80 mmHg. The exercise test was stopped due to --.

Interpretation
--

Conclusions
--

- Negative ischez respon
- Average fitness class

Physician Technician


dr. Christine Anita, SpJ
 Dokter Spesialis Jantung & Pembuluh Darah
 SIP 503/286/DPMP/Sp/2019
 SHI

Treadmill 2

| Phase Name | Stage Name | Time in Stage | Speed [km/h] | Grade [%] | Workload [METs] | HR [bpm] | BP [mmHg] | RPP [mmHg*bp /min] | VE [l/min] | ST Level [mV] | Comment |
|------------|------------|---------------|--------------|-----------|-----------------|----------|-----------|--------------------|------------|---------------|---------|
| PRETEST | SUPINE | 01:51 | 0.00 | 0.00 | 1.0 | 103 | 110/70 | 11330 | 0 | -0.10 | |
| | STANDING | 00:17 | 0.00 | 0.00 | 1.0 | 91 | 110/70 | 10010 | 0 | 0.00 | |
| | HYPERV | 00:03* | 0.00 | 0.00 | 1.0 | 90 | | 9900 | 0 | -0.05 | |
| | WARM-UP | 00:39 | 1.60 | 0.00 | 1.4 | 94 | | 10340 | 0 | -1.90 | |
| EXERCISE | STAGE 1 | 03:00 | 2.70 | 10.00 | 4.6 | 126 | 120/70 | 15120 | 0 | -0.85 | |
| | STAGE 2 | 03:00 | 4.00 | 12.00 | 7.0 | 144 | 130/80 | 18720 | 1 | 0.10 | |
| | STAGE 3 | 01:02 | 5.50 | 14.00 | 10.2 | 153 | 130/80 | 19890 | 0 | 0.10 | |
| RECOVERY | | 00:59 | 1.40 | 0.00 | 1.8 | 134 | 130/80 | 17420 | 0 | 0.00 | |

GE CASE V7.0 (10) Unconfirmed

Attend. MD: dr. Christine Anita Sp,JP

Page 1

MAHFUD, SUHERI
 Patient ID: 90086227
 13.09.2022
 13:07:02

Male 155 cm 66 kg
 46 yrs Asian
 Meds:

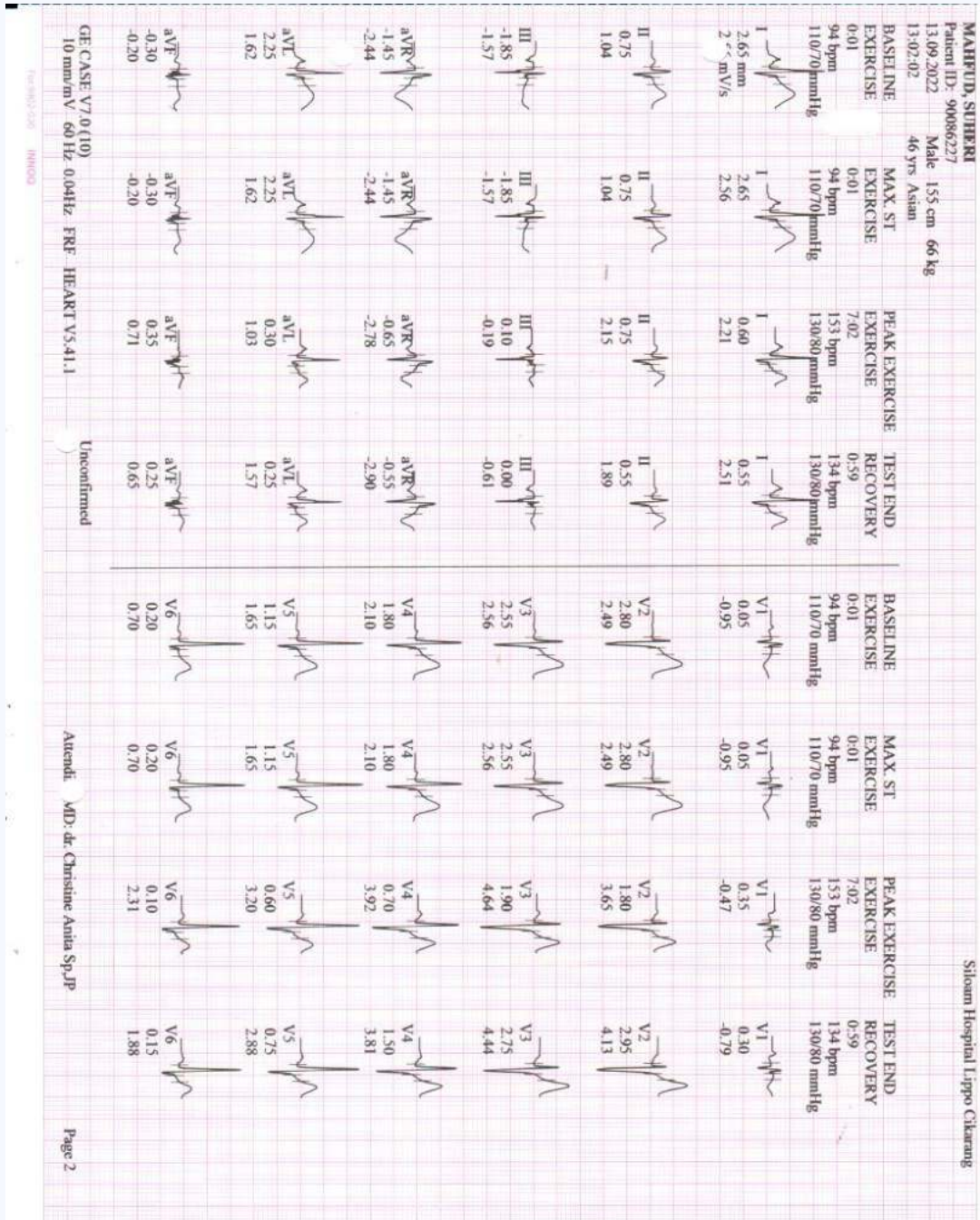
Test Reason: MCU
 Medical History: MCU

Ref. MD: dr. Christine Anita Sp,JP Ordering MD: dr. Christine Anita Sp
 Technician: Eko Susanto Test Type: Treadmill Stress Test
 Comment:

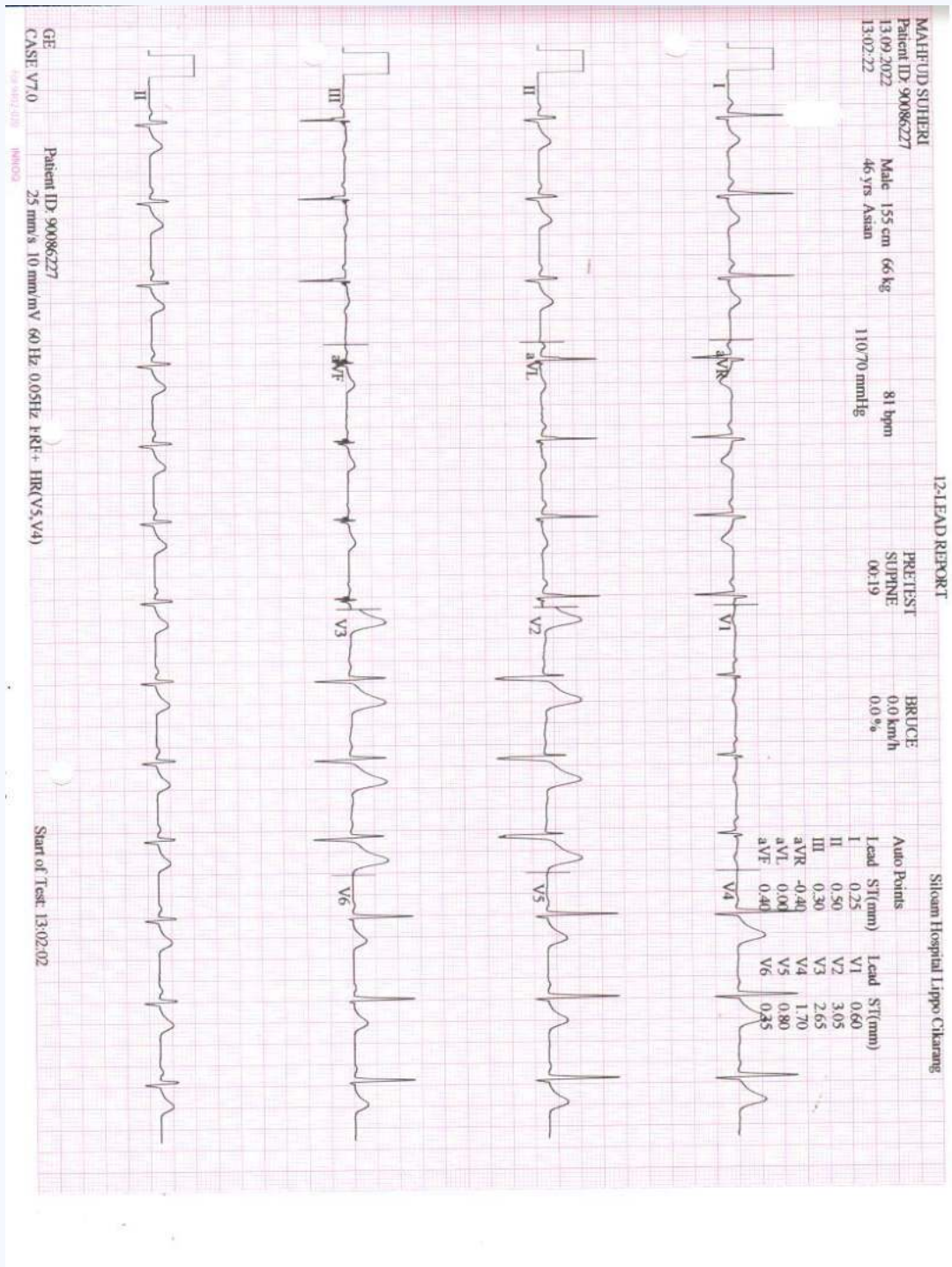
BRUCE: Exercise Time 07:01
 Max HR: 153 bpm 89 % of max predicted 174 bpm HR at rest: 82
 Max BP: 130/80 mmHg BP at rest: 110/70 Max RPP: 201.50 mmHg*bp/min
 Maximum Workload: 10.20 METS
 Max. ST: -1.85 mm, -1.57 mV/s in III: EXERCISE STAGE: 1 0-01
 Arrhythmia: A:5, PVC:10, PSVC:6
 HR reserve used: 70 %
 VE recovery: 19 bpm
 ST/HR hysteresis: 0.0000 mV
 VE recovery: 0 VE/min
 ST/HR duration: BASELINE: 88 ms, PEAK EX: 84 ms, REC.: 84 ms
 Room:
 Location: * 0 *

Siloam Hospital Lippo Cikarang

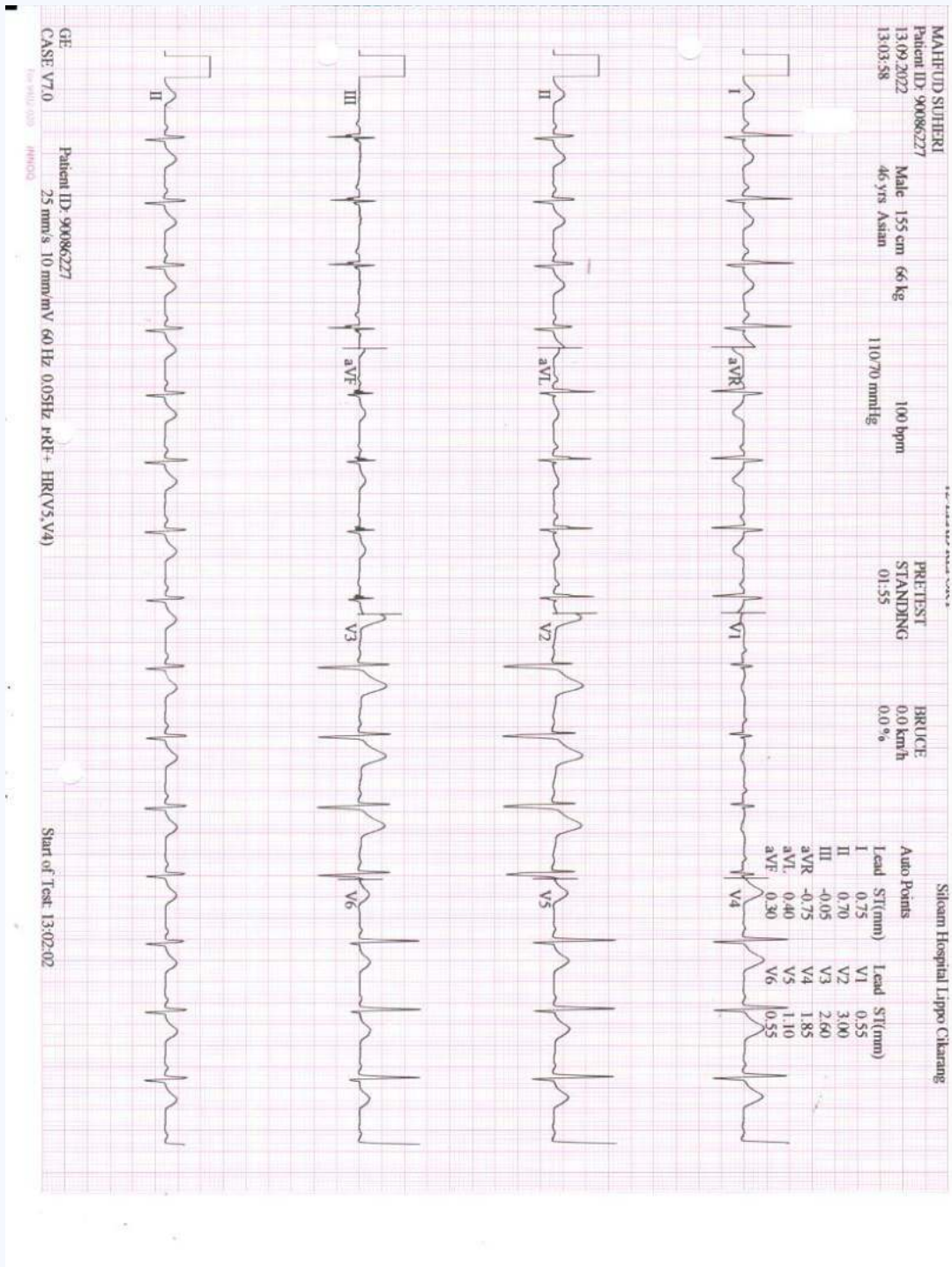
Treadmill 3



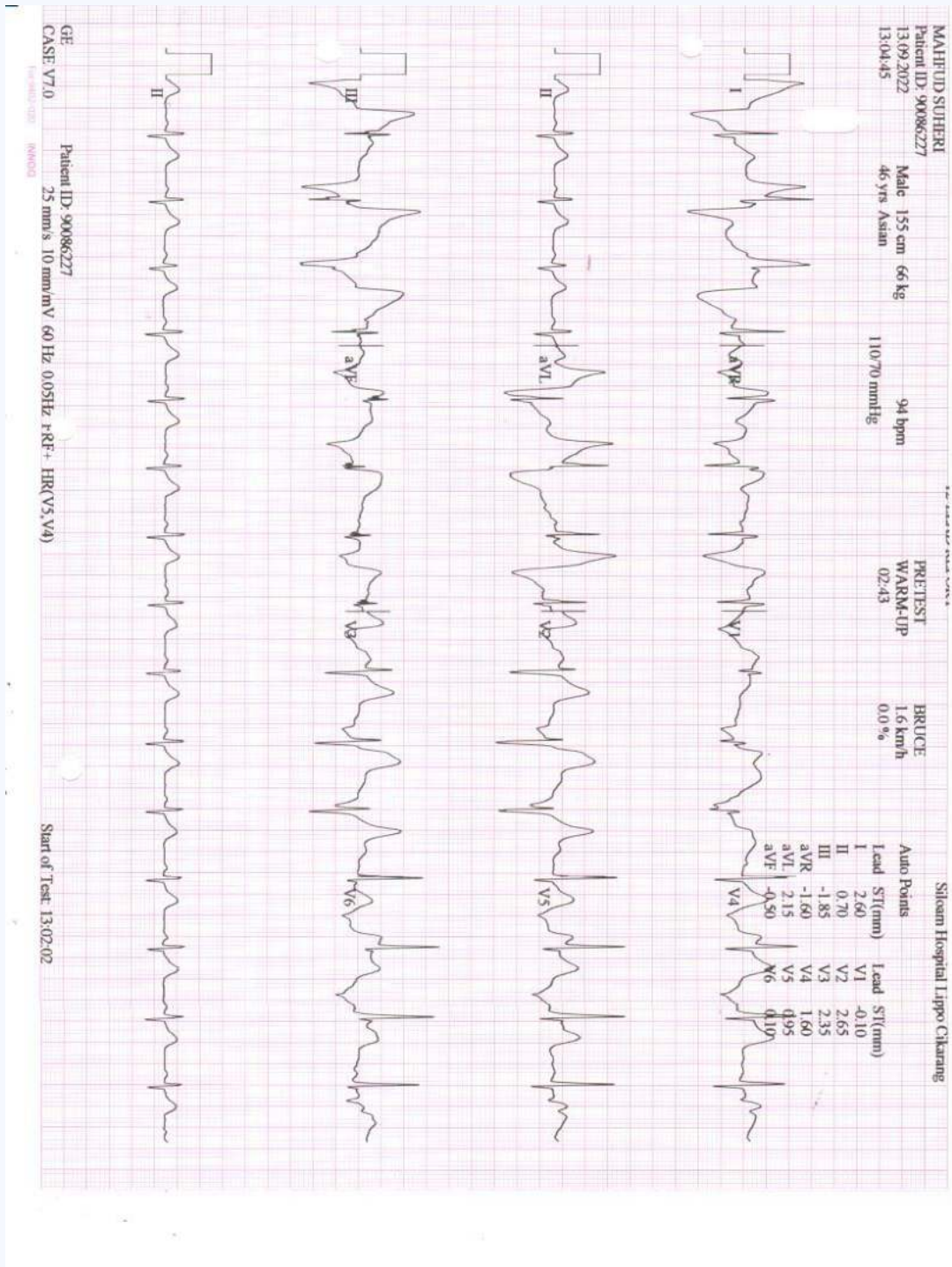
Treadmill 4



Treadmill 5

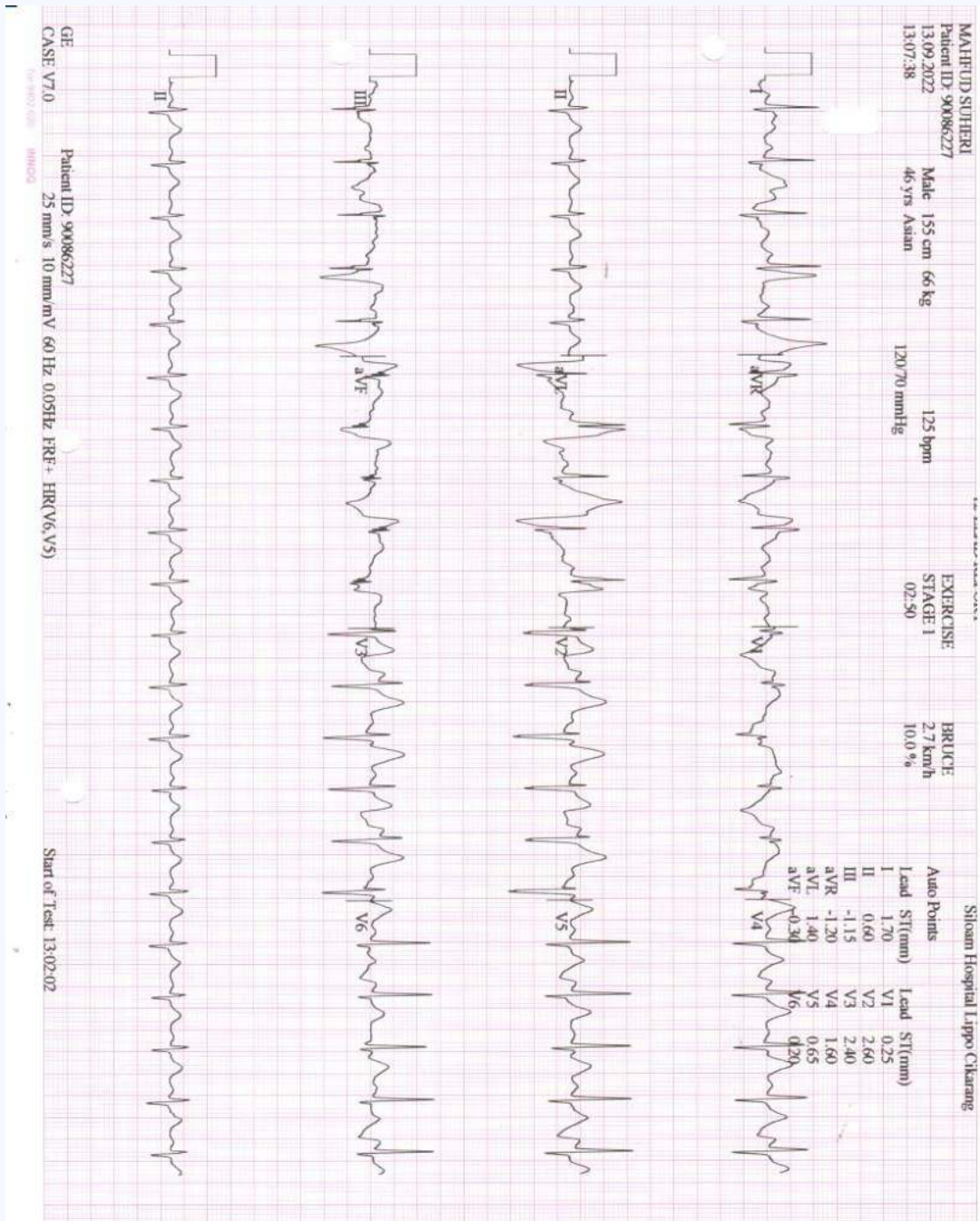


Treadmill 6



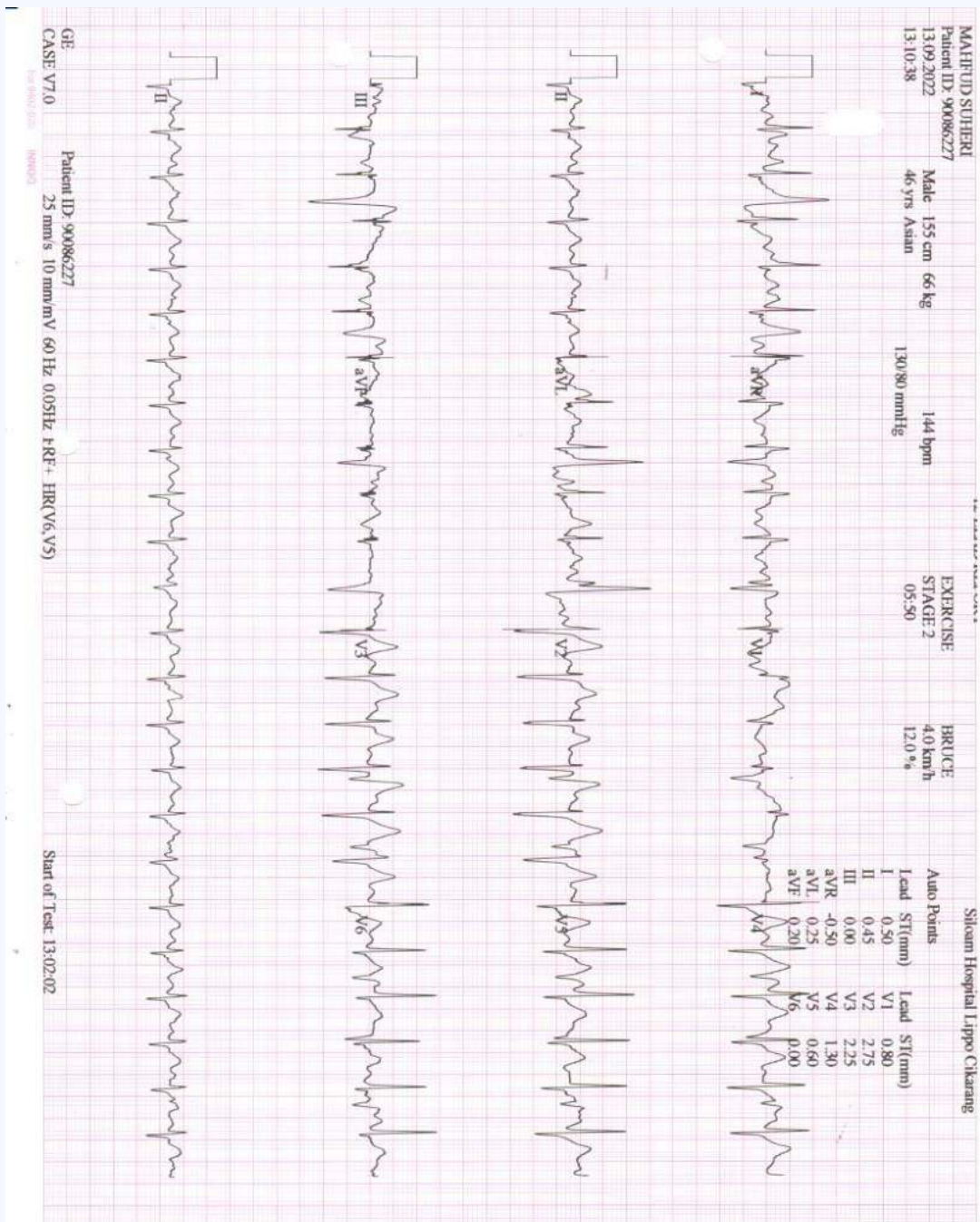
0

Treadmill 7

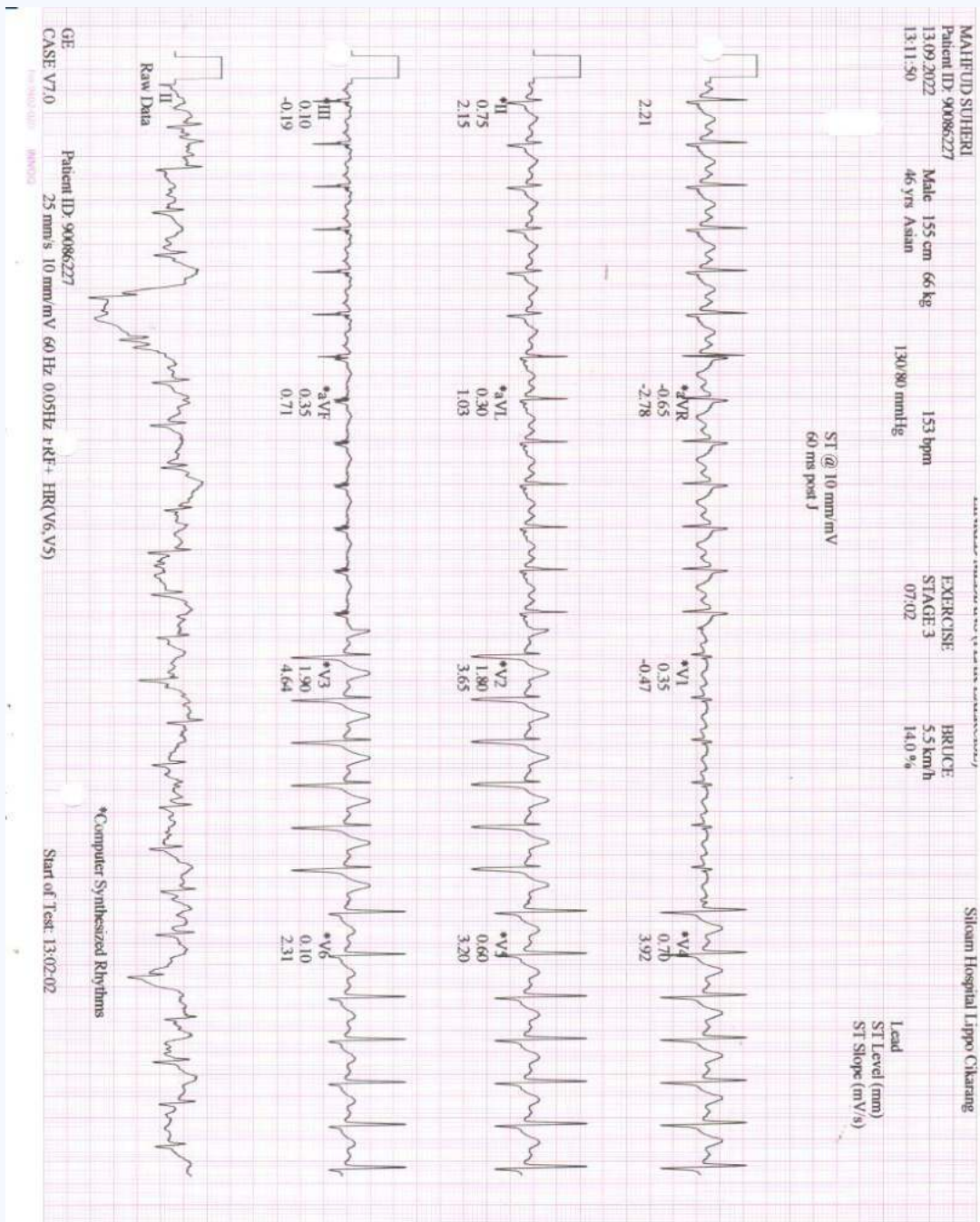


1

Treadmill 8

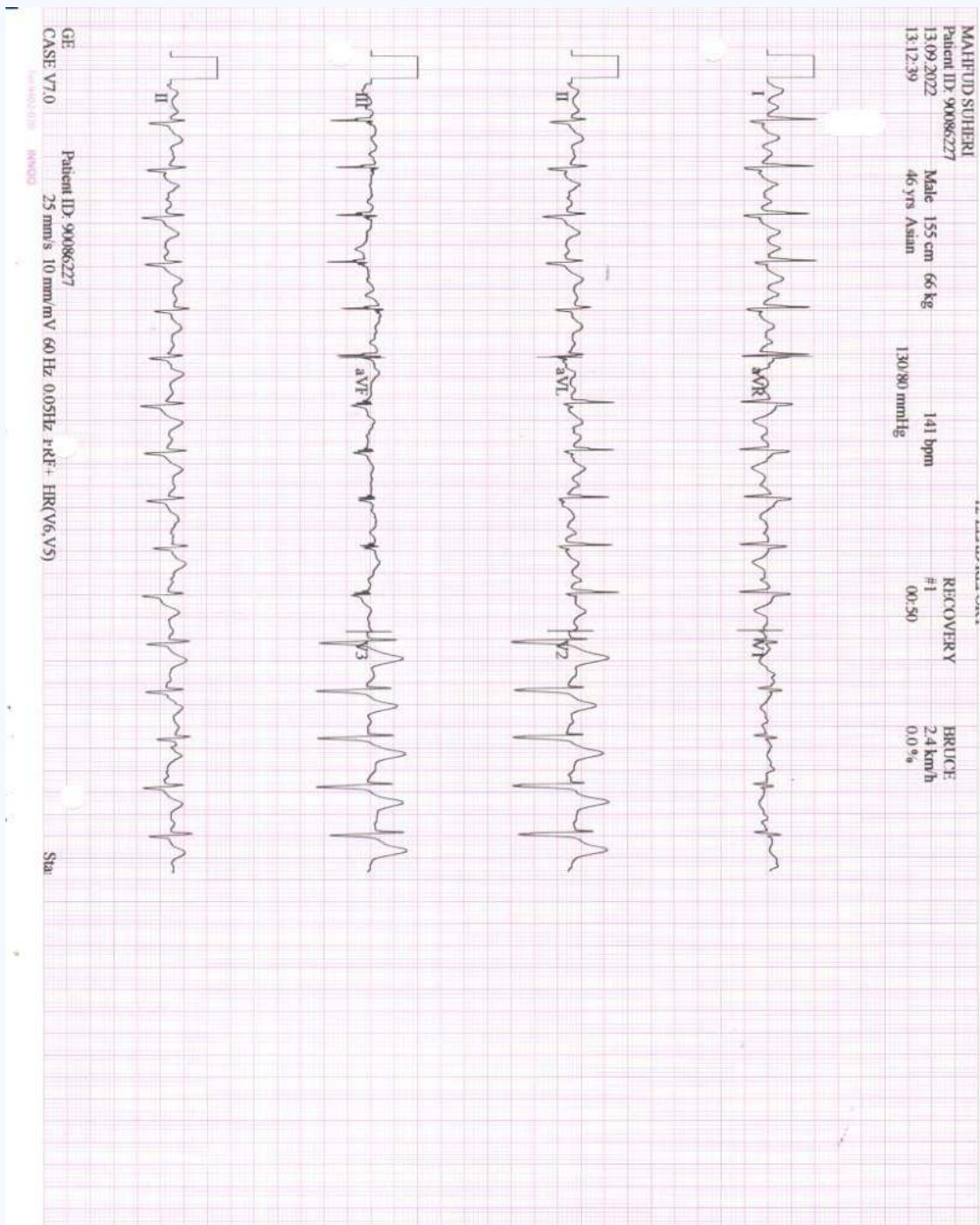


Treadmill 9



3

Treadmill 10



Teknik:

Thorax proyeksi PA

Temuan:

PARU: Normal

MEDIASTINUM: Normal

TRAKEA DAN BRONKUS: Normal

HILUS: Normal

PLEURA: Normal

DIAFRAGMA: Normal

JANTUNG: Normal CTR: <50%

AORTA: Normal

VERTEBRA THORAKAL DAN TULANG-TULANG LAINNYA: Normal

JARINGAN LUNAK: Normal

ABDOMEN YANG TERVISUALISASI: Normal

LEHER YANG TERVISUALISASI: Normal

==== [Conclusion] =====

Kesan:

Tidak tampak kelainan signifikan cor dan pulmo pada pemeriksaan saat ini.

Teknik:

USG whole abdomen

Temuan:

HEPAR: Normal

LIEN: Normal

SISTEM VENA PORTA: Normal

VENA CAVA INFERIOR, VENA HEPATIKA: Normal

SISTEM BILIER: Normal

KANTUNG EMPEDU: Normal

PANKREAS: Normal

GINJAL:

- KANAN: Normal

- KIRI: Normal

SISTEM PELVIOKALISES: Normal

BULI-BULI: Normal

KELENJAR GETAH BENING: Tidak tampak membesar

CAIRAN BEBAS: Tidak ditemukan

PROSTAT: Normal

VESIKULA SEMINALIS: Normal

===== [Conclusion] =====

Kesan:

Tidak tampak kelainan pada organ intraabdomen yang tervisualisasi saat ini

