

Certificate Of Health Assessment

Name	Age	Position	Department
ALI MUSA SIAGIAN	43 yo	INSPECTOR	-

COMPANY :

INSPEKTINDO SINERGI PERSADA



CONCLUSION

FIT TO WORK

FIT WITH MEDICAL NOTE

TEMPORARY UNFIT

UNFIT

Issued Date	Doctors Name	Prepared By
08 February 2020	Shezarina Pratita, MD PKTK : B.1537/BINWASK3-PNK3/KK/V/2019 SIP : 4/B.15a/31.74.01.1004/-1.779/e/2019	
Expired Date		Verified By
08 February 2021	dr. Muhammad Ilyas, Sp.Ok SIP : 29/B.15b/31.74.04.1004.02.009.K.1/3/-1.779.3/e/2019	

No. Formulir : FM-DR-008-05

No. Revisi : 00

Tanggal Terbit : 2 Mei 2011

Certificate Number : MP-WTC2/2-20200208/1008

MCU Validity Check

<https://mcu-validasi.medikaplaza.com>

TO WHOM IT MAY CONCERN

Kepada yang berkepentingan

This is certify that today Saturday, 08 February 2020 Medika Plaza Clinic has performed urine drug screening and/or breath alcohol test to :


Dengan ini menyatakan bahwa, pada hari ini Sabtu, 08 Februari 2020 Medika Plaza Clinic telah melakukan urine drug screening dan/atau breath alcohol test kepada :

ALI MUSA SIAGIAN

With the results are as follows :
Dengan hasil sebagai berikut :

Drugs Test <i>Uji Obat</i>	Result <i>Hasil</i>		
URINE DRUGS SCREENING			
- Amphetamine	<input type="checkbox"/> Non-Negative	<input checked="" type="checkbox"/> Negative	<input type="checkbox"/> N/A
- Met-Amphetamine	<input type="checkbox"/> Non-Negative	<input checked="" type="checkbox"/> Negative	<input type="checkbox"/> N/A
- Cocain	<input type="checkbox"/> Non-Negative	<input checked="" type="checkbox"/> Negative	<input type="checkbox"/> N/A
- THC/Canabis/Marijuana	<input type="checkbox"/> Non-Negative	<input checked="" type="checkbox"/> Negative	<input type="checkbox"/> N/A
- Morphine/Opiates	<input type="checkbox"/> Non-Negative	<input checked="" type="checkbox"/> Negative	<input type="checkbox"/> N/A
- P C P/Phencyclidine	<input type="checkbox"/> Non-Negative	<input checked="" type="checkbox"/> Negative	<input type="checkbox"/> N/A
- Barbiturate	<input type="checkbox"/> Non-Negative	<input type="checkbox"/> Negative	<input checked="" type="checkbox"/> N/A
- Benzodiazepin	<input type="checkbox"/> Non-Negative	<input checked="" type="checkbox"/> Negative	<input type="checkbox"/> N/A
- Methadone	<input type="checkbox"/> Non-Negative	<input checked="" type="checkbox"/> Negative	<input type="checkbox"/> N/A
- Propoxyphene	<input type="checkbox"/> Non-Negative	<input type="checkbox"/> Negative	<input checked="" type="checkbox"/> N/A
- Oxycodone	<input type="checkbox"/> Non-Negative	<input type="checkbox"/> Negative	<input checked="" type="checkbox"/> N/A
- MDMA	<input type="checkbox"/> Non-Negative	<input type="checkbox"/> Negative	<input checked="" type="checkbox"/> N/A
- 6-MAM	<input type="checkbox"/> Non-Negative	<input type="checkbox"/> Negative	<input checked="" type="checkbox"/> N/A
BREATH ALCOHOL TEST			
- Alcohol	<input type="checkbox"/> Non-Negative	<input checked="" type="checkbox"/> Negative	<input type="checkbox"/> N/A

Jakarta, February 08, 2020


 (dr. Vivi Surjaningsih, Sp.PK)
 Clinical Patologist

HEALTH ASSESSMENT REPORT

Of

ALI MUSA SIAGIAN
01071287

Saturday, 08 February 2020

MP WTC 2 CLINIC

World Trade Centre 2, Lower Ground Floor
Jl. Jend. Sudirman, Kav. 29 Jakarta Selatan 12920
Tlp : (62-21) 295 22 610, Fax : (62-21) 295 22 611
www.medikaplaza.com

MP WTC 2 CLINIC

World Trade Centre 2, Lower Ground Floor
Jl. Jend. Sudirman, Kav. 29 Jakarta Selatan 12920
Tlp : (62-21) 295 22 610, Fax : (62-21) 295 22 611
www.medikaplaza.com

PATIENT DATA

MedRec. : 01071287	EMPLOY. STATUS : Employee
NAME : ALI MUSA SIAGIAN	BIRTHDATE : 15 October 1976
EMPLOYEE No. : -	SEX : Male
JOB TITLE : INSPECTOR	STATUS : Married
COMP. NAME : INSPEKTINDO SINERGI PERSADA	NASIONALITY : INDONESIA

SUMMARY

MEDICAL FINDING :

1. Hypertriglyceridemia
2. Hyperuricemia
3. Increased Gamma GT
4. Non reactive Anti HBs
5. Decreasing of visual acuity of both eyes
6. Decreasing of hearing acuity on high frequency of left ear
7. ECG : VES benign
8. Abdominal USG: Multiple cholelithiasis
9. Overweight
10. Decayed, radix and calculus teeth

Your fitness status is fit with medical note:

1. ECG : VES benign
2. Abdominal USG: Multiple cholelithiasis

SUGGESTION :

1. Low fat and carbohydrate diet, exercise regularly minimal 3 times a week.
2. Low purine diet such as meats including organ meats, alcoholic beverages, beans, shrimp, scallops, some vegetables in limited amount such as: spinach, cauliflower, asparagus and mushroom
3. Take enough rest minimal 8 hours/day. Repeat liver function examination 1 month later and consult to an Internist if still increase
4. Need to get Hepatitis B vaccination
5. You need to wear glasses for near vision
6. Avoid noisy environment and use earplug properly while working at noisy work environment to prevent further hearing impairment
7. Consultation with a Cardiologist for further evaluation of ECG : VES benign
8. Consultation with an Internist / Surgeon for further evaluation of Abdominal USG: Multiple cholelithiasis
9. Reduce body weight gradually 0.5 Kgs/week, by doing regular exercise (aerobic/jogging), 3-4x/week, 30-45 minutes and reduce high calorie diet until maximal body weight is 65.61 Kgs (present body weight is 73.2 Kgs). Consultation with a Nutritionist for evaluation of overweight
10. Consultation with a Dentist for dental care, minimal once a year or better once in six month

PERCEPTIONS OF EXPOSURE BY WORKERS :

- Noise (Sometimes)
- Others (Inspector)

Responsible Doctor



Shezarina Pratna MD

Notes:

If you need the further information or consultation, please contact us via :

Email : - dr.yosephine@medikaplaza.com

- dr.yunianti@medikaplaza.com

Telepon Klinik : (62-21) 295 22 610

CLINICAL EVALUATION

Name : ALI MUSA SIAGIAN

Sex : Male

MR : 01071287

Visit : 08/02/2020

Comp.: INSPEKTINDO SINERGI PERSADA

DOB : 15 October 1976

EXAMINATION**RESULT****NOTES****ANAMNESA****PRESENT COMPLAINT AND HISTORY OF PRESENT****ILLNESS**

Present complaint

No complaint

MEDICAL HISTORY

Alergy

No

Imunisasi

No

Surgery

Yes

Soft tissue extraction, 2007

Hospitalization

Yes

Soft tissue extraction

Disease

No

LIFE STYLE

Alcohol intake

No

Smoking

No

Exercise

Yes

Everyday, walking

FAMILY MEDICAL HISTORY

Diabetes Melitus

No

Hypertension

No

Heart disease

No

Lung TB

No

Kidney disease

No

Astma

No

Mental disease

No

Epilepsy

No

Cancer

No

Color blind

No

Stroke

No

Liver disease

No

Bone & joint

No

Others disease

No

WORK EXPOSURE

Noise

Yes

Sometimes

Heat Stress

No

Cold Stress

No

Vibration

No

Involving height

No

Radiation

No

Dust

No

CLINICAL EVALUATION

Name : ALI MUSA SIAGIAN	Sex : Male	MR : 01071287	Visit : 08/02/2020
Comp.: INSPEKTINDO SINERGI PERSADA		DOB : 15 October 1976	

EXAMINATION	RESULT	NOTES
-------------	--------	-------

Toxic chemical	No	
Irritating fluid	No	
Smoke	No	
Bacterium/Virus/Parasite	No	
Blood	No	
Animal	No	
Operating heavy mobile equipment	No	
Manual Handling	No	
Sitting continuously over 4 hours	No	
Stand continuously over 4 hours	No	
Using monitor screen more than 4 hours per day	No	
Exposure	No	
Unergonomic body positions	No	
Shift work	No	
Work is not accordance with skills and knowledge	No	
Workload does not accordance with time	No	
Work conflict	No	
Inappropriate task	No	
Career barriers	No	
Family conflict	No	
Working arround rotating machinery	No	
Administration work	No	
Handling food product	No	
Others	Yes	Inspector

PHYSICAL EXAMINATION

General Appearance	Good
Body shape	Picnicus

VITAL SIGN

Body Weight	73.2 Kg
Body Height	162 Cm
BMI	27.89 Kg/m ²
Normal Weight	48.55 - 65.61 Kg
BMI Conclusion	Overweight
Blood Pressure	120/80 mmHg
Pulse	80 x/minute
Body Temperature	36.6 °C
RR	18

CLINICAL EVALUATION

Name : ALI MUSA SIAGIAN	Sex : Male	MR : 01071287	Visit : 08/02/2020
Comp. : INSPEKTINDO SINERGI PERSADA		DOB : 15 October 1976	

EXAMINATION	RESULT	NOTES
Neck Circumference	39 Cm	
Arm Circumference	32 Cm	
Chest size	101 Cm	
Abdominal Circumference	92 Cm	
SKIN		
Skin	Normal	
EYE		
Left	Normal	
Right	Normal	
ENT		
Auricle	Normal	
Ear canal	Normal	
Drums	Normal	
Septum/Conchae	Normal	
Sinuses	Normal	
Pharynx	Normal	
Tonsil	Normal	
MOUTH		
Gum	Normal	
Dental	Abnormal	Decayed, radix and calculus teeth
NECK		
General	Normal	
Thyroid Gland	Normal	
CHEST		
Form	Normal	
Lung	Normal	
Heart	Normal	
Breast	Normal	
ABDOMEN		
Form	Flat	
Palpation	Supple	
Liver	Not Palpable	
Spleen	Not Palpable	
Kidney	No Ballotment	
-	No	
Hernia inguinal	No	
EXTRIMITIES		

CLINICAL EVALUATION

Name : ALI MUSA SIAGIAN	Sex : Male	MR : 01071287	Visit : 08/02/2020
Comp. : INSPEKTINDO SINERGI PERSADA		DOB : 15 October 1976	

EXAMINATION	RESULT	NOTES
Bones, joint	Normal	
Muscles, tonus	Normal	
Fingernails	Normal	
Hand	Normal	
Foot	Normal	
RECTAL EXAMINATION		
Hemorrhoid	Negative	
Rectum	Normal	
SENSORIK EXAMINATION		
Tes Raba	Normal	
MOTORIK EXAMINATION		
Tes Grip	Normal	
REFLEX EXAMINATION		
Physiologic reflex	Normal	
Patologic reflex	Normal	
OTHERS EXAMINATION		
Coordination	Normal	
LYMPHE SYSTEM		
Submandibula	Normal	
Neck Gland	Normal	
Armpit gland	Normal	
Inguinal	Normal	

OPHTHALMOLOGY DIAGNOSTIC

Name : ALI MUSA SIAGIAN	Sex : Male	MR : 01071287	Visit : 08/02/2020
Comp.: INSPEKTINDO SINERGI PERSADA		DOB : 15 October 1976	

EXAMINATION		Right	Left
Reading		-	
Previous Glasses		-	-
Without Glasses	Distant	20/20	20/20
	Near	J2	J2
Correction	Distant	-	-
	Near	S+1.25 J1	S+1.25 J1
		-	
Tonometry		19.0 mmHg	19.0 mmHg
Funduscopy		NORMAL	NORMAL
Visual Fields		Normal	
Colour Blind Test		Normal	

Impression : Presbyopia

RADIOLOGY DIAGNOSTIC

Name : ALI MUSA SIAGIAN

Sex : Male

MR : 01071287

Visit : 08/02/2020

Comp.: INSPEKTINDO SINERGI PERSADA

DOB : 15 October 1976

EXAMINATION

RESULT

THORAX PA

No abnormality seen in both lungs.
Normal bronchovascular markings in both hili.
The heart is normal in size and shape.
The mediastinum is not widened.
Both sinuses and diaphragms are good.
No evidence of pleural effusion.
No abnormality of chest skeletal.

Impression

Normal Chest x-ray

RADIOLOGY DIAGNOSTIC

Name : ALI MUSA SIAGIAN

Sex : Male

MR : 01071287

Visit : 08/02/2020

Comp.: INSPEKTINDO SINERGI PERSADA

DOB : 15 October 1976

EXAMINATION

RESULT

USG ABDOMEN

LIVER:

Normal in size and contour, smooth surface. Normal echoes structure parenchymal which are homogeneous. No sign of SOL.

Intrahepatic vascularity and billiary tract are normal.

GALL BLADDER:

Normal in size, contour and surface. There is multiple hiperechoic lession with shadowing (greatest measurement +/- 0.55 cm)

RIGHT KIDNEY :

Normal in size, contour and surface. No sign of obstruction/ stone/ SOL.

LEFT KIDNEY:

Normal in size, contour and surface. No sign of obstruction/ stone/ SOL.

PANCREAS:

Normal in size, contour and surface. No sign of SOL.

LIEN:

Normal in size and contour, the echoes are homogeneous. No sign of SOL.

URINARY BLADDER:

Normal in size, contour and surface. No sign of stone/ SOL.

PROSTATE AND VESICULA SEMINALIS:

Normal in size and contour which are homogeneous echoes and no sign of focal lesion/ SOL.

Impression

Multiple cholelithiasis

LABORATORY RESULT

Name : ALI MUSA SIAGIAN

MR : 01071287

Visit : 08/02/2020

#Lab : IN694727671008

Comp. : INSPEKTINDO SINERGI PERSADA

Sex : Male

DOB : 15 October 1976

EXAMINATION**RESULT****NORMAL RANGE****HEMATOLOGI**

ABO/Rh Typing

"A" Rh(+) positive

Automated Blood Count

White Blood Cell (WBC)

6.5

3.8 - 11.0

Erythrocyte (RBC)

5.1

4.4 - 5.9

Haemoglobin

15.3

13.2 - 17.3

Hematocrit

45

40 - 52

Thrombocytes

267

150 - 440

MCV, MCH, MCHC

MCV

87

80 - 100

MCH

30

26 - 34

MCHC

34.3

32 - 36

ESR

18 *

0 - 10

Differential Count

Granulosit

58.0

50.0 - 70.0

Limfosit

30

20 - 40

Mid Cell

12

3 - 15

BLD CHEMISTRY/LIPID PROFILE

Total Cholesterol

180

Normal/Desireable: <200

Borderline High: 200-239

High: >=240

HDL Cholesterol

42.4

Normal : >40 - <60

Low HDL : <40

Desireable : >=60

LDL Cholesterol

100

Optimal: <100

Near/Above Optimal: 100-129

Borderline High: 130-159

High: 160-189

Very High: >=190

Triglycerides

186 *

Normal : <150

Borderline High: 150-199

High : 200-499

Very High : >=500

BLD CHEMISTRY/KIDNEY FUNCTION

Ureum

30.0

10.0 - 50.0

Creatinine

0.8

0.6- 1.3

Uric Acid

8.30 *

3.50 - 7.20

LABORATORY RESULT

Name : ALI MUSA SIAGIAN

MR : 01071287

Visit : 08/02/2020

#Lab : IN694727671008

Comp. : INSPEKTINDO SINERGI PERSADA

Sex : Male

DOB : 15 October 1976

EXAMINATION	RESULT	NORMAL RANGE
-------------	--------	--------------

BLD CHEMISTRY/LIVER FUNCTION

Total Bilirubin	0.47	0.1 - 1.0
Direct Bilirubin	0.16	0.0 - 0.2
Indirect Bilirubin	0.31	0.0 - 0.8
SGOT(AST)	27	13 - 45
SGPT (ALT)	50	13 - 50
Alkaline Phosphatase	45	30 - 120
Gamma GT	93 *	0 - 50
Albumin	4.5	3.5 - 5.5
Globulin	2.90	2.3 - 3.5
Total Protein	7.4	6.6 - 8.7

BLD CHEMISTRY/DIABETES

Glucose Fasting	94	< 100
Glucose Urine	Negative	Negative
Keton Urine	Negative	Negative

Blood Glucose 2 PP

Blood Sugar 2 Hours PP	82	< 140
Glucose Urine	Negative	Negative
Keton Urine	Negative	Negative

SEROLOGI / IMUNOLOGI

HBsAg (Qualitative)	Non Reactive	Non Reactive
Anti HBs (Qualitative)	Non Reactive	

TOXICOLOGY - DRUGS SCREENING

Methadone	Negative	Negative
Phencyclidine	Negative	Negative
THC/Marijuana	Negative	Negative
Amphetamine	Negative	Negative
Benzodiazepines	Negative	Negative
Opiat	Negative	Negative
Cocain	Negative	Negative
Metamphetamine	Negative	Negative
Alcohol	Negative	Negative

URINALYSIS**Complete Urine Analysis****Macroscopic**

Color	Yellow	
Turbidity	Clear	Clear

LABORATORY RESULT

Name : ALI MUSA SIAGIAN

MR : 01071287

Visit : 08/02/2020

#Lab : IN694727671008

Comp. : INSPEKTINDO SINERGI PERSADA

Sex : Male

DOB : 15 October 1976

EXAMINATION	RESULT	NORMAL RANGE
Specific Gravity	1.015	1.000 - 1.030
pH	6.0	4.5 - 8.0
Leucocyte	Negative	Negative
Glucose	Negative	Negative
Nitrit	Negative	Negative
Bilirubin	Negative	Negative
Blood	Negative	Negative
Urobilinogen	Normal	Normal
Protein	Negative	Negative
Keton	Negative	Negative

Microscopic

RBC	0-1	0 - 1
WBC	0-1	0 - 4
Cylinder	Negative	
Epithels Squamous	0-1	5 - 15
Crystals	Negative	
Bacteria	Negative	Negative
Others	Negative	

STOOL / RECTAL SWAP**Faeces Complete****Macroscopic**

Color	Brown	
Consistency	Smooth	
Mucus	Negative	Negative
Blood	Negative	Negative
Pus	Negative	Negative
Parasitologi Faeces	Negative	Negative
Lipid	Negative	Negative

Microscopic

RBC	0-1	0 - 1
WBC	0-1	0 - 5
Amoeba	Negative	
Ephitels	Positive	Positive
Worm Eggs	Negative	Negative
Yeast	Negative	Negative
Muscle Fiber	Negative	Negative
Others	Negative	Negative

LABORATORY RESULT

Name : ALI MUSA SIAGIAN	MR : 01071287	Visit : 08/02/2020	#Lab : IN694727671008
Comp. : INSPEKTINDO SINERGI PERSADA	Sex : Male	DOB : 15 October 1976	

EXAMINATION	RESULT	NORMAL RANGE
-------------	--------	--------------

Digestive

Amylum	Negative	Negative
Fat	Negative	
Fibers	Positive	Positive

SPIROMETRY DIAGNOSTIC

Name : ALI MUSA SIAGIAN	Sex : Male	MR : 01071287	Visit : 08/02/2020
Comp. : INSPEKTINDO SINERGI PERSADA		DOB : 15 October 1976	

EXAMINATION	RESULT
FVC Result	: 3.41 L---> 92.2 %
FEV1 Result	: 8.83 L---> 89.8 %
FEV1/FVC Result	: 82.99 %---> 109.6 %
PEF Result	: 5.97 L/S---> 58.6 %
Indonesian Standart Result	:
Index	:
Spirometry Result	: Normal

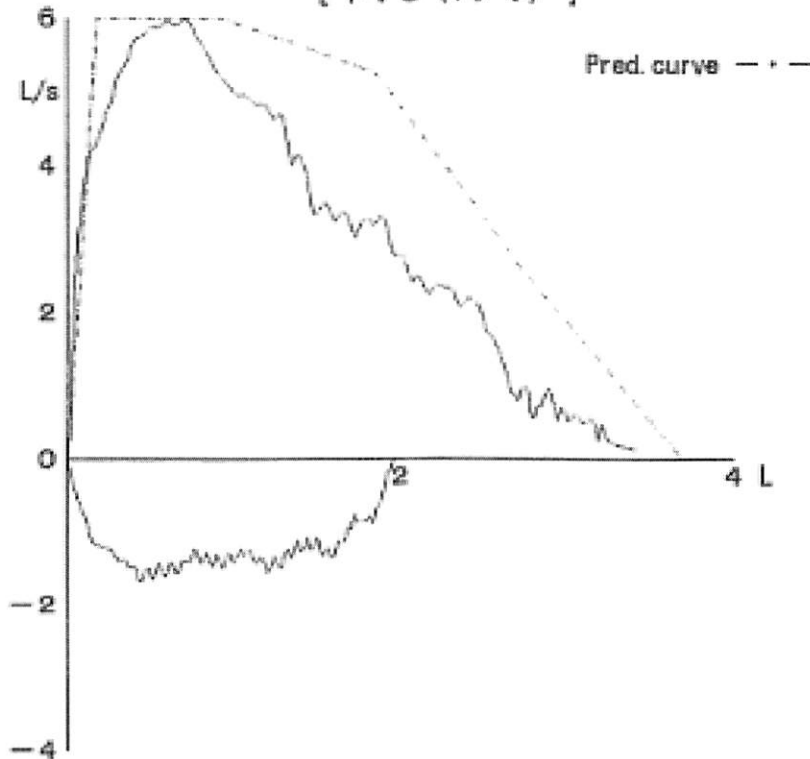
Impression : Normal Spirometric Functions

[GOLD CLASSIFICATION]

FEV1/FVC : 82.99 %
 %FEV1.0 : 89.80 %
 Stage : Normal
 Recommended treatment by GOLD:

Ali musa S
01071287

[FVC (F/V)]



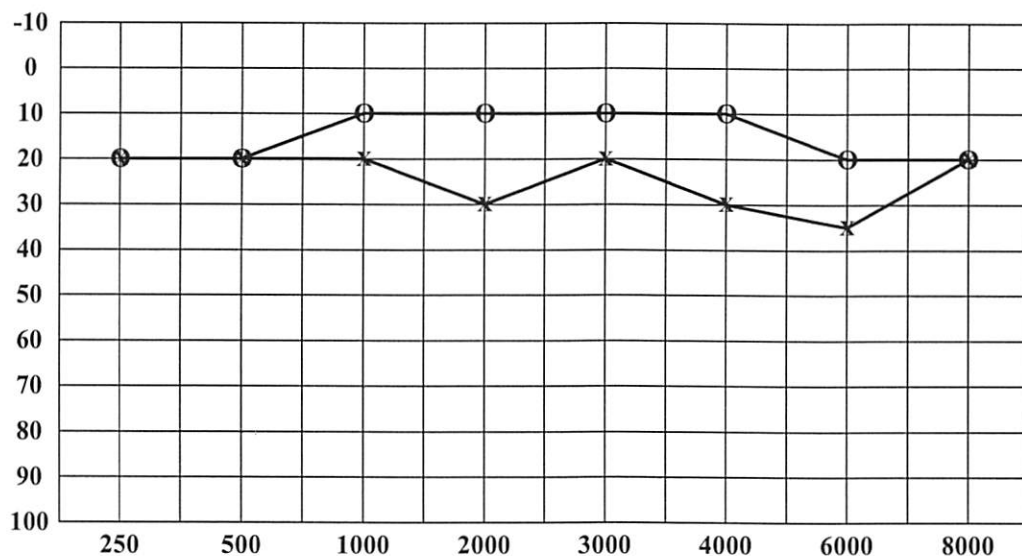
AUDIOMETRY DIAGNOSTIC

Name : ALI MUSA SIAGIAN	Sex : Male	MR : 01071287	Visit : 08/02/2020
Comp. : INSPEKTINDO SINERGI PERSADA		DOB : 15 October 1976	

RESULT

Left Ear	250	500	1000	2000	3000	4000	6000	8000
AC	20	20	20	30	20	30	35	20
BC	-	-	-	-	-	-	-	-

Right Ear	250	500	1000	2000	3000	4000	6000	8000
AC	20	20	10	10	10	10	20	20
BC	-	-	-	-	-	-	-	-



< : Right Ear (BC)
 > : Left Ear (BC)
 O : Right Ear (AC)
 X : Left Ear (AC)

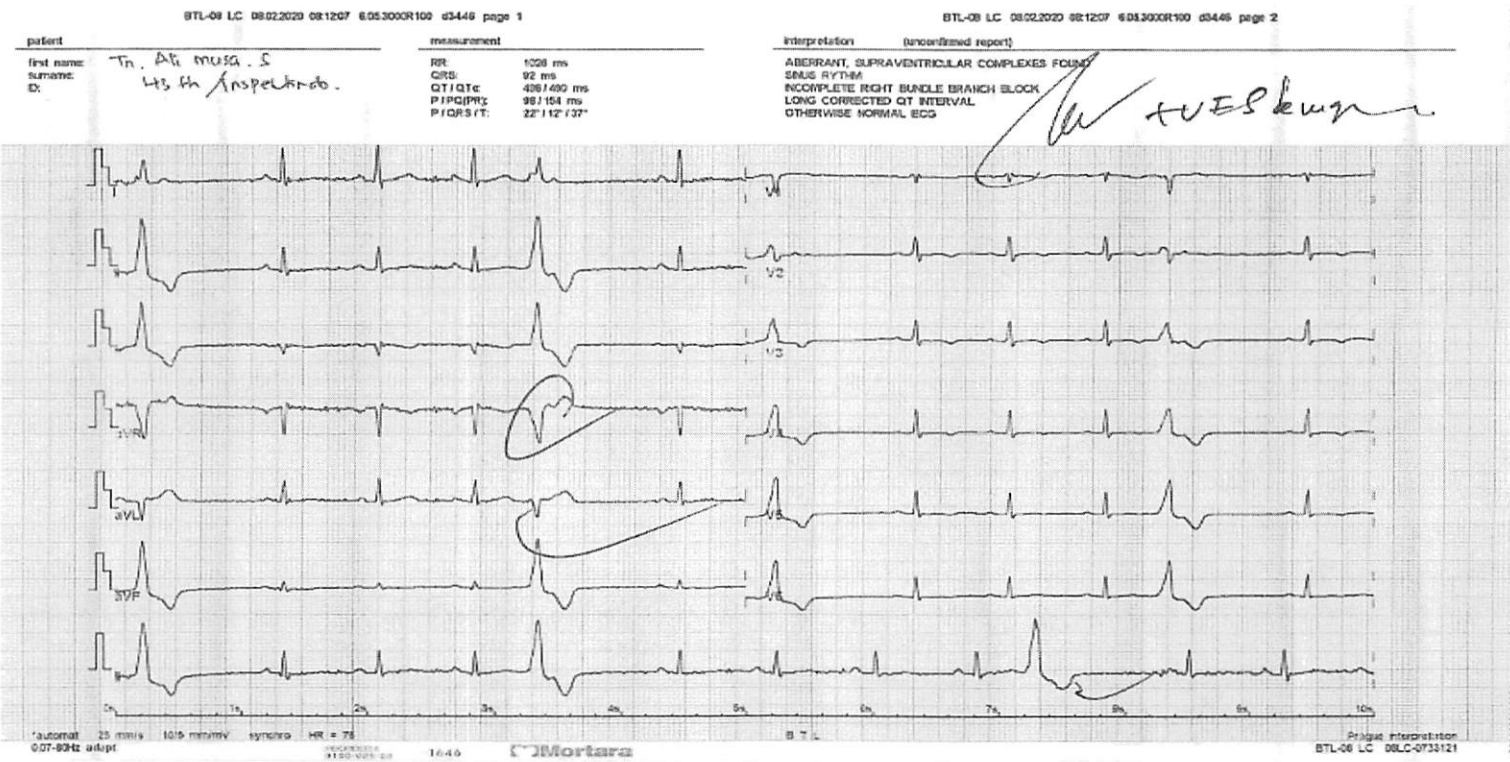
Conclusion Right Ear : Hearing threshold = 12.5 dB
(Within normal limit)

Conclusion Left Ear : Hearing threshold = 25 dB
(Within normal limit)
With decreasing on frequency
4000Hz & 6000Hz

CARDIOLOGY DIAGNOSTIC

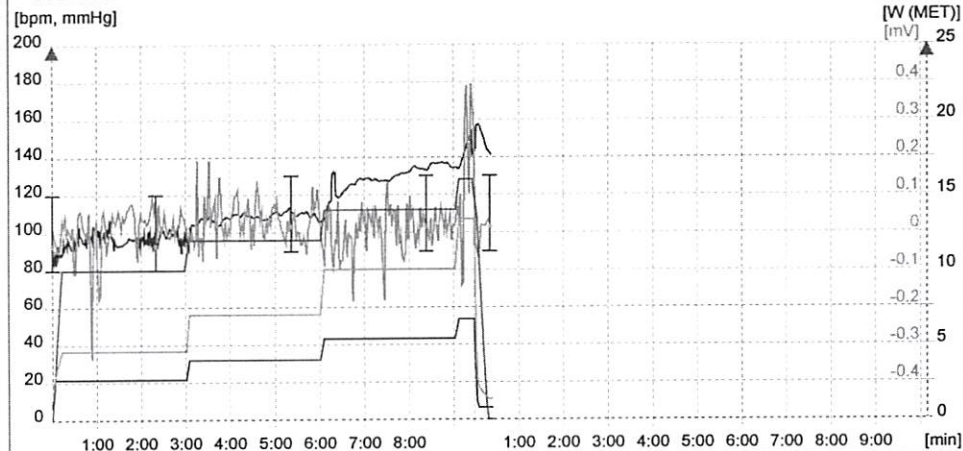
Name : ALI MUSA SIAGIAN	Sex : Male	MR : 01071287	Visit : 08/02/2020
Comp. : INSPEKTINDO SINERGI PERSADA		DOB : 15 October 1976	

EXAMINATION	RESULT	Comments :
ELECTROCARDIOGRAPHY	Sinus Rythm axis (N), P wave (N), PR int 0.16" ST - T segment (N), aritmia (+), VES benign	Normal ECG + VES benign
TREADMILL	Sinus Rythm axis (N), P wave (N), PR int 0.16" ST - T segment (N), aritmia (-)	Treadmill Exercise Test : Negative Cardiopulmonary Fitness Classification : Good METs : 13.4



**ALI MUSA SIAGIAN MR,**ID: 01071287, Born: 10/15/1976 (Male 43), 73.2 kg, 162 cm
Test Date: 2/8/2020 10:05:58 AM

MEDIKA PLAZA

Patient infoBorn: 10/15/1976
Age: 43
Sex: Male
Weight: 73.2 kg
Height: 162 cm
Smoker:
Pacemaker:**Medical history****Medications****Reason for admission****Reason for Stop****Trends****Conclusion**

[Handwritten signature]
 PT. KASIHATI MEDIKA PLAZA
 MEDIKA PLAZA

StaffPhysician: MEDIKA PLAZA WTC 2 CLINIC
Technician: MEDIKA PLAZA WTC 2 CLINIC**Test info**

Test date: 2/8/2020
 Test time: 10:05 AM
 Stress device: BTL Treadmill
 Protocol: Bruce
 Total duration: 09:27
 Stress achieved: 6.7km/h, 16.0% (~13.4MET) = 119% predicted (~11.5MET) - for 23 sec
 HR rest: 94
 HR peak: 152 = 86% predicted (176) --- 09:28 Exercise (13.4MET)
 Handgrip test: ---
 BP rest: 120/80
 BP peak: ---
 BP recovery: 130/90
 DP rest: 11280
 DP peak: 17295 = 1.5x DP at rest
 ST depression max: III -1.56mV 08:01 Exercise 10.1MET
 ST elevation max: II 1.34mV 05:48 Exercise 7.0MET
 ST/HR index: 23.0 μ V/bpm (abnormal)



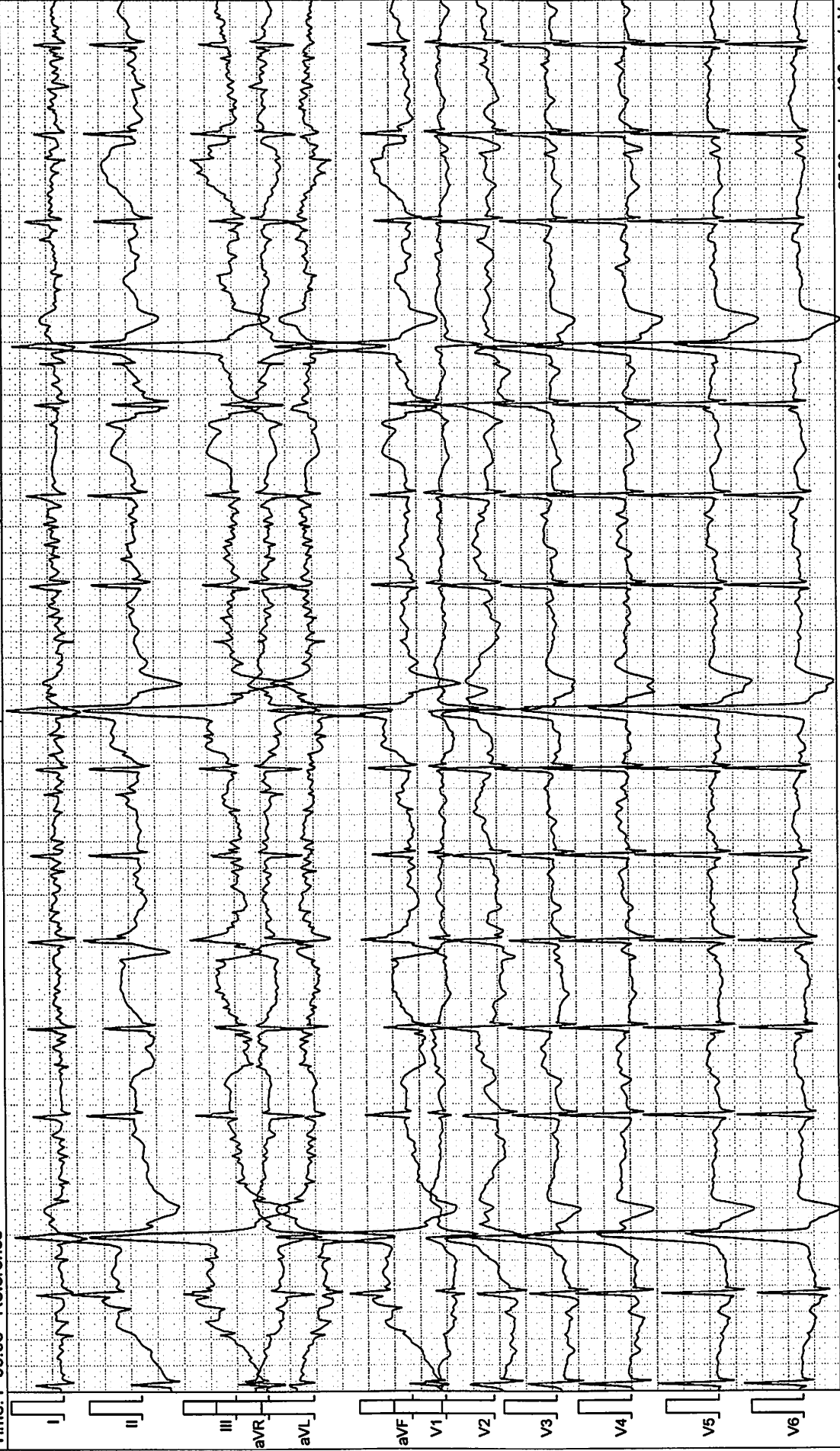
ALI MUSA SIAGIAN MR,

ID: 01071287, Born: 10/15/1976 (Male 43), 73.2 kg, 162 cm
Test Date: 2/8/2020 10:05:58 AM

MEDIKA PLAZA

Time: P 00:05 - Reference

Load: 1.4MET, HR: 94bpm, BP: 120/80



Filter: 0.07 Spline - 90 Adapt, -50 [Hz]

25.00 mm/Sec 10.0 mm/mV

MEDIKA PLAZA

BTL CardioPoint 2.30.33006.0, DIAG: 2.0.2.0; ECG: BTL-08 ECG, SN: 071D-B-02697

BTL CardioPoint - Stress Test

Page: 2



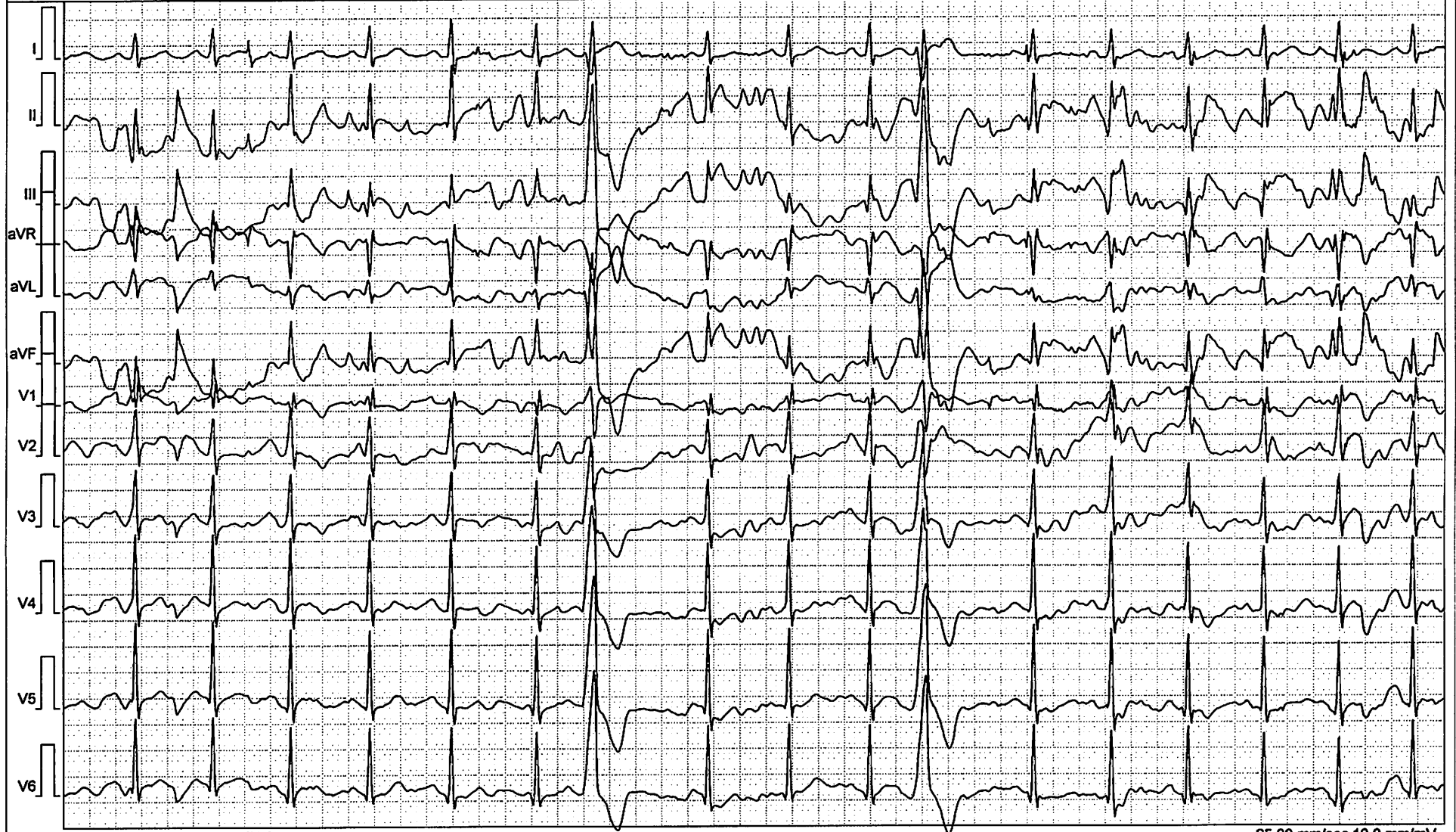ALI MUSA SIAGIAN MR,

ID: 01071287, Born: 10/15/1976 (Male 43), 73.2 kg, 162 cm
Test Date: 2/8/2020 10:05:58 AM

MEDIKA PLAZA

Time: E 02:56 - E1

Load: 4.6MET, HR: 96bpm, BP: 120/80



Filter: 0.07 Spline - 90 Adapt, ~50 [Hz]

25.00 mm/sec 10.0 mm/mV

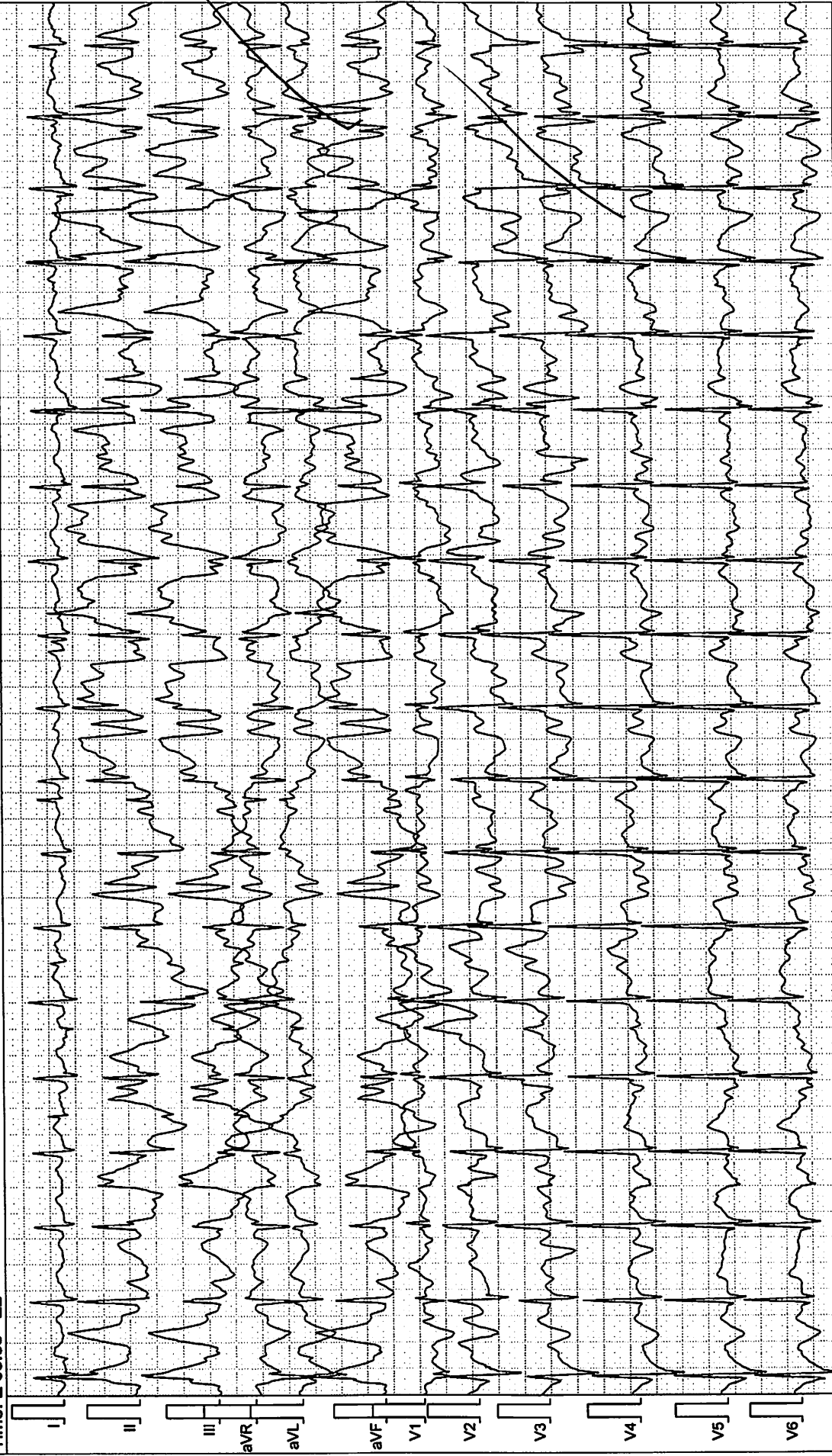


ALI MUSA SIAGIAN MR,
ID: 01071287, Bom: 10/15/1976 (Male 43), 73.2 kg, 162 cm
Test Date: 2/8/2020 10:05:58 AM

MEDIKA PLAZA

Time: E 05:58 - E2

Load: 7.0MET, HR: 106bpm, BP: 130/90



Filter: 0.07 Spine - 90 Adapt, ~50 [Hz]

25.00 mm/sec 10.0 mm/mV

MEDIKA PLAZA

BTL CardioPoint 2.30.33006.0, DIAG: 2.0.2.0; ECG: BTL-08 ECG, SN: 071D-B-02697

BTL CardioPoint - Stress Test

Page: 4




ALI MUSA SIAGIAN MR,

ID: 01071287, Born: 10/15/1976 (Male 43), 73.2 kg, 162 cm
Test Date: 2/8/2020 10:05:58 AM

MEDIKA PLAZA

Time: E 08:59 - E3

Load: 10.1MET, HR: 135bpm, BP: 130/90



Filter: 0.07 Spine - 90 Adept, ~50 [Hz]

25.00 mm/sec 10.0 mm/mV

MEDIKA PLAZA

BTL CardioPoint 2.30.33006.0, DIAG: 2.0.2.0; ECG: BTL-08 ECG, SN: 071D-B-02697

BTL CardioPoint - Stress Test

Page: 5



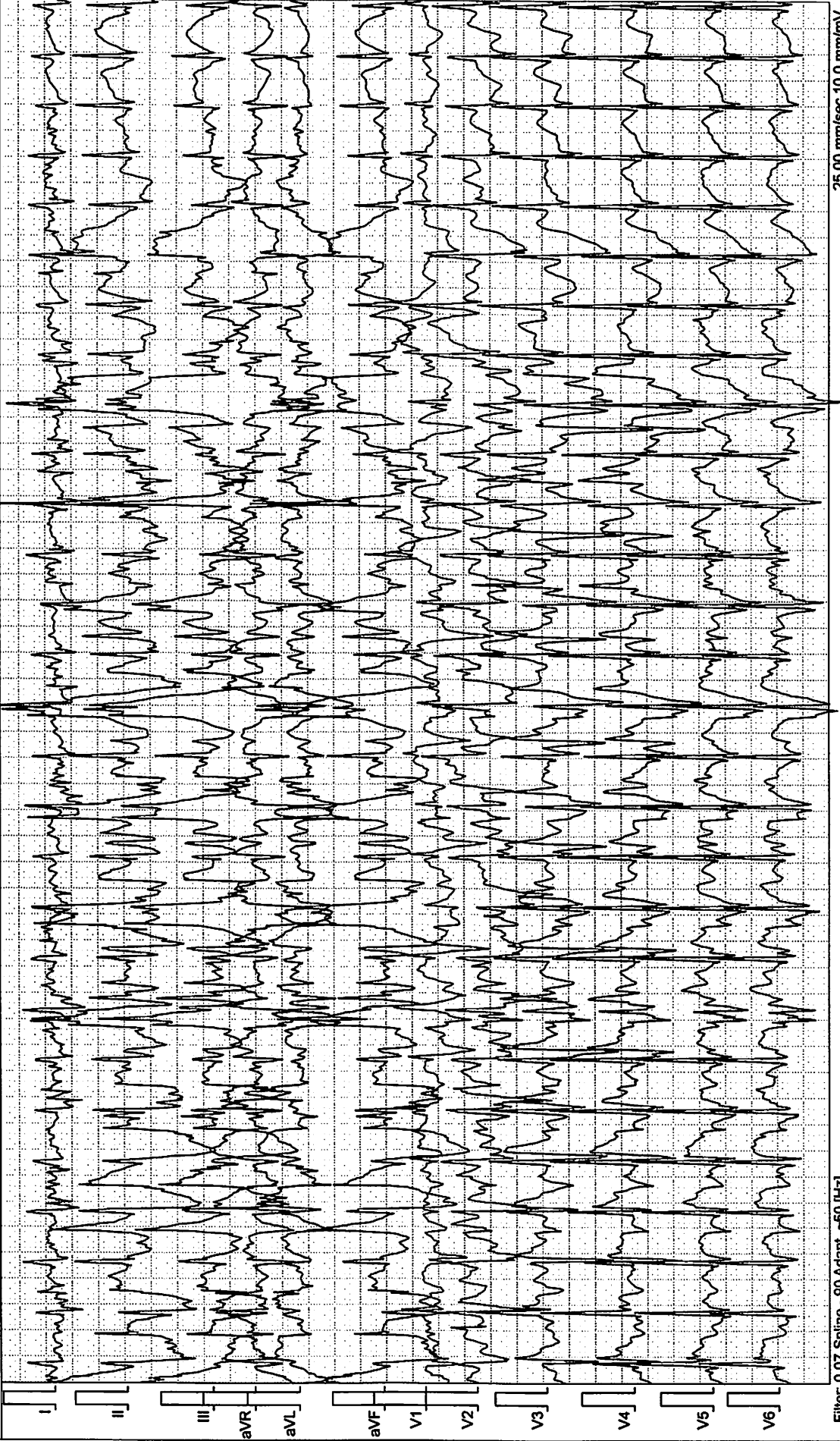
ALI MUSA SIAGIAN MR,

ID: 01071287, Born: 10/15/1976 (Male 43), 73.2 kg, 162 cm
Test Date: 2/8/2020 10:05:58 AM

MEDIKA PLAZA

Time: E 09:23 - Peak

Load: 13.4MET, HR: 142bpm, BP: -



Filter: 0.07 Spine - 90 Adapt, ~50 [Hz]

25.00 mm/sec 10.0 mm/mV

MEDIKA PLAZA

BTL CardioPoint 2.30.33006.0, DIAG: 2.0.2.0; ECG: BTL-08 ECG, SN: 071D-B-02697

BTL CardioPoint - Stress Test

Page: 6



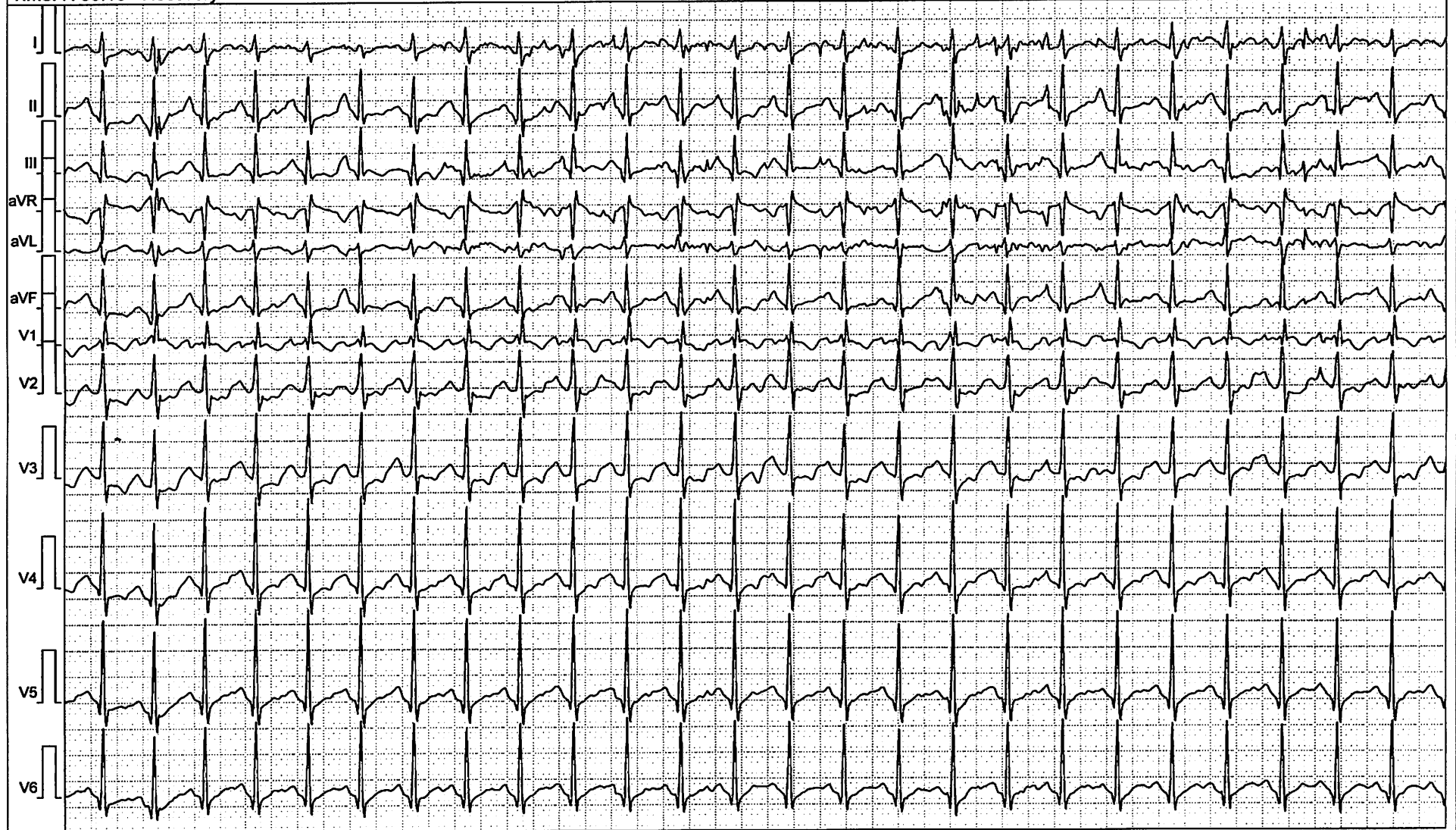
ALI MUSA SIAGIAN MR,

ID: 01071287, Born: 10/15/1976 (Male 43), 73.2 kg, 162 cm
Test Date: 2/8/2020 10:05:58 AM

MEDIKA PLAZA

Time: R 00:10 - Recovery

Load: 1.6MET, HR: 149bpm, BP: 130/90



Filter: 0.07 Spline - 90 Adapt, ~50 [Hz]

25.00 mm/sec 10.0 mm/mV



ALI MUSA SIAGIAN MR,

ID: 01071287, Born: 10/15/1976 (Male 43), 73.2 kg, 162 cm
Test Date: 2/8/2020 10:05:58 AM

MEDIKA PLAZA

Stage	Time	Load			HR bpm	BP mmHg	SpO2 %	ST Level [mV], J+: 1/8RR											
		km/h	%	MET				I	II	III	aVR	aVL	aVF	V1	V2	V3	V4	V5	V6
Reference	P 00:15	0.8	0.0	1.4	94	120/80	-	0.07	0.17	0.12	0.01	-0.03	0.14	-0.03	0.03	0.03	-0.10	0.01	0.02
E 1 stage	E 03:01	2.7	10.0	4.6	96	120/80	-	0.05	0.01	-0.07	0.03	0.01	-0.01	-0.01	-0.07	-0.09	-0.06	0.02	0.02
E 2 stage	E 06:03	4.0	12.0	7.0	108	130/90	-	0.03	-0.29	-0.03	0.07	0.02	0.02	0.11	-0.07	-0.06	0.00	0.02	0.02
E 3 stage	E 09:04	5.4	14.0	10.1	134	130/90	-	0.04	-0.01	-1.56	0.20	0.03	-0.36	0.04	-0.19	0.25	0.05	0.10	0.10
E 4 peak	E 09:28	6.7	16.0	13.4	152	-	-	0.25	-0.87	-0.97	0.03	0.48	-0.95	-0.17	-0.12	0.33	0.46	0.28	0.39
Recovery	R 00:20	0.8	16.0	2.5	147	130/90	-	0.02	0.03	0.00	-0.02	0.03	0.01	-0.16	-0.04	-0.06	0.00	0.03	0.04

PATIENT NAME : Tn. Ali Musa Siagian
No. RM : 01071287
Klinik/MCU/HCU : CO. ENT

To. Dokter :
(Counsel)

Kindly please counsel for patient who has take cares of

Diagnose :
Clinik Summary :

Counsel Request :

COUNSEL ADVISE

Finding :

Diagnosis :

Recomendation :

S. labia E1
Fg. labia - labia. Uj. Mx. larynx, sub. cr. gl. cr. dan kelenj.,
Hid. labia - labia. labia. nas. larynx, sub. cr. dan kelenj.,
Tong. larynx, kelenj. dan kelenj. sub. cr. dan kelenj.,
Date : 8/12/20

M: 12.15 db

A: m. db.

lab. cr. part

Date : 8/12/20

Time :

EP :

Signature
MP+
dr. Muh. Fajar Ramadhan Irsyal, SpTHT-KL
E.N.T
Complete Name

Formulir Number : FM - DR - 008 - 02
Revisi Number : 00
Date : 07 Juli 2017

A: S. kelenj. dan kelenj. dan kelenj. dan kelenj.
lab. cr. part

M. kelenj.

P. kelenj.