

NO REG : CPA1910090011
NO TRANS : 191010-2027Print Date : 11.10.2019
Print Time : 10:12**DATA PRIBADI**
PERSONAL DATA

| | | |
|--|-----------------------------------|------------------------------|
| Nomor Formulir <i>Formulir Number</i> | ISP-04 | |
| Nama Lengkap <i>Full Name</i> | Sihar Hallel Hotasoit | |
| Alamat <i>Address</i> | PT INSPEKTINDO SINERGI PERSADA | |
| Tanggal Lahir <i>Date of birth</i> | 6.08.1990 | Umur 29 <i>Age</i> |
| Kelamin <i>Sex</i> | Laki-laki | |
| Status Perkawinan <i>Marital Status</i> | - | |
| Pekerjaan <i>Occupation</i> | Karyawan Swasta | |
| Department / NIK <i>Department / NIK</i> | - / CPA1910090011 | |
| Kebangsaan <i>Nationality</i> | Indonesia | |
| Check Up Terakhir <i>Last Medical Check Up</i> | | |
| Jenis Medical Check Up <i>Type of Medical Check Up</i> | Medical Check Up Paket Perusahaan | |
| Tanggal Pemeriksaan <i>Date of examination</i> | 9.10.2019 | |

No Peg : CPA1910090011
Nama : Sihar Hallel Hotasoit

No Form : ISP-04

RIWAYAT KESEHATAN

Keluhan

Tidak ada

Penyakit yang pernah diderita

Operasi Usus Buntu tahun 2019

Kebiasaan **Rokok (Cigarettes)** : Ya 20 Batang/Hari / Rokok Elektrik
 Alkohol (Alcohol) : Tidak
 Kopi (Coffee) : Tidak
 Olah Raga (Exercise): Ya 1 Kali / Minggu (Berenang)
 Obat-obatan (Drugs) : Tidak

Penyakit Keluarga

Darah Tinggi (Hypertension) : Ya KAKEK
Kencing Manis (Diabetes Melitus) : Tidak
Sakit Jantung (Heart disease) : Tidak
Sakit Ginjal (Renal disease) : Tidak
Gangguan Mental (Psync. disorder) : Tidak
Lain-lain (Others) : Tidak

No Peg : CPA1910090011
 Nama : Sihar Hallel Hotasoit

No Form : ISP-04

PEMERIKSAAN FISIK

Tinggi Badan : 175.00 cm
 Berat Badan : 96 kg
 BMI : 31.28 (Obesitas)

Tekanan Darah : 120/80 mmHg
 Denyut Nadi : 70 x / menit
 RR : Normal (18)

| | | |
|---------------|---|---|
| Visus | Visus Kanan : 20/20 | Visus Kiri : 20/20 |
| Mata | <input checked="" type="checkbox"/> Tidak ada Kelainan | <input type="checkbox"/> Terdapat Kelainan |
| Kulit | <input checked="" type="checkbox"/> Tidak ada Kelainan | <input type="checkbox"/> Terdapat Kelainan |
| THT | <input checked="" type="checkbox"/> Tidak ada Kelainan | <input type="checkbox"/> Terdapat Kelainan |
| Gigi & Mulut | <input type="checkbox"/> Tidak ada Kelainan Stain RA-RB Radix : 2.7 | <input checked="" type="checkbox"/> Terdapat Kelainan |
| KGB | <input checked="" type="checkbox"/> Tidak ada Kelainan | <input type="checkbox"/> Terdapat Kelainan |
| Paru-paru | <input checked="" type="checkbox"/> Tidak ada Kelainan | <input type="checkbox"/> Terdapat Kelainan |
| Jantung | <input checked="" type="checkbox"/> Tidak ada Kelainan | <input type="checkbox"/> Terdapat Kelainan |
| Perut | <input checked="" type="checkbox"/> Tidak ada Kelainan | <input type="checkbox"/> Terdapat Kelainan |
| Ginjal | <input checked="" type="checkbox"/> Tidak ada Kelainan | <input type="checkbox"/> Terdapat Kelainan |
| Saraf | <input checked="" type="checkbox"/> Tidak ada Kelainan | <input type="checkbox"/> Terdapat Kelainan |
| Kelainan Lain | <input type="checkbox"/> Tidak ada Kelainan Konjungtiva : Pterigium OS St. I | <input checked="" type="checkbox"/> Terdapat Kelainan |

EKG : Normal
 Normal Sinus Rythm

Treadmill : Normal
 Negative Ischemic Response

No Peg : CPA1910090011
Nama : Sihar Hallel Hotasoit

No Form : ISP-04

LAPORAN SPESIFIK

AUDIOMETRI :

| | 250 | 500 | 1000 | 1500 | 2000 | 3000 | 4000 | 6000 | 8000 |
|-----------|-----|-----|------|------|------|------|------|------|------|
| Right ear | 10 | 20 | 20 | 25 | 20 | 25 | 20 | 30 | 20 |
| Left ear | 15 | 20 | 15 | 15 | 20 | 10 | 10 | 35 | 10 |

Result : ADS Dalam Batas Normal

SPIROMETRI :

VC : 93%
FCV : 95%
FEV1o : 96%
Result : Normal

Bangsai/Poli : CHECKUP
 Umur/Seks : 29Th / Laki-laki
 Tanggal Lahir : 06-08-1990
 Tanggal Terima : 09-10-2019 07:52
 Tanggal Cetak : 09-10-2019 15:38
 Halaman : 2 / 3

Pasien : **SIHAR HALLEL HUTASOIT**
 Alamat : PERUM KOPERPUM TAMBUN UTARA
 No.Pasien : **90054302**
 No.Lab : **19070814**
 No.Reg : CPA1910090011
 Dokter : dr. Ignatius Billy Koeswoyo

RUTIN

Info Klinik :

| T E S | HASIL | UNIT | NILAI RUJUKAN |
|-------|-------|------|---------------|
|-------|-------|------|---------------|

| | | | |
|-------|---------|--|-------------|
| HBsAg | reaktif | | Non reaktif |
|-------|---------|--|-------------|

URINALISA

Tangkap

| | | | |
|------------------|-----------------|-------|---------------|
| Warna | kuning | | Kuning |
| Kejernihan | agak keruh | | Jernih |
| Berat Jenis | 1.030 | | 1.005 - 1.030 |
| pH | 5.5 | | 5.0 - 7.0 |
| Lekosit Esterase | negatif | | Negatif |
| Nitrit | negatif | | Negatif |
| Protein | negatif | | Negatif |
| Glukosa | negatif | | Negatif |
| Keton | negatif | | Negatif |
| Urobilinogen | 1.00 | mg/dL | 0.10 - 1.90 |
| Bilirubin | negatif | | Negatif |
| Darah Samar | (+) 1 | | Negatif |
| Sedimen | | | |
| Eritrosit | H 15 | /uL | <3 |
| Lekosit | 5 | /uL | <10 |
| Silinder | negatif | | |
| Sel Epitel | (+) | | (+) |
| Kristal | (+) 1 Ca Oxalat | | Negatif |
| Lain-lain | negatif | | |

TINJA

Faeces Rutin

| | | | |
|-------------|---------|--|---------|
| Warna | kuning | | Coklat |
| Konsistensi | lembek | | Lembek |
| Lendir | negatif | | Negatif |
| Darah | negatif | | Negatif |

Mikroskopik

| | | | |
|--------------|---------|------|---------|
| Eritrosit | 1 - 2 | /lpb | |
| Lekosit | 2 - 4 | /lpb | |
| Epitel | positif | | |
| Telur Cacing | negatif | | Negatif |
| Amuba | negatif | | Negatif |

Pencernaan

Bangsai/Poli : CHECKUP
 Umur/Seks : 29Th / Laki-laki
 Tanggal Lahir : 06-08-1990
 Tanggal Terima : 09-10-2019 07:52
 Tanggal Cetak : 09-10-2019 15:38
 Halaman : 3 / 3

Pasien : **SIHAR HALLEL HUTASOIT**
 Alamat : PERUM KOPERPUM TAMBUN UTARA
 No.Pasien : **90054302**
 No.Lab : **19070814**
 No.Reg : CPA1910090011
 Dokter : dr. Ignatius Billy Koeswoyo

RUTIN

Info Klinik :

| T E S | HASIL | UNIT | NILAI RUJUKAN |
|-----------|---------|------|---------------|
| Amilum | negatif | | Negatif |
| Lemak | negatif | | Negatif |
| Serat | negatif | | Negatif |
| Lain-lain | Negatif | | |



| | | | |
|------------------|-------------------------|---------------------|-------------------------------|
| Patient Name | : SIHAR HALLEL HUTASOIT | Patient ID | : SHLC.90054302 |
| Sex / Age | : M / 029Y | Accession No. | : 4000007006764 |
| Modality | : CR | Scan Date | : 09-10-2019 |
| Procedure | : THORAX AP/PA | Report Date/Time | : 09-10-2019 08:32:08 AM |
| Ref. Departement | : MCU | Referring Physician | : DR. IGNATIUS BILLY KOESWOYO |

Teknik:

Thoraks proyeksi PA

Temuan:

Jantung tidak membesar , CTR < 50%.

Aorta dan mediastinum superior tidak melebar.

Trakea ditengah, kedua hillus tidak menebal.

Corakan bronkovaskular di kedua paru baik.

Tidak tampak infiltrat maupun nodul di kedua paru.

Kedua sinus kostofrenikus dan diafragma baik.

Kesan:

Tidak tampak kelainan radiologis pada cor dan pulmo.

Best Regards,

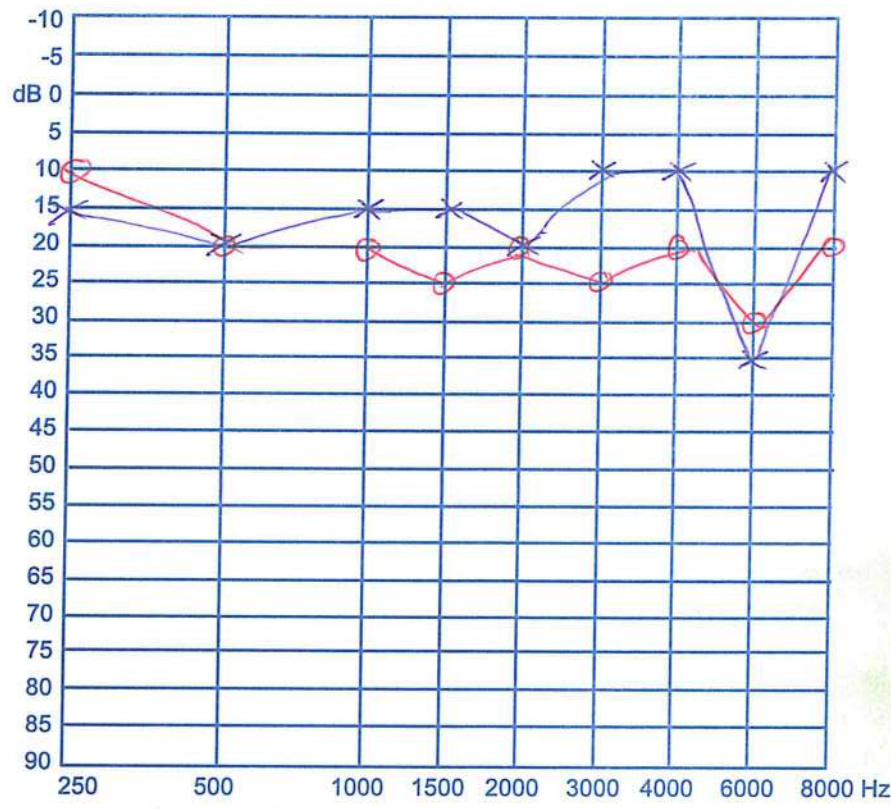



dr. Amelia Putri, Sp.Rad

This document is digitally signed and hence no manual signature is required.

**HASIL PEMERIKSAAN
AUDIOMETRI**

SIHAR HALLEL HUTASOIT / Male / Ph: 082114056329
 MR No: SHLC.90-05-43-02 / DOB: 06-Aug-1990 (28y 2m 3d)
 CPA1910090011 / 09-Oct-2019 07:35
 dr. Ignatius Billy Koeswoyo / INSPEKTINDO SINERGI PERSADA, PT



dr. Bambang Hari Santosa, SpTHT
 Spesialis Otorhinolaryngolog
 SIP : 503/040/Dinkes/Sp/2018
 SHLC

Spirolograph alpha *touch*

SPIROMETRY REPORT 09/OCT/2019, 08:40

ID: 90054302
 NAME: Sihar h HUTASOIT
 GENDER: MALE D.O.B.: 06/AUG/1990
 AGE: 29 HEIGHT: 175 cm
 WEIGHT: 95 kg SMOKER: SMOKER
 B.M.I.: 31.0 POSTURE: STANDING
 FEV1%PRED: 96 %
 PRED. SET: ERS93/POLGAR (90%)

TEST SESSION INFORMATION

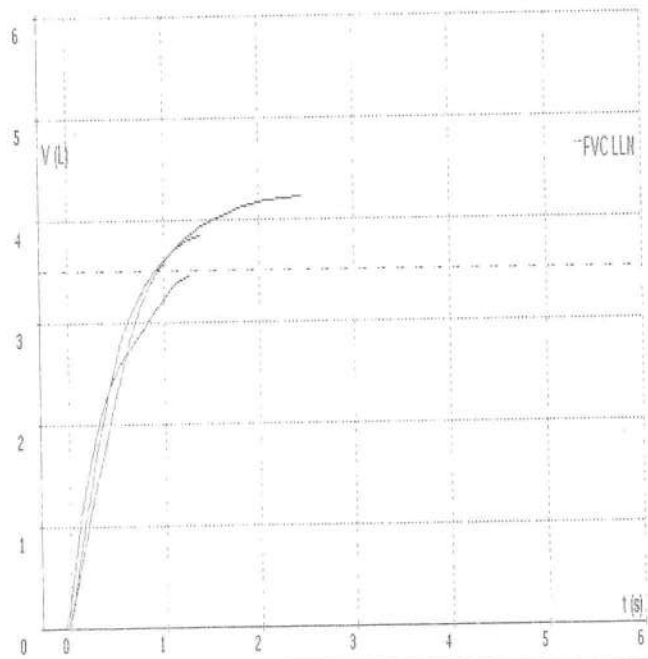
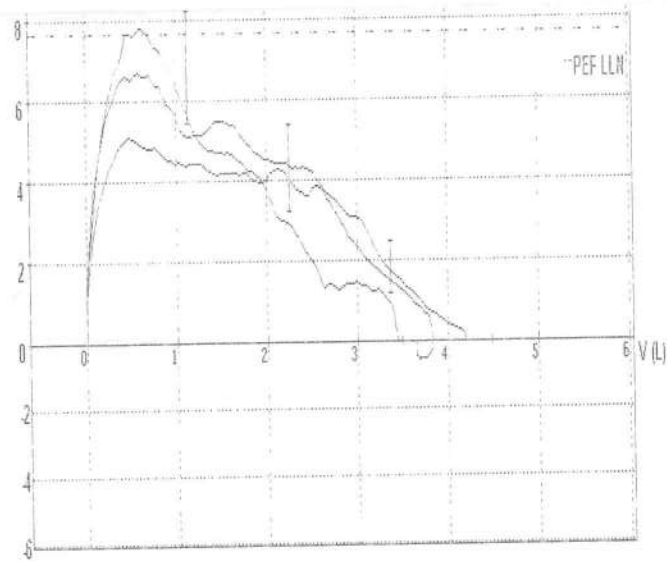
TEST DATE: 09/OCT/2019 TEST TIME: 08:38
 No BLOWS: 3 ACC. CHECK: 06/JULY/2019
 CAL. ADJ.: 06/JULY/2019 DEVICE I.D.: 31195
 TEMPERATURE: 23 °C

RESULTS TABLE (VALUES AT BTPS)

| Parameter | | Best | Norm | %PRED | Best | Best | Best |
|-----------|---------|------|------|-------|------|------|------|
| | | Meas | Pred | | 1 | 2 | 3 |
| VC | L | 4.34 | 4.69 | 93 | 4.34 | 4.34 | 4.34 |
| FVC | L | 4.25 | 4.49 | 95 | 4.25 | 3.87 | 3.47 |
| FEV1 | L | 3.61 | 3.77 | 96 | 3.42 | 3.61 | 3.11 |
| FEV1R | | 0.83 | 0.82 | 101 | 0.79 | 0.83 | 0.72 |
| FEV1/FVC | | 0.85 | 0.82 | 104 | 0.80 | 0.93 | 0.90 |
| PEF | L/s | 7.83 | 9.65 | 81 | 5.09 | 6.77 | 7.83 |
| FEF25-75 | L/s | 3.78 | 4.85 | 78 | 3.78 | 4.45 | 3.68 |
| FEF25 | L/s | 4.47 | 8.24 | 54 | 4.47 | 5.86 | 7.17 |
| FEF50 | L/s | 4.25 | 5.38 | 79 | 4.25 | 4.67 | 4.48 |
| FEF75 | L/s | 2.56 | 2.47 | 104 | 2.56 | 2.79 | 1.72 |
| PIF | L/s | 0.53 | 9.08 | 6 | - | 0.53 | - |
| MVVind | L/min | 135 | 141 | 96 | 128 | 135 | 117 |
| FET | s | 2.45 | 6.00 | 41 | 2.45 | 1.40 | 1.28 |
| Rind | KPa/L/s | 0.08 | - | - | 0.10 | 0.08 | 0.15 |

*BELOW LLN OR changes of > 12% and > 0.2 L in the FEV1 Post Bronchodilation

F(L/s)



SUGGESTED INTERPRETATION & COMMENTS

Computer interpretations cannot be relied upon for diagnosis.
 Normal ventilatory function.

Signature: _____

HASIL PEMERIKSAAN SPIROMETRI

AMA 34-0609/0:

Kesan : normal.

09/10/19



dr. Widi Usansi, Sp.P. FISR
Spesialis Paru & Pernapasan
(Pulmonologist)
SIP : NO.503/224/Dinkes/Sp/2017

| | | | |
|------------------|-------------------------|---------------------|-------------------------------|
| Patient Name | : SIHAR HALLEL HUTASOIT | Patient ID | : SHLC.90054302 |
| Sex / Age | : M / 029Y | Accession No. | : 4000007006763 |
| Modality | : US | Scan Date | : 09-10-2019 |
| Procedure | : COMPLETE ABDOMEN USG | Report Date/Time | : 09-10-2019 08:27:28 AM |
| Ref. Departement | : MCU | Referring Physician | : DR. IGNATIUS BILLY KOESWOYO |

Teknik:

USG whole abdomen

Temuan:

Hepar : Bentuk dan ukuran baik. Echostruktur parenkim homogen meningkat ringan, tidak tampak lesi fokal / SOL.

Struktur vaskular dan bilier tidak melebar.

Tidak tampak ascites.

Kandung empedu : Bentuk dan ukuran baik. Dinding tidak menebal. Tidak tampak batu maupun sludge.

Pankreas : Bentuk dan ukuran baik. Echostruktur parenkim homogen, tidak tampak lesi fokal maupun SOL. Duktus pancreatikus tidak melebar.

Kedua ginjal : Bentuk dan ukuran baik. Echostruktur parenkim homogen, differensiasi korteks dan medulla jelas.

Sistem pelviokalis tidak melebar. Tidak tampak batu/kista/SOL.

Limpa : Bentuk dan ukuran baik. Echostruktur parenkim homogen, tidak tampak lesi fokal / SOL. Vena lienalis tidak melebar.

Aorta : Kaliber baik. Tidak tampak pembesaran kelenjar getah bening paraaorta.

Vesica urinaria : Bentuk dan ukuran baik. Dinding tidak menebal. Tidak tampak batu/ SOL.

Prostat : Bentuk dan ukuran baik. Echostruktur parenkim homogen. Tidak tampak kalsifikasi.

Kesan:

Mild fatty liver.

Tidak tampak kelainan pada organ-organ intraabdomen lainnya saat ini.

Best Regards,

This document is digitally signed and hence no manual signature is required.

| | | | |
|------------------|-------------------------|---------------------|-------------------------------|
| Patient Name | : SIHAR HALLEL HUTASOIT | Patient ID | : SHLC.90054302 |
| Sex / Age | : M / 029Y | Accession No. | : 4000007006763 |
| Modality | : US | Scan Date | : 09-10-2019 |
| Procedure | : COMPLETE ABDOMEN USG | Report Date/Time | : 09-10-2019 08:27:28 AM |
| Ref. Departement | : MCU | Referring Physician | : DR. IGNATIUS BILLY KOESWOYO |



Dr. Amelia Putri, Sp.Rad

This document is digitally signed and hence no manual signature is required.

No Peg : CPA1910090011
Nama : Sihar Hallel Hotasoit

No Form : ISP-04

KESIMPULAN

Hasil pemeriksaan fisik (Physical result)

1. Kondisi Nutrisi : Obesitas (BMI=31.2)
2. Gigi : Stain RA-RB, Radix 2.7
3. Konjungtiva : Pterigium OS St. I

Note : Pasien menolak konsultasi ke Dokter Spesialis Mata

Saran dan anjuran (Advice)

1. Konsultasi ke Ahli Gizi
2. Konsultasi ke Dokter Gigi
3. Periksa ke Dokter Spesialis Mata untuk mengangkat Pterygium

Hasil pemeriksaan lab (Laboratory result)

1. Darah : Laju Endap Darah Meningkat = 22 mm/jam, ALT (SGPT) Meningkat = 164 u/l, AST (SGOT) Meningkat = 68 u/l, HBsAg = Reaktif
2. Urine : Kejernihan = Agak keruh, Darah Samar = (+) 1, Eritrosit Meningkat = 15 /uL, Kristal = (+) 1 Ca Oxalat
3. Faeces : Tidak ada kelainan

Saran dan anjuran (Advice)

1. Cari faktor - faktor penyebab alergi, Konsultasi ke Dokter Spesialis Penyakit Dalam
2. Banyak minum air putih, Test Urine ulang 7 hari lagi, Jika hasil masih abnormal, Konsultasi ke Dokter Spesialis Penyakit Dalam

Hasil pemeriksaan radiologi (Radiologic result)

1. Thorax : Tidak tampak kelainan radiologis pada cor dan pulmo
2. USG Abdomen : Mild fatty liver. Tidak tampak kelainan pada organ-organ intraabdomen lainnya saat ini

Saran dan anjuran (Advice)

2. Konsultasi ke Dokter Spesialis Penyakit Dalam

Hasil Keseluruhan

Kurang Baik

Kami mengucapkan terima kasih atas kepercayaan Anda pada
"Siloam Hospitals Lippo Cikarang" untuk Pemeriksaan
Kesehatan.

We would like to thank you for the confidence given to
the *Siloam Hospitals* Lippo Cikarang to perform this
Medical Check Up.

Kami sarankan Pemeriksaan Kesehatan rutin setiap 1 tahun.

We suggest to have a Medical Check Up Yearly.

Kepala Unit Medical Check Up



a/h Dr. Ignatius Billy Koeswoyo

NO. 503/209/Dinkes/DU/2015

Summary

et medical devices spa

via de zinis 6
+39 02 950513

Patient

Last name HALLEL HUTASOIT
First name SIHAR
Sec. name
Birthday 06/08/1990
Sex Male
ID 90054302
Reasons for test MCU
Medication MCU

Test information

Date/time 09/10/2019 10:27:12
Test Type Treadmill
Protocol bruce kmh
Pre-Exercise 02:55
Exercise 09:35
Recovery 00:34

Max HR 166 (12:36)
% on theor. HR 86% (191)
BP Max 140/80 (10:48)
DP Max 232 (12:36)

| Phase | Time mm:ss | HR bpm | BP mmHg | DP/100 | METS | Speed kmh | Elevation % | J+X ms | V5 mm |
|--------------|---------------|-----------|------------|--------|------|--------------|----------------|-----------|----------|
| Pre-Exercise | 02:55 | 76 | 100/60 | 76 | 0.7 | 1.6 | 0.0 | 60 | 1.45 |
| Peak | 12:30 | 164 | 140/80 | 229 | 13.3 | 6.7 | 16.0 | 60 | 1.15 |
| End Test | 13:04 | 147 | 140/80 | 205 | 0.0 | 0.0 | 0.0 | 60 | 2.10 |

Reasons for test termination

Conclusions

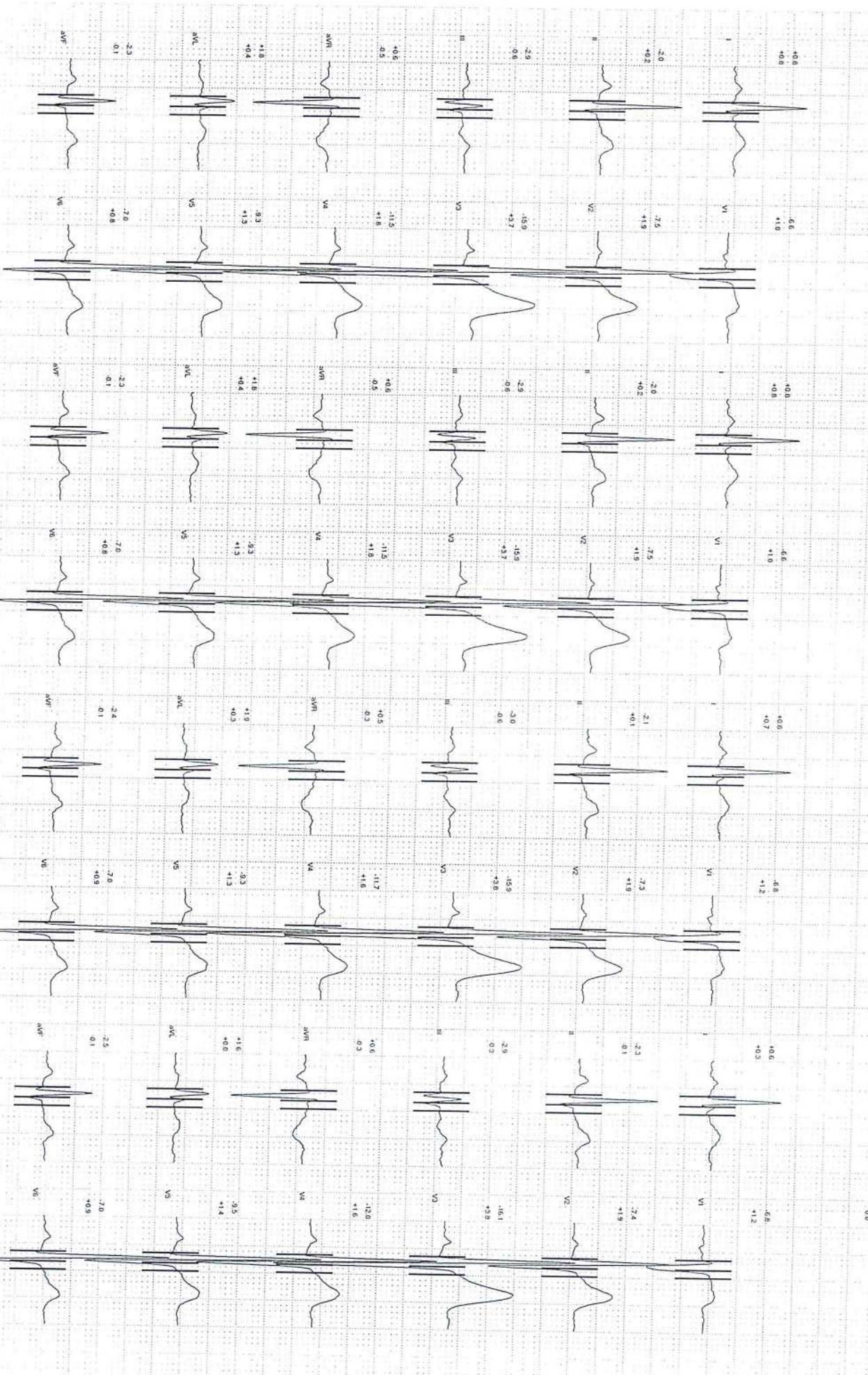
Normal relmg ECG
 Chest pain ⊕
 arthralgia ⊕
 negative urticar rppn/r
 good time

Dr. HIRONMAN Michelacondo S.p.A.
 C.A. S. D. I. O. L. O. G. I. S. T. I.
 S.P.A. Via S. Maria Maddalena 100/101
 00187 Roma

Sign

MED1 MED1

| SQPRNE | | SQPRNE | | SQPRNE | | SQPRNE | | SQPRNE | |
|------------|------------|------------|------------|------------|------------|------------|------------|------------|------------|
| Total time | Start Time | Total time | Start Time | Total time | Start Time | Total time | Start Time | Total time | Start Time |
| 00:00 | 00:00 | 00:04 | 00:04 | 00:08 | 00:08 | 00:12 | 00:12 | 00:16 | 00:16 |
| Mean HR | 64 | 65 | 66 | 66 | 66 | 66 | 66 | 66 | 66 |
| BP | - | - | - | - | - | - | - | - | - |
| Speed | 0.0 | 0.0 | 0.0 | 0.0 | 0.0 | 0.0 | 0.0 | 0.0 | 0.0 |
| Elevation | 0.0 | 0.0 | 0.0 | 0.0 | 0.0 | 0.0 | 0.0 | 0.0 | 0.0 |



16 minutes 25:00 mm/s

HALLEI, HILFSCOTT SHAWN
50054302
Male 06/06/1990

Total time: 00:28
Pre Exercise (00:28)
SUPINE (00:28)

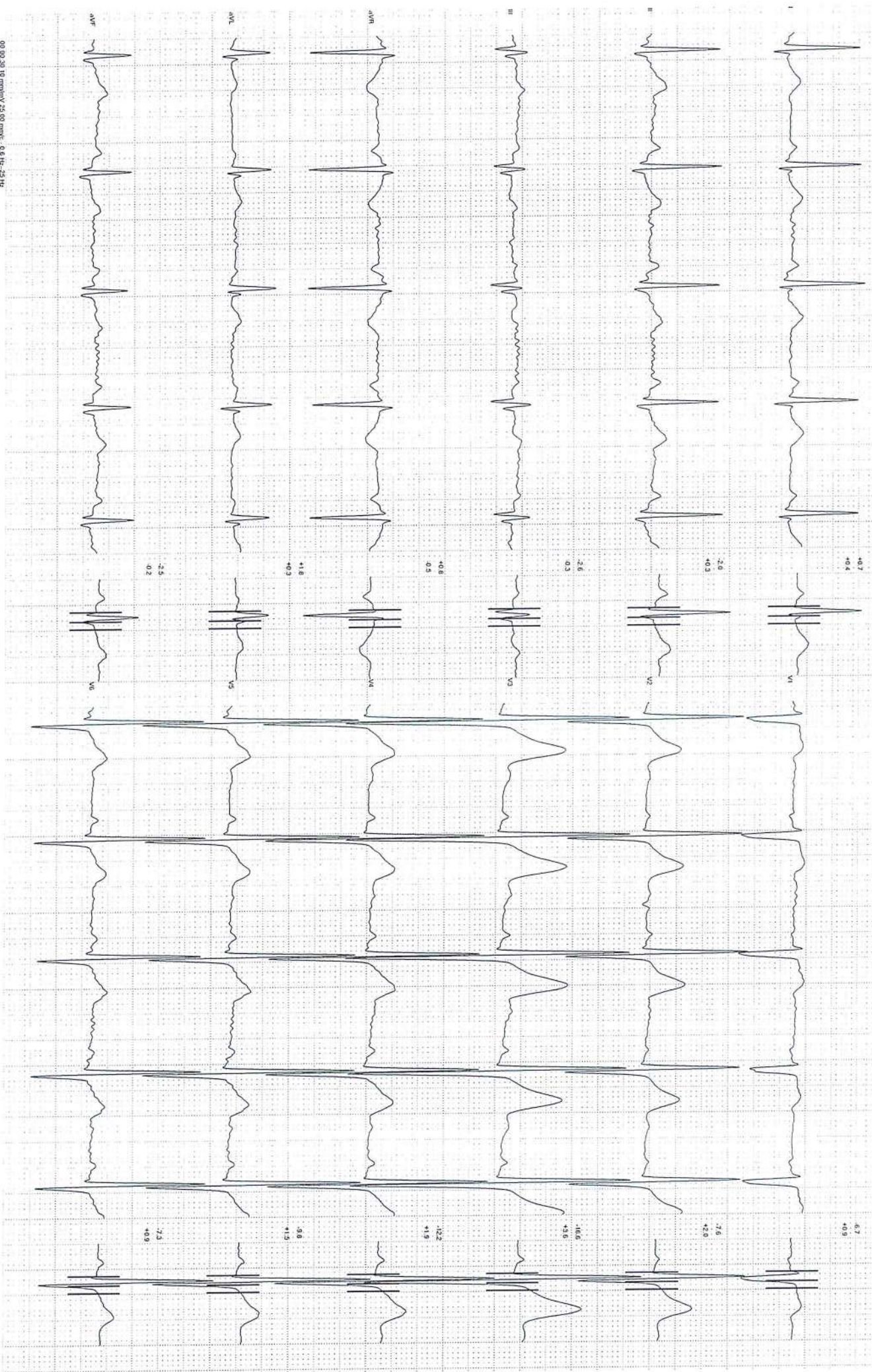
HR (bpm)
70 (30%)

Load
0.0 kmh
0.0 %

BP
100/60 mmHg

CP100
70

METS
0.0



00 00 30 10 mm/mV 25 00 mm/s - 0.0 Hz - 25 Hz

PRINTED AT: 04/06/2019 10:27:12

Total time: 00:36
Pre-Exercise (00:36)
SUPINE (00:36)

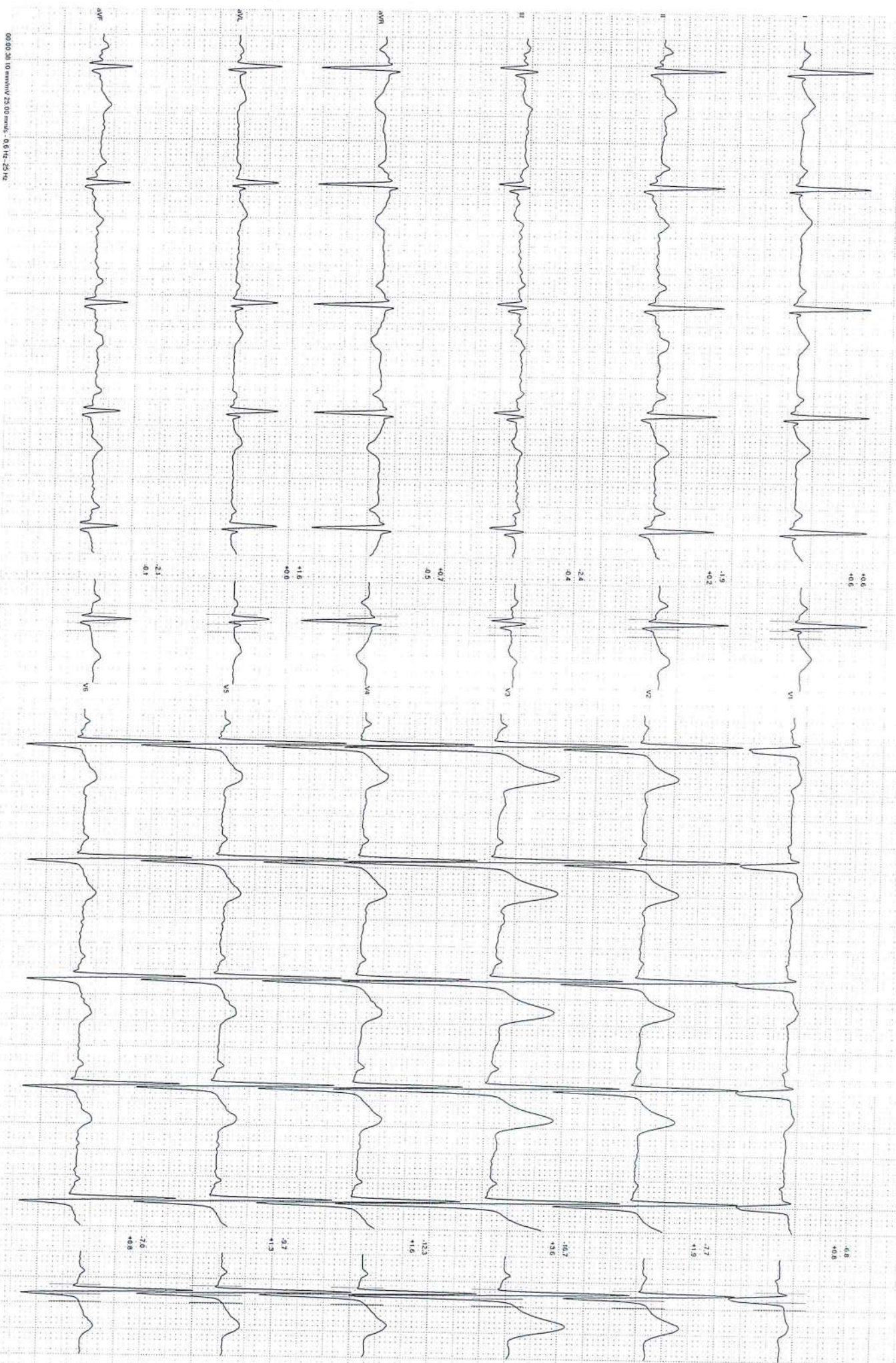
HR (bpm)
66 bpm

Load
0.0 km/h
0.0 %

BP
100/80 mmHg

DO2/100
66

MTS
0.6



00:00:36 10 minutes/25.00 mmHg - 0.674 - 25.14

Total time 02:03
Pre Exercise (02:00)
HYPER V (01:13)

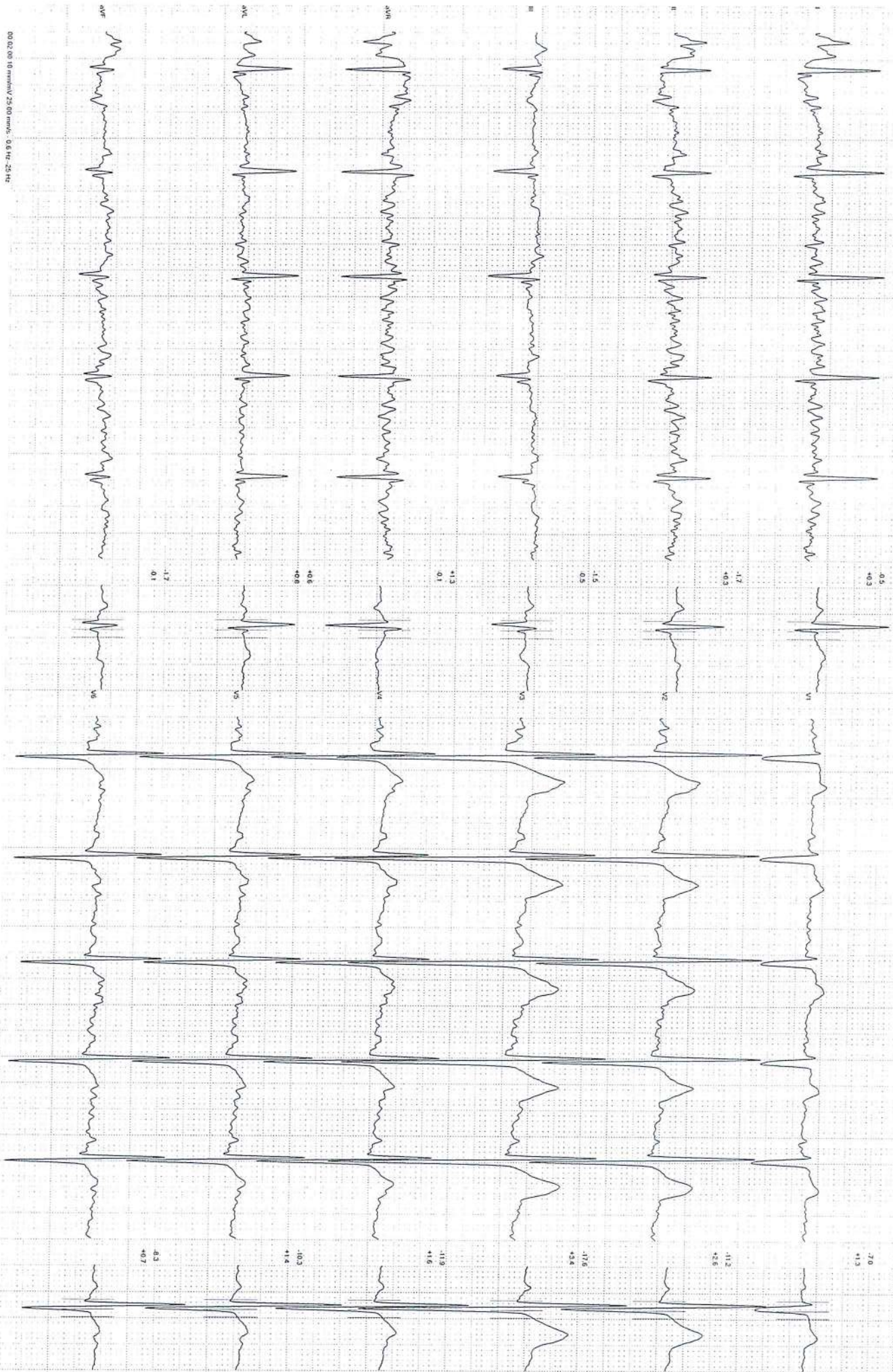
HR (bpm)
78 bpm
(40%)

Load
0.0 kmh
%

BP
100/60
mmHg

DRIVE
78

WETS
0.0



00:02:00 10 remaining 20:00 mmHg 0.6 Hz 25 Hz

Total time: 02:44
Pre-Exercise (02:44)
WARM UP (00:35)

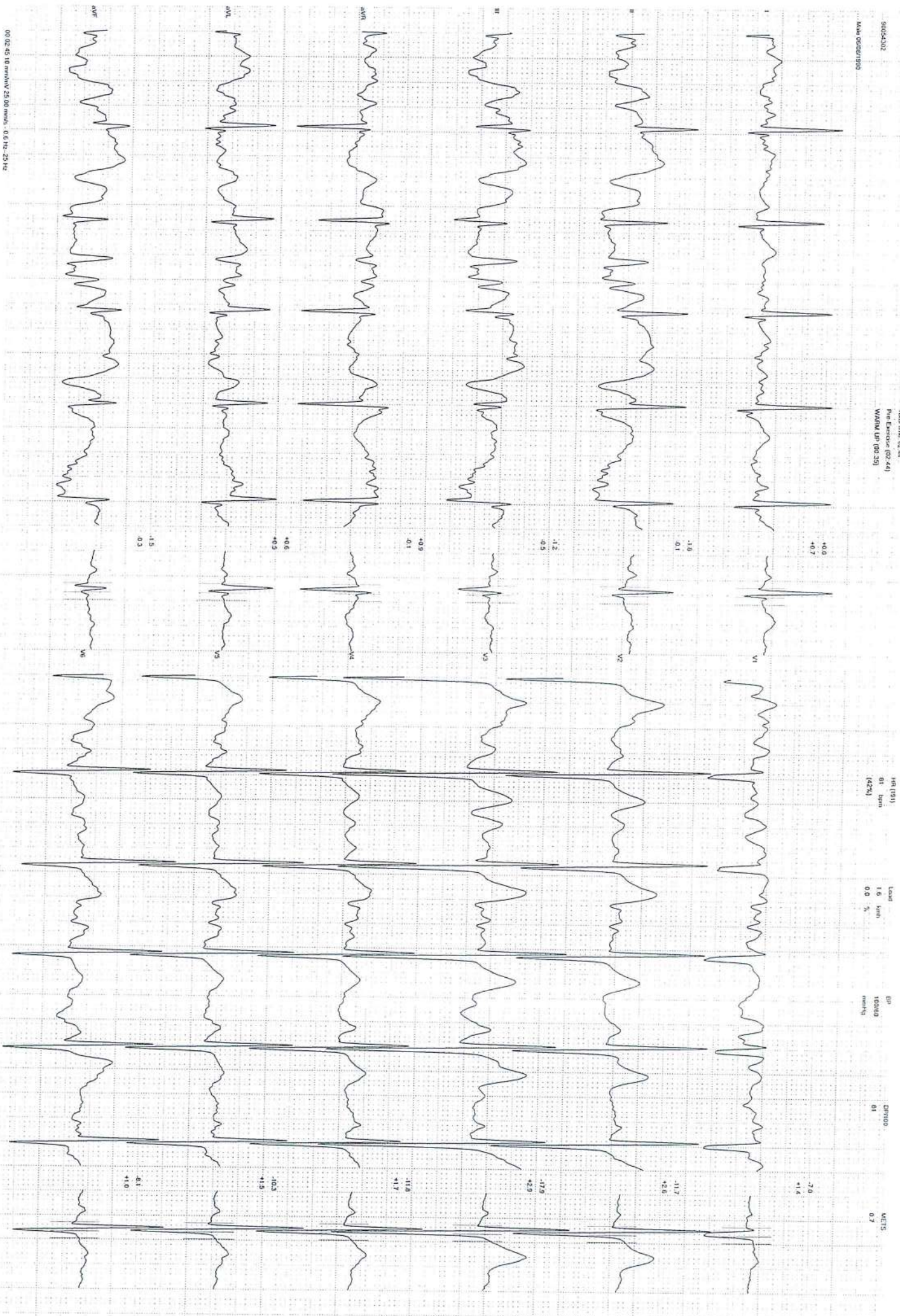HR (bpm)
81 (42%)

Load
1.6 km
0.0 %

BP
100/80
mmHg

CRP/NO
81

MEFS
0.7



00:02:45.10 running 25.00 mmHg, 0.6 Hz, 25 Hz

MALLEY, HILFSCOTT SMITH

90054302

Male 06/08/1980

Total time: 05:44
Exercise (02:49)
1 (02:49)

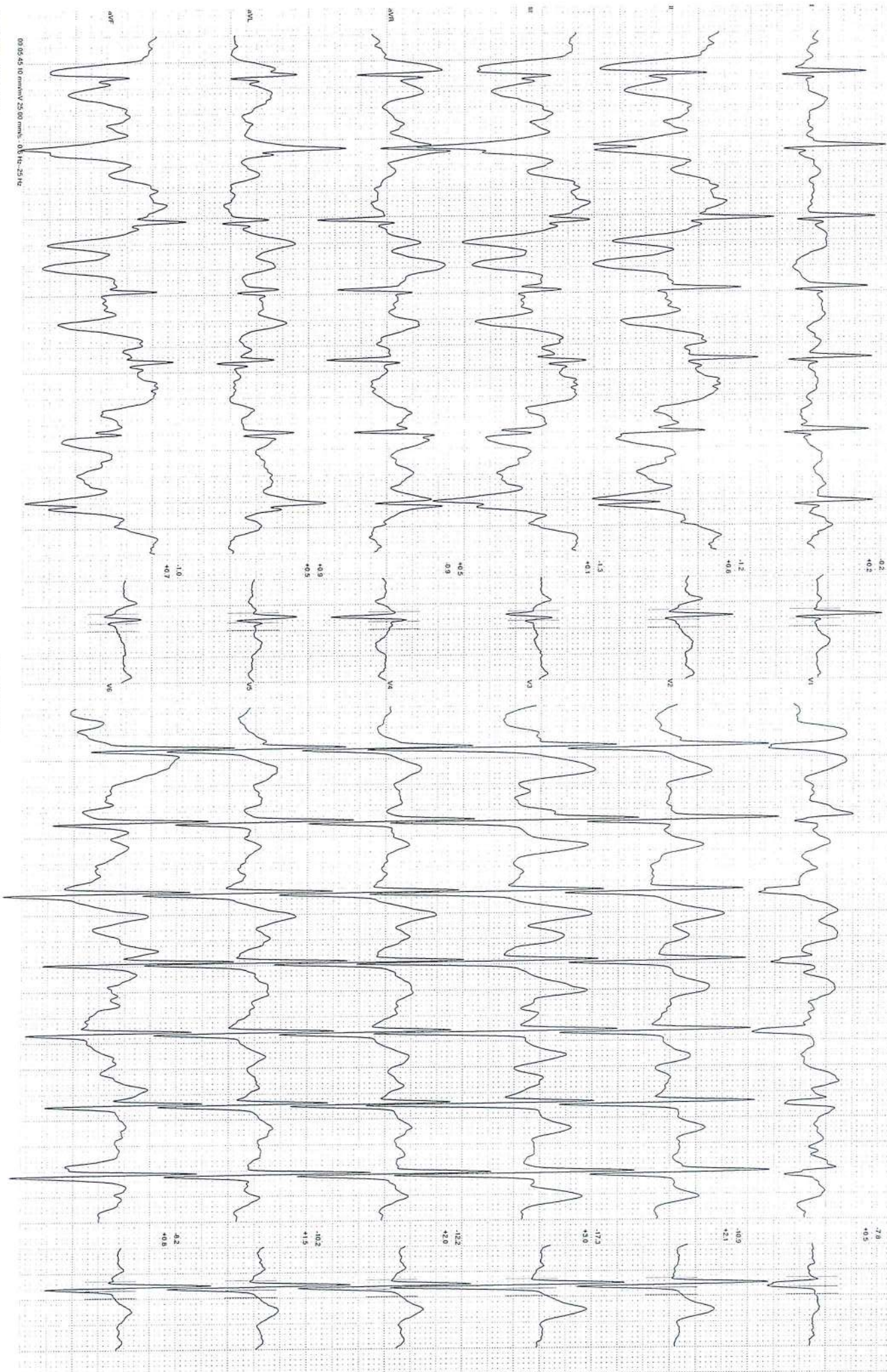
HR (131)
107 bpm
(66%)

Load
2.7 kmh
10.0 %

EP
10000
mmHg

OPR100
107

MEFS
3.6



00:05:45 to 00:05:50 interval: 25.00 mm/s, 0.05 Hz, 25 Hz

PH MEDICAL SERVICES

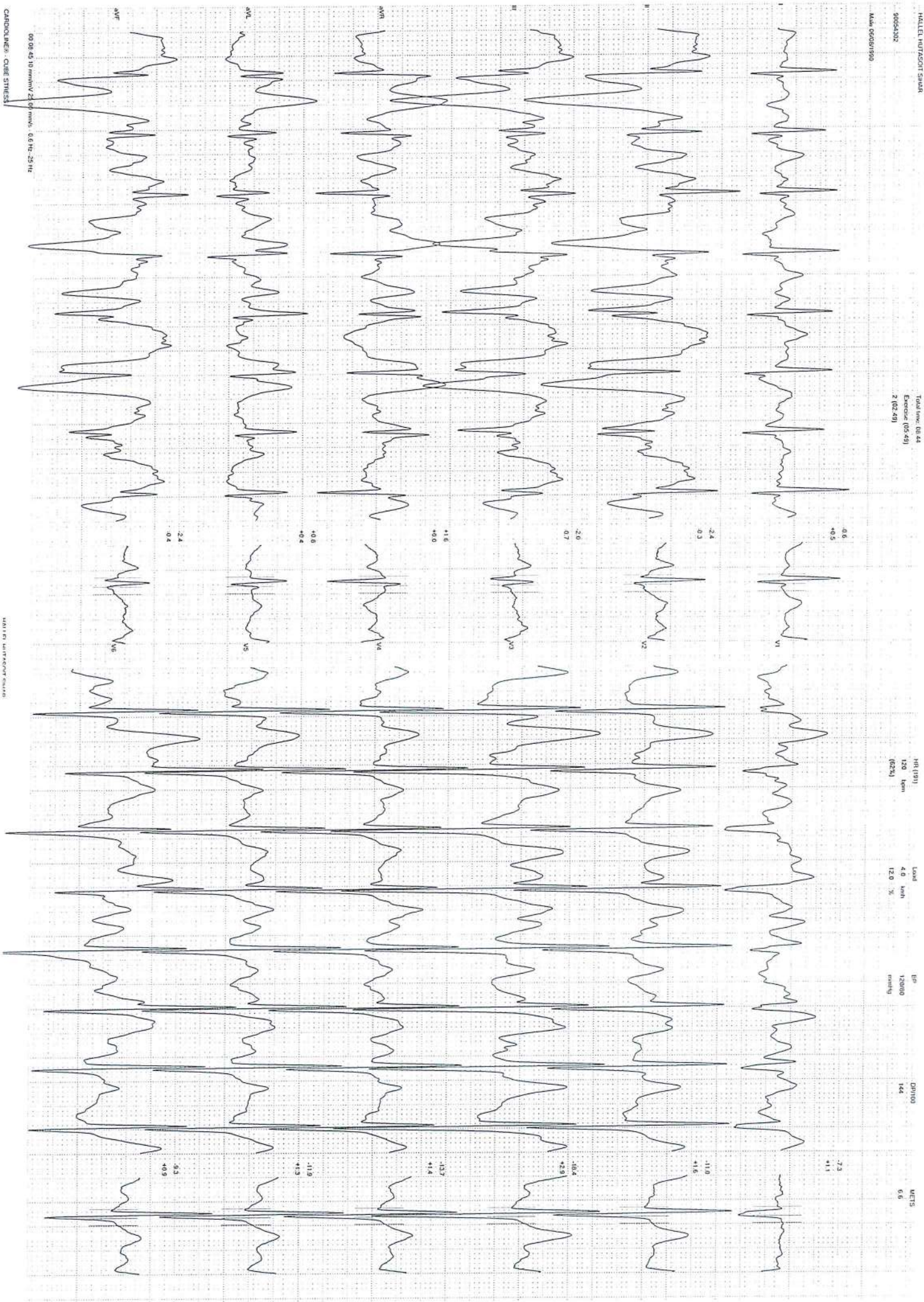
MALLEY, HILFSCOTT SMITH

HALLI, HIRJASOT SHAR

50054302

Male, 06/08/1990

Total time: 08:44
Exercise (05:59)
2 (02:45)



HAILEL HUTSOFI SHAM

90052402

Male, 06/08/1990

Total time: 11:44
Exercise (08:49)
3 (02:49)


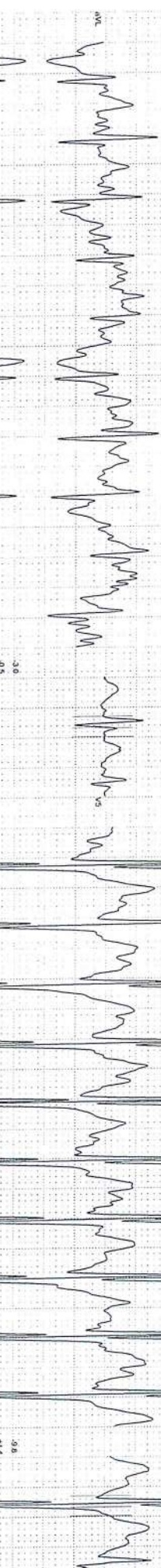
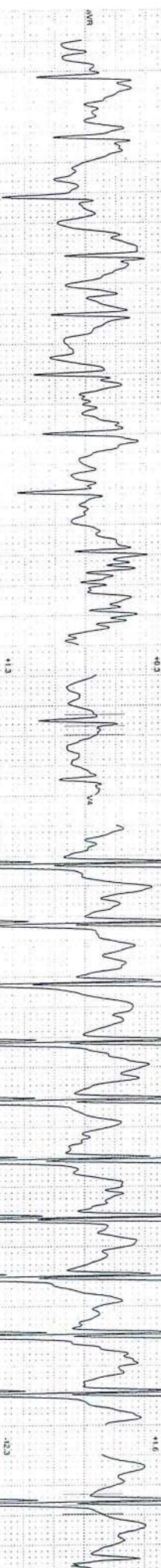
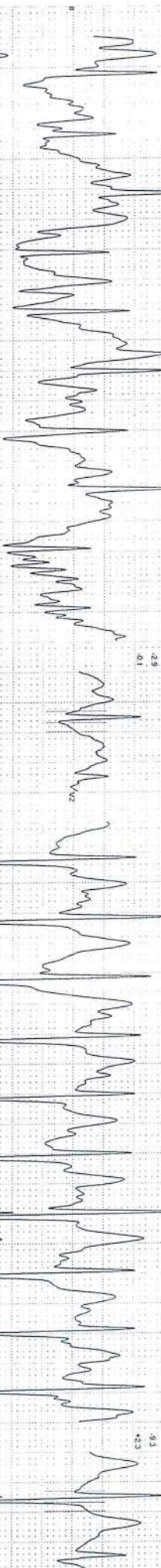

HR (bpm)
100 (60%)

Load
5.5 km/h
14.0 %

PR
140/80
mmHg

CP/100
214

MC/15
10.0



CHAQUUNE® CUBE STRESS

HAILEL HUTSOFI SHAM


00:11:45 (0:00min)/25:00 (max) - 0.6 Hz - 25 Hz

HALLEI HUTZSCOTT SHAR

30054302

Male 06/06/1980

Total time: 12:20
Exercise: 09:25
Peak: 09:25



HR (bpm)
128 bpm
(83%)

Load
6.7 km
16.0 %

BP
140/80 mmHg

DRYDO
222

METS
13.3

08:12:21 10 mmV/25.00 mm/s - 0.5 Hz - 25 Hz

CARDIOLINE® CUBE STRESS

HALLEI HUTZSCOTT SHAR

HALLEI, HUTASOVI SHAR

5004402

MAH 06/09/1990

Total time 12:32
Recovery (00:02)
1 (05:02)

HR (1/1)

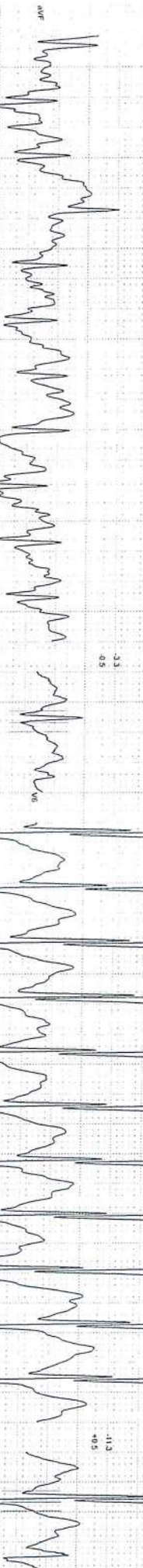
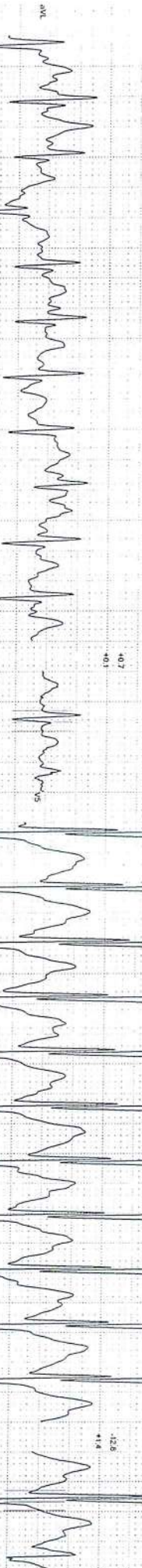
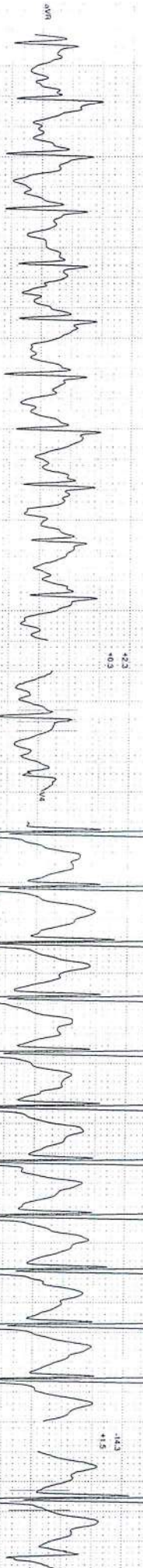


164 bpm
(65%)

Load
2.5 km
0.0 %

BP
140/80
mmHg

O2H100
229

METS
1.1



CARDIOPHYSICIAN: CLIVE STRASS

HALLEI, HUTASOVI SHAR

00 12 35 10 min/14 25 00 mmHg - 0.0 Hz - 25 Hz

HALLEE MUTAZOOR SIMAR

90024302

Male 06/08/1978

Total time: 12:26
Recovery (00:18)
2 (00:03)

HR (bpm)
153 bpm
(60%)

Load
1.7 kWh
0.0 %

BP
140/80 mmHg

OPR100
214

METS
0.6

1.1
+0.3

0.5
0.2

0.5
0.4

0.2
+0.0

0.8
+0.3

2.9
+0.1

5.9
+1.1

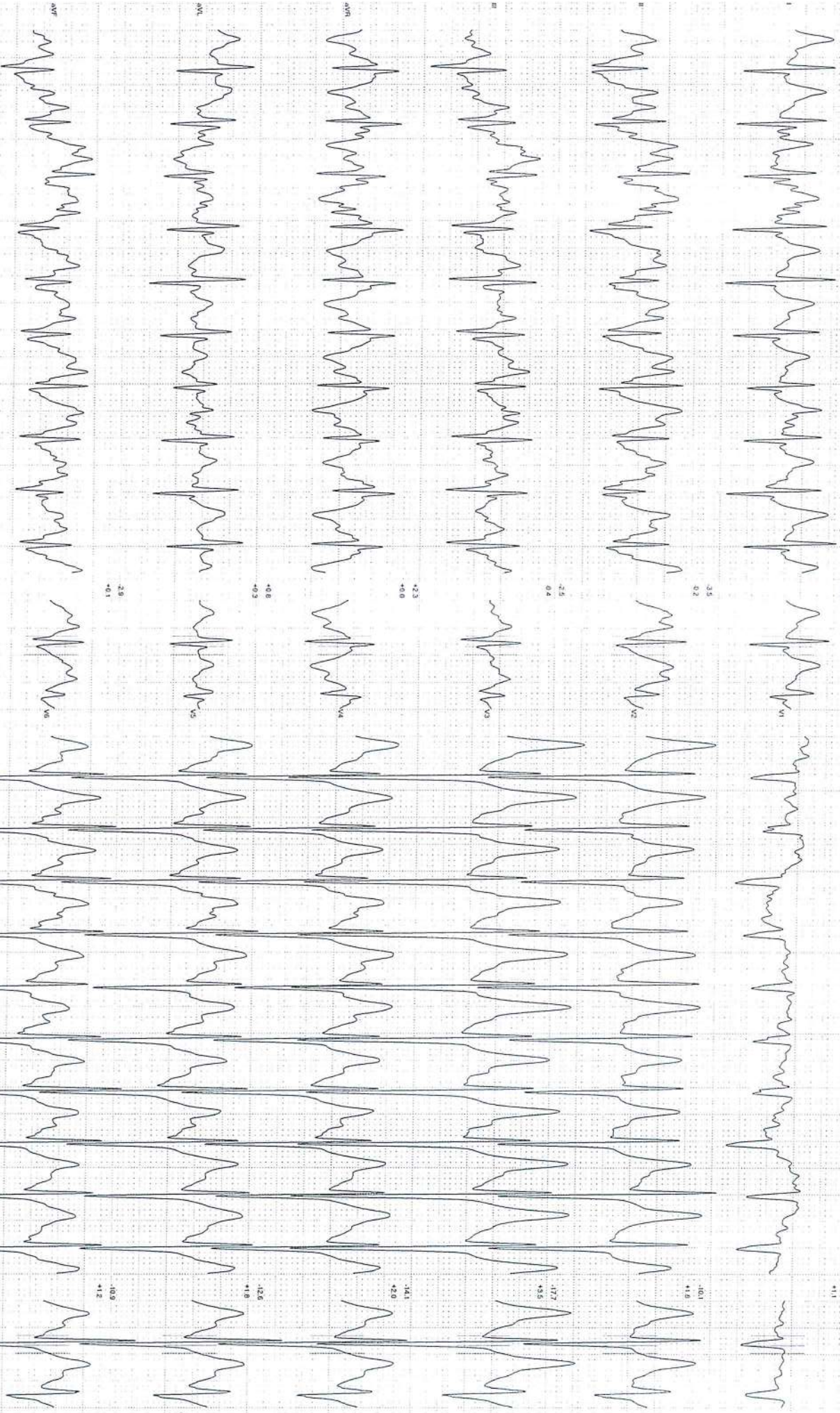
10.1
+1.9

17.7
+3.5

14.1
+2.0

12.6
+1.8

10.9
+1.2



00:12:50 10 mm/mV 25/50 mm/s 0.6 Hz 25 Hz

CARDIOLIFE, CABE STRESS

HALLEE MUTAZOOR SIMAR

GE MAC1200 ST

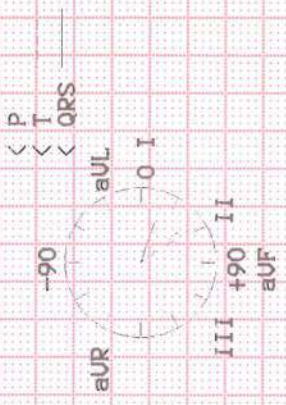
HR 64 bpm

Measurement Results:

QRS : 106 ms
 QT/QTcB : 392 / 407 ms
 PR : 152 ms
 P : 116 ms
 RR/PP : 730 / 740 ms
 P/QRS/T : 50 / 20 / 55 degrees
 QTU/QTcBD : 52 / 54 ms
 Sokolow : 1.5 mV
 NK : 8

Interpretation

normal ECG



Unconfirmed report

