

Certificate Of Health Assessment




Name	Age	Position	Department
ACHMAD CHOIRONI	36 yo	SPV	TESTING

COMPANY :

INSPEKTINDO SINERGI PERSADA, PT

CONCLUSION

Fit for work to the job described	
Fit with Medical Note (Restriction and/or Limitation)	✓
Temporary Unfit	
Unfit for work to the job described	

Issued Date	Doctors Name	Prepared By
26 November 2019	Puteri Melati, MD PKTK : KEP.264/BINWASK3-PNK3/KK/VI/2019 SIP : 23/B.15a/31.74.04.1004/-1.779.3/e/2019	 
Expired Date		Verified By
26 November 2020	dr. Muhammad Ilyas, Sp.Ok SIP : 29/B.15b/31.74.04.1004.02.009.K.1/3/-1.779.3/e/2019	 PT. KARTIKA BINA MEDIKATAMA

No. Formulir : FM-DR-008-05
 No. Revisi : 00
 Tanggal Terbit : 2 Mei 2011

Certificate Number : MP-BOP/1-20191126/118543
 MCU Validity Check
<https://mcu-validasi.medikaplaza.com>

PT. KARTIKA BINA MEDIKATAMA

TO WHOM IT MAY CONCERN

Kepada yang berkepentingan

This is certify that today Tuesday, 26 November 2019 Medika Plaza Clinic has performed urine drug screening and/or breath alcohol test to :

Dengan ini menyatakan bahwa, pada hari ini Selasa, 26 November 2019 Medika Plaza Clinic telah melakukan urine drug screening dan/atau breath alcohol test kepada :

ACHMAD CHOIRONI

With the results are as follows :

Dengan hasil sebagai berikut :

<u>Drugs Test</u> <i>Uji Obat</i>	<u>Result</u> <i>Hasil</i>		
URINE DRUGS SCREENING			
- Amphetamine	<input type="checkbox"/> Non-Negative	<input checked="" type="checkbox"/> Negative	<input type="checkbox"/> N/A
- Met-Amphetamine	<input type="checkbox"/> Non-Negative	<input type="checkbox"/> Negative	<input checked="" type="checkbox"/> N/A
- Cocain	<input type="checkbox"/> Non-Negative	<input checked="" type="checkbox"/> Negative	<input type="checkbox"/> N/A
- THC/Canabis/Marijuana	<input type="checkbox"/> Non-Negative	<input checked="" type="checkbox"/> Negative	<input type="checkbox"/> N/A
- Morphine/Opiates	<input type="checkbox"/> Non-Negative	<input checked="" type="checkbox"/> Negative	<input type="checkbox"/> N/A
- P C P/Phencyclidine	<input type="checkbox"/> Non-Negative	<input type="checkbox"/> Negative	<input checked="" type="checkbox"/> N/A
- Barbiturate	<input type="checkbox"/> Non-Negative	<input type="checkbox"/> Negative	<input checked="" type="checkbox"/> N/A
- Benzodiazepin	<input type="checkbox"/> Non-Negative	<input checked="" type="checkbox"/> Negative	<input type="checkbox"/> N/A
- Methadone	<input type="checkbox"/> Non-Negative	<input type="checkbox"/> Negative	<input checked="" type="checkbox"/> N/A
- Propoxyphene	<input type="checkbox"/> Non-Negative	<input type="checkbox"/> Negative	<input checked="" type="checkbox"/> N/A
- Oxycodone	<input type="checkbox"/> Non-Negative	<input type="checkbox"/> Negative	<input checked="" type="checkbox"/> N/A
- MDMA	<input type="checkbox"/> Non-Negative	<input checked="" type="checkbox"/> Negative	<input type="checkbox"/> N/A
- 6-MAM	<input type="checkbox"/> Non-Negative	<input type="checkbox"/> Negative	<input checked="" type="checkbox"/> N/A
BREATH ALCOHOL TEST			
- Alcohol	<input type="checkbox"/> Non-Negative	<input type="checkbox"/> Negative	<input checked="" type="checkbox"/> N/A

Jakarta, November 26, 2019



PT. KARTIKA BINA MEDIKATAMA
(dr. Esther Poerwantoro, Sp.PK)
Clinical Patologist

HEALTH ASSESSMENT REPORT

Of

ACHMAD CHOIRONI

01035755

Tuesday, 26 November 2019

MP BELTWAY CLINIC

Beltway Office Park, Annex Building, Ground Floor

Jl. TB. Simatupang Kav.41, Jakarta Selatan 12550

Tlp : (62-21) 808 66 099, Fax : (62-21) 808 66 098

www.medikaplaza.com

MP BELTWAY CLINIC

Beltway Office Park, Annex Building, Ground Floor
Jl. TB. Simatupang Kav.41, Jakarta Selatan 12550
Tlp : (62-21) 808 66 099, Fax : (62-21) 808 66 098
www.medikapla.com

PATIENT DATA

MedRec.	: 01035755	EMPLOY. STATUS	: Employee
NAME	: ACHMAD CHOIRONI	BIRTHDATE	: 02 March 1983
EMPLOYEE No.	:	SEX	: Male
JOB TITLE	: SPV	STATUS	: Married
COMP. NAME	: INSPEKTINDO SINERGI PERSADA, PT	NASIONALITY	: Indonesia

SUMMARY

MEDICAL FINDING :

1. Hypertriglyceridemia
2. Non reactive Anti HBs
3. Overweight
4. Prehypertension
5. Decayed, radix, and calculus teeth
6. Severe conductive hearing loss of righ ear and Decreasing of hearing acuity on high and low frequency of left ear

Your fitness status is fit with medical note:

1. Hypertriglyceridemia
2. Severe conductive hearing loss of righ ear

PERCEPTIONS OF EXPOSURE BY WORKERS :

- Dust
- Others (Onshore/offshore)
- Stand continuously over 4 hours

SUGGESTION :

1. Low fat and carbohydrate diet, exercise regularly minimal 3 times a week. Consultation with an Internist for further evaluation of Hypertrygliceridemia
2. Need to get Hepatitis B vaccination (booster)
3. Reduce body weight gradually 0.5 Kgs/week, by doing regular exercise (aerobic/jogging), 3-4x/week, 30-45 minutes and reduce high calorie diet until maximal body weight is 60.84Kgs (present body weight is 72.1Kgs). Consultation with a Nutritionist for evaluation of overweight
4. Low salt diet and monitor your blood pressure regularly minimal once in two weeks. Consult to a cardiologist, if your blood pressure tends to increase.
5. Consultation with a Dentist for dental care, minimal once a year or better once in six month
6. Avoid noisy environment or use earplug properly while working at noisy work environment to prevent further hearing impairment. Consultation with an ENT Specialist for further evaluation and examination of Severe conductive hearing loss of righ ear

Responsible Doctor



Puteri Melati, MD

Notes:

If you need the further information or consultation, please contact us via :

Email : - beltway.doctor@medikapla.com
- beltway.doctor2@medikapla.com

Telepon Klinik : (62-21) 8086 6000

CLINICAL EVALUATION

Name : ACHMAD CHOIRONI	Sex : Male	MR : 01035755	Visit : 26/11/2019
Comp. : INSPEKTINDO SINERGI PERSADA, PT		DOB : 02 March 1983	

EXAMINATION	RESULT	NOTES
-------------	--------	-------

ANAMNESA

PRESENT COMPLAINT AND HISTORY OF PRESENT

ILLNESS

Present complaint

No complaint

MEDICAL HISTORY

Alergy	No
Imunisasi	Yes
Surgery	No
Hospitalization	No
Disease	No

LIFE STYLE

Alcohol intake	No	
Smoking	Yes	Mild smoker
Exercise	Yes	Futsal

FAMILY MEDICAL HISTORY

Diabetes Melitus	No
Hypertension	No
Heart disease	No
Lung TB	No
Kidney disease	No
Astma	No
Mental disease	No
Epilepsy	No
Cancer	No
Color blind	No
Stroke	No
Liver disease	No
Bone & joint	No
Others disease	No

WORK EXPOSURE

Noise	No
Heat Stress	No
Cold Stress	No
Vibration	No
Involving height	No
Radiation	No
Dust	Yes

CLINICAL EVALUATION

Name : ACHMAD CHOIRONI	Sex : Male	MR : 01035755	Visit : 26/11/2019
Comp.: INSPEKTINDO SINERGI PERSADA, PT		DOB : 02 March 1983	

EXAMINATION	RESULT	NOTES
Toxic chemical	No	
Irritating fluid	No	
Smoke	No	
Bacterium/Virus/Parasite	No	
Blood	No	
Animal	No	
Operating heavy mobile equipment	No	
Manual Handling	No	
Sitting continuously over 4 hours	No	
Stand continuously over 4 hours	Yes	
Using monitor screen more than 4 hours per day	No	
Exposure	No	
Unergonomic body positions	No	
Shift work	No	
Work is not accordance with skills and knowledge	No	
Workload does not accordance with time	No	
Work conflict	No	
Inappropriate task	No	
Career barriers	No	
Family conflict	No	
Working arround rotating machinery	No	
Administration work	No	
Handling food product	No	
Others	Yes	Onshore/offshore
PHYSICAL EXAMINATION		
General Appearance	Good	
Body shape	Picnicus	
VITAL SIGN		
Body Weight	72.1 Kg	
Body Height	156 Cm	
BMI	29.62 Kg/m2	
Normal Weight	45.02 - 60.84 Kg	
BMI Conclusion	Overweight	
Blood Pressure	130/80 mmHg	
Pulse	77 x/minute	
Body Temperature	36.6 °C	
RR	20	

CLINICAL EVALUATION

Name : ACHMAD CHOIRONI	Sex : Male	MR : 01035755	Visit : 26/11/2019
Comp.: INSPEKTINDO SINERGI PERSADA, PT		DOB : 02 March 1983	

EXAMINATION	RESULT	NOTES
Neck Circumference	42 Cm	
Arm Circumference	33 Cm	
Chest size	92 Cm	
Abdominal Circumference	88 Cm	
SKIN		
Skin	Normal	
EYE		
Left	Normal	
Right	Normal	
ENT		
Auricle	Normal	
Ear canal	Normal	
Drums	Normal	
Septum/Conchae	Normal	
Sinuses	Normal	
Pharynx	Normal	
Tonsil	Normal	
MOUTH		
Gum	Normal	
Dental	Abnormal	Decayed, radix, and calculus teeth
NECK		
General	Normal	
Thyroid Gland	Normal	
CHEST		
Form	Normal	
Lung	Normal	
Heart	Normal	
Breast	Normal	
ABDOMEN		
Form	Flat	
Palpation	Supple	
Liver	Not Palpable	
Spleen	Not Palpable	
Kidney	No Ballotment	
-	No	
Hernia inguinal	No	
EXTRIMITIES		

CLINICAL EVALUATION

Name : ACHMAD CHOIRONI	Sex : Male	MR : 01035755	Visit : 26/11/2019
Comp. : INSPEKTINDO SINERGI PERSADA, PT		DOB : 02 March 1983	

EXAMINATION	RESULT	NOTES
Bones, joint	Normal	
Muscles, tonus	Normal	
Fingernails	Normal	
Hand	Normal	
Foot	Normal	
RECTAL EXAMINATION		
Hemorrhoid	Negative	
Rectum	Normal	
SENSORIK EXAMINATION		
Tes Raba	Normal	
MOTORIK EXAMINATION		
Tes Grip	Normal	
REFLEX EXAMINATION		
Physiologic reflex	Normal	
Patologic reflex	Normal	
OTHERS EXAMINATION		
Coordination	Normal	
LYMPHE SYSTEM		
Submandibula	Normal	
Neck Gland	Normal	
Armpit gland	Normal	
Inguinal	Normal	

OPHTHALMOLOGY DIAGNOSTIC

Name : ACHMAD CHOIRONI	Sex : Male	MR : 01035755	Visit : 26/11/2019
Comp. : INSPEKTINDO SINERGI PERSADA, PT		DOB : 02 March 1983	

EXAMINATION		Right	Left
Reading		-	
Previous Glasses		-	-
Without Glasses	Distant	20/20	20/20
	Near	J1	J1
Correction	Distant	-	-
	Near	-	-
Depth Perception		-	
Tonometry		13.0 mmHg	13.0 mmHg
Funduscopy		NORMAL	NORMAL
Visual Fields		-	
Colour Blind Test		Normal	

Impression :

RADIOLOGY DIAGNOSTIC

Name : ACHMAD CHOIRONI

Sex : Male

MR : 01035755

Visit : 26/11/2019

Comp.: INSPEKTINDO SINERGI PERSADA, PT

DOB : 02 March 1983

EXAMINATION

RESULT

THORAX PA

No abnormality seen in both lungs.
Normal bronchovascular markings in both hili.
The heart is normal in size and shape.
The mediastinum is not widened.
Both sinus and diaphragms are good.
No evidence of pleural effusion.

Impression

Normal chest.
No evidence of specific process in both lungs.

LABORATORY RESULT

Name : ACHMAD CHOIRONI	MR : 01035755	Visit : 26/11/2019	#Lab : IN68732677454
Comp. : INSPEKTINDO SINERGI PERSADA, PT	Sex : Male	DOB : 02 March 1983	

EXAMINATION	RESULT	NORMAL RANGE
-------------	--------	--------------

HEMATOLOGI

ABO/Rh Typing "A" Rh(+) positive

Automated Blood Count

White Blood Cell (WBC)	9.0	3.8 - 11.0
Erythrocyte (RBC)	5.4	4.4 - 5.9
Haemoglobin	15.7	13.2 - 17.3
Hematocrit	45	40 - 52
Thrombocytes	334	150 - 440

MCV, MCH, MCHC

MCV	83	80 - 100
MCH	29	26 - 34
MCHC	35.0	32 - 36
ESR	28 *	0 - 10

Differential Count

Basophils	1	0 - 1
Eosinophil	8 *	2 - 4
Bands / Stab	1 *	3 - 5
Neutrophils	49 *	50 - 70
Lymphocytes	34	25 - 40
Monocytes	7	2 - 8

BLD CHEMISTRY/LIPID PROFILE

Total Cholesterol	196	Normal/Desireable: <200 Borderline High: 200-239 High: >=240
HDL Cholesterol	38.2 *	Normal : >40 - <60 Low HDL : <40 Desireable : >=60
LDL Cholesterol	89	Optimal: <100 Near/Above Optimal: 100-129 Borderline High: 130-159 High: 160-189 Very High: >=190
Triglycerides	345 *	Normal : <150 Borderline High: 150-199 High : 200-499 Very High : >=500

BLD CHEMISTRY/KIDNEY FUNCTION

LABORATORY RESULT

Name : ACHMAD CHOIRONI	MR : 01035755	Visit : 26/11/2019	#Lab : IN68732677454
Comp. : INSPEKTINDO SINERGI PERSADA, PT	Sex : Male	DOB : 02 March 1983	

EXAMINATION	RESULT	NORMAL RANGE
Ureum	27.8	10.0 - 50.0
Creatinine	1.1	0.6- 1.3
Uric Acid	6.58	3.50 - 7.20

BLD CHEMISTRY/LIVER FUNCTION

SGOT(AST)	29	13 - 45
SGPT (ALT)	37	13 - 50

BLD CHEMISTRY/ELECTROLYTES

Sodium (Na)	135	135 - 155
Potassium (K)	4.5	3.6 - 5.5
Chloride (Cl)	105	95 - 108

BLD CHEMISTRY/DIABETES

Glucose Fasting	89	< 100
Glucose Urine	Negative	Negative
Keton Urine	Negative	Negative

Blood Glucose 2 PP

Blood Sugar 2 Hours PP	86	< 140
Glucose Urine	Negative	Negative
Keton Urine	Negative	Negative

SEROLOGI / IMUNOLOGI

HBsAg (Quantitative)	0.00	0.00 - 0.03
Anti Hbs (Quantitative)	0.0 *	>= 5.0

TOXICOLOGY - DRUGS SCREENING

MDMA	Negative	Negative
THC/Marijuana	Negative	Negative
Amphetamine	Negative	Negative
Benzodiazepines	Negative	Negative
Opiat	Negative	Negative
Cocain	Negative	Negative

URINALYSIS**Complete Urine Analysis****Macroscopic**

Color	Light Yellow	
Turbidity	Clear	Clear
Specific Gravity	1.017	1.000 - 1.030
pH	5.5	4.5 - 8.0
Leucocyte	Negative	Negative
Glucose	Negative	Negative

LABORATORY RESULT

Name : ACHMAD CHOIRONI	MR : 01035755	Visit : 26/11/2019	#Lab : IN68732677454
Comp. : INSPEKTINDO SINERGI PERSADA, PT	Sex : Male	DOB : 02 March 1983	

EXAMINATION	RESULT	NORMAL RANGE
Nitrit	Negative	Negative
Bilirubin	Negative	Negative
Blood	Negative	Negative
Urobilinogen	Normal	Normal
Protein	Negative	Negative
Keton	Negative	Negative
Microscopic		
RBC	0-1	0 - 1
WBC	0-1	0 - 4
Cylinder	Negative	
Epithels Squamous	0-1	5 - 15
Crystals	Negative	
Bacteria	Negative	Negative
Others	Negative	

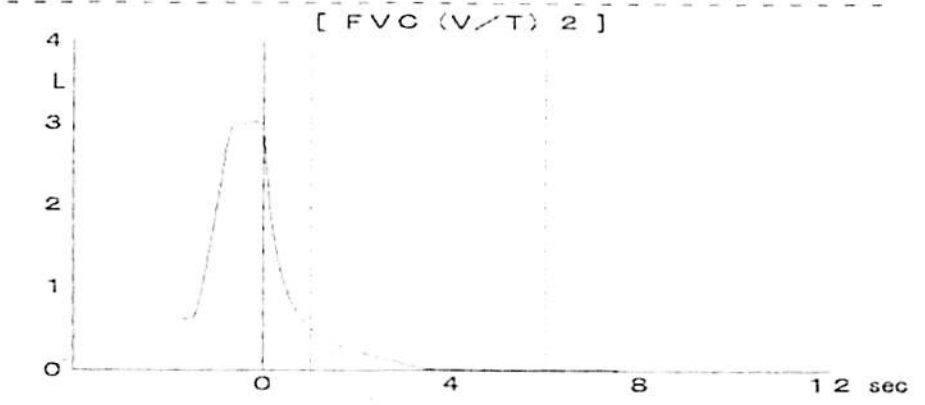
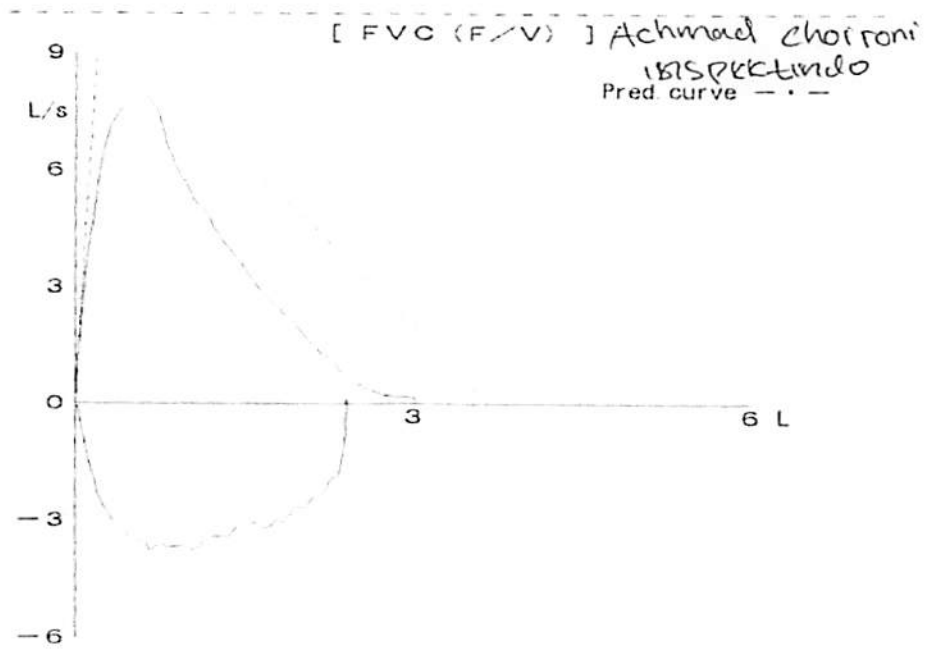
SPIROMETRY DIAGNOSTIC

Name : ACHMAD CHOIRONI	Sex : Male	MR : 01035755	Visit : 26/11/2019
Comp. : INSPEKTINDO SINERGI PERSADA, PT	DOB : 02 March 1983		

EXAMINATION	RESULT
-------------	--------

FVC Result	: 3.03 L---> 82.3 %
FEV1 Result	: 2.52 L---> 79.2 %
FEV1/FVC Result	: 83.17 %---> 106.1 %
PEF Result	: 7.92 L/S---> 78.4 %
Indonesian Standart Result	:
Index	:
Spirometry Result	: Normal

Impression : Normal Spirometric Functions



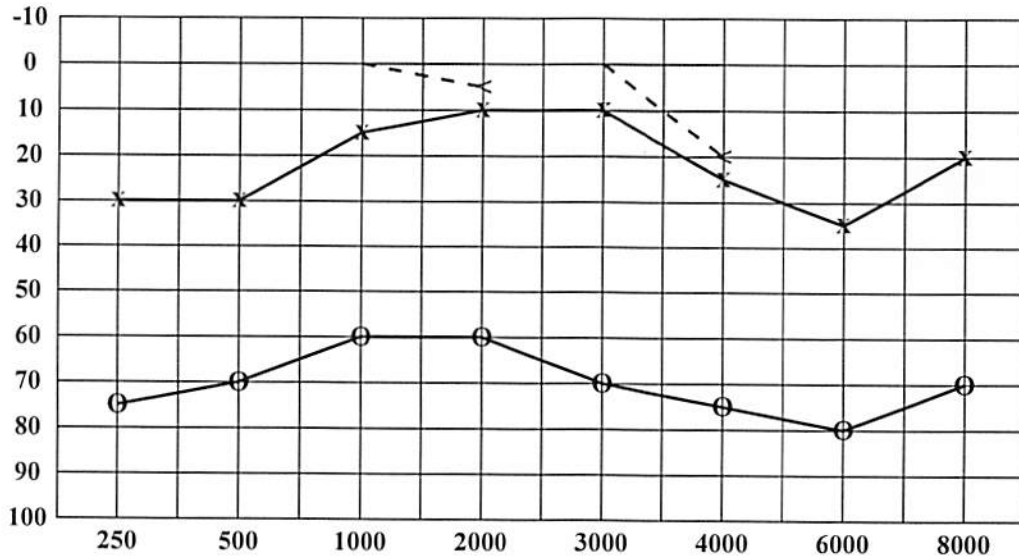
AUDIOMETRY DIAGNOSTIC

Name : ACHMAD CHOIRONI	Sex : Male	MR : 01035755	Visit : 26/11/2019
Comp. : INSPEKTINDO SINERGI PERSADA, PT		DOB : 02 March 1983	

RESULT

Left Ear	250	500	1000	2000	3000	4000	6000	8000
AC	30	30	15	10	10	25	35	20
BC	-	-	-	-	-	-	-	-

Right Ear	250	500	1000	2000	3000	4000	6000	8000
AC	75	70	60	60	70	75	80	70
BC	-	-	-	5	-	20	-	-



Conclusion Right Ear : Severe conductive hearing loss = 66.25 dB
 With decreasing on frequency
 250Hz, 4000Hz, 6000Hz, 8000Hz

Conclusion Left Ear : Hearing threshold = 20 dB
 (Within normal limit)
 With decreasing on frequency 250Hz & 6000Hz

CARDIOLOGY DIAGNOSTIC

Name : ACHMAD CHOIRONI	Sex : Male	MR : 01035755	Visit : 26/11/2019
Comp. : INSPEKTINDO SINERGI PERSADA, PT		DOB : 02 March 1983	

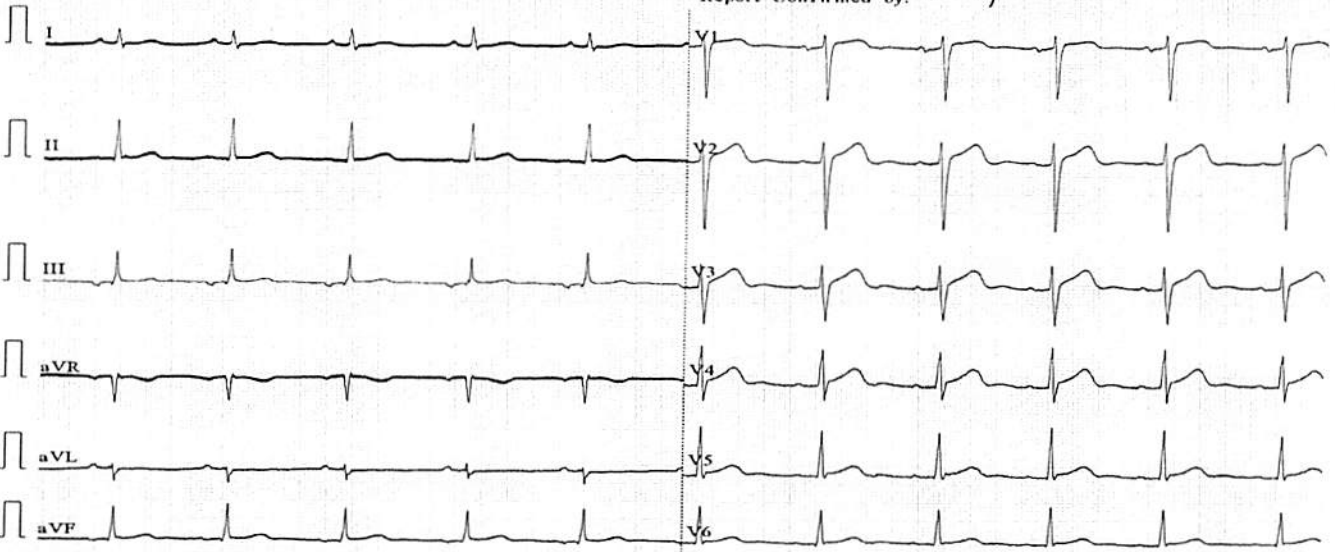
EXAMINATION	RESULT	Comments :
ELECTROCARDIOGRAPHY	Sinus Rythm axis (N), P wave (N), PR int 0.16" ST - T segment (N), aritmia (-)	Normal ECG
TREADMILL	Sinus Rythm axis (N), P wave (N), PR int 0.16" ST - T segment (N), aritmia (-)	Treadmill Exercise Test : Negative Cardiopulmonary Fitness Classification : Good METs : 12.6

ID: 05
ACHMAD CHOIRONI
Male 36Years

26-11-2019 07:16:35
HR : 65 bpm
P : 102 ms
PR : 172 ms
QRS : 92 ms
QT/QTc : 420/437 ms
P/QRS/T : -16/74/64
RV5/SV1 : 1.266/1.413 mV

Diagnosis Information:
Possible ectopic atrial rhythm
Borderline ECG

Report Confirmed by:



0.67-100Hz AC50 25mm/s 10mm/mV 2*5.0s ♡65 SB-1200Express V2.21 Glasgow V28.6.0

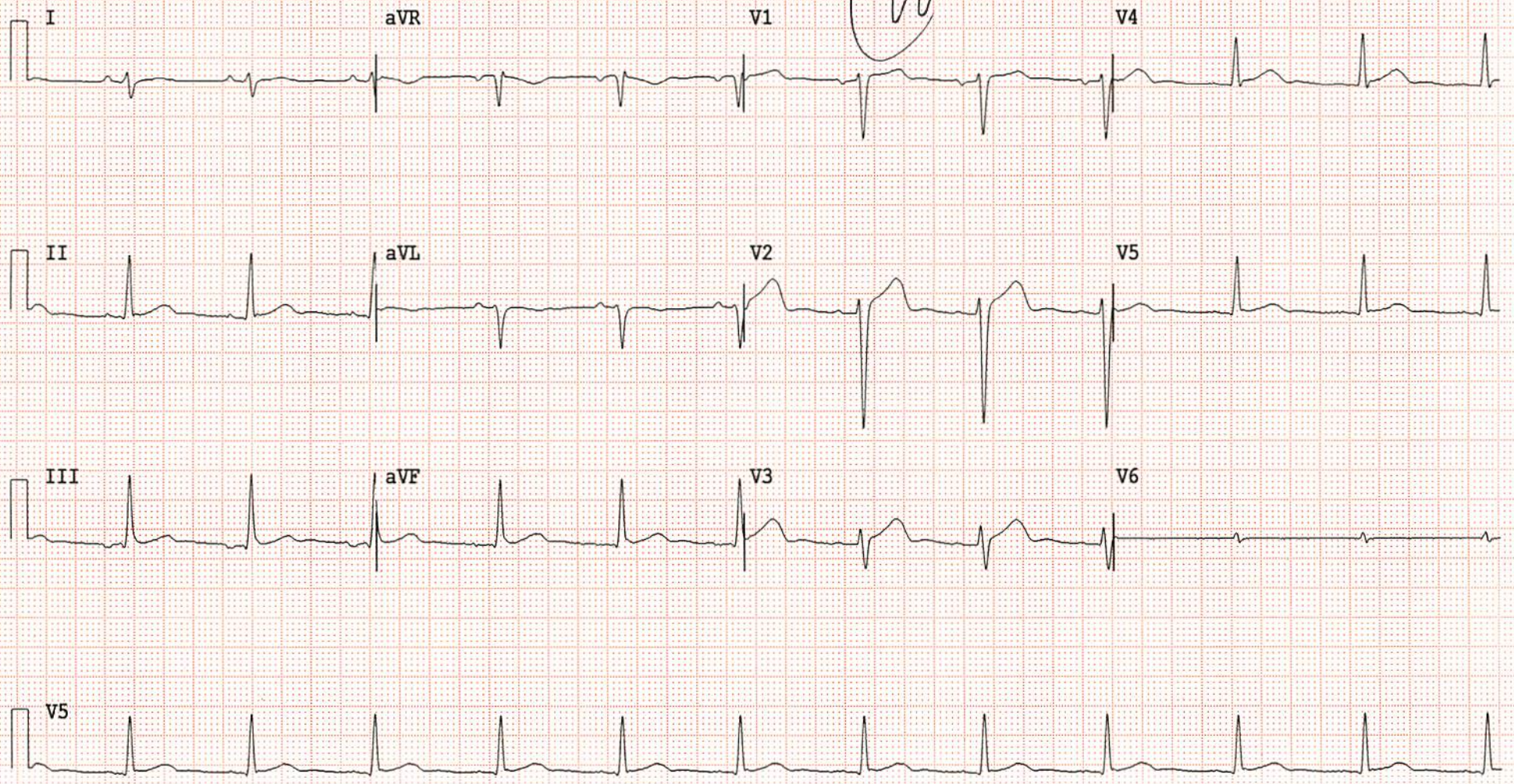
Name: ACHMAD CHOIRONI
ID: INSPEKTINDO 11/26/2019 07:46:56

HR: 72 Medication(s): No Medication
BP: 140/90 : No Medication
Age: 36 Years Clin. Class: Normal
Gender: Male : Normal
Race: Oriental Department: MEDIKA PLAZA
Height: 156 cm Technician: Pr.Agung
Weight: 72 Kg Physician: Dr.Adolf DSJP

	I	aVR	V1	V4
L	0.5	-0.7	1.2	1.5
S	0.4	-0.5	0.2	0.7
	II	aVL	V2	V5
L	0.8	0.1	3.8	0.7
S	0.5	0.1	1.9	0.3
	III	aVF	V3	V6
L	0.3	0.5	2.6	0.0
S	0.0	0.3	1.4	0.1

Levels measured at 80mS Post-J Levels in mm Slope in uV/mS

Baseline ECG



Name: ACHMAD CHOIRONI

Worst Case S-T Depression

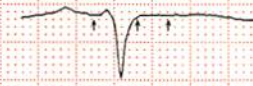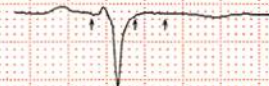
ID: INSPEKTINDO

11/26/2019 07:49:54

HR: 93 Phase: Exercise
BP: 140/90 Exercise Time: 02:50
RPE: 1/02:50 Stage/Time: 1/02:50
METs: 4.6 Workload: 2.7 kmh 10.0 % grade
Protocol: Bruce

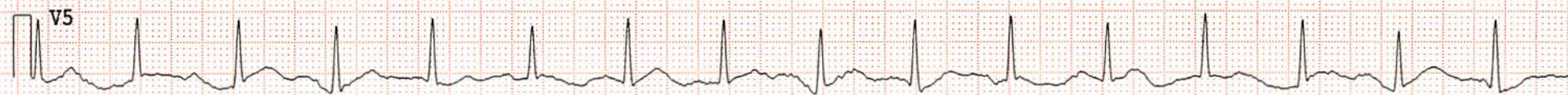
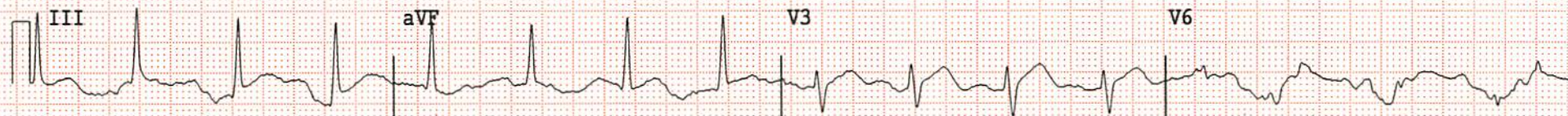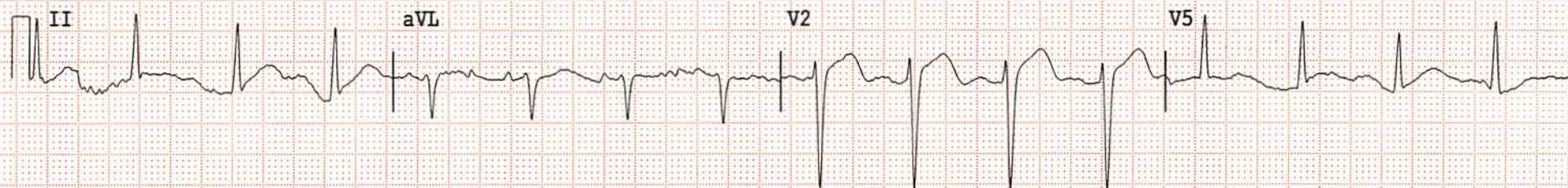
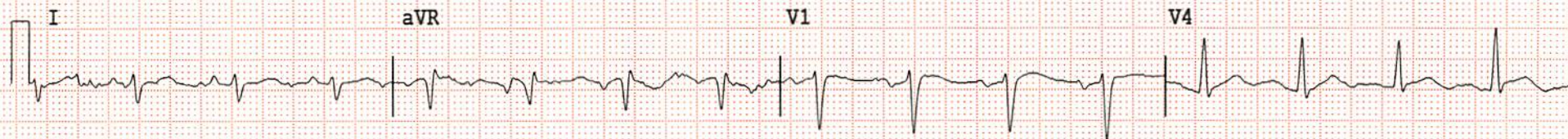
Baseline

Current



aVL
L 0.1
S 0.1
J+80ms

aVL
L 0.0
S 0.1
J+80ms



Name: ACHMAD CHOIRONI

Worst Case S-T Depression

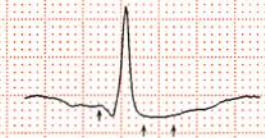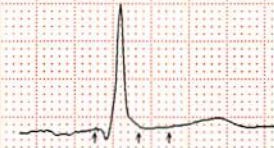ID: INSPEKTINDO

11/26/2019 07:52:54

HR: 107 Phase: Exercise
 BP: 150/90 Exercise Time: 05:50
 RPE: Stage/Time: 2/02:50
 METs: 7.0 Workload: 4.0 kmh 12.0 % grade
 Protocol: Bruce

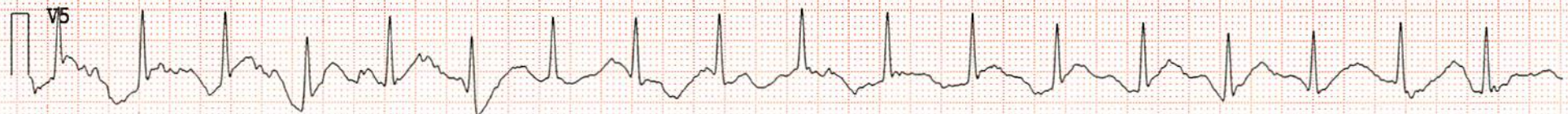
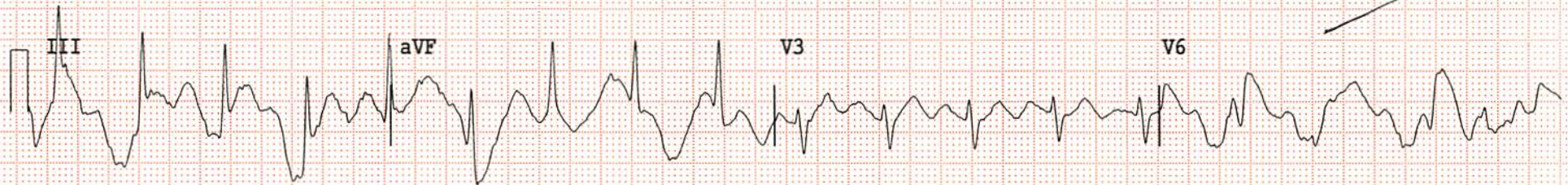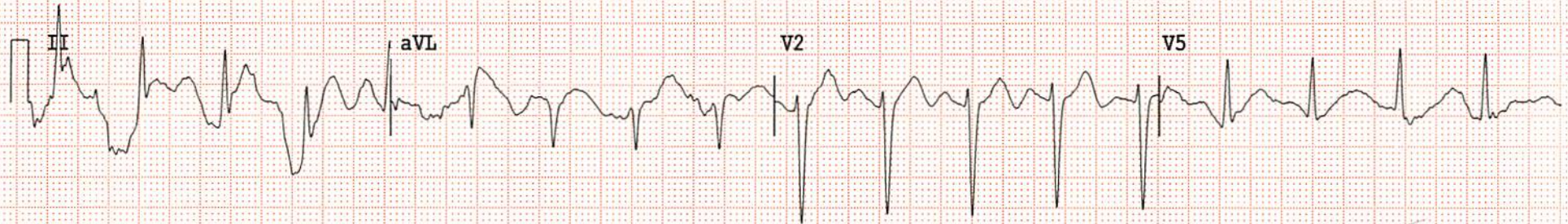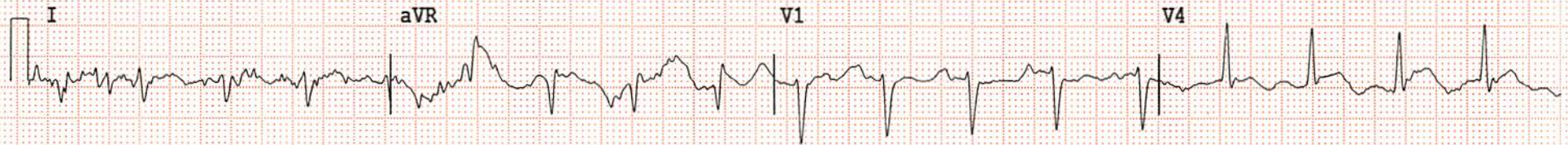
Baseline

Current



III
 L 0.3
 S 0.0
 J+80ms

III
 L -1.1
 S 0.0
 J+80ms



Name: ACHMAD CHOIRONI

Worst Case S-T Depression

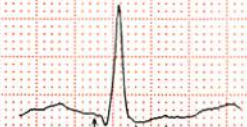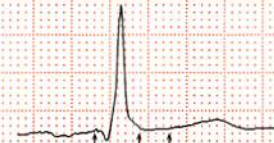ID: INSPEKTINDO

11/26/2019 07:55:54

HR: 131 Phase: Exercise
 BP: 160/100 Exercise Time: 08:50
 RPE: Stage/Time: 3/02:50
 METs: 10.0 Workload: 5.4 kmh 13.9 % grade
 Protocol: Bruce

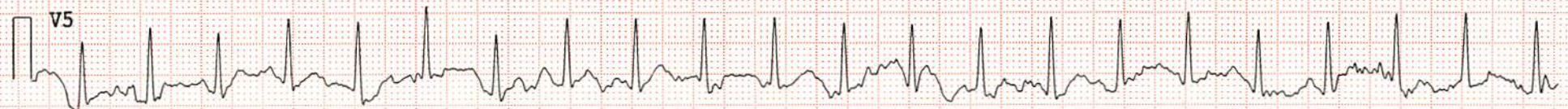
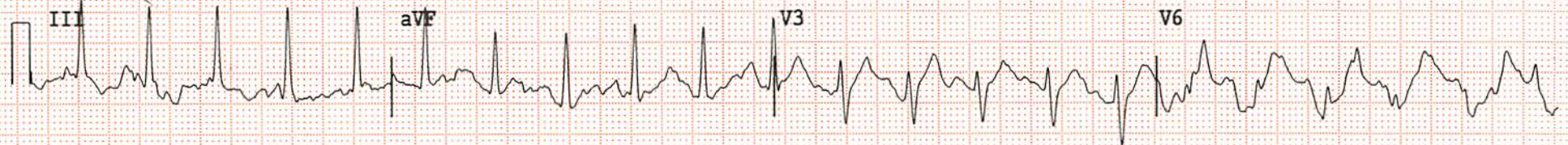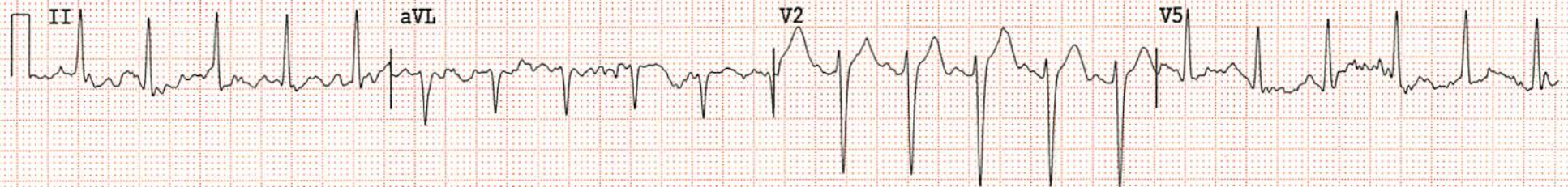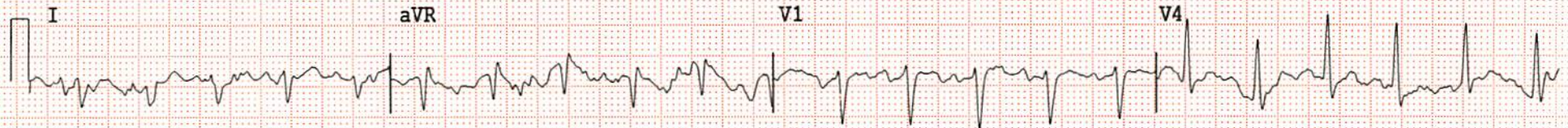
Baseline

Current



III
 L 0.3
 S 0.0
 J+80ms

III
 L -0.2
 S 1.2
 J+80ms



Name: ACHMAD CHOIRONI

Worst Case S-T Depression

ID: INSPEKTINDO

11/26/2019 07:57:37

HR: 156

Maximum Exercise

BP: 160/100

Exercise Time: 10:33

RPE:

Stage/Time: 4/01:33

METs: 12.6

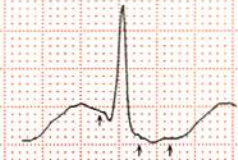
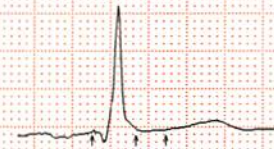
Workload: 6.7 kmh 16.1 % grade

Protocol: Bruce

Bruce

Baseline

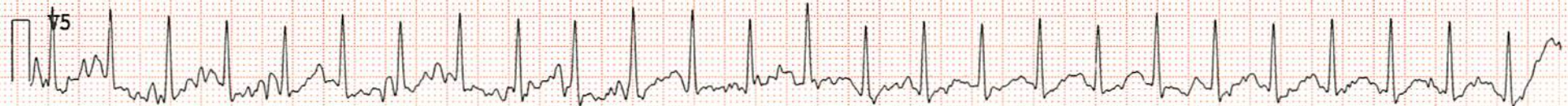
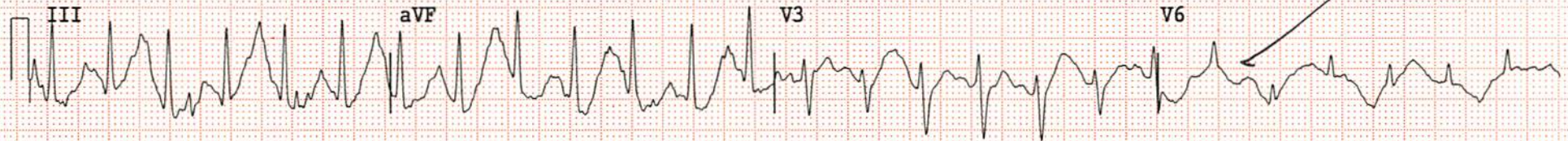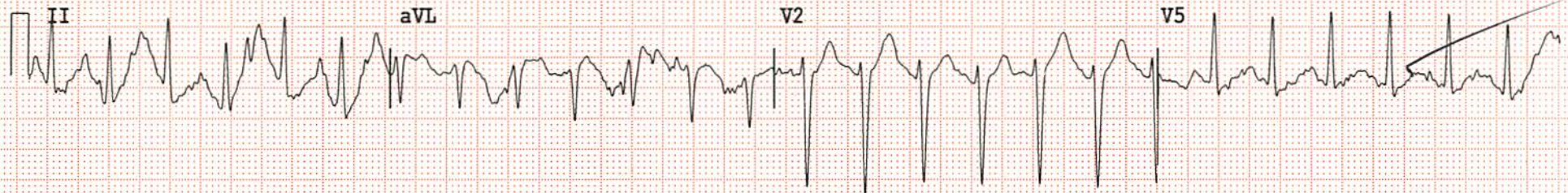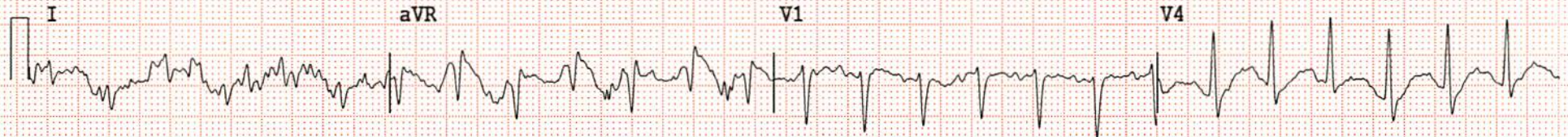Current



III
L 0.3
S 0.0
J+80ms

III
L -3.6
S 2.2
J+80ms

MAXIMUM EXERCISE ECG



Name: ACHMAD CHOIRONI

FINAL REPORT TEST SUMMARY

ID: INSPEKTINDO

11/26/2019 07:58:05

SUMMARY:

- The Bruce test ran for 10:33 mins. Peak METs was 12.6
- A peak heart rate of 156 bpm was achieved at 10:32 mins in exercise.
- 85% of the 184 bpm max was reached.
- The peak BP was 160/100 (during Exercise). Baseline was 140/90.

S-T SEGMENT ANALYSIS:

- Lead III first exercise depression exceeded 03:40 of Exercise
- ST depression exceeded 01:30 mins.
- 4.1mm maximum depression was exhibited at Exercise.

Medication(s): No Medication
: No Medication

Age: 36 Years

Clin. Class: Normal

Gender: Male

: Normal

Race: Oriental

Department: MEDIKA PLAZA

Height: 156 cm


Technician: Pr.Agung

Weight: 72 Kg

Physician: Dr.Adolf DSJP

Protocol: Bruce

TIME	PHASE	KMH	GRADE	HR	BP	RPP	METS	ECTOPIC	RPE	EVENTS	COMMENTS
00:00	Exercise	1.3	0.0	75			1.0			Bruce	
01:00	Exercise	2.7	10.0	92	140/90	128	2.1				
02:00	Exercise	2.7	10.0	93			4.2				
03:00	Exercise	2.7	10.0	96	140/90	134	4.6				
04:00	Exercise	4.0	12.0	102	140/90	142	5.7				
05:00	Exercise	4.0	12.0	109	140/90	152	7.0				
06:00	Exercise	4.0	12.0	108	150/90	162	7.0				
07:00	Exercise	5.4	13.9	123			8.4				
08:00	Exercise	5.4	13.9	128			10.0				
09:00	Exercise	5.4	13.9	132	160/100	211	10.0				
10:00	Exercise	6.7	16.1	151	160/100	241	11.8				
10:33	Max Exer.	6.7	16.1	156	160/100	249	12.6				
00:28	Recovery	2.0	0.0	141			10.1				



PT. KARTIKA BINA MEDIKATAMA

**CONSULTATION
SHEET**

PATIENT NAME : Tn. Achmad Cholroni
No. RM : 01.035755 / Inspektindo
Klinik/MCU/HCU : ENT (S)

To. Dokter :
(Counsel)

Kindly please counsel for patient who has take cares of

Diagnose :
Clinik Summary :

Counsel Request :

COUNSEL ADVISE : the tympanic sklerotic both ear, cerumen mm. Right ear
Wose Cal euhpy, sepleu devuto left nose

Finding : Kwant T₁T₃ , with krupta.

Diagnosis : Severe Heavy loss 02,5dB Right ear
Unilateral Hypertrophy tonsil, Severe Heavy loss dextra.

Recomendation :
Date : 26/11/19

- Suggest to Tonsilectomy
- Use ear protection when working in noisy Area.

Time :
EP :

MP+
Signature
PT. KARTIKA BINA MEDIKATAMA
dr. MERISTIANA CHRISTIANE, Sp.THT-KI
SIP: 13/B.156/31.24.04/1.779.3/2018

Complete Name