


## Medical Screening Questionnaire And Examination Record

Surname: <u>ALFONSUS</u>		Forenames: <u>LIQUORI</u>		
Address: <u>Cluster Fresno Blok H-19 Jakarta</u>		Tel No: <u>0813 6464 8252</u>		
Date of Birth: <u>01 AUG 1992</u>				
GP's Name:				
GP's Address:				
Date of Last Offshore Medical:		Offshore Occupation/Job Title : <u>INSPECTION</u>		
Emergency Response Role :				
Social / Occupational History		Yes	No	Comments
(1)	Do you smoke? If so, how many per day?	✓		
(2)	If an ex-smoker, when did you give up?		✓	
(3)	Average weekly alcohol consumption: state quantity and type.		✓	
(4)	Have you been exposed to any known occupational hazard such as noise, radiation, dusts, asbestos, chemicals or lead?		✓	
(5)	Do you use protective clothing, safety glasses or hearing protection?	✓		
(6)	Have you ever developed any medical condition in connection with your occupation? If so, please give details eg hearing loss/skin condition/wheeze/backache/muscle strain/blood disease?	✓		
(7)	Have you suffered any industrial injury? If so, please give details:	✓		
(8)	Have you ever had any previous audiometric screening? Was this normal? State when and where.	✓		
(9)	Have you ever had any previous lung function screening? Was this normal? State when and where.	✓		
(10)	Have you ever been rejected from employment on medical ground?		✓	
(11)	Have you ever received compensation, or is there any industrial claim pending?		✓	
(12)	Have you ever been medivaced from an offshore installation?	✓		
Examining Physician's comments :				

*\* Source : Medical Aspects of Fitness for Work Offshore Guidance for Examining Physicians Oil & Gas UK, March 2008*

**Medical Screening Questionnaire And  
 Examination Record (cont'd)**

<b>Do you have, or have you been diagnosed as suffering from any of the following?</b> (Please circle and elaborate)			
Please circle and elaborate			
(1) Chest pain/heart pain	Yes	<input checked="" type="radio"/> No	
(2) High blood pressure / stroke	Yes	<input checked="" type="radio"/> No	
(3) Asthma / Epilepsy/Diabetes	Yes	<input checked="" type="radio"/> No	
(4) Peptic ulcer disease	Yes	<input checked="" type="radio"/> No	
(5) Kidney disease (eg stones)	Yes	<input checked="" type="radio"/> No	
(6) Psychiatric disorder (eg anxiety, depression)	Yes	<input checked="" type="radio"/> No	
(7) Tuberculosis	Yes	<input checked="" type="radio"/> No	
(8) Cancer	Yes	<input checked="" type="radio"/> No	
Do any of your immediate family (parents/brothers/sisters) have a history of any of the above conditions? Please specify :			

<b>Do you currently have any of the following?</b>			
(1) Backache/joint or muscular pain	Yes	<input checked="" type="radio"/> No	
(2) Hernia/rupture	Yes	<input checked="" type="radio"/> No	
(3) Visual Impairment	Yes	<input checked="" type="radio"/> No	
(4) Perforated eardrum / discharge from ear	Yes	<input checked="" type="radio"/> No	
(5) Recurrent indigestion	Yes	<input checked="" type="radio"/> No	
(6) Jaundice/hepatitis/gall bladder disease	Yes	<input checked="" type="radio"/> No	
(7) Change in bowel habit/diarrhoea	Yes	<input checked="" type="radio"/> No	
(8) Blood in stools/piles/haemorrhoids	Yes	<input checked="" type="radio"/> No	
(9) Shortness of breath/coughing up blood	Yes	<input checked="" type="radio"/> No	
(10) Recurrent bronchitis/pneumonia	Yes	<input checked="" type="radio"/> No	
(11) Blood in urine/kidney complications/stones	Yes	<input checked="" type="radio"/> No	
(12) Headaches/migraine/dizziness	Yes	<input checked="" type="radio"/> No	
Physician's comments :			
I certify that the above information is correct :			
 Signed : <u>Alfan Sugandi</u> ..... [ Employee ]			

\* Source : Medical Aspects of Fitness for Work Offshore Guidance for Examining Physicians Oil & Gas UK, March 2008

**Medical Screening Questionnaire And Examination Record (cont'd)**

**Medical Examination**

*To Be Completed By Examining Physician*

<b>Photographic ID :</b>	Passport number :	
	Driver's license number :	
	Other :	

Height	Weight	BMI	BP	Pulse	FEV <sub>1</sub>	FVC	FEV <sub>1</sub> /FVC	Urinalysis		
								Protein	Blood	Glucose
171 cm	93 kg	31.8 kg/m <sup>2</sup>	110/80 mmHg	77 X/ min			N/A	Neg	trace	Neg.

Vision Distance			Vision Near			Colour		VDU
L	Aided L	Both	L	Aided L	Both	Normal	Abnormal	
20/20			J1			✓		
R	Aided R		R	Aided R		✓		
20/20			J1					

	Normal	Abnormal	Comments
Audiometric Screening	✓		
Substance Abuse Screening	✓		
Stool Culture (Catering Crew)	✓		
<b>Further investigations</b>			
Blood tests		✓	1. Leukocytosis 3. Increase SPT, 6 gamma Gt level 2. Dyslipidemia 4. Leukocytoria (G-I)
Chest X-Ray	✓		Hematuria (trace)
Electrocardiograph (ECG) / Treadmill	✓		
Spirometry		N/A	
USG		✓	Fatty liver Right hydronephrosis e.g suspect water stone

\* Source : Medical Aspects of Fitness for Work Offshore Guidance for Examining Physicians Oil & Gas UK, March 2008

(Has been consulted to urologist)

DD/strichre.

**Medical Screening Questionnaire And  
 Examination Record (cont'd)**

	Normal	Abnormal	Comments
1. Eyes/pupils	✓		Per case d , calculus , impacted , filled teeth
2. Ear, nose and throat	✓		
3. Teeth		✓	
4. Lungs/chest	✓		
5. Cardiovascular	✓		
6. Abdomen	✓		
7. Hernial orifices	✓		
8. Genitourinary	✓		
9. Musculoskeletal	✓		
10. Skin	✓		
11. Varicose veins	✓		
12. Neurological	✓		
<b>Physician to comment on any abnormalities :</b>			

Certification	Comment/Reason
Fit for offshore work as per Oil & Gas UK guidelines	✓
Fit for restricted offshore work following discussion with operating company's medical adviser	
Temporarily unfit for offshore work	
Permanently unfit for offshore work	


Physician's signature :   
 Print name : **dr. Puteri Melati**   
 Date of examination : **SIP: 23/B. 15A/PTA KARTIKA, BINA MEDIKATAMA**  
 30/07/2020

\* Source : Medical Aspects of Fitness for Work Offshore Guidance for Examining Physicians Oil & Gas UK, March 2008

## Unrestricted Offshore Work Certificate

### Medical Certificate of Fitness for Offshore Work

( Issued in accordance with Oil and gas UK Guidelines )

<b>Name :</b>	ALFONSUS LIQUORI
<b>Date of Birth :</b>	01 August 1992
<b>Employing Company Name :</b>	INSPEKTINDO SINERGI PERSADA, PT
<b>Occupation :</b>	INSPECTOR
<p>This individual has been examined in accordance          with Oil &amp; Gas UK Guidelines and is  <b>Medical Fit for Unrestricted To The Job Described At Offshore Work</b></p>	
<b>Examining Physician Name :</b>	dr. Frans Denis Martogi
<b>Oil &amp; Gas UK PIN No. :</b>	OGUK/2017/2465
<b>Date of Examination :</b>	30 July 2020
<b>Date of Expiry of Certificate :</b>	30 July 2022
<b>Signed :</b>	

PT. KARTIKA BINA MEDIKATAMA

**PT. KARTIKA BINA MEDIKATAMA**

## MP BELTWAY CLINIC

Beltway Office Park, Annex Building, Ground Floor  
Jl. TB. Simatupang Kav.41, Jakarta Selatan 12550  
Tlp : (62-21) 808 66 099, Fax : (62-21) 808 66 098  
www.medikaplaza.com

### PATIENT DATA

MedRec.	: 01.00064128	EMPLOY. STATUS	: Employee
NAME	: ALFONSUS LIQUORI	BIRTHDATE	: 01 August 1992
EMPLOYEE No.	: -	SEX	: Male
JOB TITLE	: INSPECTOR	STATUS	: Single
COMP. NAME	: INSPEKTINDO SINERGI PERSADA, PT	NASIONALITY	: INDONESIA

### SUMMARY

#### MEDICAL FINDING :

1. Leukocytosis
2. Dyslipidemia
3. Increase SGPT, Gamma Gt level
4. Leukocyturia (+1), hematuria (trace)
5. Obesity
6. Decayed, calculus, impacted, and filled teeth
7. Decreasing of hearing acuity on high frequency of left ear
8. USG abdomen : Fatty liver. Right hydronephrosis ec suspect ureter stone DD/stricture (has been consulted to urologist)

#### PERCEPTIONS OF EXPOSURE BY WORKERS :

- Working around rotating machinery
- Involving height
- Administration work
- Others (Offshore and onshore)
- Sitting continuously over 4 hours
- Stand continuously over 4 hours
- Using monitor screen more than 4 hours per day
- Unergonomic body positions

Your fitness status is fit for unrestricted to the job described at offshore work

#### SUGGESTION :

1. Repeat Leukocyt examination after 1 month and consultation with an Internist if still increase
2. Low fat and carbohydrate diet and exercise regularly minimal 3 times a week. Consultation with an Internist for further evaluation of dyslipidemia
3. Take enough rest minimal 8 hours/day. Repeat SGPT and Gamma GT examination 1 month later and consult to an Internist if still increase
4. Drink more water at least 2lt/day (8-10 glasses/day). Repeat urinalysis after 2 weeks
5. Reduce body weight gradually 0.5 Kgs/week, by doing regular exercise (aerobic/jogging), 3-4x/week, 30-45 minutes and reduce high calorie diet until maximal body weight is 73.10 Kgs (present body weight is 93 Kgs). Consultation with a Nutritionist for evaluation of obesity
6. Consultation with a Dentist for dental care, minimal once a year or better once in six month
7. Avoid noisy environment and use earplug properly while working at noisy work environment to prevent further hearing impairment
8. Low fat diet and exercise regularly minimum 3x/week. Repeat abdominal USG 6 months later and consultation with an Internist to evaluate fatty liver. Consultation with an Urologist for further evaluation of Right hydronephrosis ec suspect ureter stone DD/stricture

#### Responsible Doctor



Puteri Melati, MD

#### Notes:

If you need the further information or consultation, please contact us via :

Email : - beltway.doctor@medikaplaza.com  
- beltway.doctor2@medikaplaza.com  
Telepon Klinik : (62-21) 8086 6000

PRIVATE

Printed by : reysti

Oilfield Services Indonesia

**PT. Schlumberger Geophysics Nusantara**  
Suite 4201, Wisma Mulia  
Jln. Gatot Subroto No 42,  
Jakarta 12710, Indonesia.

**SURAT RUJUKAN**

Kepada: dr Radiologist  
Di tempat

Dengan hormat,

Bersama ini kami rujuk karyawan kami:

Nama : Alfonsus Liquori  
Usia : 28 yo  
Pekerjaan : Karyawan

Dari hasil MCU dijumpai USG di daerah renal dengan gambaran right hidronephrosis ec urther stone, Dd stricture.

Urinalysis: hematuria (trace)

Mohon konsul untuk dilakukan BNO IVP atau pilihan lebih lanjut

Terima kasih atas bantuan dan kerjasamanya.

Jakarta, 5 Aug 2020

Salam Sejawat,



dr. James Siagian

**SURAT JAWABAN RUJUKAN**

Kepada:  
Dr. James Siagian  
Di tempat

Berdasarkan hasil pemeriksaan kami terhadap pasien di bawah ini:

Nama : Alfonsus Liquori  
Usia : 28 yo  
Pekerjaan : Karyawan

Didapatkan:  
Anamnesa: *Myxi saat BAK*

Pemeriksaan  
Fisik: *Myxi ke. k. f. k. (-)*

Pemeriksaan laboratorium dan atau penunjang  
lainnya: *USG: Btk Btk Ginjal*

Diagnosa: *Btk Btk*

Terapi yang  
diberikan: *Bism Btk Btk*  
*Tamsumo sda. ke*

Kesimpulan terhadap kondisi klinis pasien saat  
ini: *Pasien telah di terapi Bism Btk Btk &*  
*dirinya telah sembuh. Btk*

Fit untuk bekerja:  Ya  Tidak

21 Sept 2020

Dokter Pemeriksa

*Dr. Charles Johannes, SpU*  
Spesialis Urologi  
SIP: 5067157-Burkes/Sp/2017



### HASIL PEMERIKSAAN RADIOLOGI

No. RM : 200218  
Nama Pasien : ALFONSUS LIQUORI, TN.  
JK/Umur : L / 28 Th 0 Bl 6 Hr  
Alamat : CLUSTER FRESNO BLOK H DELTAMAS,  
No. Periksa : 2020/08/07/000204  
Pemeriksaan : CT- Abdomen Bawah Tanpa Kontras dengan Proyeksi : , kV : , mAS : , FFD : , BSF : , Inak : ,  
Jml Penyinaran : , Dosis Radiasi : ,  
Penanggung Jawab : dr. MUHAMMAD TAUFIQUR  
Dokter Pengirim : dr. CHARLES JOHANES, Sp.U  
Tgl. Pemeriksaan : 07-08-2020  
Jam Pemeriksaan : 10:32:30  
Poli : POLI UROLOGI

#### Hasil Pemeriksaan :

Dilakukan MSCT scan abdomen sampai pelvis potongan aksial. Dibuat rekonstruksi potongan coronal dan sagital. Scanning tanpa memakai kontras oral dan intravena.

#### Scanning daerah :

Gaster : ukuran tidak membesar, tidak tampak massa.

Hepar : ukuran tidak membesar, permukaan rata, densitas homogen. Tidak tampak massa. Vena porta tidak melebar. Vena hepatica tidak melebar. Venacava inferior tidak melebar. Duktus biliaris intrahepatal tidak melebar. Tidak tampak koleksi cairan di sekitarnya.

Kantung empedu : ukuran tidak membesar, dinding tidak menebal, reguler. Tidak tampak massa/batu. Duktus biliaris ekstrahepatal tidak melebar.

Limpa : ukuran tidak membesar, densitas homogen. Vena lienalis tidak melebar. Tidak tampak koleksi cairan di sekitarnya.

Pankreas : ukuran tidak membesar, densitas homogen, duktus pankreatikus tidak melebar.

Ginjal kanan : ukuran tidak membesar, struktur parenkim homogen, sistem pelvokalises tidak melebar, tidak tampak batu/ massa.

Ginjal kiri : ukuran tidak membesar, struktur parenkim homogen, sistem pelvokalises tidak melebar. Tampak lesi hiperdens densitas batu diameter l.k 6.1 mm pada pool atas.

Vesika urinaria : terisi penuh, dinding tidak menebal. tidak tampak batu/massa. Perivesical fat normal.

Rektum : posisi normal, dinding tidak menebal, perirectal fat normal.

#### Kesimpulan :

MSCT Scan abdomen sampai pelvis menunjukkan :

- Nefrolithiasis sinistra.
- Scanning hepar, kantung empedu, limpa, pankreas, ginjal kanan, vesika urinaria dan rektum

Penanggung Jawab



Tgl.Cetak : 07/08/2020 10.32.32

Petugas Radiologi



ARI WIBOWO



## Certificate Of Health Assessment

Name	Age	Position	Department
ALFONSUS LIQUORI	28 yo	INSPECTOR	-

COMPANY :
<b>INSPEKTINDO SINERGI PERSADA, PT</b>

### CONCLUSION

FIT TO WORK	
FIT WITH MEDICAL NOTE	
TEMPORARY UNFIT	✓
UNFIT	

Issued Date	Doctors Name	Prepared By
30 July 2020	<b>Puteri Melati, MD</b> <small>PKTK : KEP.264/BINWASK3-PNK3/KK/VI/2019            SIP : 23/B.15a/31.74.04.1004/-1.779.3/e/2019</small>	
Expired Date		Verified By
30 July 2021	<b>dr. Muhammad Ilyas, Sp.Ok</b> <small>SIP : 29/B.15b/31.74.04.1004.02.009.K.1/3/-1.779.3/e/2019</small>	 <b>PT. KARTIKA BINA MEDIKATAMA</b>

No. Formulir : FM-DR-008-05  
 No. Revisi : 00  
 Tanggal Terbit : 2 Mei 2011

Certificate Number : MP-BOP/1-20200730/124593  
 MCU Validity Check  
<https://mcu-validasi.medikaplaza.com>

**PT. KARTIKA BINA MEDIKATAMA**



## TO WHOM IT MAY CONCERN

### *Kepada yang berkepentingan*

This is certify that today Thursday, 30 July 2020 Medika Plaza Clinic has performed urine drug screening and/or breath alcohol test to :

*Dengan ini menyatakan bahwa, pada hari ini Kamis, 30 Juli 2020 Medika Plaza Clinic telah melakukan urine drug screening dan/atau breath alcohol test kepada :*

### **ALFONSUS LIQUORI**

With the results are as follows :

*Dengan hasil sebagai berikut :*

<u>Drugs Test</u> <i>Uji Obat</i>	<u>Result</u> <i>Hasil</i>		
<b>URINE DRUGS SCREENING</b>			
- Amphetamine	<input type="checkbox"/> Non-Negative	<input checked="" type="checkbox"/> Negative	<input type="checkbox"/> N/A
- Met-Amphetamine	<input type="checkbox"/> Non-Negative	<input checked="" type="checkbox"/> Negative	<input type="checkbox"/> N/A
- Cocain	<input type="checkbox"/> Non-Negative	<input checked="" type="checkbox"/> Negative	<input type="checkbox"/> N/A
- THC/Canabis/Marijuana	<input type="checkbox"/> Non-Negative	<input checked="" type="checkbox"/> Negative	<input type="checkbox"/> N/A
- Morphine/Opiates	<input type="checkbox"/> Non-Negative	<input checked="" type="checkbox"/> Negative	<input type="checkbox"/> N/A
- P C P/Phencyclidine	<input type="checkbox"/> Non-Negative	<input checked="" type="checkbox"/> Negative	<input type="checkbox"/> N/A
- Barbiturate	<input type="checkbox"/> Non-Negative	<input type="checkbox"/> Negative	<input checked="" type="checkbox"/> N/A
- Benzodiazepin	<input type="checkbox"/> Non-Negative	<input checked="" type="checkbox"/> Negative	<input type="checkbox"/> N/A
- Methadone	<input type="checkbox"/> Non-Negative	<input checked="" type="checkbox"/> Negative	<input type="checkbox"/> N/A
- Propoxyphene	<input type="checkbox"/> Non-Negative	<input type="checkbox"/> Negative	<input checked="" type="checkbox"/> N/A
- Oxycodone	<input type="checkbox"/> Non-Negative	<input type="checkbox"/> Negative	<input checked="" type="checkbox"/> N/A
- MDMA	<input type="checkbox"/> Non-Negative	<input type="checkbox"/> Negative	<input checked="" type="checkbox"/> N/A
- 6-MAM	<input type="checkbox"/> Non-Negative	<input type="checkbox"/> Negative	<input checked="" type="checkbox"/> N/A
<b>BREATH ALCOHOL TEST</b>			
- Alcohol	<input type="checkbox"/> Non-Negative	<input checked="" type="checkbox"/> Negative	<input type="checkbox"/> N/A

Jakarta, July 30, 2020



**PT. KARTIKA BINA MEDIKATAMA**  
( dr. Dian Wahyu Tanjungsari, Sp.PK )

Clinical Patologist

# **HEALTH ASSESSMENT REPORT**

*Of*

**ALFONSUS LIQUORI**  
**01.00064128**

**Thursday, 30 July 2020**

## **MP BELTWAY CLINIC**

Beltway Office Park, Annex Building, Ground Floor  
Jl. TB. Simatupang Kav.41, Jakarta Selatan 12550  
Tlp : (62-21) 808 66 099, Fax : (62-21) 808 66 098  
[www.medikaplaza.com](http://www.medikaplaza.com)

## MP BELTWAY CLINIC

Beltway Office Park, Annex Building, Ground Floor  
Jl. TB. Simatupang Kav.41, Jakarta Selatan 12550  
Tlp : (62-21) 808 66 099, Fax : (62-21) 808 66 098  
www.medikapla.com

### PATIENT DATA

MedRec.	: 01.00064128	EMPLOY. STATUS	: Employee
NAME	: ALFONSUS LIQUORI	BIRTHDATE	: 01 August 1992
EMPLOYEE No.	: -	SEX	: Male
JOB TITLE	: INSPECTOR	STATUS	: Single
COMP. NAME	: INSPEKTINDO SINERGI PERSADA, PT	NASIONALITY	: INDONESIA

### SUMMARY

#### MEDICAL FINDING :

1. Leukocytosis
2. Dyslipidemia
3. Increase SGPT, Gamma Gt level
4. Leukocyturia (+1), hematuria (trace)
5. Obesity
6. Decayed, calculus, impacted, and filled teeth
7. Decreasing of hearing acuity on high frequency of left ear
8. USG abdomen : Fatty liver. Right hydronephrosis ec suspect ureter stone DD/stricture

Your fitness status is temporary unfit

#### PERCEPTIONS OF EXPOSURE BY WORKERS :

- Working around rotating machinery
- Involving height
- Administration work
- Others (Offshore and onshore)
- Sitting continuously over 4 hours
- Stand continuously over 4 hours
- Using monitor screen more than 4 hours per day
- Unergonomic body positions

#### SUGGESTION :

1. Repeat Leukocyt examination after 1 month and consultation with an Internist if still increase
2. Low fat and carbohydrate diet and exercise regularly minimal 3 times a week. Consultation with an Internist for further evaluation of dyslipidemia
3. Take enough rest minimal 8 hours/day. Repeat SGPT and Gamma GT examination 1 month later and consult to an Internist if still increase
4. Drink more water at least 2lt/day (8-10 glasses/day). Repeat urinalysis after 2 weeks
5. Reduce body weight gradually 0.5 Kgs/week, by doing regular exercise (aerobic/jogging), 3-4x/week, 30-45 minutes and reduce high calorie diet until maximal body weight is 73.10 Kgs (present body weight is 93 Kgs). Consultation with a Nutritionist for evaluation of obesity
6. Consultation with a Dentist for dental care, minimal once a year or better once in six month
7. Avoid noisy environment and use earplug properly while working at noisy work environment to prevent further hearing impairment
8. Low fat diet and exercise regularly minimum 3x/week. Repeat abdominal USG 6 months later and consultation with an Internist to evaluate fatty liver. Consultation with an Urologist for further evaluation of Right hydronephrosis ec suspect ureter stone DD/stricture

#### Responsible Doctor



Puteri Melati, MD

#### Notes:

If you need the further information or consultation, please contact us via :

Email : - beltway.doctor@medikapla.com  
- beltway.doctor2@medikapla.com  
Telepon Klinik : (62-21) 8086 6000

## CLINICAL EVALUATION

Name : ALFONSUS LIQUORI	Sex : Male	MR : 01.00064128	Visit : 30/07/2020
Comp. : INSPEKTINDO SINERGI PERSADA, PT		DOB : 01 August 1992	

EXAMINATION	RESULT	NOTES
-------------	--------	-------

### ANAMNESA

#### PRESENT COMPLAINT AND HISTORY OF PRESENT

#### ILLNESS

Present complaint

No complaint

#### MEDICAL HISTORY

Allergy	Yes	Seafood
Imunisasi	Yes	
Surgery	Yes	Tonsilectomy (2000), and fracture metacarpal dextra (2009)
Hospitalization	Yes	Tonsilectomy (2000), and bicycle accident (2009)
Disease	No	

#### LIFE STYLE

Alcohol intake	Yes	Occasionally
Smoking	Yes	Mild smoker
Exercise	Yes	Jogging, and badminton 1x/week

#### FAMILY MEDICAL HISTORY

Diabetes Melitus	No	
Hypertension	Yes	Mother
Heart disease	No	
Lung TB	No	
Kidney disease	No	
Astma	No	
Mental disease	No	
Epilepsy	No	
Cancer	No	
Color blind	No	
Stroke	No	
Liver disease	No	
Bone & joint	No	
Others disease	No	

#### WORK EXPOSURE

Noise	No	
Heat Stress	No	
Cold Stress	No	
Vibration	No	
Involving height	Yes	

## CLINICAL EVALUATION

Name : ALFONSUS LIQUORI	Sex : Male	MR : 01.00064128	Visit : 30/07/2020
Comp.: INSPEKTINDO SINERGI PERSADA, PT		DOB : 01 August 1992	

EXAMINATION	RESULT	NOTES
Radiation	No	
Dust	No	
Toxic chemical	No	
Irritating fluid	No	
Smoke	No	
Bacterium/Virus/Parasite	No	
Blood	No	
Animal	No	
Operating heavy mobile equipment	No	
Manual Handling	No	
Sitting continuously over 4 hours	Yes	
Stand continuously over 4 hours	Yes	
Using monitor screen more than 4 hours per day	Yes	
Exposure	No	
Unergonomic body positions	Yes	
Shift work	No	
Work is not accordance with skills and knowledge	No	
Workload does not accordance with time	No	
Work conflict	No	
Inappropriate task	No	
Career barriers	No	
Family conflict	No	
Working arround rotating machinery	Yes	
Administration work	Yes	
Handling food product	No	
Others	Yes	Offshore and onshore
<b>PHYSICAL EXAMINATION</b>		
General Appearance	Good	
Body shape	Picnicus	
<b>VITAL SIGN</b>		
Body Weight	93 Kg	
Body Height	171 Cm	
BMI	31.8 Kg/m2	
Normal Weight	54.10 - 73.10 Kg	
BMI Conclusion	Obesity	
Blood Pressure	110/80 mmHg	
Pulse	77 x/minute	

## CLINICAL EVALUATION

Name : ALFONSUS LIQUORI	Sex : Male	MR : 01.00064128	Visit : 30/07/2020
Comp. : INSPEKTINDO SINERGI PERSADA, PT		DOB : 01 August 1992	

EXAMINATION	RESULT	NOTES
Body Temperature	36 °C	
RR	20	
Neck Circumference	43 Cm	
Arm Circumference	38 Cm	
Chest size	107 Cm	
Abdominal Circumference	104 Cm	
<b>SKIN</b>		
Skin	Abnormal	Tattoo in the chest, back and right lower leg, scar on right hand (history of fracture metacarpal dextra)
<b>EYE</b>		
Left	Normal	
Right	Normal	
<b>ENT</b>		
Auricle	Normal	
Ear canal	Normal	
Drums	Normal	
Septum/Conchae	Normal	
Sinuses	Normal	
Pharynx	Normal	
Tonsil	Normal	
<b>MOUTH</b>		
Gum	Normal	
Dental	Abnormal	Decayed, calculus, impacted, and filled teeth
<b>NECK</b>		
General	Normal	
Thyroid Gland	Normal	
<b>CHEST</b>		
Form	Normal	
Lung	Normal	
Heart	Normal	
Breast	Normal	
<b>ABDOMEN</b>		
Form	Flat	
Palpation	Supple	
Liver	Not Palpable	
Spleen	Not Palpable	



## CLINICAL EVALUATION

Name : ALFONSUS LIQUORI	Sex : Male	MR : 01.00064128	Visit : 30/07/2020
Comp. : INSPEKTINDO SINERGI PERSADA, PT		DOB : 01 August 1992	

EXAMINATION	RESULT	NOTES
Kidney	No Ballotment	
-	No	
Hernia inguinal	No	
<b>EXTRIMITIES</b>		
Bones, joint	Normal	
Muscles, tonus	Normal	
Fingernails	Normal	
Hand	Normal	
Foot	Normal	
<b>RECTAL EXAMINATION</b>		
Hemorrhoid	Negative	
Rectum	Normal	
<b>SENSORIK EXAMINATION</b>		
Tes Raba	Normal	
<b>MOTORIK EXAMINATION</b>		
Tes Grip	Normal	
<b>REFLEX EXAMINATION</b>		
Physiologic reflex	Normal	
Patologic reflex	Normal	
<b>OTHERS EXAMINATION</b>		
Coordination	Normal	
<b>LYMPHE SYSTEM</b>		
Submandibula	Normal	
Neck Gland	Normal	
Armpit gland	Normal	
Inguinal	Normal	

## OPHTHALMOLOGY DIAGNOSTIC

Name : ALFONSUS LIQUORI	Sex : Male	MR : 01.00064128	Visit : 30/07/2020
Comp.: INSPEKTINDO SINERGI PERSADA, PT		DOB : 01 August 1992	

EXAMINATION		Right	Left
Reading		-	-
Previous Glasses		-	-
Without Glasses	Distant	20/20	20/25
	Near	J1	J1
Correction	Distant	-	S-0.50 20/20
	Near	-	-
Depth Perception		-	-
Tonometry		18.0 mmHg	18.0 mmHg
Funduscopy		NORMAL	NORMAL
Visual Fields		Normal	
Colour Blind Test		Normal	

Impression : Myopia simplex OS

## RADIOLOGY DIAGNOSTIC

Name : ALFONSUS LIQUORI

Sex : Male

MR : 01.00064128

Visit : 30/07/2020

Comp. : INSPEKTINDO SINERGI PERSADA, PT

DOB : 01 August 1992

### EXAMINATION

### RESULT

THORAX PA

No abnormality seen in both lungs.  
Normal bronchovascular markings in both hili.  
The heart is normal in size and shape.  
The mediastinum is not widened.  
Both sinus and diaphragms are good.  
No evidence of pleural effusion.

Impression

Normal heart and lungs

## RADIOLOGY DIAGNOSTIC

Name : ALFONSUS LIQUORI	Sex : Male	MR : 01.00064128	Visit : 30/07/2020
Comp.: INSPEKTINDO SINERGI PERSADA, PT		DOB : 01 August 1992	

EXAMINATION	RESULT
-------------	--------

USG ABDOMEN

LIVER:

Normal in size and contour, smooth surface, parenchyme echoes structures increased. No sign of SOL.

Intrahepatic vascularity and billiary tract are normal.

GALL BLADDER:

Normal in size, contour and surface. No sign of SOL/ sludge/ stone.

RIGHT KIDNEY :

Normal in size. The pelviocalyceal system is dilatated. No detected stone at right kidney.

LEFT KIDNEY:

Normal in size, contour and surface. No sign of obstruction/ stone/ SOL.

PANCREAS:

Normal in size, contour and surface. No sign of SOL.

LIEN:

Normal in size and contour, the echoes are homogenous. No sign of SOL.

URINARY BLADDER:

Normal in size, contour and surface. No sign of stone/ SOL.

PROSTATE AND VESICULA SEMINALIS:

Normal in size and contour which are homogenous echoes and no sign of focal lesion/ SOL.

Impression

Fatty liver.

Right hydronephrosis ec suspect ureter stone DD/ stricture.

Other abdominal organs are normal.

Advice : BNO - IVP or Urography CT scan.

## LABORATORY RESULT

Name : ALFONSUS LIQUORI	MR : 01.00064128	Visit : 30/07/2020	#Lab : IN71212734659
Comp. : INSPEKTINDO SINERGI PERSADA, PT	Sex : Male	DOB : 01 August 1992	

EXAMINATION	RESULT	NORMAL RANGE
-------------	--------	--------------

### HEMATOLOGI

ABO/Rh Typing "B" Rh(+) positive

#### Automated Blood Count

White Blood Cell (WBC)	11.2 *	3.8 - 11.0
Erythrocyte (RBC)	5.5	4.4 - 5.9
Haemoglobin	17.1	13.2 - 17.3
Hematocrit	47	40 - 52
Thrombocytes	317	150 - 440

#### MCV, MCH, MCHC

MCV	86	80 - 100
MCH	31	26 - 34
MCHC	36.2 *	32 - 36
ESR	4	0 - 10

#### Differential Count

Basophils	0	0 - 1
Eosinophil	2	2 - 4
Bands / Stab	4	3 - 5
Neutrophils	50	50 - 70
Lymphocytes	37	25 - 40
Monocytes	7	2 - 8

### BLD CHEMISTRY/LIPID PROFILE

Total Cholesterol	207 *	Normal/Desireable: <200 Borderline High: 200-239 High: >=240
HDL Cholesterol	31.3 *	Normal : >40 - <60 Low-HDL : <40 Desireable : >=60
LDL Cholesterol	111	Optimal: <100 Near/Above Optimal: 100-129 Borderline High: 130-159 High: 160-189 Very High: >=190
Triglycerides	325 *	Normal : <150 Borderline High: 150-199 High : 200-499 Very High : >=500

### BLD CHEMISTRY/KIDNEY FUNCTION

## LABORATORY RESULT

Name : ALFONSUS LIQUORI	MR : 01.00064128	Visit : 30/07/2020	#Lab : IN71212734659
Comp.: INSPEKTINDO SINERGI PERSADA, PT	Sex : Male	DOB : 01 August 1992	

EXAMINATION	RESULT	NORMAL RANGE
Ureum	16.1	10.0 - 50.0
Creatinine	1.1	0.6 - 1.3
Uric Acid	6.31	3.50 - 7.20

### BLD CHEMISTRY/LIVER FUNCTION

Total Bilirubin	0.50	0.1 - 1.0
Direct Bilirubin	0.11	0.0 - 0.2
Indirect Bilirubin	0.39	0.0 - 0.8
SGOT(AST)	28	13 - 45
SGPT (ALT)	57 *	13 - 50
Alkaline Phosphatase	83	30 - 120
Gamma GT	59 *	0 - 50
Albumin	4.6	3.5 - 5.5
Globulin	3.00	2.3 - 3.5
Total Protein	7.6	6.6 - 8.7

### BLD CHEMISTRY/DIABETES

Glucose Fasting	89	< 100
Glucose Urine	Negative	Negative
Keton Urine	Negative	Negative

#### Blood Glucose 2 PP

Blood Sugar 2 Hours PP	109	< 140
Glucose Urine	Negative	Negative
Keton Urine	Negative	Negative

### SEROLOGI / IMUNOLOGI

HBsAg (Quantitative)	0.00	0.00 - 0.03
Anti Hbs (Quantitative)	112.9	>= 5.0

### TOXICOLOGY - DRUGS SCREENING

Methadone	Negative	Negative
Phencyclidine	Negative	Negative
THC/Marijuana	Negative	Negative
Amphetamine	Negative	Negative
Benzodiazepines	Negative	Negative
Opiat	Negative	Negative
Cocain	Negative	Negative
Metamphetamine	Negative	Negative
Alcohol	Negative	Negative

### URINALYSIS

#### Complete Urine Analysis

## LABORATORY RESULT

Name : ALFONSUS LIQUORI	MR : 01.00064128	Visit : 30/07/2020	#Lab : IN71212734659
Comp. : INSPEKTINDO SINERGI PERSADA, PT	Sex : Male	DOB : 01 August 1992	

EXAMINATION	RESULT	NORMAL RANGE
-------------	--------	--------------

### Macroscopic

Color	Light Yellow	
Turbidity	Clear	Clear
Specific Gravity	1.010	1.000 - 1.030
pH	5.5	4.5 - 8.0
Leucocyte	Positive 1 (75)	Negative
Glucose	Negative	Negative
Nitrit	Negative	Negative
Bilirubin	Negative	Negative
Blood	Trace	Negative
Urobilinogen	Normal	Normal
Protein	Negative	Negative
Keton	Negative	Negative

### Microscopic

RBC	0-1	0 - 1
WBC	2-4	0 - 4
Cylinder	Negative	
Epithels Squamous	0-2	5 - 15
Crystals	Negative	
Bacteria	Negative	Negative
Others	Negative	

## STOOL / RECTAL SWAP

### Faeces Complete

#### Macroscopic

Color	Brown	
Consistency	Smooth	
Mucus	Negative	Negative
Blood	Negative	Negative
Pus	Negative	Negative
Parasitologi Faeces	Negative	Negative
Lipid	Negative	Negative

#### Microscopic

RBC	0-1	0 - 1
WBC	0-1	0 - 5
Amoeba	Negative	
Ephitels	Positive	Positive
Worm Eggs	Negative	Negative

## LABORATORY RESULT

Name : ALFONSUS LIQUORI	MR : 01.00064128	Visit : 30/07/2020	#Lab : IN71212734659
Comp.: INSPEKTINDO SINERGI PERSADA, PT	Sex : Male	DOB : 01 August 1992	

EXAMINATION	RESULT	NORMAL RANGE
Yeast	Negative	Negative
Muscle Fiber	Negative	Negative
Others	Negative	Negative
<b>Digestive</b>		
Amylum	Negative	Negative
Fat	Negative	
Fibers	Positive	Positive



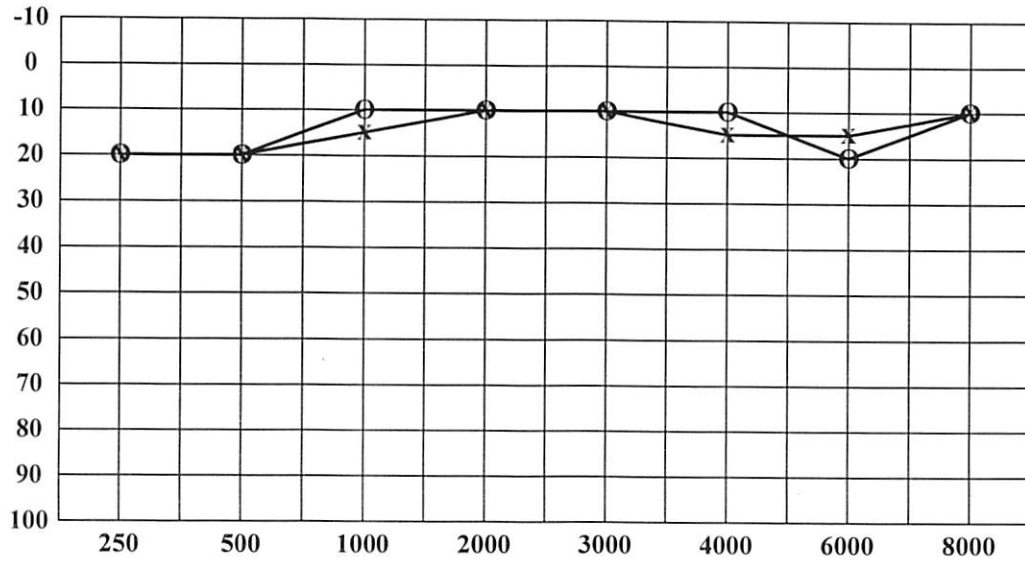
# AUDIOMETRY DIAGNOSTIC

Name : ALFONSUS LIQUORI	Sex : Male	MR : 01.00064128	Visit : 30/07/2020
Comp. : INSPEKTINDO SINERGI PERSADA, PT		DOB : 01 August 1992	

## RESULT

Left Ear	250	500	1000	2000	3000	4000	6000	8000
AC	20	20	15	10	10	15	15	10
BC	-	-	-	-	-	-	-	-

Right Ear	250	500	1000	2000	3000	4000	6000	8000
AC	20	20	10	10	10	10	20	10
BC	-	-	-	-	-	-	-	-



< : Right Ear (BC)  
 > : Left Ear (BC)  
  
 O : Right Ear (AC)  
 X : Left Ear (AC)

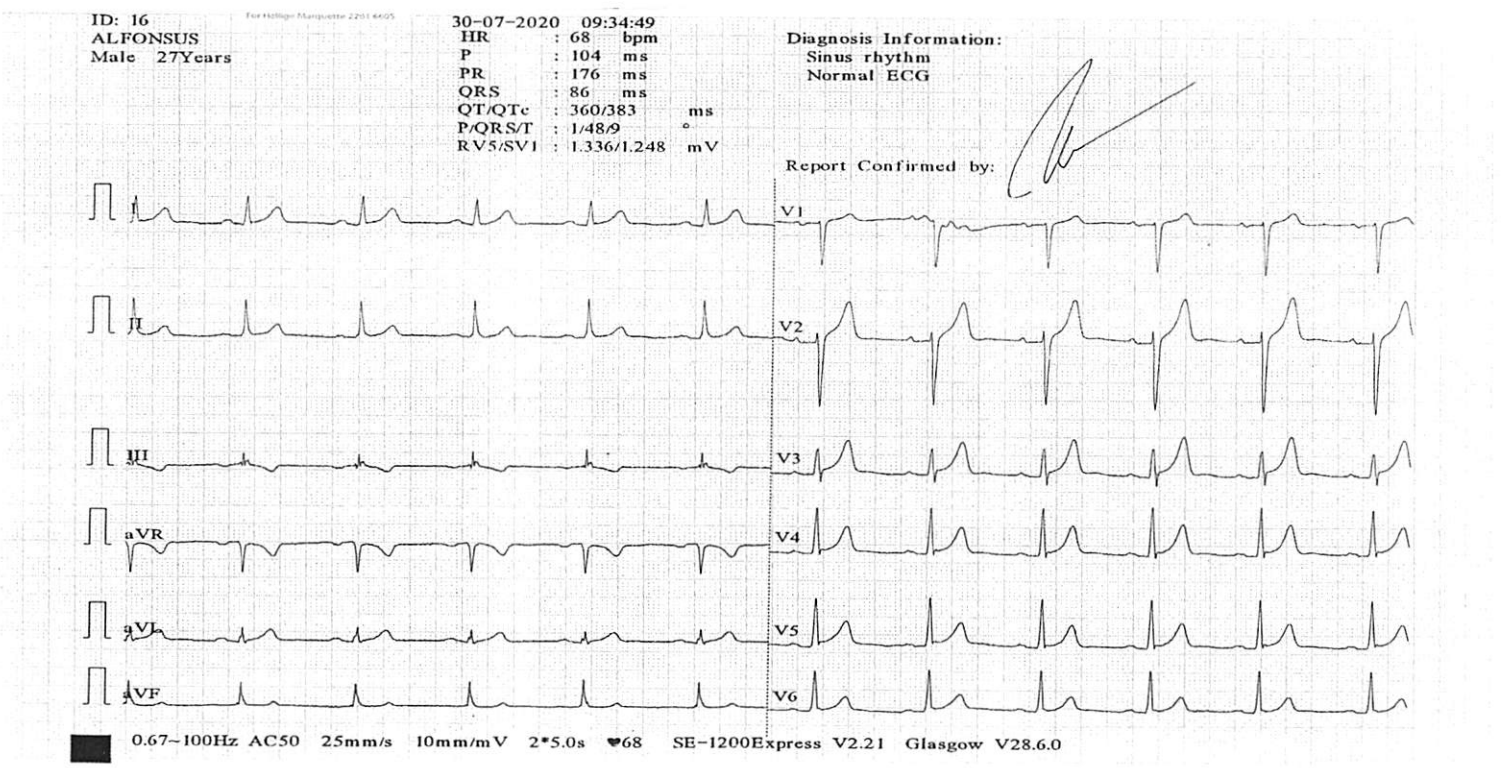
Conclusion Right Ear : Hearing threshold = 12.5 dB  
(Within normal limit)

Conclusion Left Ear : Hearing threshold = 15 dB  
(Within normal limit)

# CARDIOLOGY DIAGNOSTIC

Name : ALFONSUS LIQUORI	Sex : Male	MR : 01.00064128	Visit : 30/07/2020
Comp.: INSPEKTINDO SINERGI PERSADA, PT		DOB : 01 August 1992	

EXAMINATION	RESULT	Comments :
ELECTROCARDIOGRAPHY	Sinus Rythm axis ( N ), P wave ( N ), PR int 0.16" ST - T segment ( N ), aritmia (-)	Normal ECG
TREADMILL	Sinus Rythm axis ( N ), P wave ( N ), PR int 0.16" ST - T segment ( N ), aritmia (-)	Treadmill Exercise Test : Negative Cardiopulmonary Fitness Classification ; Good METs : 13.4





# ALFONSUS LIQUORI, MR

ID: 01.00064128, Born: 8/1/1992 (Male 27), 93 kg, 171 cm  
Test Date: 7/30/2020 9:04:53 AM

MEDIKA PLAZA

## Patient info

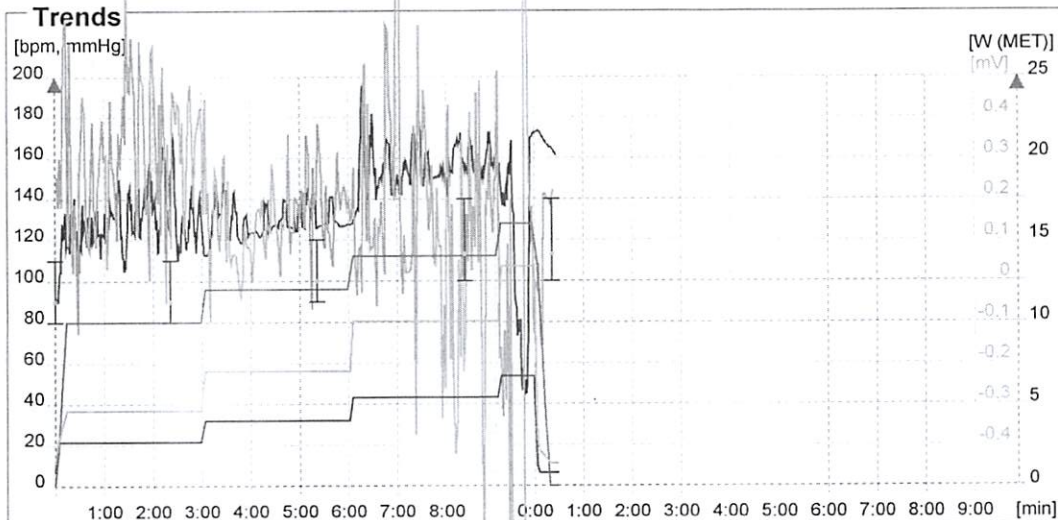
born: 8/1/1992  
age: 27  
sex: Male  
weight: 93 kg  
height: 171 cm  
smoker:  
alcohol:

## Medical history

## Medications

## Reason for admission

## Reason for Stop



## Conclusion

*[Handwritten signature]*  
 - PT. MEDIKA BINA MEDIKATAMA

## Staff

Physician: user  
Technician:

## Test info

Test date: 7/30/2020  
 Test time: 9:04 AM  
 Stress device: BTL Treadmill  
 Protocol: Bruce  
 Total duration: 09:47  
 Stress achieved: 6.7km/h, 16.0% (~13.4MET) = 95% predicted (~13.9MET) - for 45 sec  
 HR rest: 100  
 HR peak: 119 = 62% predicted (192) --- 09:4 Exercise (13.4MET)  
 Handgrip test:  
 BP rest: 110/80  
 BP peak:  
 BP recovery: 140/100  
 DP rest: 11000  
 DP peak: 21990 = 2.0x DP at rest  
 ST depression max: V1 -20.23mV 09:33 Exercise 13.4MET  
 ST elevation max: III 18.59mV 09:33 Exercise 13.4MET  
 ST/HR index: 4.4 µV/bpm (abnormal)



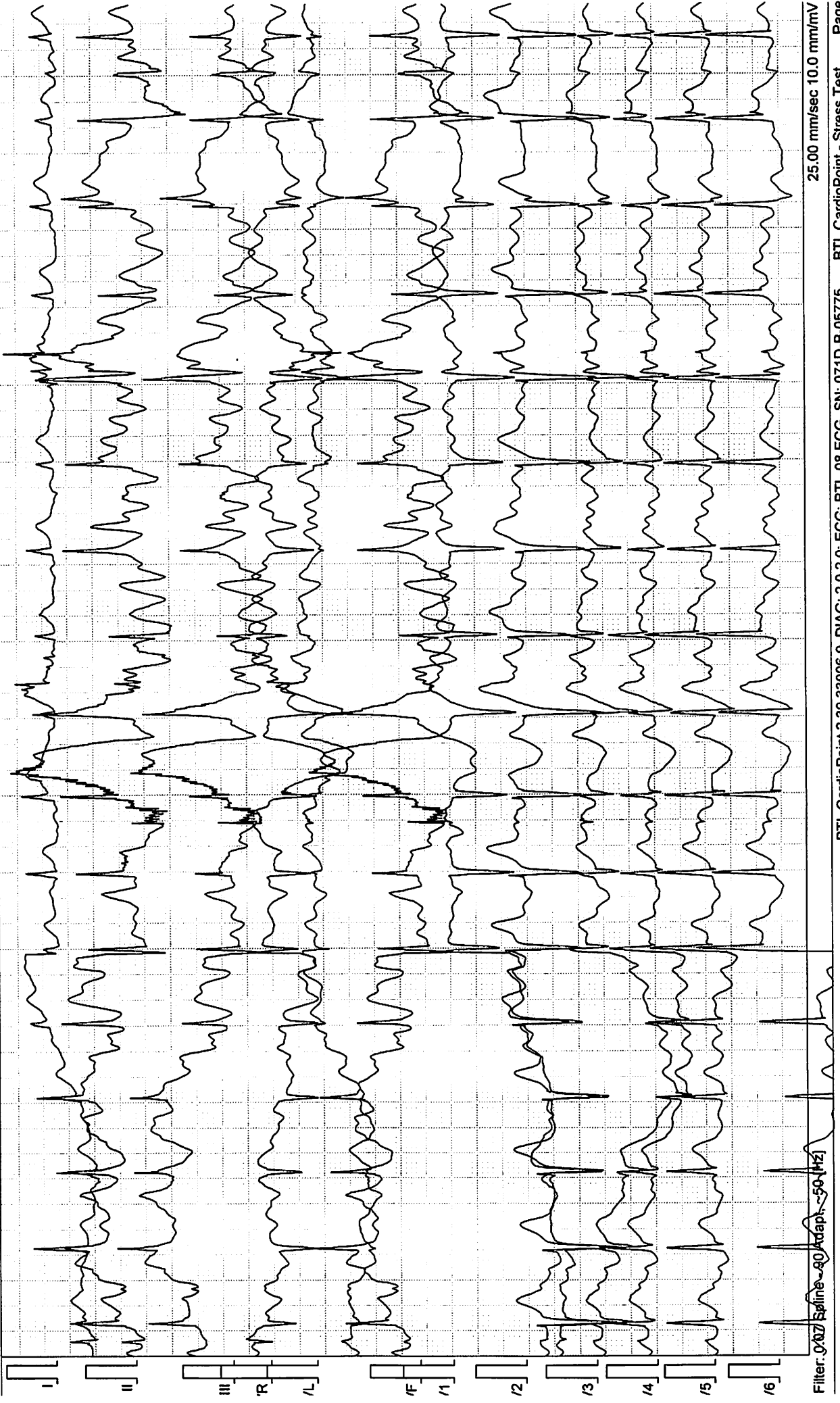
**ALFONSUS LIQUORI, MR**

ID: 01.00064128, Born: 8/1/1992 (Male 27), 93 kg, 171 cm  
Test Date: 7/30/2020 9:04:53 AM

MEDIKA PLAZA

Time: P 00:05 - Reference

Load: 1.4MET, HR: 100bpm, BP: 110/80



Filter: 0.07 Spine - 80 Adap. - 50 Hz

25.00 mm/sec 10.0 mm/mV




**ALFONSUS LIQUORI, MR**

ID: 01.00064128, Born: 8/1/1992 (Male 27), 93 kg, 171 cm  
Test Date: 7/30/2020 9:04:53 AM

MEDIKA PLAZA

Time: E 02:56 - E1  
Load: 4.6MET, HR: 128bpm, BP: 110/80



Filter: 0.07 Spline - 90 Adapt, ~50 [Hz]

edika Plaza Clinic

BTL CardioPoint 2.30.33006.0, DIAG: 2.0.2.0; ECG: BTL-08 ECG, SN: 071D-B-05775

BTL CardioPoint - Stress Test

Page

25.00 mm/sec 10.0 mm/mV



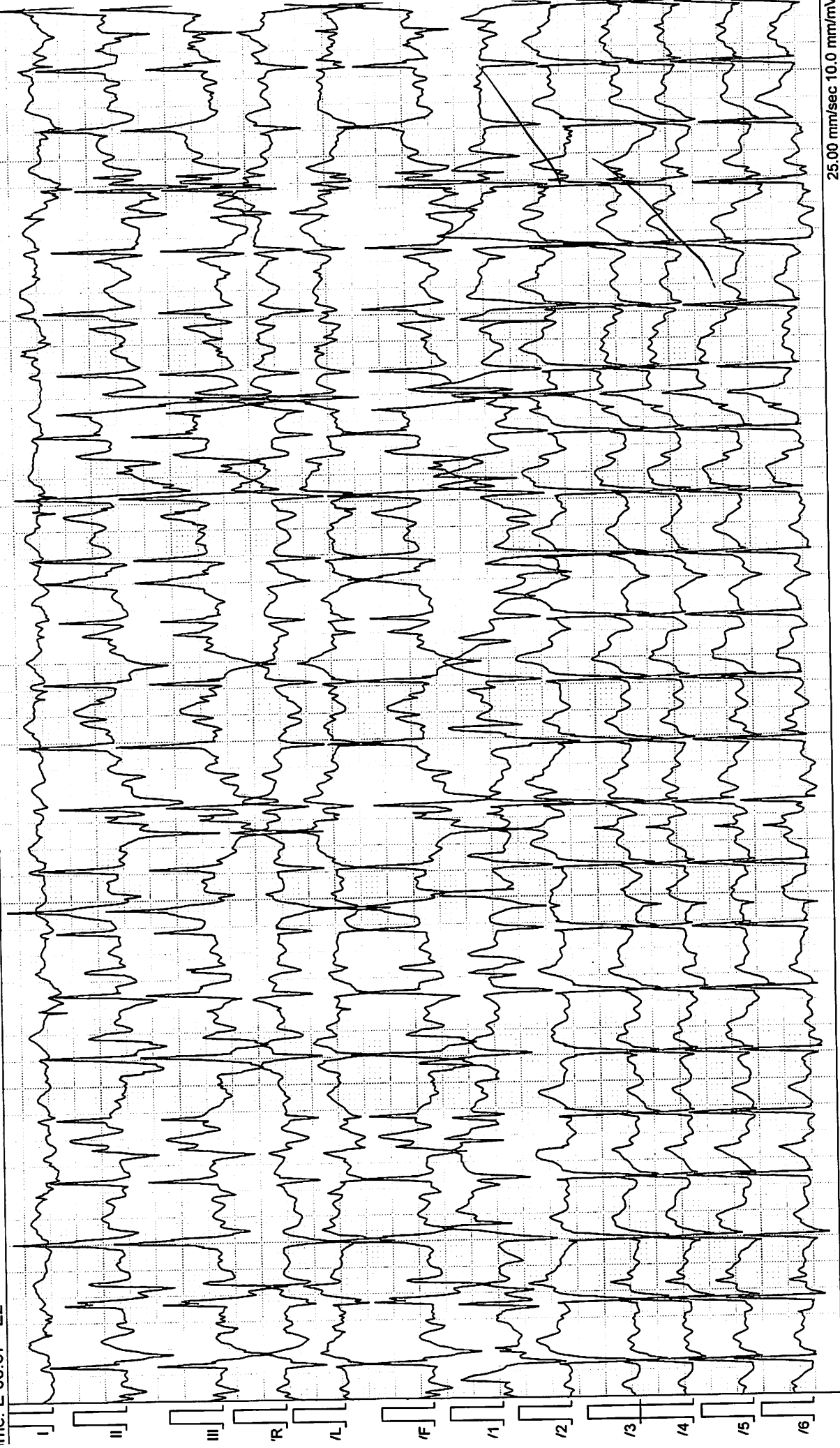
**ALFONSUS LIQUORI, MR**

ID: 01.00064128, Born: 8/1/1992 (Male 27), 93 kg, 171 cm  
Test Date: 7/30/2020 9:04:53 AM



Load: 7.0MET, HR: 128bpm, BP: 120/90

Time: E 05:57 - E2



25.00 mm/sec 10.0 mm/mV

Filter: 0.07 Spine - 90 Adapt, ~50 [Hz]

Medika Plaza Clinic




**ALFONSUS LIQUORI, MR**

ID: 01.00064128, Born: 8/1/1992 (Male 27), 93 kg, 171 cm  
Test Date: 7/30/2020 9:04:53 AM

MEDIKA PLAZA

Load: 10.1MET, HR: 162bpm, BP: 140/100

Time: E 08:58 - E3



25.00 mm/sec 10.0 mm/mV

Filter: 0.07 Spine - 90 Adapt, ~50 [Hz]

edika Plaza Clinic

BTL CardioPoint 2.30.33006.0, DIAG: 2.0.2.0; ECG: BTL-08 ECG, SN: 071D-B-05775

BTL CardioPoint - Stress Test

Page




**ALFONSUS LIQUORI, MR**

ID: 01.00064128, Born: 8/1/1992 (Male 27), 93 kg, 171 cm  
Test Date: 7/30/2020 9:04:53 AM

MEDIKA PLAZA

Load: 13.4MET, HR: 172bpm, BP: -

Time: E 09:43 - Peak



25.00 mm/sec 10.0 mm/mV

Filter: 0.07 Spine - 90 Adapt, ~50 [Hz]

Medika Plaza Clinic

BTL CardioPoint 2.30.33006.0, DIAG: 2.0.2.0; ECG: BTL-08 ECG, SN: 071D-B-05775

Page

BTL CardioPoint - Stress Test






**ALFONSUS LIQUORI, MR**

ID: 01.00064128, Born: 8/1/1992 (Male 27), 93 kg, 171 cm  
Test Date: 7/30/2020 9:04:53 AM

MEDIKA PLAZA

Time: R 00:10 - Recovery Load: 1.7MET, HR: 167bpm, BP: 140/100



Filter: 0.07 Spline - 90 Adapt, -50 [Hz]

edika Plaza Clinic

BTL CardioPoint 2.30.33006.0, DIAG: 2.0.2.0; ECG: BTL-08 ECG, SN: 071D-B-05775

25.00 mm/sec 10.0 mm/mV

Page

BTL CardioPoint - Stress Test

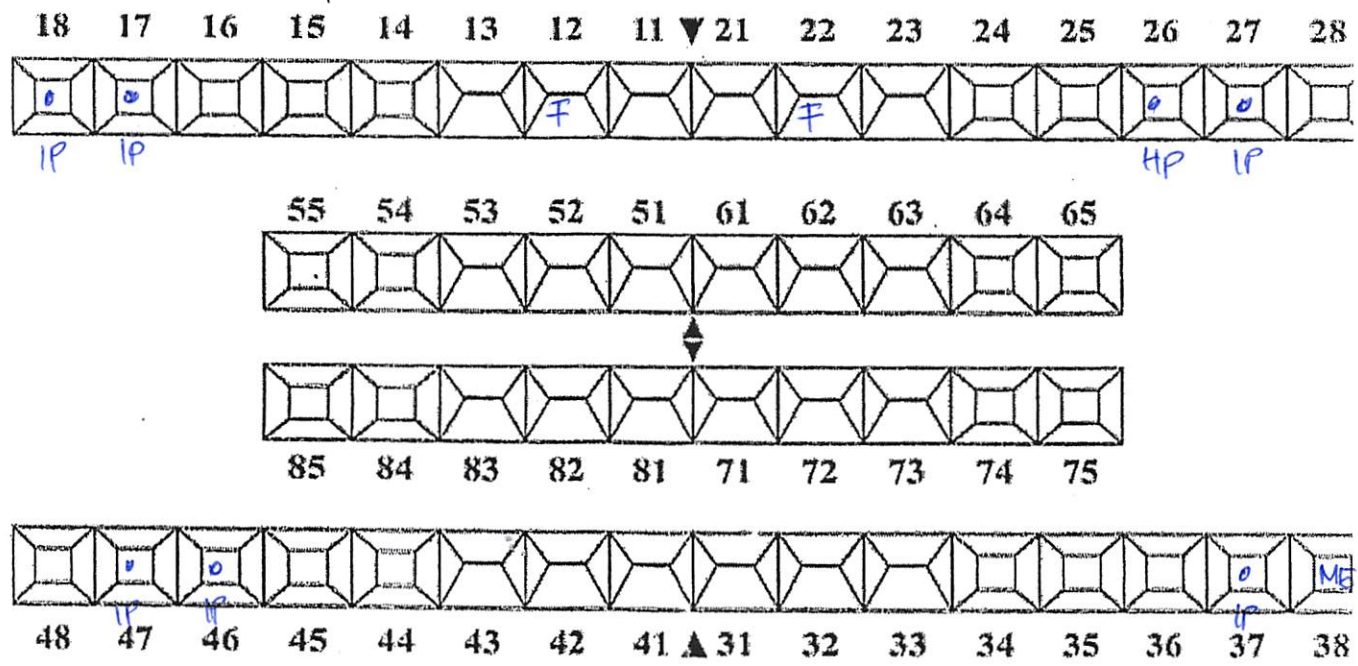
**ALFONSUS LIQUORI, MR**ID: 01.00064128, Born: 8/1/1992 (Male 27), 93 kg, 171 cm  
Test Date: 7/30/2020 9:04:53 AM

MEDIKA PLAZA

Stage	Time	Load			HR bpm	BP mmHg	SpO2 %	ST Level [ mV ], J+: 100ms User edited J position											
		km/h	%	MET				I	II	III	aVR	aVL	aVF	V1	V2	V3	V4	V5	V6
Reference	E 00:03	0.8	0.0	1.4	<b>100</b>	110/80	-	0.13	0.20	0.00	-0.11	-0.02	0.16	0.09	0.34	0.16	0.16	0.19	0.19
E 1 stage	E 03:01	2.7	10.0	4.6	<b>127</b>	110/80	-	0.08	-1.75	-1.72	0.64	0.74	-1.73	0.59	0.54	0.64	0.55	0.37	0.30
E 2 stage	E 06:02	4.0	12.0	7.0	<b>127</b>	120/90	-	0.16	0.02	-0.47	0.01	0.17	0.02	0.35	0.34	0.26	0.17	0.20	0.15
E 3 stage	E 09:03	5.4	14.0	10.1	<b>155</b>	140/100	-	0.33	-0.97	-1.74	0.29	1.01	-1.19	0.48	0.89	0.66	0.66	0.52	0.35
E 4 peak	E 09:48	6.7	16.0	13.4	<b>119</b>	-	-	0.02	18.59	18.59	-9.66	-9.43	18.54	-20.23	-20.22	-20.19	-20.23	-20.15	-20.1
Recovery	R 00:20	0.8	16.0	2.5	<b>167</b>	140/100	-	0.06	0.12	0.03	-0.12	0.05	0.07	0.09	0.34	0.20	0.16	0.19	0.17

16

DENTAL EXAMINATION			
Name: <u>Alfonsus Liqvari</u>	Sex: M / F	MR :	Visit <u>30/20</u>
Comp.: <u>Inspektindo Sinergi</u>		DOB : .....	<u>7</u>
ODONTOGRAM			



Calculus +2

DIAGNOSA

- Orl sedang
- Gingivitis
- Hiperemia Alpa 28
- Irritasi Alpa 18 17 27 37 46 47
- Impaksi 38

TREATMENT PLANNING

- Pro Scaling
- Pro Filling 26 18 17 27 37 46 47
- Pro odontektomi 38

Verified by: drg. Ilona Amalia / drg. Fajar Sulawati / drg. Siti Darjah / drg. Herlina

Ilona Amalia 30/7/20

