

## Certificate Of Health Assessment

Name	Age	Position	Department
ACHMAD CHOIRONI	39 yo	Inspection Supervisor	TESTING

**COMPANY :**

**INSPEKTINDO SINERGI PERSADA, PT**

### CONCLUSION



FIT TO WORK

FIT WITH MEDICAL NOTE

✓

TEMPORARY UNFIT

UNFIT

Issued Date	Doctors Name	Prepared By
22 September 2022	<b>Puteri Melati, MD</b> <small>PKTK : KEP.264 BINWASK3-PNK3/KK VI/2019 SIP : 23.B.15a/31.74.04.1004/-1.779.3 e 2019</small>	
Expired Date		Verified By
22 September 2023	<b>dr. Muhammad Ilyas, Sp.Ok</b> <small>SIP : 29.B.15b/31.74.04.1004.02.009.K.1/3/-1.779.3 e 2019</small>	 PT. KARTIKA BINA MEDIKATAMA

No. Formulir : FM-DR-008-05  
 No. Revisi : 00  
 Tanggal Terbit : 2 Mei 2011

Certificate Number : MP-BOP/1-20220922/140715  
 MCU Validity Check  
<https://mcu-validasi.medikaplaza.com>

## TO WHOM IT MAY CONCERN

### *Kepada yang berkepentingan*

This is certify that today Thursday, 22 September 2022 Medika Plaza Clinic has performed urine drug screening and/or breath alcohol test to :

*Dengan ini menyatakan bahwa, pada hari ini Kamis, 22 September 2022 Medika Plaza Clinic telah melakukan urine drug screening dan/atau breath alcohol test kepada :*

### **ACHMAD CHOIRONI**

With the results are as follows :

*Dengan hasil sebagai berikut :*

<u>Drugs Test</u>	<u>Result</u>		
<i>Uji Obat</i>	<i>Hasil</i>		
<b>URINE DRUGS SCREENING</b>			
- Amphetamine	<input type="checkbox"/> Non-Negative	<input checked="" type="checkbox"/> Negative	<input type="checkbox"/> N/A
- Met-Amphetamine	<input type="checkbox"/> Non-Negative	<input checked="" type="checkbox"/> Negative	<input type="checkbox"/> N/A
- Cocain	<input type="checkbox"/> Non-Negative	<input checked="" type="checkbox"/> Negative	<input type="checkbox"/> N/A
- THC/Canabis/Marijuana	<input type="checkbox"/> Non-Negative	<input checked="" type="checkbox"/> Negative	<input type="checkbox"/> N/A
- Morphine/Opiates	<input type="checkbox"/> Non-Negative	<input checked="" type="checkbox"/> Negative	<input type="checkbox"/> N/A
- P C P/Phencyclidine	<input type="checkbox"/> Non-Negative	<input checked="" type="checkbox"/> Negative	<input type="checkbox"/> N/A
- Barbiturate	<input type="checkbox"/> Non-Negative	<input type="checkbox"/> Negative	<input checked="" type="checkbox"/> N/A
- Benzodiazepin	<input type="checkbox"/> Non-Negative	<input checked="" type="checkbox"/> Negative	<input type="checkbox"/> N/A
- Methadone	<input type="checkbox"/> Non-Negative	<input checked="" type="checkbox"/> Negative	<input type="checkbox"/> N/A
- Propoxyphene	<input type="checkbox"/> Non-Negative	<input type="checkbox"/> Negative	<input checked="" type="checkbox"/> N/A
- Oxycodone	<input type="checkbox"/> Non-Negative	<input type="checkbox"/> Negative	<input checked="" type="checkbox"/> N/A
- MDMA	<input type="checkbox"/> Non-Negative	<input type="checkbox"/> Negative	<input checked="" type="checkbox"/> N/A
- 6-MAM	<input type="checkbox"/> Non-Negative	<input type="checkbox"/> Negative	<input checked="" type="checkbox"/> N/A
<b>BREATH ALCOHOL TEST</b>			
- Alcohol	<input type="checkbox"/> Non-Negative	<input checked="" type="checkbox"/> Negative	<input type="checkbox"/> N/A

Jakarta, September 22, 2022



PT. KARTIKA BINA MEDIKATAMA  
( dr. Petty Atmadja, Sp.PK )

Clinical Patologist

# **HEALTH ASSESSMENT REPORT**

*of*

**ACHMAD CHOIRONI**

**01035753**

**Thursday, 22 September 2022**

## **MP BELTWAY CLINIC**

**Beltway Office Park, Gated Building, Ground Floor**

**J. TB. Simatupang Kavali, Jakarta Selatan 12111**

**Tel: 021-52111001-56199, Fax: 021-50136091**

**[www.msdilkgp.com](http://www.msdilkgp.com)**

## MP BELTWAY CLINIC

Beltway Office Park, Annex Building, Ground Floor  
Jl. TB. Simatupang Kav.41, Jakarta Selatan 12550  
Tlp : (62-21) 808 66 099, Fax : (62-21) 808 66 098  
www.medikaplaza.com

### PATIENT DATA

MedRec.	: 01035755	EMPLOY. STATUS	: Employee
NAME	: ACHMAD CHOIRONI	BIRTHDATE	: 02 March 1983
EMPLOYEE No.	:	SEX	: Male
JOB TITLE	: Inspection Supervisor	STATUS	: Married
COMP. NAME	: INSPEKTINDO SINERGI PERSADA, PT	NASIONALITY	: Indonesia

### SUMMARY

#### MEDICAL FINDING :

1. Leukocytosis
2. Increase ESR count
3. Hypertriglyceridemia
4. Non reactive Anti Hbs
5. Obesity
6. Decayed, gangrene pulp, fractur, radix, and calculus teeth
7. USG Abdomen : Fatty liver, Left kidney agenesis
8. Severe conductive hearing loss of right ear and Decreasing of hearing acuity on high frequency of left ear

#### PERCEPTIONS OF EXPOSURE BY WORKERS :

- Administration work

Your fitness status is fit with medical note:

1. Increase ESR count
2. Hypertriglyceridemia
3. USG Abdomen : Fatty liver, Left kidney agenesis
4. Severe conductive hearing loss of right ear

#### SUGGESTION :

1. Repeat Leucocyt examination after 1 month and consultation with an Internist if still increase
2. Consultation with an Internist for further evaluation of Increase ESR count
3. Consultation with an Internist for further evaluation of Hypertrygliceridemia
4. Need to get Hepatitis B vaccination (booster)
5. Reduce body weight gradually 0.5 Kgs/week, by doing regular exercise (aerobic/jogging), 3-4x/week, 30-45 minutes and reduce high calorie diet until maximal body weight is 60.84Kgs (present body weight is 74.1Kgs). Consultation with a Nutritionist for evaluation of obesity
6. Consultation with a Dentist for dental care, minimal once a year or better once in six month
7. Low fat diet and exercise regularly minimum 3x/week. Repeat abdominal USG 6 months later and Consultation with an Internist for further evaluation of USG Abdomen : Fatty liver, Left kidney agenesis
8. Avoid noisy environment or use earplug properly while working at noisy work environment to prevent further hearing impairment. Consultation with an ENT Specialist for further evaluation Severe conductive hearing loss of right ear

#### Responsible Doctor



Puteri Melati, MD

#### Notes:

If you need the further information or consultation, please contact us via :

- Email : - enjelita@medikaplaza.com  
- Rezkha.Amalia@medikaplaza.com  
- Puteri.Melati@medikaplaza.com

Telepon Klinik : (62-21) 8086 6099

PRIVATE

Printed by : reysti

## CLINICAL EVALUATION

Name : ACHMAD CHOIRONI	Sex : Male	MR : 01035755	Visit : 22/09/2022
Comp. : INSPEKTINDO SINERGI PERSADA, PT		DOB : 02 March 1983	
EXAMINATION	RESULT	NOTES	

### ANAMNESIS

#### PRESENT COMPLAINT AND HISTORY OF PRESENT

#### ILLNESS

Present complaint

No complaint

#### MEDICAL HISTORY

Allergy No

Imunisasi Yes

Surgery Yes

Hospitalization No

Disease No

Nose fracture

#### LIFE STYLE

Alcohol intake No

Smoking Yes

Exercise Yes

Mild smoker

Footsal, and cycling

#### FAMILY MEDICAL HISTORY

Diabetes Melitus No

Hypertension No

Heart disease No

Lung TB No

Kidney disease No

Astma No

Mental disease No

Epilepsy No

Cancer No

Color blind No

Stroke No

Liver disease No

Bone & joint No

Others disease No

#### WORK EXPOSURE

Noise No

Heat Stress No

Cold Stress No

Vibration No

Involving height No

Radiation No

Dust No

## CLINICAL EVALUATION

Name : ACHMAD CHOIRONI	Sex : Male	MR : 01035755	Visit : 22/09/2022
Comp. : INSPEKTINDO SINERGI PERSADA, PT		DOB : 02 March 1983	

EXAMINATION	RESULT	NOTES
Toxic chemical	No	
Irritating fluid	No	
Smoke	No	
Bacterium/Virus/Parasite	No	
Blood	No	
Animal	No	
Operating heavy mobile equipment	No	
Manual Handling	No	
Sitting continuously over 4 hours	No	
Stand continuously over 4 hours	No	
Using monitor screen more than 4 hours per day	No	
Exposure	No	
Unergonomic body positions	No	
Shift work	No	
Work is not accordance with skills and knowledge	No	
Workload does not accordance with time	No	
Work conflict	No	
Inappropriate task	No	
Career barriers	No	
Family conflict	No	
Working around rotating machinery	No	
Administration work	Yes	
Handling food product	No	
Others	No	
<b>PHYSICAL EXAMINATION</b>		
General Appearance	Good	
Body shape	Picnicus	
<b>VITAL SIGN</b>		
Body Weight	74.1 Kg	
Body Height	156 Cm	
BMI	30.44 Kg/m <sup>2</sup>	
Normal Weight	45.02 - 60.84 Kg	
BMI Conclusion	Obesity	
Blood Pressure	120/80 mmHg	
Pulse	76 x/minute	
Body Temperature	36.4 °C	
RR	18	



## CLINICAL EVALUATION

Name : ACHMAD CHOIRONI	Sex : Male	MR : 01035755	Visit : 22/09/2022
Comp. : INSPEKTINDO SINERGI PERSADA, PT		DOB : 02 March 1983	

EXAMINATION	RESULT	NOTES
Neck Circumference	43 Cm	
Arm Circumference	34 Cm	
Chest size	90 Cm	
Abdominal Circumference	92 Cm	
<b>SKIN</b>		
Skin	Normal	
<b>EYE</b>		
Left	Normal	
Right	Normal	
<b>ENT</b>		
Auricle	Normal	
Ear canal	Normal	
Drums	Normal	
Septum/Conchae	Normal	
Sinuses	Normal	
Pharynx	Normal	
Tonsil	Normal	
<b>MOUTH</b>		
Gum	Normal	
Dental	Abnormal	Decayed, gangrene pulp, fractur, radix, and calculus teeth
<b>NECK</b>		
General	Normal	
Thyroid Gland	Normal	
<b>CHEST</b>		
Form	Normal	
Lung	Normal	
Heart	Normal	
Breast	Normal	
<b>ABDOMEN</b>		
Form	Flat	
Palpation	Supple	
Liver	Not Palpable	
Spleen	Not Palpable	
Kidney	No Ballotment	
Nyeri Ketok (CVA)	No	
Hernia inguinal	No	

**CLINICAL EVALUATION**

<b>Name</b> : ACHMAD CHOIRONI	<b>Sex</b> : Male	<b>MR</b> : 01035755	<b>Visit</b> : 22/09/2022
<b>Comp.</b> : INSPEKTINDO SINERGI PERSADA, PT		<b>DOB</b> : 02 March 1983	
EXAMINATION	RESULT	NOTES	

**EXTRIMITIES**

Bones, joint	Normal
Muscles, tonus	Normal
Fingernails	Normal
Hand	Normal
Foot	Normal

**RECTAL EXAMINATION**

Hemorrhoid	Negative
Rectum	Normal

**SENSORIK EXAMINATION**

Tes Raba	Normal
----------	--------

**MOTORIK EXAMINATION**

Tes Grip	Normal
----------	--------

**REFLEX EXAMINATION**

Physiologic reflex	Normal
Patologic reflex	Normal

**OTHERS EXAMINATION**

Coordination	Normal
--------------	--------

**LYMPHE SYSTEM**

Submandibula	Normal
Neck Gland	Normal
Armpit gland	Normal
Inguinal	Normal

**MUSKULOSKLETAL EXAMINATION**

Lhermitte Test	Negative
Spurling Test	Negative
Neers Test	Negative
Yergason Test	Negative
Phalen Test	Negative
Tinel Test	Negative
Finkelstein Test	Negative
Straight Leg Raise Test	Negative



## OPHTHALMOLOGY DIAGNOSTIC

Name : ACHMAD CHOIRONI	Sex : Male	MR : 01035755	Visit : 22/09/2022
Comp. : INSPEKTINDO SINERGI PERSADA, PT		DOB : 02 March 1983	

EXAMINATION		Right	Left
Reading		-	
Previous Glasses		-	-
Without Glasses	Distant	20/20	20/20
	Near	J1	J1
Correction	Distant	-	-
	Near	-	-
Depth Perception		-	
Tonometry		14.0 mmHg	15.0 mmHg
Funduscopy		NORMAL	NORMAL
Visual Fields		Normal	
Colour Blind Test		Normal	

Impression :

**RADIOLOGY DIAGNOSTIC****Name** : ACHMAD CHOIRONI**Sex** : Male**MR** : 01035755**Visit** : 22/09/2022**Comp.** : INSPEKTINDO SINERGI PERSADA, PT**DOB** : 02 March 1983**EXAMINATION****RESULT**

THORAX PA

No abnormality seen in both lungs.  
Normal bronchovascular markings in both hili.  
The heart is normal in size and shape.  
The mediastinum is not widened.  
Both sinus and diaphragms are good.  
No evidence of pleural effusion.

Impression

Normal heart and lungs.

## RADIOLOGY DIAGNOSTIC

Name : ACHMAD CHOIRONI	Sex : Male	MR : 01035755	Visit : 22/09/2022
Comp. : INSPEKTINDO SINERGI PERSADA, PT	DOB : 02 March 1983		
EXAMINATION	RESULT		

**USG ABDOMEN**

**LIVER:**

Liver tip is blunt, there are increase attenuation echoes structure parenchyme which are homogenous. No sign of SOL.

Intrahepatic vascularity and billiary tract are normal.

**GALL BLADDER:**

Normal in size, contour and surface. No sign of SOL/ sludge/ stone.

**RIGHT KIDNEY:**

Normal in size, contour and surface. No sign of obstruction/ stone/ SOL.

Left kidney's echostructure was not detected.

**PANCREAS:**

Normal in size, contour and surface. No sign of SOL.

**LIEN:**

Normal in size and contour, the echoes are homogenous. No sign of SOL.

**URINARY BLADDER:**

Normal in size, contour and surface. No sign of stone/ SOL.

**PROSTATE AND VESICULA SEMINALIS:**

Normal in size and contour which are homogenous echoes and no sign of focal lesion/ SOL.

**Impression**

Fatty liver.

Left kidney agenesis. Note : Had been confirmed at CT scan ( 2021 ).

Other abdominal organs are normal.

## LABORATORY RESULT

Name : ACHMAD CHOIRONI	MR : 01035755	Visit : 22/09/2022	#Lab : IN790432598715
Comp. : INSPEKTINDO SINERGI PERSADA, PT	Sex : Male	DOB : 02 March 1983	
EXAMINATION	RESULT	NORMAL RANGE	

### HEMATOLOGI

ABO/Rh Typing "A" Rh(+) positive

#### Automated Blood Count

White Blood Cell (WBC)	12.5 *	3.8 - 11.0
Erythrocyte (RBC)	5.3	4.4 - 5.9
Haemoglobin	15.2	13.2 - 17.3
Hematocrit	44	40 - 52
Thrombocytes	361	150 - 440

#### MCV, MCH, MCHC

MCV	84	80 - 100
MCH	29	26 - 34
MCHC	34.4	32 - 36
ESR	63 *	0 - 10

#### Differential Count

Basophils	0	0 - 1
Eosinophil	4	2 - 4
Bands / Stab	5	3 - 5
Neutrophils	57	50 - 70
Lymphocytes	27	25 - 40
Monocytes	7	2 - 8

### BLD CHEMISTRY/LIPID PROFILE

Total Cholesterol	129	Normal/Desireable: <200 Borderline High: 200-239 High: >=240
HDL Cholesterol	38.0 *	Normal : >40 - <60 Low HDL : <40 Desireable : >=60
LDL Cholesterol	50	Optimal: <100 Near/Above Optimal: 100-129 Borderline High: 130-159 High: 160-189 Very High: >=190
Triglycerides	205 *	Normal : <150 Borderline High: 150-199 High : 200-499 Very High : >=500

### BLD CHEMISTRY/KIDNEY FUNCTION

**LABORATORY RESULT**

Name : ACHMAD CHOIRONI	MR : 01035755	Visit : 22/09/2022	#Lab : IN790432598715
Comp. : INSPEKTINDO SINERGI PERSADA, PT	Sex : Male	DOB : 02 March 1983	

EXAMINATION	RESULT	NORMAL RANGE
Ureum	19.5	10.0 - 50.0
Creatinine	1.06	0.60 - 1.30
Uric Acid	5.57	3.50 - 7.20

**BLD CHEMISTRY/LIVER FUNCTION**

Total Bilirubin	0.90	0.1 - 1.0
Direct Bilirubin	0.17	0.0 - 0.2
Indirect Bilirubin	0.73	0.0 - 0.8
SGOT(AST)	21	13 - 45
SGPT (ALT)	31	13 - 50
Alkaline Phosphatase	44	30 - 120
Gamma GT	32	0 - 50
Albumin	4.1	3.5 - 5.5
Globulin	3.30	2.3 - 3.5
Total Protein	7.4	6.6 - 8.7

**BLD CHEMISTRY/DIABETES**

Glucose Fasting	83	< 100
Glucose Urine	Negative	Negative
Keton Urine	Negative	Negative

**Blood Glucose 2 PP**

Blood Sugar 2 Hours PP	88	< 140
Glucose Urine	Negative	Negative
Keton Urine	Negative	Negative

**SEROLOGI / IMUNOLOGI**

HBsAg (Quantitative)	0.00	0.00 - 0.03
Anti Hbs (Quantitative)	0.0 *	>= 5.0

**TOXICOLOGY - DRUGS SCREENING**

Methadone	Negative	Negative
Phencyclidine	Negative	Negative
THC/Marijuana	Negative	Negative
Amphetamine	Negative	Negative
Benzodiazepines	Negative	Negative
Opiat	Negative	Negative
Cocain	Negative	Negative
Metamphetamine	Negative	Negative
Alcohol	Negative	Negative

**URINALYSIS****Complete Urine Analysis**

## LABORATORY RESULT

Name : ACHMAD CHOIRONI	MR : 01035755	Visit : 22/09/2022	#Lab : IN790432598715
Comp. : INSPEKTINDO SINERGI PERSADA, PT	Sex : Male	DOB : 02 March 1983	
EXAMINATION	RESULT	NORMAL RANGE	

### Macroscopic

Color	Yellow	
Turbidity	Clear	Clear
Specific Gravity	1.009	1.000 - 1.030
pH	5.5	4.5 - 8.0
Leucocyte	Negative	Negative
Glucose	Negative	Negative
Nitrit	Negative	Negative
Bilirubin	Negative	Negative
Blood	Negative	Negative
Urobilinogen	Normal	Normal
Protein	Negative	Negative
Keton	Negative	Negative

### Microscopic

RBC	0-1	0 - 1
WBC	0-1	0 - 4
Cylinder	Negative	
Epithels Squamous	0-1	5 - 15
Crystals	Negative	
Bacteria	Negative	Negative
Others	Negative	

## STOOL / RECTAL SWAP

### Faeces Complete

#### Macroscopic

Color	Brown	
Consistency	Smooth	
Mucus	Negative	Negative
Blood	Negative	Negative
Pus	Negative	Negative
Parasit	Negative	Negative
Lipid	Negative	Negative

#### Microscopic

RBC	0-1	0 - 1
WBC	0-2	0 - 5
Amoeba	Negative	
Ephitels	Positive	Positive
Worm Eggs	Negative	Negative

## LABORATORY RESULT

Name : ACHMAD CHOIRONI	MR : 01035755	Visit : 22/09/2022	#Lab : IN790432598715
Comp. : INSPEKTINDO SINERGI PERSADA, PT	Sex : Male	DOB : 02 March 1983	

EXAMINATION	RESULT	NORMAL RANGE
Yeast	Negative	Negative
Muscle Fiber	Negative	Negative
Others	Negative	Negative
<b>Digestive</b>		
Amylum	Negative	Negative
Fat	Negative	
Fibers	Positive	Positive



## SPIROMETRY DIAGNOSTIC

Name : ACHMAD CHOIRONI	Sex : Male	MR : 01035755	Visit : 22/09/2022
Comp. : INSPEKTINDO SINERGI PERSADA, PT		DOB : 02 March 1983	

EXAMINATION	RESULT
-------------	--------

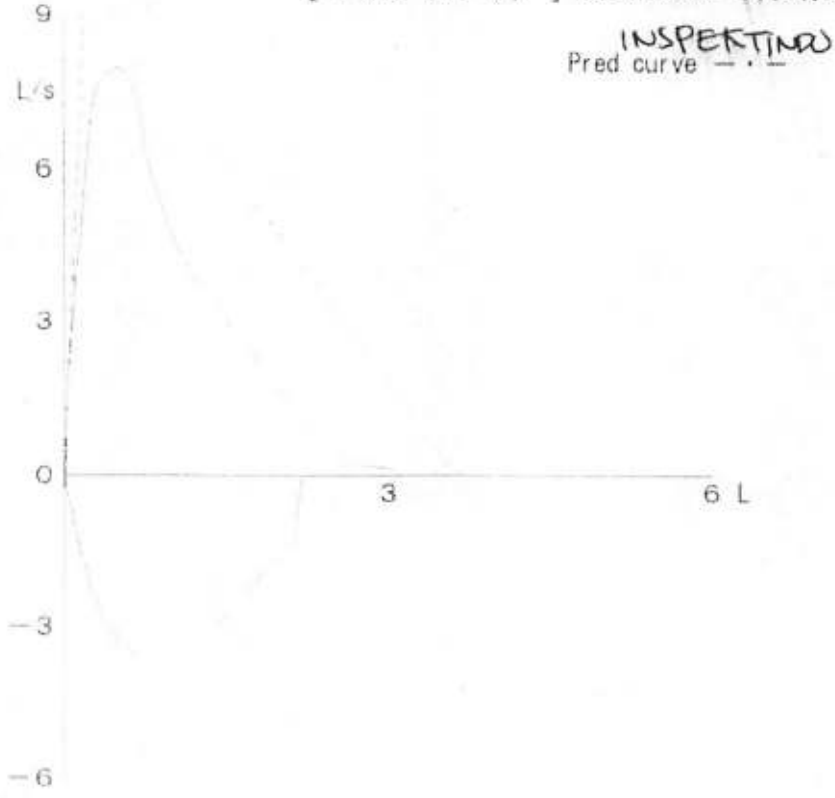
FVC Result	: 3.05 L---> 84.0 %
FEV1 Result	: 2.48 L---> 80.5 %
FEV1/FVC Result	: 81.31 %---> 105.3 %
PEF Result	: 7.93 L/S---> 78.7 %
Indonesian Standart Result	:
Index	:
Spirometry Result	: Normal

Impression : Normal Spirometric Functions

### [ COPD CLASSIFICATION ]

FEV1/FVC                    81.31 %  
 %FEV1 0                    80.50 %  
 Stage                        Normal  
 Recommended treatment by GOLD

[ FVC (F/V) ] ACHMAD CHOIRONI



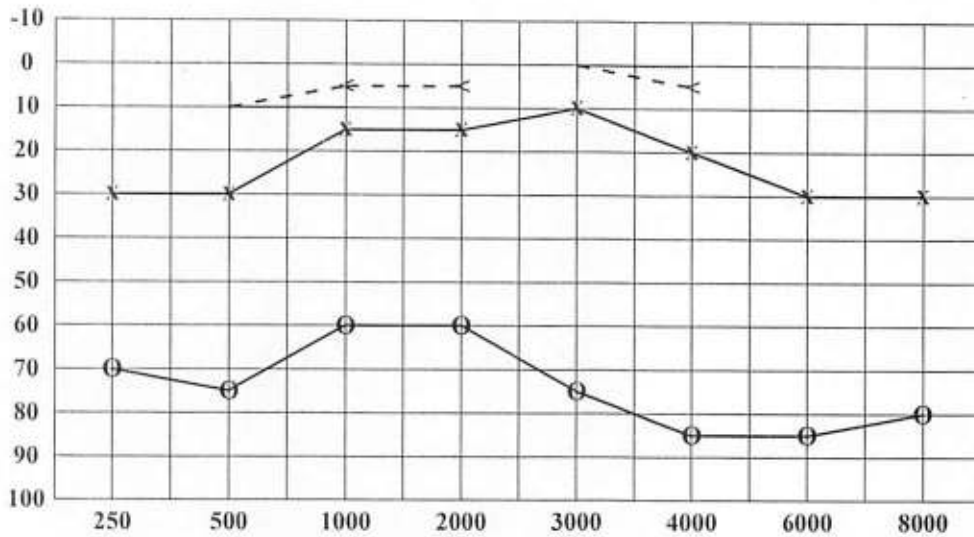
# AUDIOMETRY DIAGNOSTIC

Name : ACHMAD CHOIRONI	Sex : Male	MR : 01035755	Visit : 22/09/2022
Comp. : INSPEKTINDO SINERGI PERSADA, PT		DOB : 02 March 1983	

## RESULT

Left Ear	250	500	1000	2000	3000	4000	6000	8000
AC	30	30	15	15	10	20	30	30
BC	-	-	-	-	-	-	-	-

Right Ear	250	500	1000	2000	3000	4000	6000	8000
AC	70	75	60	60	75	85	85	80
BC	-	10	5	5	-	5	-	-



< : Right Ear (BC)  
 > : Left Ear (BC)  
 O : Right Ear (AC)  
 X : Left Ear (AC)

**Conclusion Right Ear** : Severe conductive hearing loss = 70 dB  
 With decreasing on frequency  
 250Hz, 4000Hz, 6000Hz, 8000Hz

**Conclusion Left Ear** : Hearing threshold = 20 dB  
 (Within normal limit)  
 With decreasing on frequency 250Hz, 6000Hz,  
 8000Hz

PATIENT NAME : Achmad. Choirani  
No. RM : 01095795  
Clinik/MCU/HCU : Co. E.W.T

To. Dokter :  
(Counsel)

Kindly please counsel for patient who has take cares of

Diagnose :  
Clinik Summary :

Counsel Request :

**COUNSEL ADVISE**

ear : tympanic membrane Intact, no Cerumen  
nose : clear eustachian, no secretions  
throat : T2 T2 no hyperemia  
• Audiology : Severe. Heavy disorder Right ear 70db  
Diagnosis : Heavy conductive with mild limit sinistra  
Chronic otitis media, severe heavy loss dextra.  
Recommendation :

- Stop smoking.
- Use ear protection when working in my farm.

Date : 22/9/2022  
Time :  
EP :



PT. KARTIKA BINA MEDIKATAMA

Signature

**dr Meristiana Christiane, Sp.THT-KL**

18/B.158/31.74.04.1004.02.009.K.1.b/31-772.3/e/2022

Complete Name

# CARDIOLOGY DIAGNOSTIC

Name : ACHMAD CHOIRONI	Sex : Male	MR : 01035755	Visit : 22/09/2022
Comp. : INSPEKTINDO SINERGI PERSADA, PT		DOB : 02 March 1983	

EXAMINATION	RESULT	Comments :
-------------	--------	------------

ELECTROCARDIOGRAPHY	Sinus Rythm axis ( N ), P wave ( N ), PR int 0.16" ST - T segment ( N ), aritmia (-)	Normal ECG
---------------------	---	------------

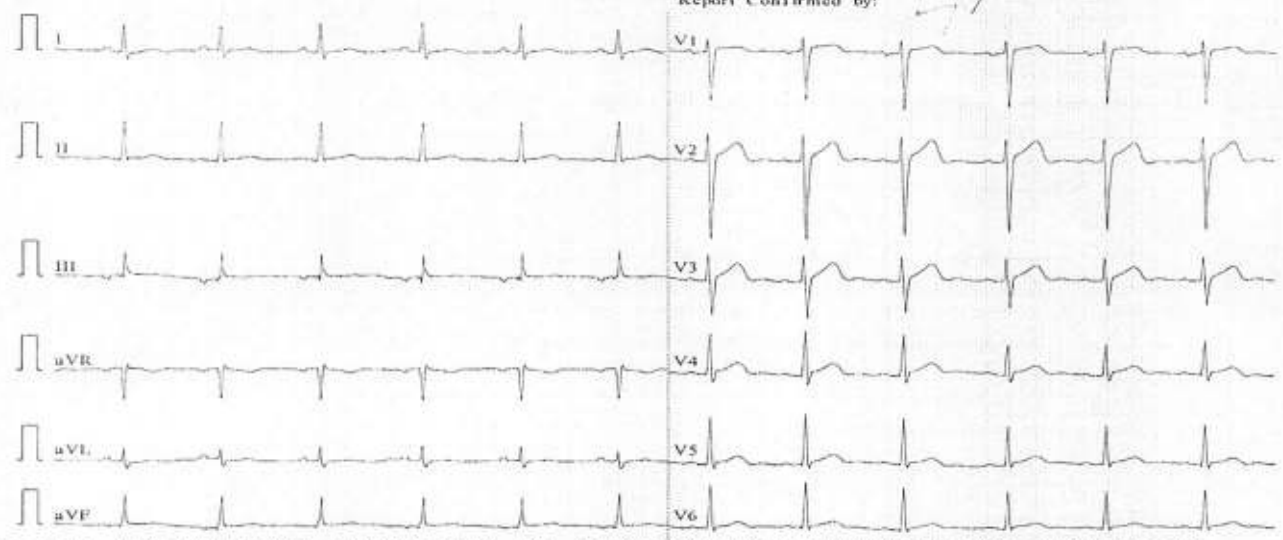
TREADMILL	Sinus Rythm axis ( N ), P wave ( N ), PR int 0.16" ST - T segment ( N ), aritmia (-)	Treadmill Exercise Test : Negative Cardiopulmonary Fitness Classification : Good METs : 13.6
-----------	---	---

ID: 43  
ACHMAD CHOIRONI  
Male 39Months

22-09-2022 09:56:41  
HR : 74 bpm  
P : 100 ms  
PR : 160 ms  
QRS : 92 ms  
QT/QTc : 388/431 ms  
P-QRS/T : -9/62/48  
RV5/SV1 : 1.208/1.473 mV

Diagnosis Information:  
— Interpretation based on pediatric criteria —  
Sinus bradycardia with borderline 1st degree A-V block  
Possible right ventricular hypertrophy  
Borderline ECG

Report Confirmed by:



0.67-100Hz AC50 25mm/s 10mm/mV 2\*5.0s ♥74 SE-1200Express V2.21 Glasgow V28.6.0 Klinik Medika Plaza BOP







ACHMAD CHOIRONI, MR

III, DUKUN-BOI, BOKI, PERUMPERA, JAWA BARU, 20114, No. 105, 106, 107

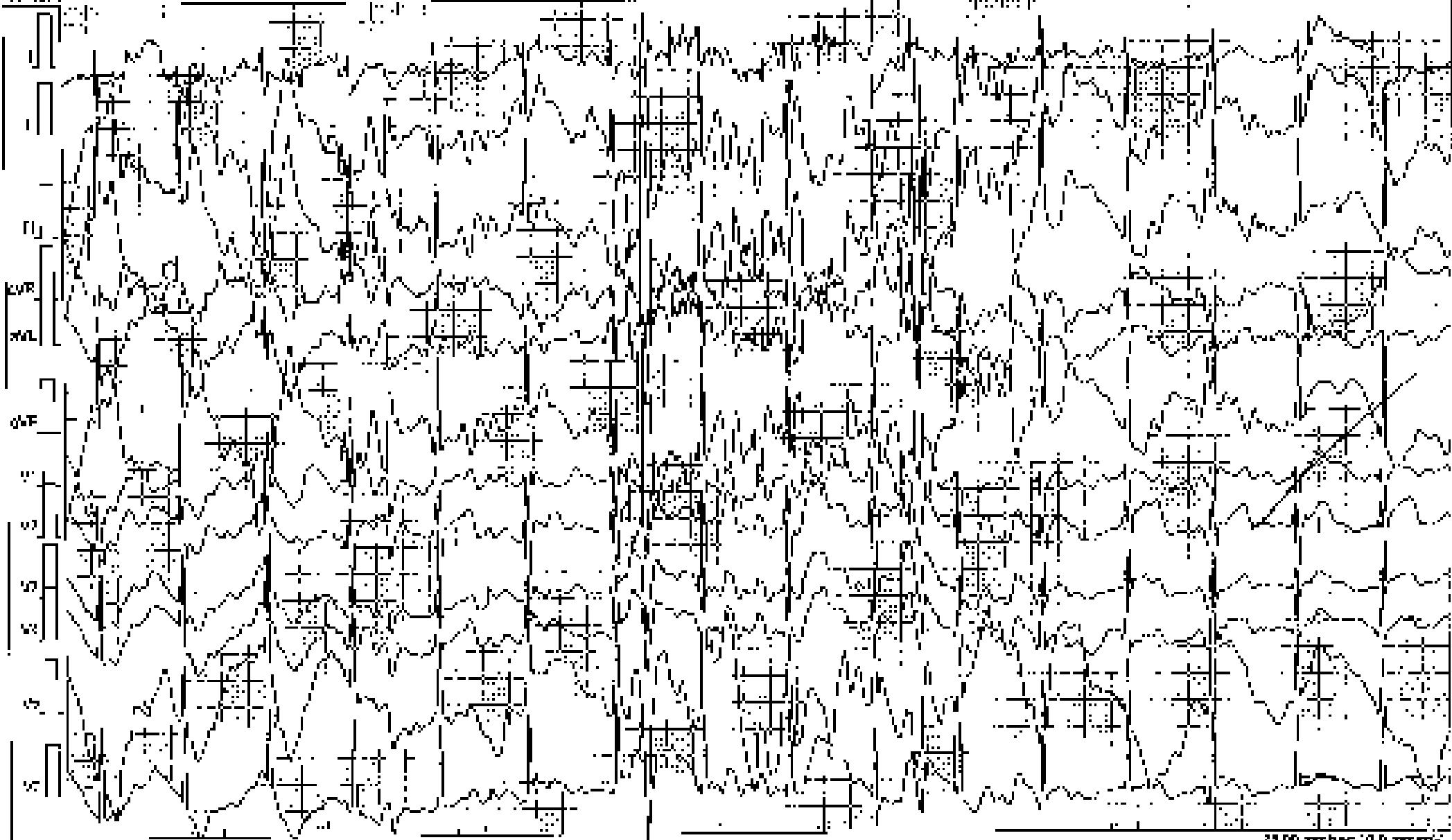
Telephone: 091222077, 091222078

Fax: 091222077

KUN KUNDEMA PLAZA

Time: P 0015 - Reference:

Lead: 1.4V, 0.150, 120µm, BP 12080



Time: 12:00, SpO2: 90, Arterial: 50, HR: 70

20 00 mm/Amc 10 0 0 mm/Amc



ACHMAD CHOIRONI, MR

IP: 192.168.1.100 Date: 03/21/2024 (H): 09: 14: 14, 156 cm

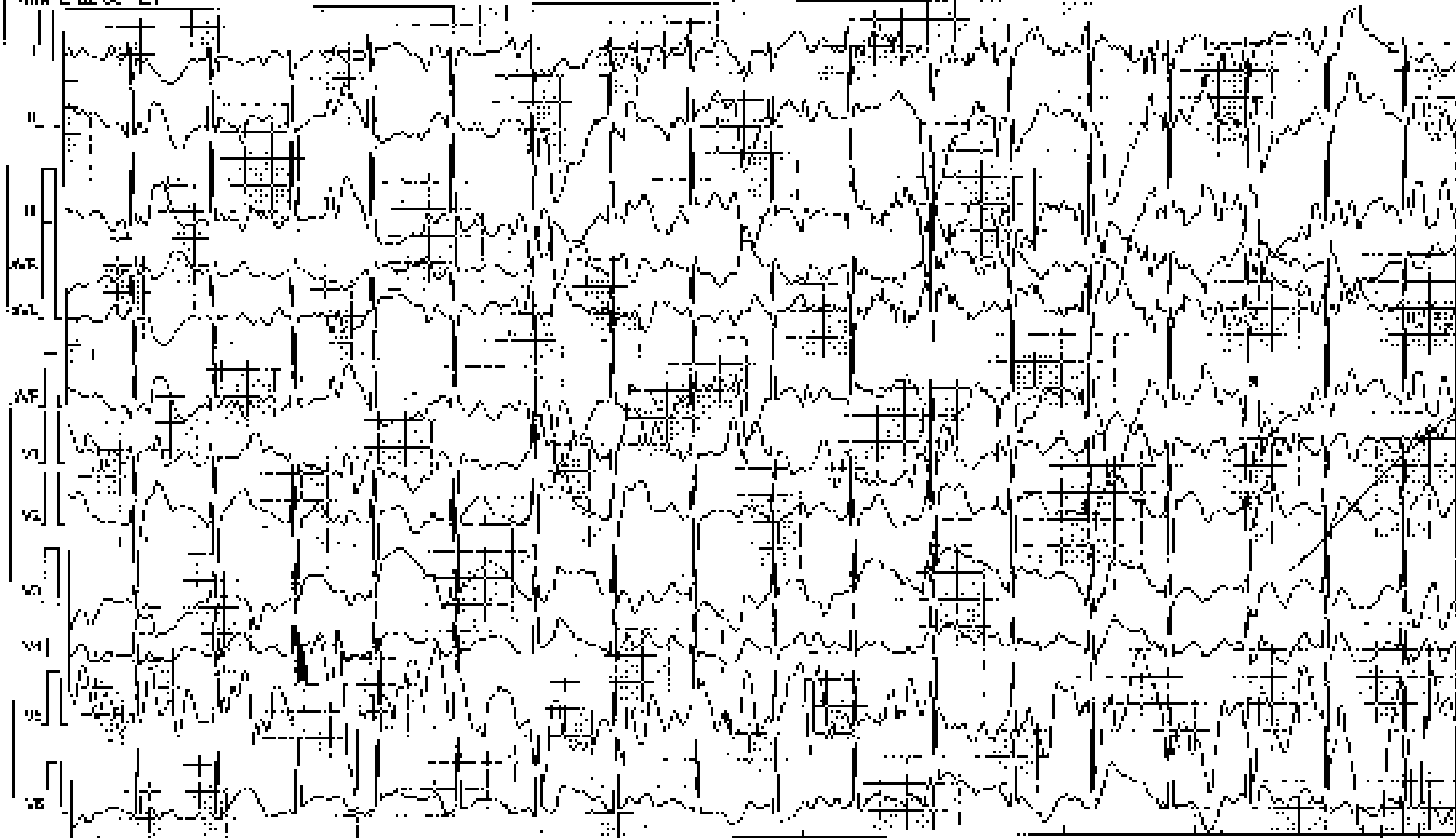
Inst: Loka: 22-2200221-0000

Inst. type: BHS5707

KUNING MEDICAL

Lead: 4, 5, 6, 7 HR: 80 bpm, BP: 120/80

Time: E 02:00 - L1



File: 0107 Sp1 na-2024 na-00 (HR)

25.00 mm/sec (10 mm/mV)





ACHMAD CHOIRONI, MR

ID: 21003755, Birth: 1981/04/15, 35.56 kg, 170 cm

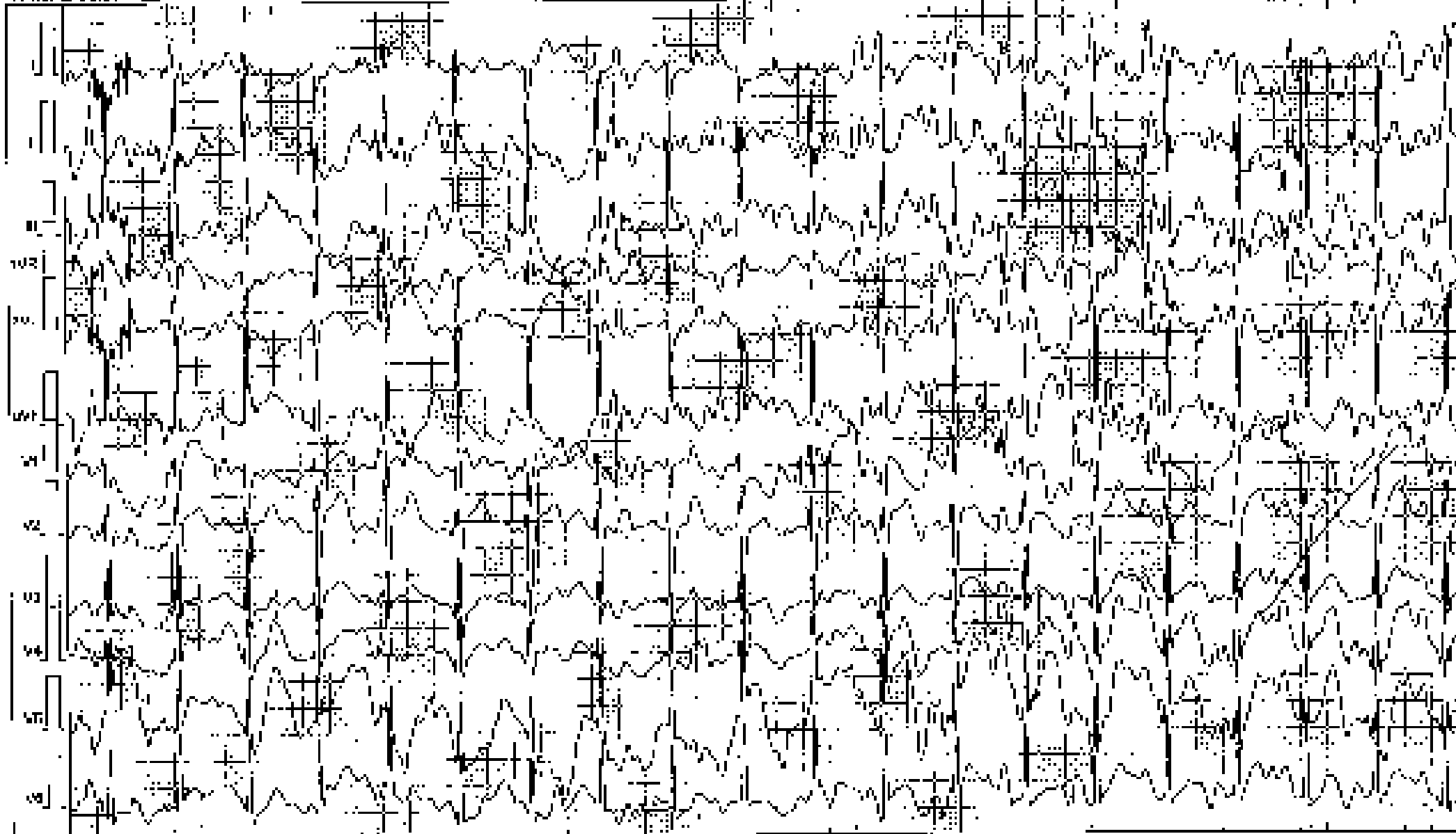
UJL ID No: 220625001140170

Locality: 82066 Inpt

KEMAR WELKS PLAZA

Lead: F0M1ET, HR: 112bpm, DP: 130/80

Time: E 08:07 - 02



55mm x 37mm 50mm - 50 (1-7)


SGI Product, 10.5cm x 10.5cm



ACHMAD CHOIRUNIHAR

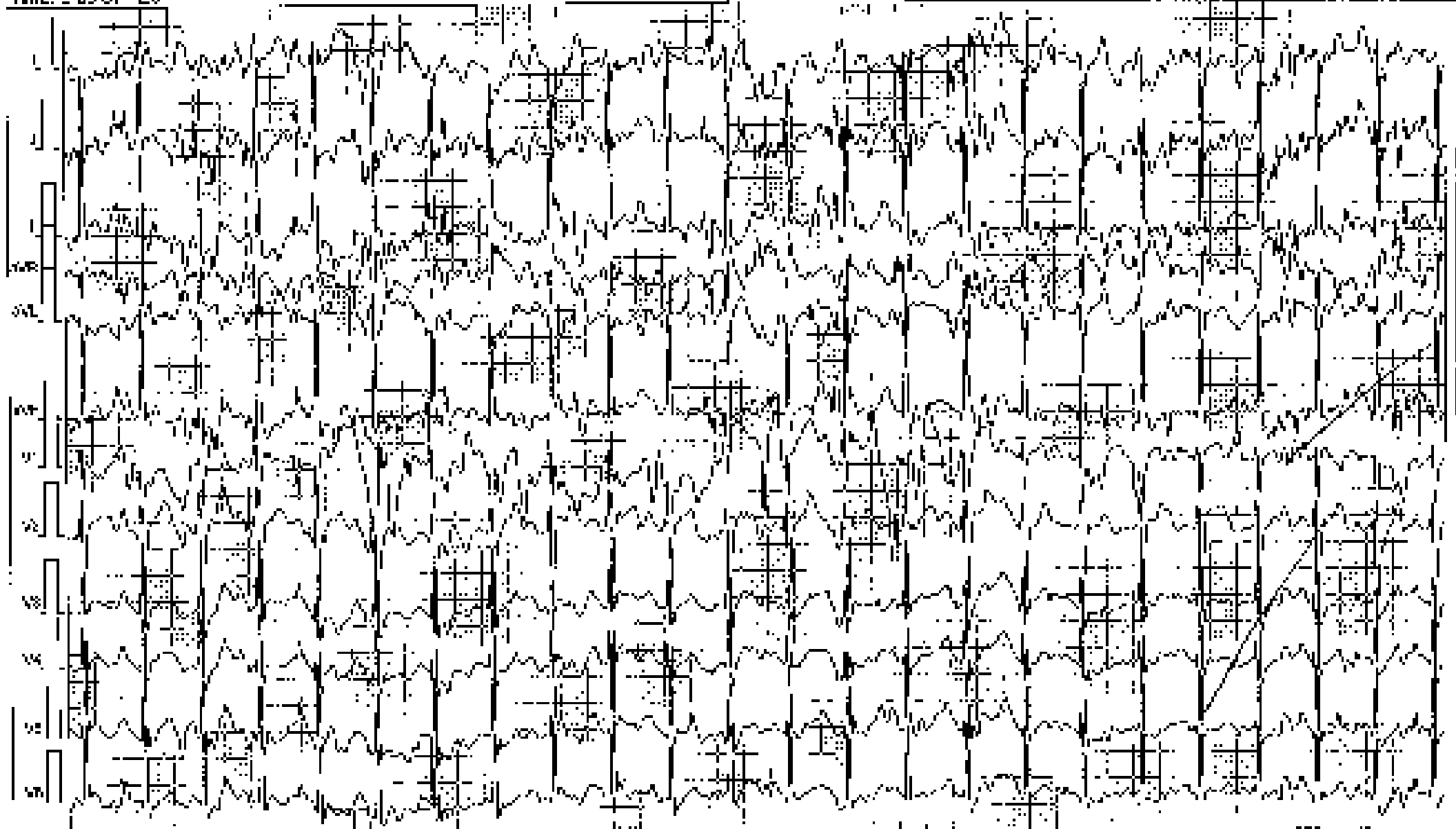Di: 21020750, Bdr. 10201, 922, 0415 261, 24, 1 kg, 155 cm  
Tgl: 02/02/2022, 12:00  
No: 1000, 800000000

411112 UTAPU PLAZA



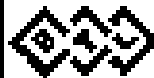Time: E 09:07 - L9

Level: 10.2MFT HR: 155bpm, BP: 140/90



ITW: P57 Sp1 m - 50 (0-2)

25.00 (1/2) 100 (1/2) 100 (1/2)



ACHTMAD CHOIRONI, MR

LJ 01 315770, Item: 0302019931644, 031 14.0 kg, 100cm

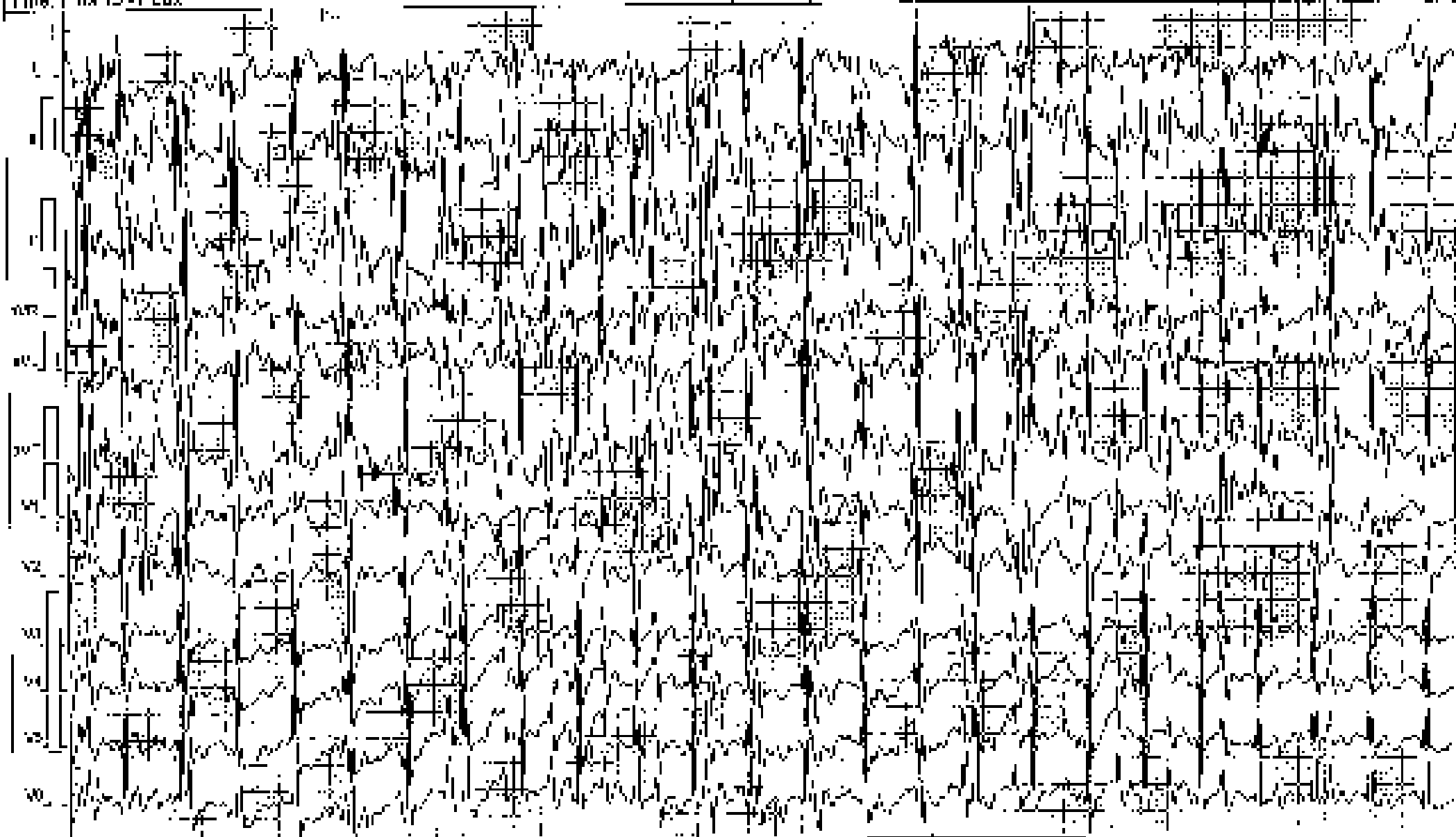
Taxi Date: 22/04/2022 11:45:00

Taxi type: Single Seat

PT. MIRA METERA PLAZA

Fig. F 09 15 - Peak

Loss: 10.0MEI, HR: 153bpm, EP:



- 2022/04/22 11:45:00 (Printed: 2022/04/22 11:45:00)

2022/04/22 11:45:00



AGH MAD UNDIRONI, MR

D: 01000000 Date: 22/07/2009 Jwb: 25, 74, 140 132 cm

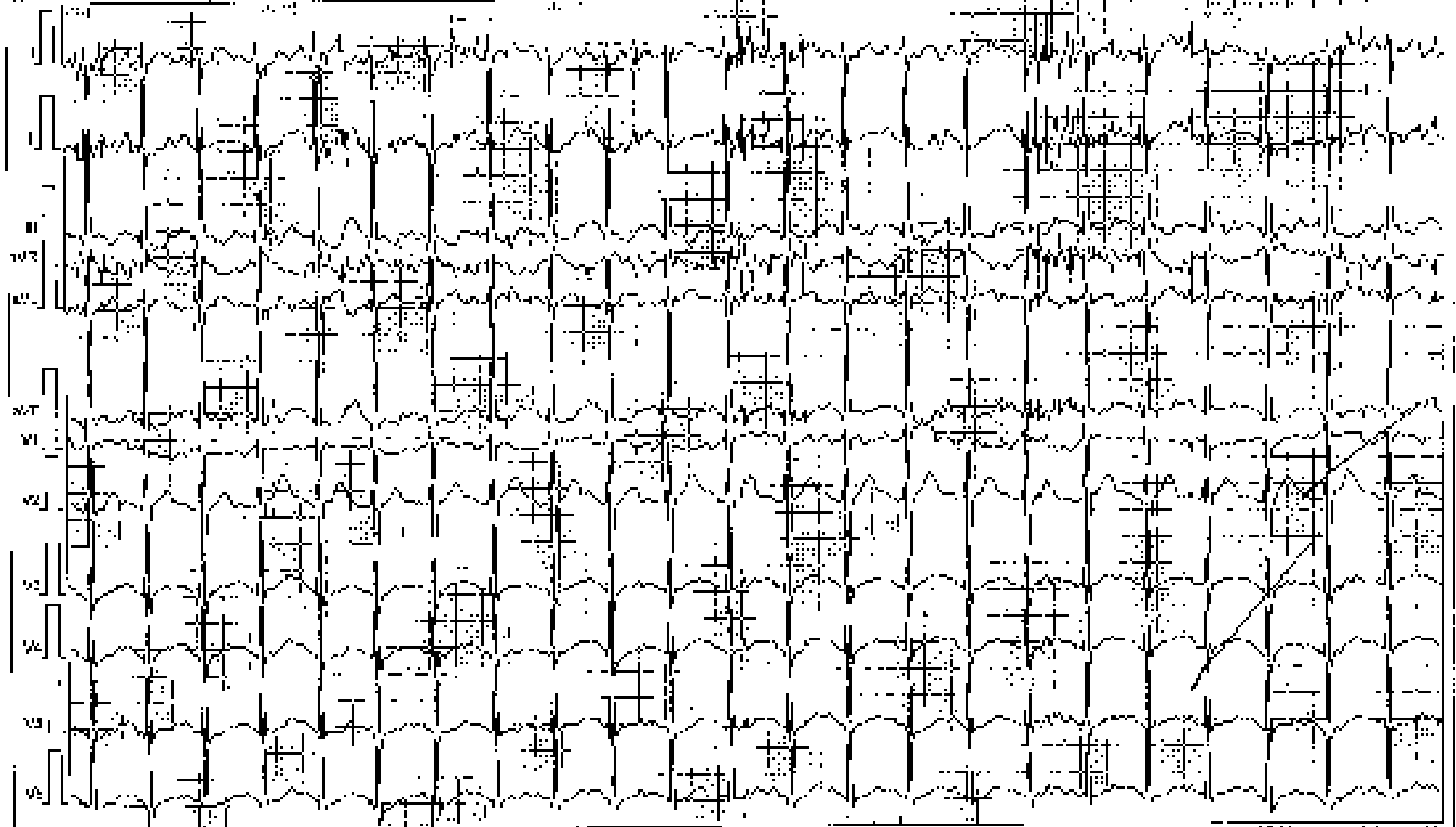
Time: 08: 28/07/2009 11: 47:00

Time type: 8P: 05: 00P

PT. MEDICA PLAZA

Time: R 00:10 Recover

Level: 2 CMFT, HR: 66bpm, BP: 140/80



Filter: 0.5 Hz, Sp1 to -90, Adapt, -90 Hz

5000 mV, 10.0 mm/s



ACHMAD SUPRIYONO, MR

Di: 01050700, From: 0300019823 (Auto 99), to: 1 kg, 100 cm

Test Date: 22/04/2022 11:42:00

Test type: Exercise Test

RUMAH KECERITA PLAZA

Stage	Time	Load			HR	BP	SpO2	ET Level [ mV ], J+; 100RR											
		km/h	%	MET				mmHg	%	I	II	III	aVR	aVI	aVF	V1	V2	V3	V4
Reference	P 00:15	0,8	0,3	1,1	123	120/80	-	0,94	0,71	0,75	-0,12	-1,52	2,82	-0,32	0,29	0,79	-0,70	-1,20	-0,72
F1 stage	E 00:07	2,7	10,0	4,0	88	120/80	-	0,96	-0,25	-0,17	0,07	0,07	-0,17	0,15	0,34	0,03	0,19	0,10	0,14
L2 stage	F 05:02	4,0	12,0	7,0	111	130/80	-	0,84	0,16	-0,28	-0,27	0,21	-0,27	0,12	0,32	0,07	-0,09	-2,45	-0,08
F3 stage	E 08:02	5,5	14,0	10,2	135	140/80	-	-0,10	-0,34	-0,16	0,15	0,33	-0,25	0,21	0,25	0,01	-0,09	0,06	0,10
#4 peak	F 09:20	6,0	16,0	13,9	155	140/80	-	0,69	0,06	-0,29	-0,28	0,29	-0,05	0,23	-0,24	-0,13	-0,27	-0,55	-0,20
Recovery	R 00:20	0,8	16,0	2,6	119	140/80	-	0,93	-0,05	-0,01	0,01	0,06	-0,22	-0,24	0,21	0,05	0,04	0,01	0,02