



Certificate Of Health Assessment

Name	Age	Position	Department
SYAIFUL	34 yo	INSPECTOR	-

COMPANY :
INSPEKTINDO SINERGI PERSADA

CONCLUSION	
Fit for work to the job described	
Fit with Medical Note (Restriction and/or Limitation)	✓
Unfit for work to the job described	

Date	Doctors Name	Signature
22 January 2018	Anggita Nur Aziza, MD	  PT. KARTIKA BINA MEDIKATAMA

No. Formulir : FM-DR-008-05
 No. Revisi : 00
 Tanggal Terbit : 2 Mei 2011

TO WHOM IT MAY CONCERN

Kepada yang berkepentingan

This is certify that today Monday, 22 January 2018 Medika Plaza Clinic has performed urine drug screening and/or breath alcohol test to :


Dengan ini menyatakan bahwa, pada hari ini Senin, 22 Januari 2018 Medika Plaza Clinic telah melakukan urine drug screening dan/atau breath alcohol test kepada :

SYAIFUL

With the results are as follows :
Dengan hasil sebagai berikut :

Drugs Test <i>Uji Obat</i>	Result <i>Hasil</i>		
URINE DRUGS SCREENING			
- Amphetamine	<input type="checkbox"/> Non-Negative	<input checked="" type="checkbox"/> Negative	<input type="checkbox"/> N/A
- Met-Amphetamine	<input type="checkbox"/> Non-Negative	<input type="checkbox"/> Negative	<input checked="" type="checkbox"/> N/A
- Cocain	<input type="checkbox"/> Non-Negative	<input checked="" type="checkbox"/> Negative	<input type="checkbox"/> N/A
- THC/Canabis/Marijuana	<input type="checkbox"/> Non-Negative	<input checked="" type="checkbox"/> Negative	<input type="checkbox"/> N/A
- Morphine/Opiates	<input type="checkbox"/> Non-Negative	<input checked="" type="checkbox"/> Negative	<input type="checkbox"/> N/A
- P C P/Phencyclidine	<input type="checkbox"/> Non-Negative	<input type="checkbox"/> Negative	<input checked="" type="checkbox"/> N/A
- Barbiturate	<input type="checkbox"/> Non-Negative	<input type="checkbox"/> Negative	<input checked="" type="checkbox"/> N/A
- Benzodiazepin	<input type="checkbox"/> Non-Negative	<input type="checkbox"/> Negative	<input checked="" type="checkbox"/> N/A
- Methadone	<input type="checkbox"/> Non-Negative	<input type="checkbox"/> Negative	<input checked="" type="checkbox"/> N/A
- Propoxyphene	<input type="checkbox"/> Non-Negative	<input type="checkbox"/> Negative	<input checked="" type="checkbox"/> N/A
- Oxycodone	<input type="checkbox"/> Non-Negative	<input type="checkbox"/> Negative	<input checked="" type="checkbox"/> N/A
- MDMA	<input type="checkbox"/> Non-Negative	<input checked="" type="checkbox"/> Negative	<input type="checkbox"/> N/A
- 6-MAM	<input type="checkbox"/> Non-Negative	<input type="checkbox"/> Negative	<input checked="" type="checkbox"/> N/A
BREATH ALCOHOL TEST			
- Alcohol	<input type="checkbox"/> Non-Negative	<input checked="" type="checkbox"/> Negative	<input type="checkbox"/> N/A

Jakarta, January 22, 2018


 (dr. Esther Puorwantoro, Sp.PK)
 Clinical Patologist

MP BELTWAY CLINIC

Beltway Office Park, Annex Building, Ground Floor
Jl. TB. Simatupang Kav.41, Jakarta Selatan 12550
Tlp : (62-21) 808 66 099, Fax : (62-21) 808 66 098
www.medikaplaza.com

PATIENT DATA

MedRec.	: 01031455	EMPLOY. STATUS	: Employee
NAME	: SYAIFUL	BIRTHDATE	: 03 February 1983
EMPLOYEE No.	:	SEX	: Male
JOB TITLE	: INSPECTOR	STATUS	: Married
COMP. NAME	: INSPEKTINDO SINERGI PERSADA	NASIONALITY	: Indonesia

SUMMARY

MEDICAL FINDING :

1. Hypertrygliceridemia with Fatty liver
 2. Hyperuricemia
 3. Non reactive anti HBs
 4. Decreasing of visual acuity of right eye
 5. Ocular hypertension of both eyes
 6. Missing, decayed, radix, calculus teeth
- Your fitness status is fit with medical note :
1. Hypertrygliceridemia with Fatty liver
 2. Ocular hypertension of both eyes

SUGGESTION :

1. Low fat and carbohydrate diet, exercise regularly minimal 3x/week. Consult to an internist for evaluation Hypertrygliceridemia with Fatty liver
2. Low purine diet such as meats including organ meats, alcoholic beverages, beans, shrimp, scallops, some vegetables in limited amount such as: spinach, cauliflower, asparagus and mushroom
3. Need to get Hepatitis B vaccination
4. Need to wear a glasses for distant vision
5. Consult to an Opthamologist for evaluation of Ocular Hypertension of both eyes
6. See a dentist for dental care minimal once a year or better once in 6 months

Responsible Doctor


Ahegita Nur Aziza, MD

Notes:

If you need the further information or consultation, please contact us via :

Email : - dr.Meiwulandari@medikaplaza.com
- dr.yosephine@medikaplaza.com
Telepon Klinik : (62-21) 295 22 610

PRIVATE

Printed by : vicka I

CLINICAL EVALUATION

Name : SYAIFUL	Sex : Male	MR : 01031455	Visit : 22/01/2018
Comp. : INSPEKTINDO SINERGI PERSADA		DOB : 03 February 1983	
EXAMINATION	RESULT	NOTES	

ANAMNESA

PRESENT COMPLAINT AND HISTORY OF PRESENT

ILLNESS

Present complaint

No complaint

MEDICAL HISTORY

Alergy	No
Imunisasi	Yes
Surgery	No
Hospitalization	No
Disease	No

LIFE STYLE

Alcohol intake	No
Smoking	No
Exercise	Yes Soccer 1x/week

FAMILY MEDICAL HISTORY

Diabetes Melitus	No
Hypertension	No
Heart disease	No
Lung TB	No
Kidney disease	No
Astma	No
Mental disease	No
Epilepsy	No
Cancer	No
Color blind	No
Stroke	No
Liver disease	No
Bone & joint	No
Others disease	No

WORK EXPOSURE

Noise	Yes
Heat Stress	No
Cold Stress	No
Vibration	Yes
Involving height	Yes
Radiation	No
Dust	Yes

CLINICAL EVALUATION

Name : SYAIFUL **Sex :** Male **MR :** 01031455 **Visit :** 22/01/2018

Comp. : INSPEKTINDO SINERGI PERSADA **DOB :** 03 February 1983

EXAMINATION	RESULT	NOTES
-------------	--------	-------

Toxic chemical	Yes	
Iritating fluid	No	
Smoke	Yes	
Bacterium/Virus/Parasite	No	
Blood	No	
Animal	No	
Operating heavy mobile equipment	No	
Manual Handling	Yes	
Sitting continuously over 4 hours	No	
Stand continuously over 4 hours	No	
Using monitor screen more than 4 hours per day	No	
Exposure	No	
Unergonomic body positions	No	
Shift work	No	
Work is not accordance with skills and knowledge	No	
Workload does not accordance with time	No	
Work conflict	No	
Inappropriate task	No	
Career barriers	No	
Family conflict	No	
Working arround rotating machinery	Yes	
Administration work	No	
Handling food product	No	
Others	No	

PHYSICAL EXAMINATION

General Apppearance	Good
Body shape	Athleticus

VITAL SIGN

Body Weight	68.1 Kg
Body Height	166 Cm
BMI	24.71 Kg/m2
Normal Weight	50.98 - 68.89 Kg
BMI Conclusion	Normal
Blood Pressure	120/80 mmHg
Pulse	82 x/minute
Body Temperature	36.2 °C
RR	18

CLINICAL EVALUATION

Name : SYAIFUL Sex : Male MR : 01031455 Visit : 22/01/2018

Comp. : INSPEKTINDO SINERGI PERSADA DOB : 03 February 1983

EXAMINATION	RESULT	NOTES
Neck Circumference	-	
Arm Circumference	-	
Chest size	-	
Abdominal Circumference	90 Cm	
SKIN		
Skin	Normal	
EYE		
Left	Normal	
Right	Normal	
ENT		
Auricle	Normal	
Ear canal	Normal	
Drums	Normal	
Septum/Conchae	Normal	
Sinuses	Normal	
Pharynx	Normal	
Tonsil	Normal	
MOUTH		
Gum	Normal	
Dental	Abnormal	Missing, decayed, radix, calculus teeth
NECK		
General	Normal	
Thyroid Gland	Normal	
CHEST		
Form	Normal	
Lung	Normal	
Heart	Normal	
Breast	Normal	
ABDOMEN		
Form	Flat	
Palpation	Supple	
Liver	Not Palpable	
Spleen	Not Palpable	
Kidney	No Ballotment	
-	No	
Hernia inguinal	No	
EXTRIMITIES		

CLINICAL EVALUATION

Name : SYAIFUL	Sex : Male	MR : 01031455	Visit : 22/01/2018
Comp. : INSPEKTINDO SINERGI PERSADA		DOB : 03 February 1983	

EXAMINATION	RESULT	NOTES
Bones, joint	Normal	
Muscles, tonus	Normal	
Fingernails	Normal	
Hand	Normal	
Foot	Normal	
RECTAL EXAMINATION		
Hemorrhoid	Negative	
Rectum	Normal	
SENSORIK EXAMINATION		
Tes Raba	Normal	
MOTORIK EXAMINATION		
Tes Grip	Normal	
REFLEX EXAMINATION		
Physiologic reflex	Normal	
Patologic reflex	Normal	
OTHERS EXAMINATION		
Coordination	Normal	
LYMPHE SYSTEM		
Submandibula	Normal	
Neck Gland	Normal	
Armpit gland	Normal	
Inguinal	Normal	

OPHTHALMOLOGY DIAGNOSTIC

Name : SYAIFUL Sex : Male MR : 01031455 Visit : 22/01/2018

Comp. : INSPEKTINDO SINERGI PERSADA DOB : 03 February 1983

EXAMINATION		Right	Left
Reading		-	-
Previous Glasses		-	-
Without Glasses	Distant	20/30	20/20
	Near	J1	J1
Correction	Distant	S-0.50 20/20	S-0.50 20/20
	Near	-	-
		-	-
Tonometry		25.0 mmHg	23.7 mmHg
Funduscopy		NORMAL	NORMAL
Visual Fields		-	-
Colour Blind Test		Normal	

Impression : Myopia simplex ODS
Hypertensi ocular ODS

Recheck 1-2 weeks later

RADIOLOGY DIAGNOSTIC

Name : SYAIFUL	Sex : Male	MR : 01031455	Visit : 22/01/2018
----------------	------------	---------------	--------------------

Comp. : INSPEKTINDO SINERGI PERSADA	DOB : 03 February 1983
-------------------------------------	------------------------

EXAMINATION	RESULT
-------------	--------

THORAX PA

No abnormality seen in both lungs.
Normal bronchovascular markings in both hili.
The heart is normal in size and shape.
The mediastinum is not widened.
Both sinus and diaphragms are good.
No evidence of pleural effusion.

Impression

Normal chest.
No evidence of specific process in both lungs.

RADIOLOGY DIAGNOSTIC

Name : SYAIFUL	Sex : Male	MR : 01031455	Visit : 22/01/2018
Comp. : INSPEKTINDO SINERGI PERSADA		DOB : 03 February 1983	

EXAMINATION**RESULT****USG ABDOMEN****LIVER:**

Normal in size and contour, smooth surface, parenchyme echoes structures increased. No sign of SOL.

Intrahepatic vascularity and billiary tract are normal.

GALL BLADDER:

Normal in size, contour and surface. No sign of SOL/ sludge/ stone.

RIGHT KIDNEY :

Normal in size, contour and surface. No sign of obstruction/stone/ SOL.

LEFT KIDNEY:

Normal in size, contour and surface. No sign of obstruction/ stone/ SOL.

PANCREAS:

Normal in size, contour and surface. No sign of SOL.

LIEN:

Normal in size and contour, the echoes are homogenous. No sign of SOL.

URINARY BLADDER:

Normal in size, contour and surface. No sign of stone/ SOL.

PROSTATE AND VESICULA SEMINALIS:

Normal in size and contour which are homogenous echoes and no sign of focal lesion/ SOL.

Impression

Fatty liver.

Other abdominal organs are normal.

LABORATORY RESULT

Name : SYAIFUL	MR : 01031455	Visit : 22/01/2018	#Lab : IN623125108780
Comp. : INSPEKTINDO SINERGI PERSADA	Sex : Male	DOB : 03 February 1983	
EXAMINATION	RESULT	NORMAL RANGE	

HEMATOLOGI

Automated Blood Count

White Blood Cell (WBC)	10.6	3.8 - 11.0
Erythrocyte (RBC)	5.4	4.4 - 5.9
Haemoglobin	15.8	13.2 - 17.3
Hematocrit	46	40 - 52
Thrombocytes	317	150 - 440

MCV, MCH, MCHC

MCV	87	80 - 100
MCH	30	26 - 34
MCHC	34.1	32 - 36
ESR	2	0 - 10

Differential Count

Basophils	0	0 - 1
Eosinophil	3	2 - 4
Bands / Stab	1 *	3 - 5
Neutrophils	46 *	50 - 70
Lymphocytes	41 *	25 - 40
Monocytes	9 *	2 - 8

BLD CHEMISTRY/LIPID PROFILE

Total Cholesterol	199	Normal/Desireable: <200 Borderline High: 200-239 High: >=240
HDL Cholesterol	44.3	Normal : >40 - <60 Low HDL : <40 Desireable : >=60
LDL Cholesterol	113	Optimal: <100 Near/Above Optimal: 100-129 Borderline High: 130-159 High: 160-189 Very High: >=190
Tryglicerides	211 *	Normal : <150 Borderline High: 150-199 High : 200-499 Very High : >=500

BLD CHEMISTRY/KIDNEY FUNCTION

Ureum	17.2	10.0 - 50.0
-------	------	-------------

LABORATORY RESULT

Name : SYAIFUL	MR : 01031455	Visit : 22/01/2018	#Lab : IN623125108780
Comp. : INSPEKTINDO SINERGI PERSADA	Sex : Male	DOB : 03 February 1983	

EXAMINATION	RESULT	NORMAL RANGE
Creatinine	1.0	0.6 - 1.3
Uric Acid	8.7 *	3.5 - 7.2

BLD CHEMISTRY/LIVER FUNCTION

Total Bilirubin	0.9	0.1 - 1.0
SGOT(AST)	38	13 - 45
SGPT (ALT)	48	13 - 50
Alkaline Phosphatase	74	30 - 120
Gamma GT	37	0 - 50
Albumin	4.8	3.5 - 5.5
Globulin	2.50	2.3 - 3.5
Total Protein	7.3	6.6 - 8.7

BLD CHEMISTRY/DIABETES

Glucose Fasting	97	< 100
Glucose Urine	Negative	Negative
Keton Urine	Negative	Negative

Blood Glucose 2 PP

Blood Sugar 2 Hours PP	92	< 140
Glucose Urine	Negative	Negative
Keton Urine	Negative	Negative

SEROLOGI / IMUNOLOGI

HBsAg (Quantitative)	0.00	0.00 - 0.03
Anti Hbs (Quantative)	0.2 *	>= 5.0
VDRL	Negative	Negative

TOXICOLOGY - DRUGS SCREENING

MDMA	Negative	Negative
THC/Marijuana	Negative	Negative
Amphetamine	Negative	Negative
Opiat	Negative	Negative
Cocain	Negative	Negative
Alcohol	Negative	Negative

URINALYSIS

Complete Urine Analysis

Macroscopic

Color	Colorless	
Turbidity	Clear	Clear
Specific Gravity	1.012	1.000 - 1.030
pH	5.5	4.5 - 8.0

LABORATORY RESULT

Name : SYAIFUL	MR : 01031455	Visit : 22/01/2018	#Lab : IN623125108780
Comp. : INSPEKTINDO SINERGI PERSADA	Sex : Male	DOB : 03 February 1983	

EXAMINATION	RESULT	NORMAL RANGE
Leucocyte	Negative	Negative
Glucose	Negative	Negative
Nitrit	Negative	Negative
Bilirubin	Negative	Negative
Blood	Negative	Negative
Urobilinogen	Normal	Normal
Protein	Negative	Negative
Keton	Negative	Negative
Microscopic		
RBC	0-1	0 - 1
WBC	0-1	0 - 4
Cylinder	Negative	
Epithels Squamous	0-1	5 - 15
Crystals	Negative	
Bacteria	Negative	Negative
Others	Negative	

SPIROMETRY DIAGNOSTIC

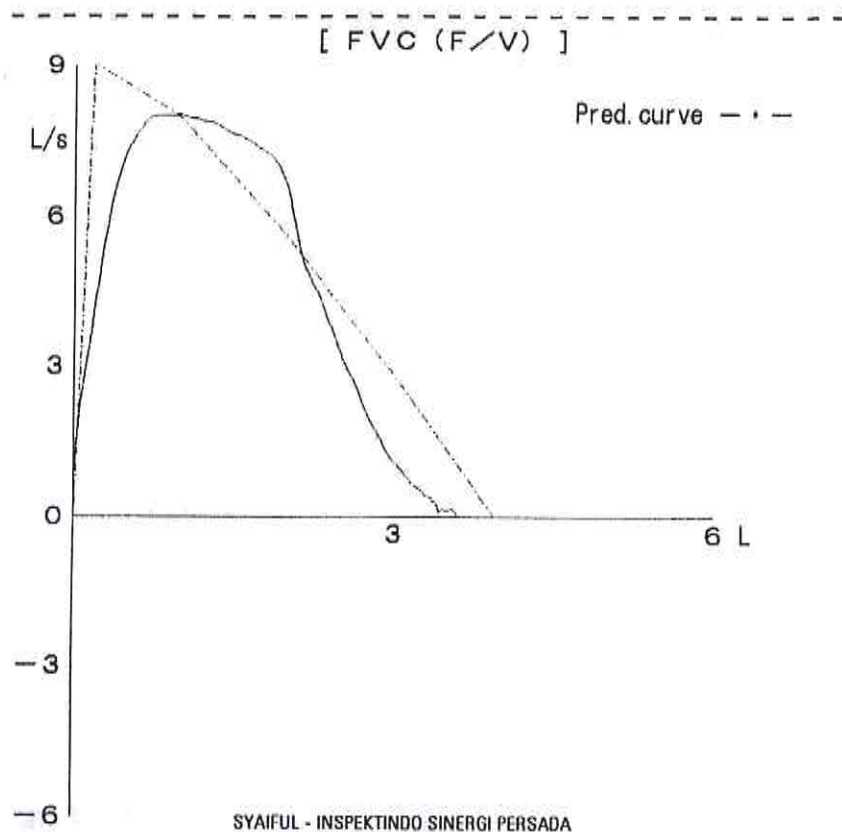
Name : SYAIFUL	Sex : Male	MR : 01031455	Visit : 22/01/2018
Comp. : INSPEKTINDO SINERGI PERSADA		DOB : 03 February 1983	

EXAMINATION	RESULT
FVC Result	: 3.60 L---> 91.1 %
FEV1 Result	: 3.26 L---> 90.8 %
FEV1/FVC Result	: 90.56 %---> 114.5 %
PEF Result	: 8.00 L/S---> 77.0 %
Indonesian Standart Result	:
Index	:
Spirometry Result	: Normal

Impression : Normal Spirometric Functions

[COPD CLASSIFICATION]

FEV1/FVC : 90.56 %
 %FEV1.0 : 90.80 %
 Stage : Normal
 Recommended treatment by GOLD:



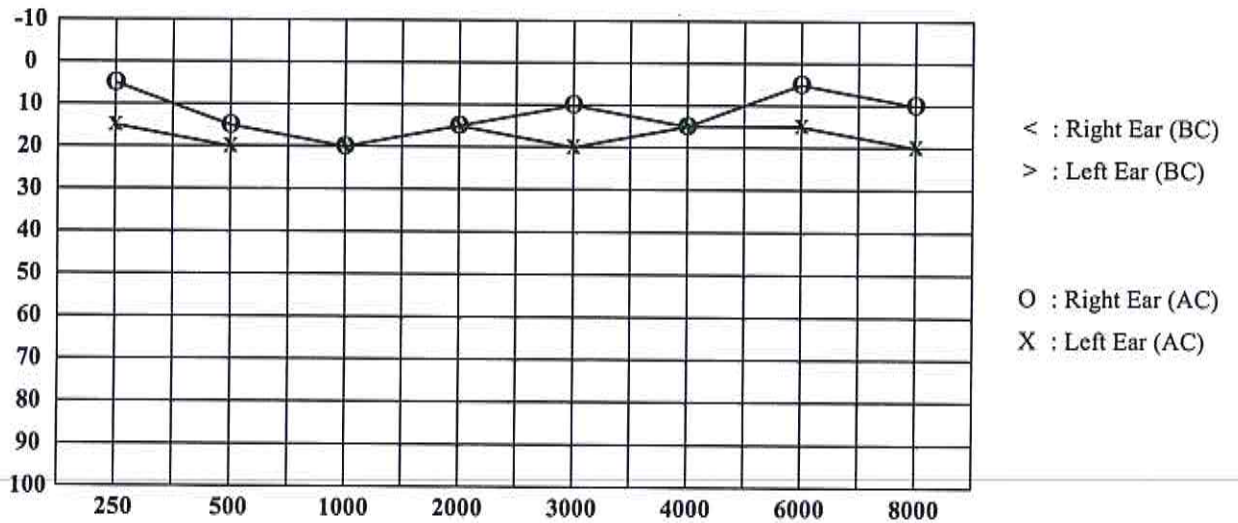
AUDIOMETRY DIAGNOSTIC

Name : SYAIFUL	Sex : Male	MR : 01031455	Visit : 22/01/2018
Comp. : INSPEKTINDO SINERGI PERSADA		DOB : 03 February 1983	

RESULT

Left Ear	250	500	1000	2000	3000	4000	6000	8000
AC	15	20	20	15	20	15	15	20
BC	-	-	-	-	-	-	-	-

Right Ear	250	500	1000	2000	3000	4000	6000	8000
AC	5	15	20	15	10	15	5	10
BC	-	-	-	-	-	-	-	-



Conclusion Right Ear : Hearing threshold = 16.25 dB
(Within normal limit)

Conclusion Left Ear : Hearing threshold = 17.5 dB
(Within normal limit)

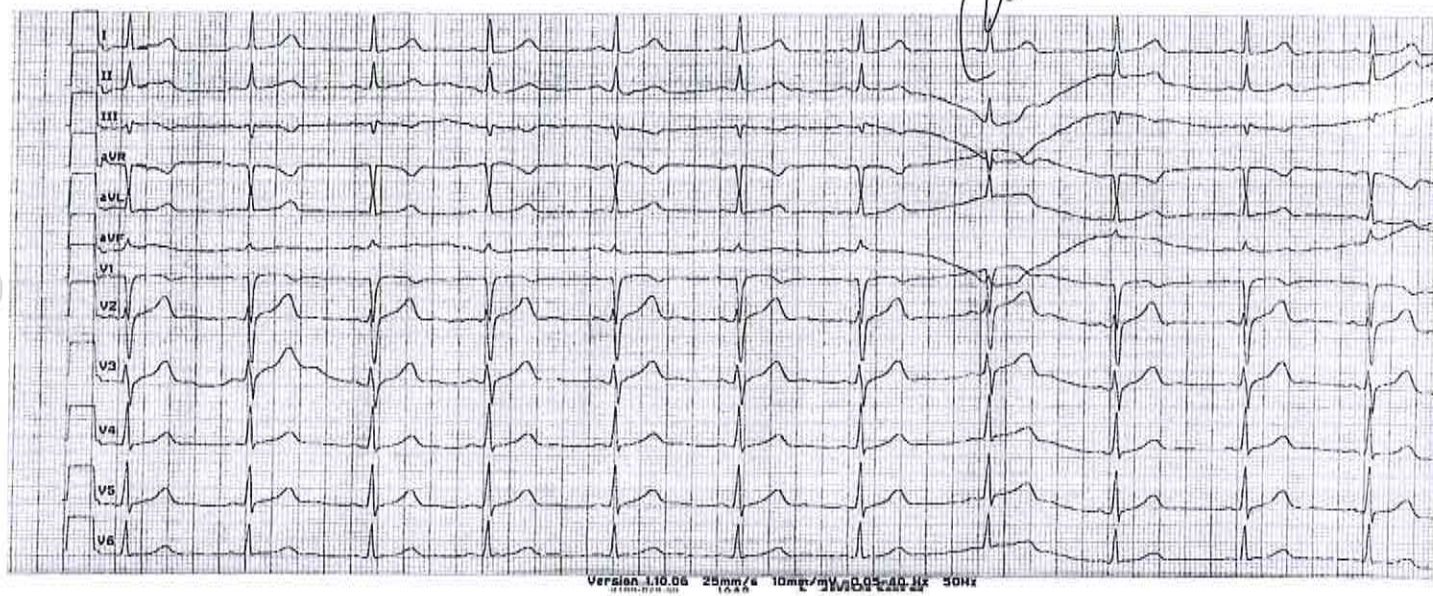
CARDIOLOGY DIAGNOSTIC

Name : SYAIFUL	Sex : Male	MR : 01031455	Visit : 22/01/2018
Comp.: INSPEKTINDO SINERGI PERSADA		DOB : 03 February 1983	

EXAMINATION	RESULT	Comments :
ELECTROCARDIOGRAPHY	Sinus Rythm axis (N), P wave (N), PR int 0.16" ST - T segment (N), aritmia (-)	Normal ECG
TREADMILL	Sinus Rythm axis (N), P wave (N), PR int 0.16" ST - T segment (N), aritmia (-)	Treadmill Exercise Test : Negative Cardiopulmonary Fitness Classification : Good METs : 13.4

SYAIFUL
DOB: 03/02/1983
W: 34 yo
INSPEKTINDO SINERGI PERSADA

22-Jan-2018 6:49:39



SYAIFUL, MR

ID: 01031455, Born: 03/02/1983 (Male 34), 68 kg, 166 cm
Test Date: 22/01/2018 7:56:29

MEDIKA PLAZA

MP+
MEDICAL PLAZA

Patient info

Born: 03/02/1983
Age: 34
Sex: Male
Weight: 68 Kg
Height: 166 cm
Smoker:
Pacemaker:

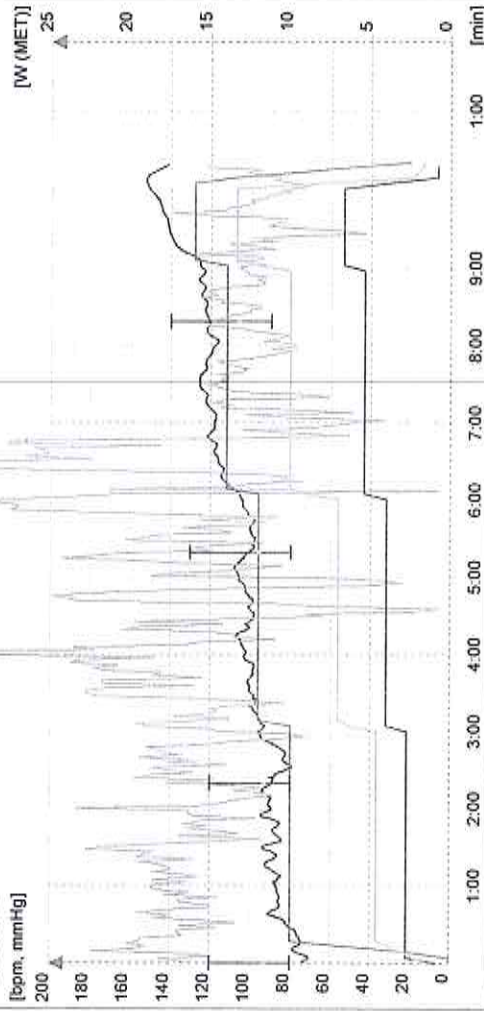
Medical history

Medications

Reason for Admission

Reason for Stop

Trends



Conclusion

[Handwritten signature]

MP+

PT. KARTIKA BINA MEDIKA PLAZA

Staff

Attending doctor:
Technician:

Adolf Amahorseya, SpJP
Jeni, NR

Test info

Test date: 22/01/2018
Test time: 7:56
Stress device: BTL Treadmill
Protocol: Bruce
Total duration: 10:01
Stress achieved: 6,7 km/h, 16,0% (~13,4MET) = 141% predicted (~10,1MET) - for 62 sec
HR rest: 78
HR peak: 148 = 89% predicted (166) — 10:02 Exercise (13,4MET)
Handgrip test: —
BP rest: 120/80
BP peak: —
BP recovery: —
DP rest: 8760
DP peak: 16834 = 1,9x DP at rest
ST depression max: III -0,86mV 03:57 Exercise 7,0MET
ST elevation max: V4 0,77mV 05:42 Exercise 7,0MET
ST/HR index: 2,4 µV/bpm (abnormal)



SYAIFUL, MR

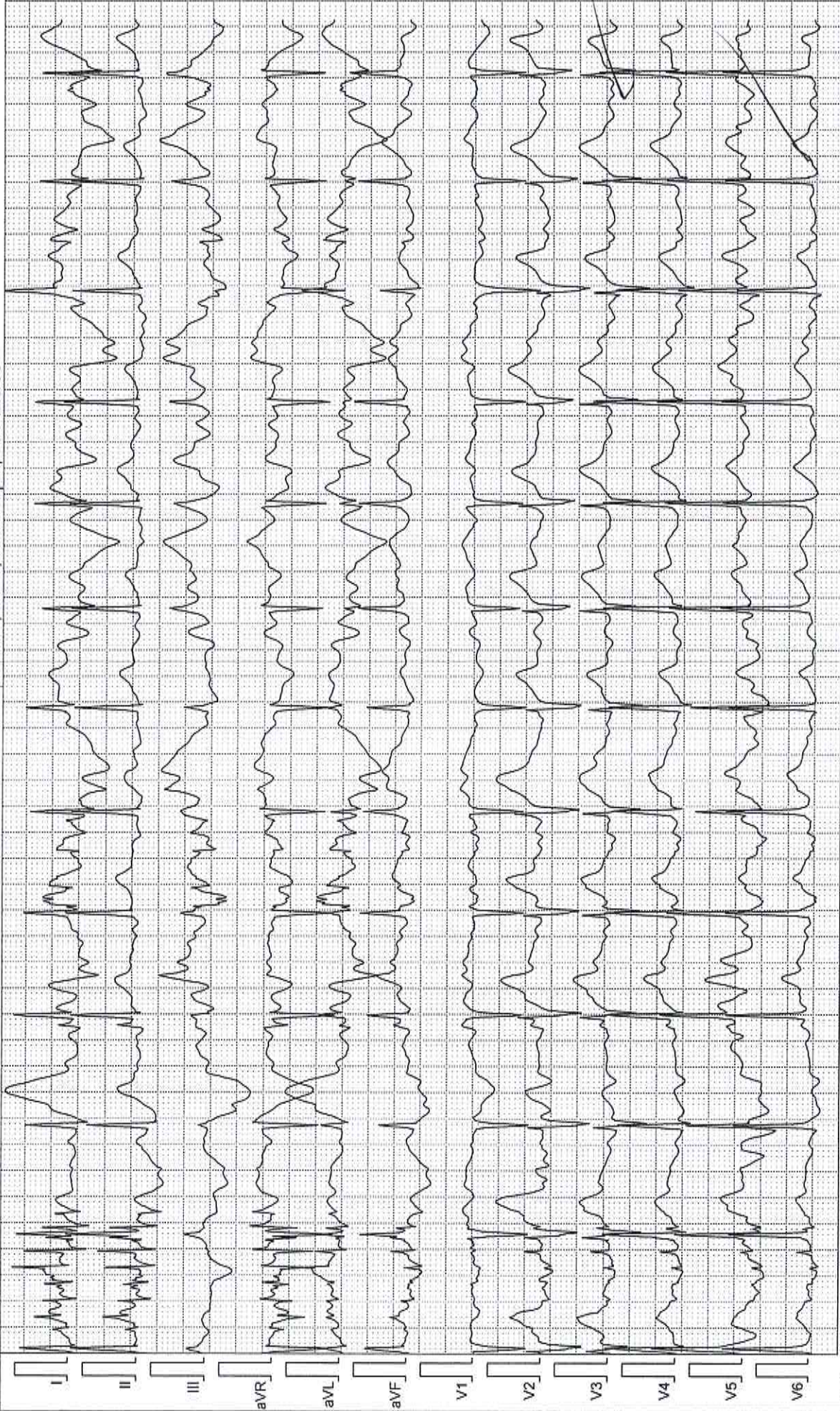
ID: 01031455, Born: 03/02/1983 (Male 34), 68 kg, 166 cm
Test Date: 22/01/2018 7:56:29

MEDIKA PLAZA

MP+

Time: P 00:16 - Reference

Load: 1.4MET, HR: 73bpm, BP: 120/80



Filter: 0.07 Spline - 90 Adapt, ~50 [Hz]

25,00 mm/sec 10,0 mm/mV

SYAIFUL, MR

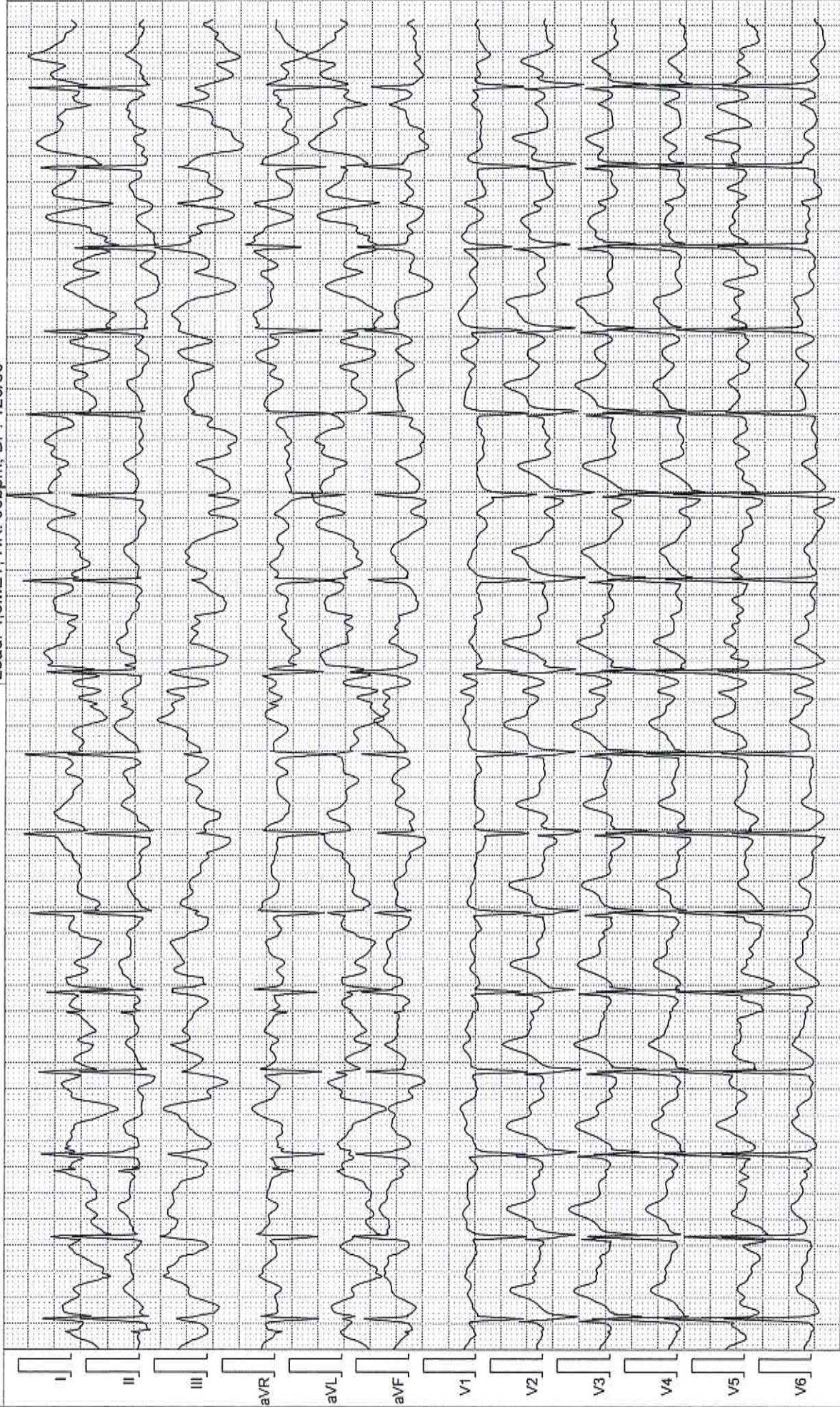
ID: 01031455, Born: 03/02/1983 (Male 34), 68 kg, 166 cm
Test Date: 22/10/2018 7:56:29

MEDIKA PLAZA

MP+

Time: E 02:56 - E1

Load: 4.6MET, HR: 96bpm, BP: 120/80



Filter: 0.07 Spline - 90 Adapt, ~50 [Hz]

25.00 mm/sec 10.0 mm/mV



SYAIFUL, MR

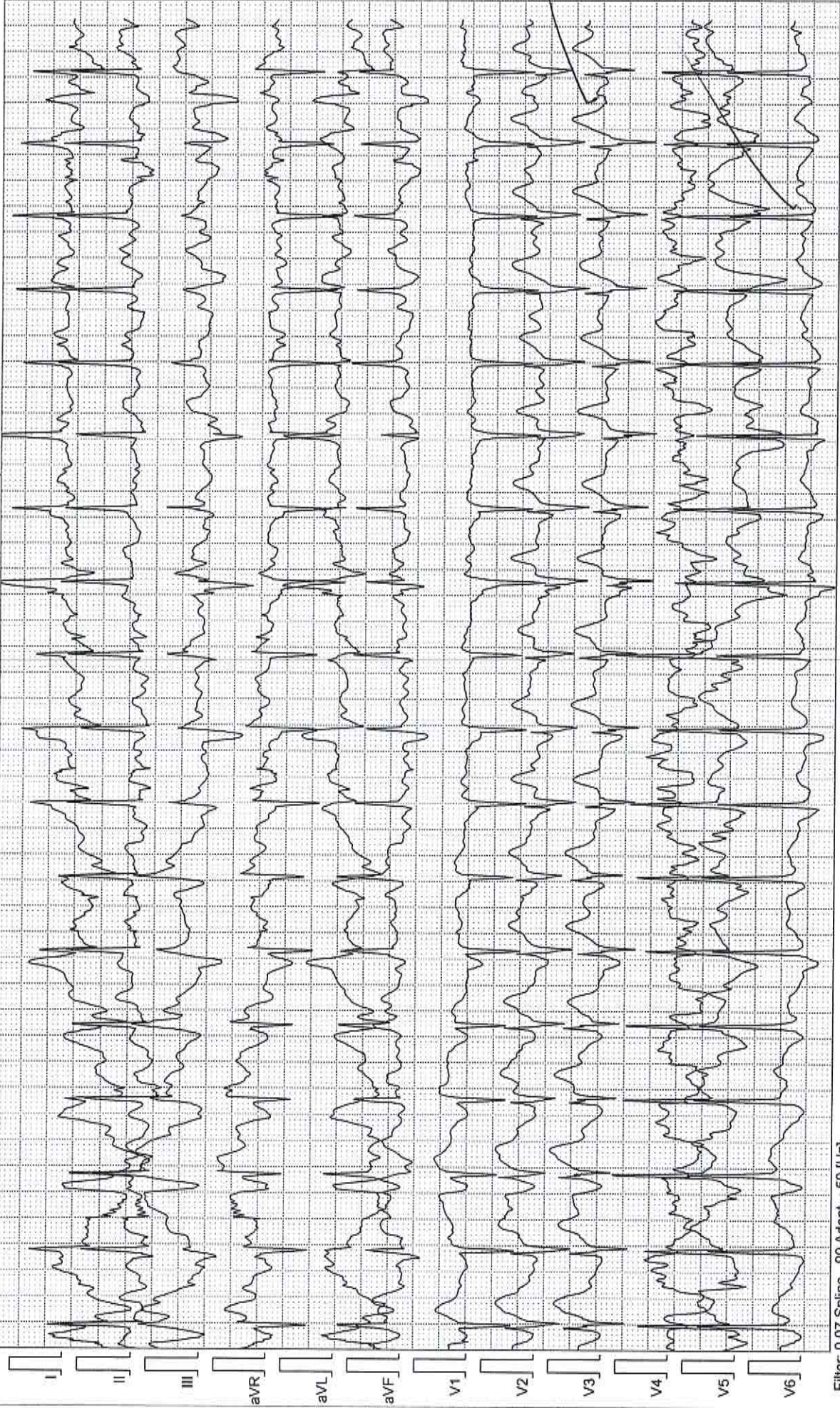
ID: 01031455, Born: 03/02/1983 (Male 34), 68 kg, 166 cm
Test Date: 22/10/2018 7:56:29

MEDIKA PLAZA

MP+

Time: E 05:55 - E2

Load: 7,0MET, HR: 104bpm, BP: 130/80



Filter: 0.07 Spine - 90 Adapt, ~50 [Hz]

25,00 mm/sec 10,0 mm/mV



SYAIFUL, MR

ID 01031455, Born: 03/02/1983(Male 34), 68 kg, 166 cm
Test Date: 22/01/2018 7:56:29

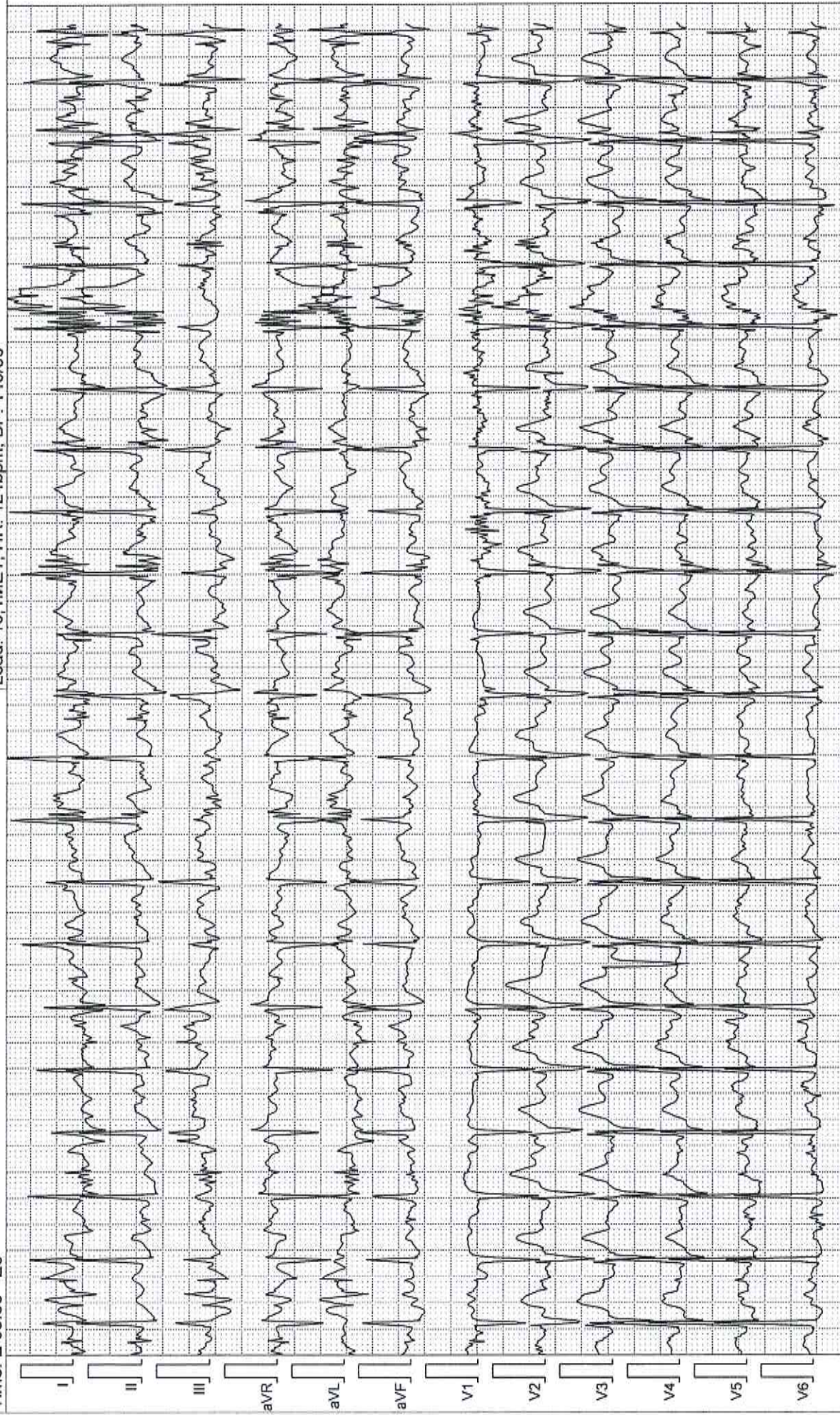
MEDIKA PLAZA

MP+

MEDIKA PLAZA

Time: E 08:55 - E3

Load: 10.1MET, HR: 124bpm, BP: 140/90



Filter: 0.07 Spline - 90 Adapt, ~50 [Hz]

25.00 mm/sec 10.0 mm/mV



SYAIFUL, MR


ID 01031455, Born: 03/02/1983(Male 34), 68 kg, 166 cm
Test Date: 22/01/2018 7:56:29

MEDIKA PLAZA

MP⁺
MEDICAL DATA

Time: E 09:57 - Peak

Load: 13.4MET, HR: 151bpm, BP: -



Filter: 0.07 Spline - 90 Adapt. ~50 [Hz]

25.00 mm/sec 10.0 mm/mV



SYAIFUL, MR


ID: 01031455, Born: 03/02/1983 (Male 34), 68 kg, 166 cm
Test Date: 22/01/2018 7:56:29

MEDIKA PLAZA

MP+

Time: R 00:10 - RECOVERY

Load: 2,1MET, HR: 147bpm, BP: -



Filter: 0.07 Spline - 90 Adapt, ~50 [Hz]

25,00 mm/sec 10,0 mm/mV

SYAIFUL, MR

ID 01031455, Born: 03/02/1983(Male 34), 68 kg, 166 cm
 Test Date: 22/01/2018 7:56:29

MEDIKA PLAZA

MP+

Stage	Time	Load		HR bpm	BP mmhg	SpO2 %	ST Level [mV], J+: 1/8RR											
		km/h	%				I	II	III	aVR	aVL	aVF	V1	V2	V3	V4	V5	V6
Reference	E 00:02	0,8	0,0	73	120/80	-	0,17	0,02	-0,15	-0,09	0,15	-0,07	-0,01	0,14	0,15	0,07	-0,09	-0,03
E 1 step	E 03:01	2,7	10,0	94	120/80	-	-0,14	0,14	0,28	0,00	-0,21	0,21	0,12	0,21	0,24	0,14	0,01	0,05
E 2 step	E 06:00	4,0	12,0	104	130/80	-	0,57	-0,30	-0,86	-0,14	0,72	-0,58	-0,03	0,07	-0,01	-0,11	0,12	-0,20
E 3 step	E 08:59	5,4	14,0	124	140/90	-	-0,03	-0,09	-0,06	0,06	0,01	-0,07	0,10	0,14	0,16	0,03	-0,03	-0,03
E 4 peak	E 10:02	6,7	16,0	148	-	-	-0,02	-0,09	-0,08	0,05	0,04	-0,09	0,10	0,14	0,18	-0,02	-0,10	-0,09
RECOVERY	R 00:20	0,8	16,0	147	-	-	-0,01	0,09	0,09	-0,04	-0,05	0,08	0,09	0,18	0,23	0,10	0,03	0,00

PATIENT NAME : TM. SYAIFUL

No. RM : 01.031455

Clinik/MCU/HCU : ENT

To. Dokter :
(Counsel)

Kindly please counsel for patient who has take cares of

Diagnose :
Clinik Summary :

Counsel Request :

COUNSEL ADVISE

Finding

Diagnosis

Recomendation

Ear : Tympanic membrane intact
Note : Inferior turbinate eutrophy
Throat : Tonsil T3T3, wide crypta
Audiometry : Normal hearing threshold
- chronic tonsillitis
- Note & Ear examination within normal limit.

Date : 22/01/2018
Time :
EP :

Signature
dr. Meristiana Cristiane, Sp. THT
Spesialis THT

