



MEDIKA PLAZA
INDONESIA

MEDIKA PLAZA HEALTH & MEDICAL SERVICES

Medical Screening Questionnaire And Examination Record

Surname: <u>SYAIFUL</u>		Forenames:	
Address: <u>Jl. Lumbu timur II^A no 281</u>		Tel No: <u>0812 1849 1446</u>	
Date of Birth: <u>03 feb 1983</u>			
GP's Name:			
GP's Address:			
Date of Last Offshore Medical: <u>2018 / 01 / 23</u>		Offshore Occupation/Job Title: <u>Inspector</u>	
Emergency Response Role :			
Social / Occupational History			
	Yes	No	Comments
(1) Do you smoke? If so, how many per day?	<input checked="" type="checkbox"/>	<input type="checkbox"/>	<u>12 btrng</u>
(2) If an ex-smoker, when did you give up?	<input type="checkbox"/>	<input type="checkbox"/>	
(3) Average weekly alcohol consumption: state quantity and type.	<input type="checkbox"/>	<input checked="" type="checkbox"/>	
(4) Have you been exposed to any known occupational hazard such as noise, radiation, dusts, asbestos, chemicals or lead?	<input type="checkbox"/>	<input checked="" type="checkbox"/>	
(5) Do you use protective clothing, safety glasses or hearing protection?	<input checked="" type="checkbox"/>	<input type="checkbox"/>	
(6) Have you ever developed any medical condition in connection with your occupation? If so, please give details eg hearing loss/skin condition/wheeze/backache/muscle strain/blood disease?	<input type="checkbox"/>	<input checked="" type="checkbox"/>	
(7) Have you suffered any industrial injury? If so, please give details:	<input type="checkbox"/>	<input checked="" type="checkbox"/>	
(8) Have you ever had any previous audiometric screening? Was this normal? State when and where.	<input type="checkbox"/>	<input checked="" type="checkbox"/>	
(9) Have you ever had any previous lung function screening? Was this normal? State when and where.	<input type="checkbox"/>	<input type="checkbox"/>	
(10) Have you ever been rejected from employment on medical ground?	<input type="checkbox"/>	<input checked="" type="checkbox"/>	
(11) Have you ever received compensation, or is there any industrial claim pending?	<input type="checkbox"/>	<input checked="" type="checkbox"/>	
(12) Have you ever been medivaced from an offshore installation?	<input checked="" type="checkbox"/>	<input checked="" type="checkbox"/>	
Examining Physician's comments :			

* Source : Medical Aspects of Fitness for Work Offshore Guidance for Examining Physicians Oil & Gas UK, March 2008

**Medical Screening Questionnaire And
 Examination Record (cont'd)**

Do you have, or have you been diagnosed as suffering from any of the following?
(Please circle and elaborate)

Please circle and elaborate

(1) Chest pain/heart pain	Yes	<input checked="" type="radio"/> No	
(2) High blood pressure / stroke	Yes	<input checked="" type="radio"/> No	
(3) Asthma / Epilepsy/Diabetes	Yes	<input checked="" type="radio"/> No	
(4) Peptic ulcer disease	Yes	<input checked="" type="radio"/> No	
(5) Kidney disease (eg stones)	Yes	<input checked="" type="radio"/> No	
(6) Psychiatric disorder (eg anxiety, depression)	Yes	<input checked="" type="radio"/> No	
(7) Tuberculosis	Yes	<input checked="" type="radio"/> No	
(8) Cancer	Yes	<input checked="" type="radio"/> No	


Do any of your immediate family (parents/brothers/sisters) have a history of any of the above conditions? Please specify :

Do you currently have any of the following?

(1) Backache/joint or muscular pain	Yes	<input checked="" type="radio"/> No	
(2) Hernia/rupture	Yes	<input checked="" type="radio"/> No	
(3) Visual impairment	Yes	<input checked="" type="radio"/> No	
(4) Perforated eardrum / discharge from ear	Yes	<input checked="" type="radio"/> No	
(5) Recurrent indigestion	Yes	<input checked="" type="radio"/> No	
(6) Jaundice/hepatitis/gall bladder disease	Yes	<input checked="" type="radio"/> No	
(7) Change in bowel habit/diarrhoea	Yes	<input checked="" type="radio"/> No	
(8) Blood in stools/piles/haemorrhoids	Yes	<input checked="" type="radio"/> No	
(9) Shortness of breath/coughing up blood	Yes	<input checked="" type="radio"/> No	
(10) Recurrent bronchitis/pneumonia	Yes	<input checked="" type="radio"/> No	
(11) Blood in urine/kidney complications/stones	Yes	<input checked="" type="radio"/> No	
(12) Headaches/migraine/dizziness	Yes	<input checked="" type="radio"/> No	

Physician's comments :

I certify that the above information is correct :

Signed :  Syaiful [Employee]

** Source : Medical Aspects of Fitness for Work Offshore Guidance for Examining Physicians Oil & Gas UK, March 2008*

**Medical Screening Questionnaire And
 Examination Record (cont'd)**

	Normal	Abnormal	Comments
1. Eyes/pupils	✓		Decayed, rad x, missing, Calculus Teeth
2. Ear, nose and throat	✓		
3. Teeth		✓	
4. Lungs/chest	✓		
5. Cardiovascular	✓		
6. Abdomen	✓		
7. Hernial orifices	✓		
8. Genitourinary	✓		
9. Musculoskeletal	✓		
10. Skin	✓		
11. Varicose veins	✓		
12. Neurological	✓		
Physician to comment on any abnormalities :			

Certification	Comment/Reason
Fit for offshore work as per Oil & Gas UK guidelines	✓
Fit for restricted offshore work following discussion with operating company's medical adviser	
Temporarily unfit for offshore work	
Permanently unfit for offshore work	

Physician's signature :  **MP+**
 Print name : **Dr. Frans. D. Martogi**
 Date of examination : **07/02/2019**
PT. KARTIKA BINA MEDIKATAMA

* Source : Medical Aspects of Fitness for Work Offshore Guidance for Examining Physicians Oil & Gas UK, March 2008

Unrestricted Offshore Work Certificate

Medical Certificate of Fitness for Offshore Work

(Issued in accordance with Oil and gas UK Guidelines)

Name :	SYAIFUL
Date of Birth :	03 February 1983
Employing Company Name :	INSPEKTINDO SINERGI PERSADA
Occupation :	INSPECTOR

This individual has been examined in accordance
 with Oil & Gas UK Guidelines and is
Medical Fit for Unrestricted To The Job Described At Offshore Work

Examining Physician Name :	dr. Frans Denis Martogi
Oil & Gas UK PIN No. :	OGUK/2017/2465
Date of Examination :	07 February 2019
Date of Expiry of Certificate :	07 February 2021
Signed :	


MP+
 PT. KARTIKA BINA MEDIKATAMA

TO WHOM IT MAY CONCERN

Kepada yang berkepentingan

This is certify that today Thursday, 07 February 2019 Medika Plaza Clinic has performed urine drug screening and/or breath alcohol test to :


Dengan ini menyatakan bahwa, pada hari ini Kamis, 07 Februari 2019 Medika Plaza Clinic telah melakukan urine drug screening dan/atau breath alcohol test kepada :

SYAIFUL

With the results are as follows :
Dengan hasil sebagai berikut :

Drugs Test <i>Uji Obat</i>	Result <i>Hasil</i>		
URINE DRUGS SCREENING			
- Amphetamine	<input type="checkbox"/> Non-Negative	<input checked="" type="checkbox"/> Negative	<input type="checkbox"/> N/A
- Met-Amphetamine	<input type="checkbox"/> Non-Negative	<input checked="" type="checkbox"/> Negative	<input type="checkbox"/> N/A
- Cocain	<input type="checkbox"/> Non-Negative	<input checked="" type="checkbox"/> Negative	<input type="checkbox"/> N/A
- THC/Canabis/Marijuana	<input type="checkbox"/> Non-Negative	<input checked="" type="checkbox"/> Negative	<input type="checkbox"/> N/A
- Morphine/Opiates	<input type="checkbox"/> Non-Negative	<input checked="" type="checkbox"/> Negative	<input type="checkbox"/> N/A
- P C P/Phencyclidine	<input type="checkbox"/> Non-Negative	<input type="checkbox"/> Negative	<input checked="" type="checkbox"/> N/A
- Barbiturate	<input type="checkbox"/> Non-Negative	<input type="checkbox"/> Negative	<input checked="" type="checkbox"/> N/A
- Benzodiazepin	<input type="checkbox"/> Non-Negative	<input checked="" type="checkbox"/> Negative	<input type="checkbox"/> N/A
- Methadone	<input type="checkbox"/> Non-Negative	<input checked="" type="checkbox"/> Negative	<input type="checkbox"/> N/A
- Propoxyphene	<input type="checkbox"/> Non-Negative	<input type="checkbox"/> Negative	<input checked="" type="checkbox"/> N/A
- Oxycodone	<input type="checkbox"/> Non-Negative	<input type="checkbox"/> Negative	<input checked="" type="checkbox"/> N/A
- MDMA	<input type="checkbox"/> Non-Negative	<input type="checkbox"/> Negative	<input checked="" type="checkbox"/> N/A
- 6-MAM	<input type="checkbox"/> Non-Negative	<input type="checkbox"/> Negative	<input checked="" type="checkbox"/> N/A
BREATH ALCOHOL TEST			
- Alcohol	<input type="checkbox"/> Non-Negative	<input checked="" type="checkbox"/> Negative	<input type="checkbox"/> N/A

Jakarta, February 07, 2019


 (dr. Esther Poerwanto, Sp.PK)
 Clinical Patologist

HEALTH ASSESSMENT REPORT

Of

SYAIFUL
01031455

Thursday, 07 February 2019

MP BELTWAY CLINIC

Beltway Office Park, Annex Building, Ground Floor

Jl. TB. Simatupang Kav.41, Jakarta Selatan 12550

Tlp : (62-21) 808 66 099, Fax : (62-21) 808 66 098

www.medikaplaza.com

MP BELTWAY CLINIC

Beltway Office Park, Annex Building, Ground Floor
Jl. TB. Simatupang Kav.41, Jakarta Selatan 12550
Tlp : (62-21) 808 66 099, Fax : (62-21) 808 66 098
www.medikaplaaza.com

PATIENT DATA

MedRec.	: 01031455	EMPLOY. STATUS	: Employee
NAME	: SYAIFUL	BIRTHDATE	: 03 February 1983
EMPLOYEE No.	: -	SEX	: Male
JOB TITLE	: INSPECTOR	STATUS	: Married
COMP. NAME	: INSPEKTINDO SINERGI PERSADA	NASIONALITY	: Indonesia

SUMMARY

MEDICAL FINDING :

1. Leucocytosis
 2. Hypertriglyceridemia (has been prescribed medication)
 3. Decayed, radix, missing, calculus teeth
 4. Decreasing of visual acuity of both eyes
- Your fitness status is fit for unrestricted to the job described at offshore work.

SUGGESTION :

1. Repeat Leucocyt examination after 1 month
2. Low fat and carbohydrate diet, exercise regularly minimal 3 times a week.
3. See a dentist for dental care, minimal once a year or better once in six month
4. You need to wear the glasses for distant vision

Responsible Doctor


Restu Natasya Fachrini, MD

Notes:

If you need the further information or consultation, please contact us via :

Email : - beltway.doctor@medikaplaaza.com
- beltway.doctor2@medikaplaaza.com

Telepon Klinik : (62-21) 8086 6000

PRIVATE

Printed by : reysti

CLINICAL EVALUATION

Name : SYAIFUL

Sex : Male

MR : 01031455

Visit : 07/02/2019

Comp. : INSPEKTINDO SINERGI PERSADA

DOB : 03 February 1983

EXAMINATION

RESULT

NOTES

ANAMNESA

PRESENT COMPLAINT AND HISTORY OF PRESENT ILLNESS

Present complaint

No complain

MEDICAL HISTORY

Alergy	No
Imunisasi	Yes
Surgery	No
Hospitalization	No
Disease	No

LIFE STYLE

Alcohol intake	No	
Smoking	Yes	Moderate smoker
Exercise	Yes	Badminton and futsal 2x/week

FAMILY MEDICAL HISTORY

Diabetes Melitus	No
Hypertension	No
Heart disease	No
Lung TB	No
Kidney disease	No
Astma	No
Mental disease	No
Epilepsy	No
Cancer	No
Color blind	No
Stroke	No
Liver disease	No
Bone & joint	No
Others disease	No

WORK EXPOSURE

Noise	No
Heat Stress	No
Cold Stress	No
Vibration	No
Involving height	No
Radiation	No
Dust	No

Verified by : dr. Puteri Melati

PRIVATE

Printed by : reysti

CLINICAL EVALUATION

Name : SYAIFUL

Sex : Male

MR : 01031455

Visit : 07/02/2019

Comp. : INSPEKTINDO SINERGI PERSADA

DOB : 03 February 1983

EXAMINATION	RESULT	NOTES
Toxic chemical	No	
Irritating fluid	No	
Smoke	No	
Bacterium/Virus/Parasite	No	
Blood	No	
Animal	No	
Operating heavy mobile equipment	No	
Manual Handling	No	
Sitting continuously over 4 hours	No	
Stand continuously over 4 hours	No	
Using monitor screen more than 4 hours per day	No	
Exposure	No	
Unergonomic body positions	No	
Shift work	No	
Work is not accordance with skills and knowledge	No	
Workload does not accordance with time	No	
Work conflict	No	
Inappropriate task	No	
Career barriers	No	
Family conflict	No	
Working arround rotating machinery	No	
Administration work	No	
Handling food product	No	
Others	Yes	Offshore/onshore
PHYSICAL EXAMINATION		
General Appearance	Good	
Body shape	Athleticus	
VITAL SIGN		
Body Weight	68.2 Kg	
Body Height	167 Cm	
BMI	24.45 Kg/m2	
Normal Weight	51.59 - 69.72 Kg	
BMI Conclusion	Normal	
Blood Pressure	110/70 mmHg	
Pulse	64 x/minute	
Body Temperature	36.1 °C	
RR	19	

Verified by : dr.Puteri Melati

PRIVATE

Printed by : reysti

CLINICAL EVALUATION

Name : SYAIFUL	Sex : Male	MR : 01031455	Visit : 07/02/2019
Comp. : INSPEKTINDO SINERGI PERSADA		DOB : 03 February 1983	

EXAMINATION	RESULT	NOTES
Neck Circumference	36 Cm	
Arm Circumference	32 Cm	
Chest size	96 Cm	
Abdominal Circumference	90 Cm	
SKIN		
Skin	Normal	
EYE		
Left	Normal	
Right	Normal	
ENT		
Auricle	Normal	
Ear canal	Normal	
Drums	Normal	
Septum/Conchae	Normal	
Sinuses	Normal	
Pharynx	Normal	
Tonsil	Normal	
MOUTH		
Gum	Normal	
Dental	Abnormal	Decayed, radix, missing, calculus teeth
NECK		
General	Normal	
Thyroid Gland	Normal	
CHEST		
Form	Normal	
Lung	Normal	
Heart	Normal	
Breast	Normal	
ABDOMEN		
Form	Flat	
Palpation	Supple	
Liver	Not Palpable	
Spleen	Not Palpable	
Kidney	No Ballotment	
-	No	
Hernia inguinal	No	
EXTRIMITIES		

CLINICAL EVALUATION

Name : SYAIFUL		Sex : Male	MR : 01031455	Visit : 07/02/2019
Comp. : INSPEKTINDO SINERGI PERSADA		DOB : 03 February 1983		
EXAMINATION	RESULT	NOTES		

Bones, joint	Normal	
Muscles, tonus	Normal	
Fingernails	Normal	
Hand	Normal	
Foot	Normal	
RECTAL EXAMINATION		
Hemorrhoid	Negative	
Rectum	Normal	
SENSORIK EXAMINATION		
Tes Raba	Normal	
MOTORIK EXAMINATION		
Tes Grip	Normal	
REFLEX EXAMINATION		
Physiologic reflex	Normal	
Patologic reflex	Normal	
OTHERS EXAMINATION		
Coordination	Normal	
LIMPHE SYSTEM		
Submandibula	Normal	
Neck Gland	Normal	
Armpit gland	Normal	
Inguinal	Normal	

OPHTHALMOLOGY DIAGNOSTIC

Name : SYAIFUL	Sex : Male	MR : 01031455	Visit : 07/02/2019
Comp.: INSPEKTINDO SINERGI PERSADA		DOB : 03 February 1983	

EXAMINATION		Right	Left
Reading		-	-
Previous Glasses		-	-
Without Glasses	Distant	20/50	20/30
	Near	J1	J1
Correction	Distant	-	-
	Near	-	-
Depth Perception		-	-
Tonometry		-	-
Funduscopy		-	-
Visual Fields		-	-
Colour Blind Test		Normal	

Impression : Decreasing of visual acuity of both eyes

RADIOLOGY DIAGNOSTIC

Name : SYAIFUL

Sex : Male

MR : 01031455

Visit : 07/02/2019

Comp.: INSPEKTINDO SINERGI PERSADA

DOB : 03 February 1983

EXAMINATION

RESULT

THORAX PA

No abnormality seen in both lungs.
Normal bronchovascular markings in both hili.
The heart is normal in size and shape.
The mediastinum is not widened.
Both sinus and diaphragms are good.
No evidence of pleural effusion.

Impression

Normal chest.
No evidence of specific process in both lungs.

LAB NO: 19003010

Nama :

Umur :

Alamat :



SYAIFUL
01031456-L
03-02-83

INSPEKTINDO SINERGI PERSADA

GOL DARAH

A

+ / Pos

Rh



anti : A



anti : B



anti : AB



anti : Rh

LABORATORY RESULT

Name : SYAIFUL	MR : 01031455	Visit : 07/02/2019	#Lab : IN658127033834
Comp. : INSPEKTINDO SINERGI PERSADA	Sex : Male	DOB : 03 February 1983	
EXAMINATION	RESULT	NORMAL RANGE	

HEMATOLOGI

ABO/Rh Typing "A" Rh(+) positive

Automated Blood Count

White Blood Cell (WBC)	11.5 *	3.8 - 11.0
Erythrocyte (RBC)	5.7	4.4 - 5.9
Haemoglobin	16.7	13.2 - 17.3
Hematocrit	50	40 - 52
Thrombocytes	346	150 - 440

MCV, MCH, MCHC

MCV	88	80 - 100
MCH	29	26 - 34
MCHC	33.5	32 - 36
ESR	10	0 - 10

Differential Count

Basophils	0	0 - 1
Eosinophil	2	2 - 4
Bands / Stab	2 *	3 - 5
Neutrophils	45 *	50 - 70
Lymphocytes	42 *	25 - 40
Monocytes	9 *	2 - 8

BLD CHEMISTRY/LIPID PROFILE

Total Cholesterol	187	Normal/Desireable: <200 Borderline High: 200-239 High: >=240
HDL Cholesterol	41.4	Normal : >40 - <60 Low HDL : <40 Desireable : >=60
LDL Cholesterol	99	Optimal: <100 Near/Above Optimal: 100-129 Borderline High: 130-159 High: 160-189 Very High: >=190
Tryglicerides	232 *	Normal : <150 Borderline High: 150-199 High : 200-499 Very High : >=500

BLD CHEMISTRY/KIDNEY FUNCTION

LABORATORY RESULT

Name : SYAIFUL	MR : 01031455	Visit : 07/02/2019	#Lab : IN658127033834
Comp. : INSPEKTINDO SINERGI PERSADA	Sex : Male	DOB : 03 February 1983	

EXAMINATION	RESULT	NORMAL RANGE
Ureum	10.0	10.0 - 50.0
Creatinine	0.8	0.6- 1.3
Uric Acid	6.2	3.5 - 7.2

BLD CHEMISTRY/LIVER FUNCTION

SGOT(AST)	22	13 - 45
SGPT (ALT)	25	13 - 50
Alkaline Phosphatase	74	30 - 120
Gamma GT	18	0 - 50

BLD CHEMISTRY/DIABETES

Glucose Fasting	100 *	< 100
Glucose Urine	Negative	Negative
Keton Urine	Negative	Negative

Blood Glucose 2 PP

Blood Sugar 2 Hours PP	94	< 140
Glucose Urine	Negative	Negative
Keton Urine	Negative	Negative

TOXICOLOGY - DRUGS SCREENING

Methadone	Negative	Negative
THC/Marijuana	Negative	Negative
Amphetamine	Negative	Negative
Benzodiazepines	Negative	Negative
Opiat	Negative	Negative
Cocain	Negative	Negative
Metamphetamine	Negative	Negative
Alcohol	Negative	Negative

URINALYSIS**Complete Urine Analysis****Macroscopic**

Color	Colorless	
Turbidity	Clear	Clear
Specific Gravity	1.009	1.000 - 1.030
pH	5.5	4.5 - 8.0
Leucocyte	Negative	Negative
Glucose	Negative	Negative
Nitrit	Negative	Negative
Bilirubin	Negative	Negative
Blood	Negative	Negative

LABORATORY RESULT

Name : SYAIFUL	MR : 01031455	Visit : 07/02/2019	#Lab : IN658127033834
Comp. : INSPEKTINDO SINERGI PERSADA	Sex : Male	DOB : 03 February 1983	

EXAMINATION	RESULT	NORMAL RANGE
Urobilinogen	Normal	Normal
Protein	Negative	Negative
Keton	Negative	Negative
Microscopic		
RBC	0-1	0 - 1
WBC	0-1	0 - 4
Cylinder	Negative	
Epithels Squamous	0-1	5 - 15
Crystals	Negative	
Bacteria	Negative	Negative
Others	Negative	

STOOL / RECTAL SWAP

Faeces Complete

Macroscopic

Color	Brown	
Consistency	Smooth	
Mucus	Negative	Negative
Blood	Negative	Negative
Pus	Negative	Negative
Parasitologi Faeces	Negative	Negative
Lipid	Negative	Negative

Microscopic

RBC	0-1	0 - 1
WBC	0-2	0 - 5
Amoeba	Negative	
Ephitels	Positive	Positive
Worm Eggs	Negative	Negative
Yeast	Negative	Negative
Muscle Fiber	Negative	Negative
Others	Negative	Negative

Digestive

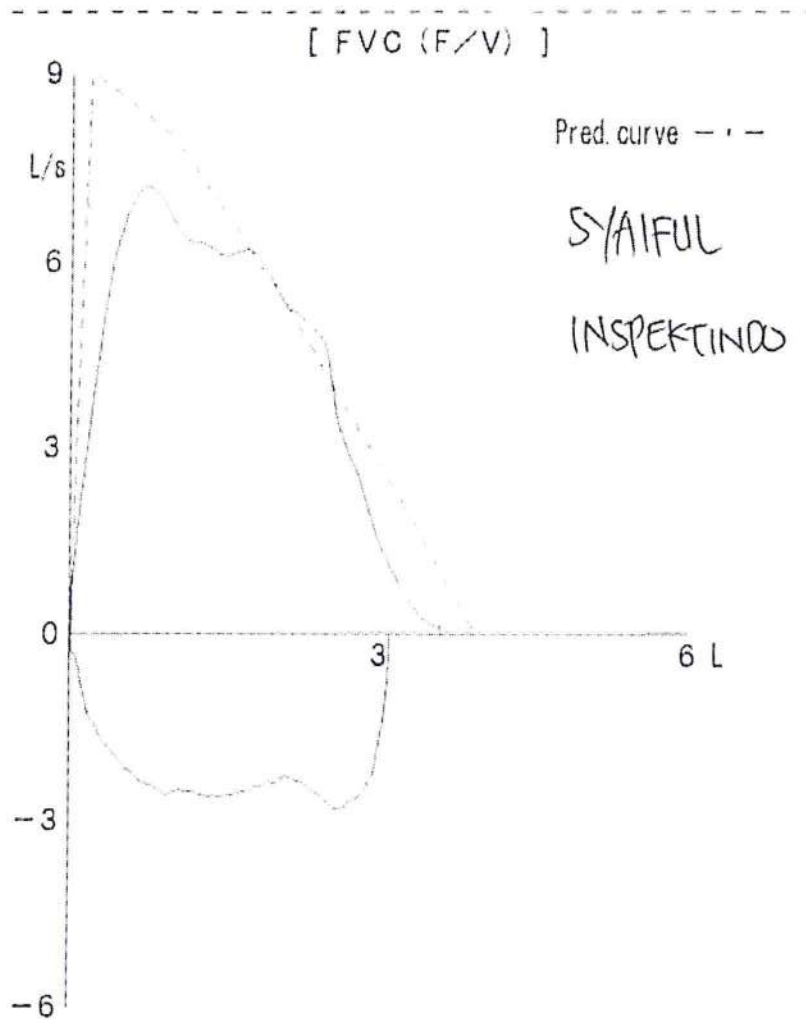
Amylum	Negative	Negative
Fat	Negative	
Fibers	Positive	Positive

SPIROMETRY DIAGNOSTIC

Name : SYAIFUL	Sex : Male	MR : 01031455	Visit : 07/02/2019
Comp. : INSPEKTINDO SINERGI PERSADA		DOB : 03 February 1983	

EXAMINATION	RESULT
FVC Result	: 3.62 L---> 91.9 %
FEV1 Result	: 3.32 L---> 93.3 %
FEV1/FVC Result	: 91.71 %---> 117.0 %
PEF Result	: 7.18 L/S---> 68.9 %
Indonesian Standart Result	:
Index	:
Spirometry Result	: Normal

Impression : Normal Spirometric Functions



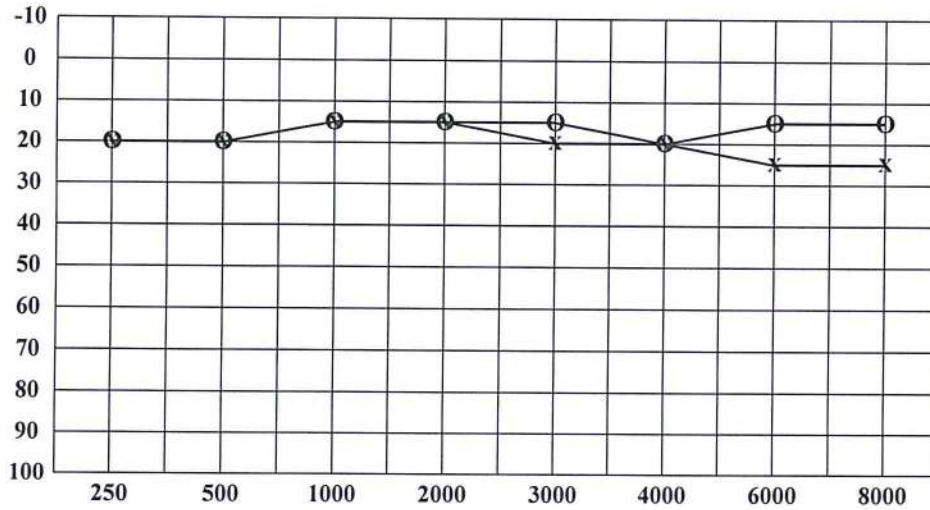
AUDIOMETRY DIAGNOSTIC

Name : SYAIFUL	Sex : Male	MR : 01031455	Visit : 07/02/2019
Comp.: INSPEKTINDO SINERGI PERSADA		DOB : 03 February 1983	

RESULT

Left Ear	250	500	1000	2000	3000	4000	6000	8000
AC	20	20	15	15	20	20	25	25
BC	-	-	-	-	-	-	-	-

Right Ear	250	500	1000	2000	3000	4000	6000	8000
AC	20	20	15	15	15	20	15	15
BC	-	-	-	-	-	-	-	-



< : Right Ear (BC)

> : Left Ear (BC)

O : Right Ear (AC)

X : Left Ear (AC)

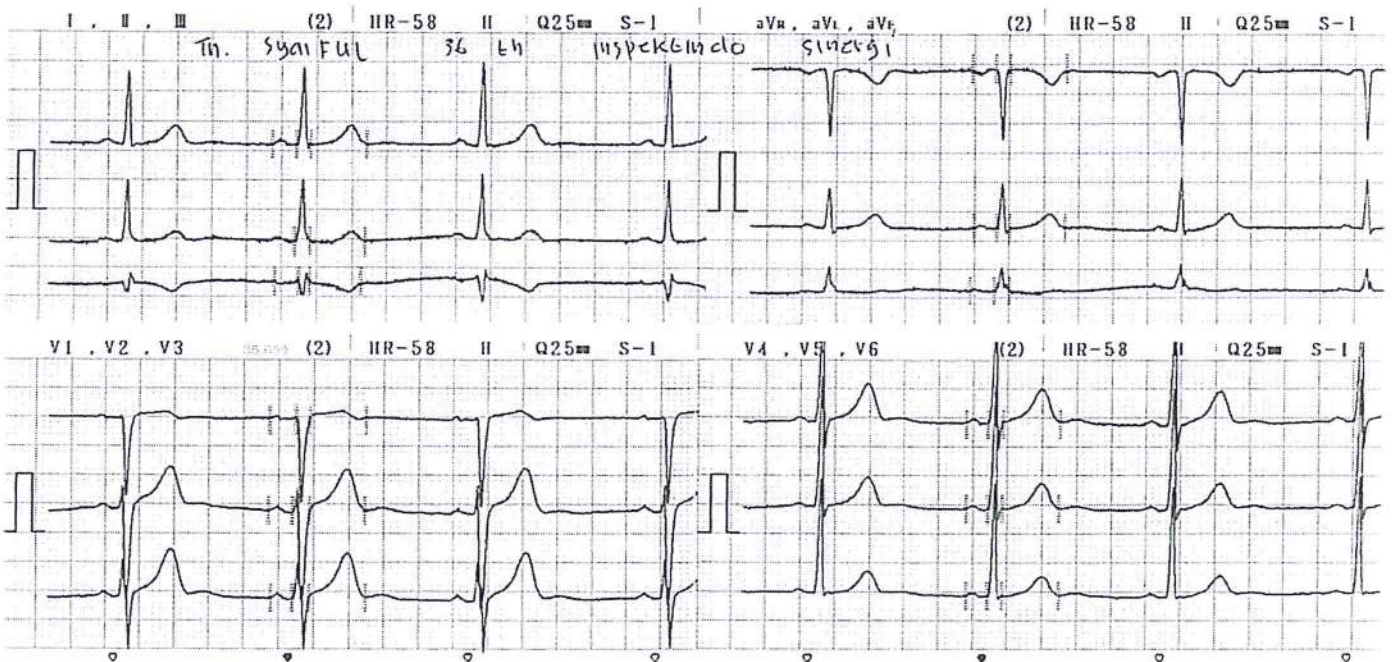
Conclusion Right Ear : Hearing threshold = 17.5 dB
(Within normal limit)

Conclusion Left Ear : Hearing threshold = 17.5 dB
(Within normal limit)

CARDIOLOGY DIAGNOSTIC

Name : SYAIFUL	Sex : Male	MR : 01031455	Visit : 07/02/2019
Comp.: INSPEKTINDO SINERGI PERSADA		DOB : 03 February 1983	

EXAMINATION	RESULT	Comments :
ELECTROCARDIOGRAPHY	Sinus Rythm axis (N), P wave (N), PR int 0.16" ST - T segment (N), aritmia (-)	Normal ECG
TREADMILL	Sinus Rythm axis (N), P wave (N), PR int 0.16" ST - T segment (N), aritmia (-)	Treadmill Exercise Test : Negative Cardiopulmonary Fitness Classification : Good METs : 10.5

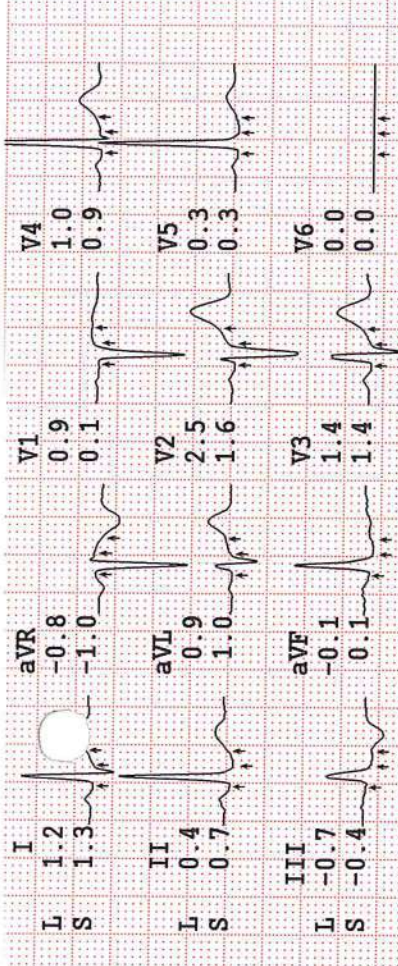


NAME: IN. SIAIFUL
ID: INSPEKTINDO

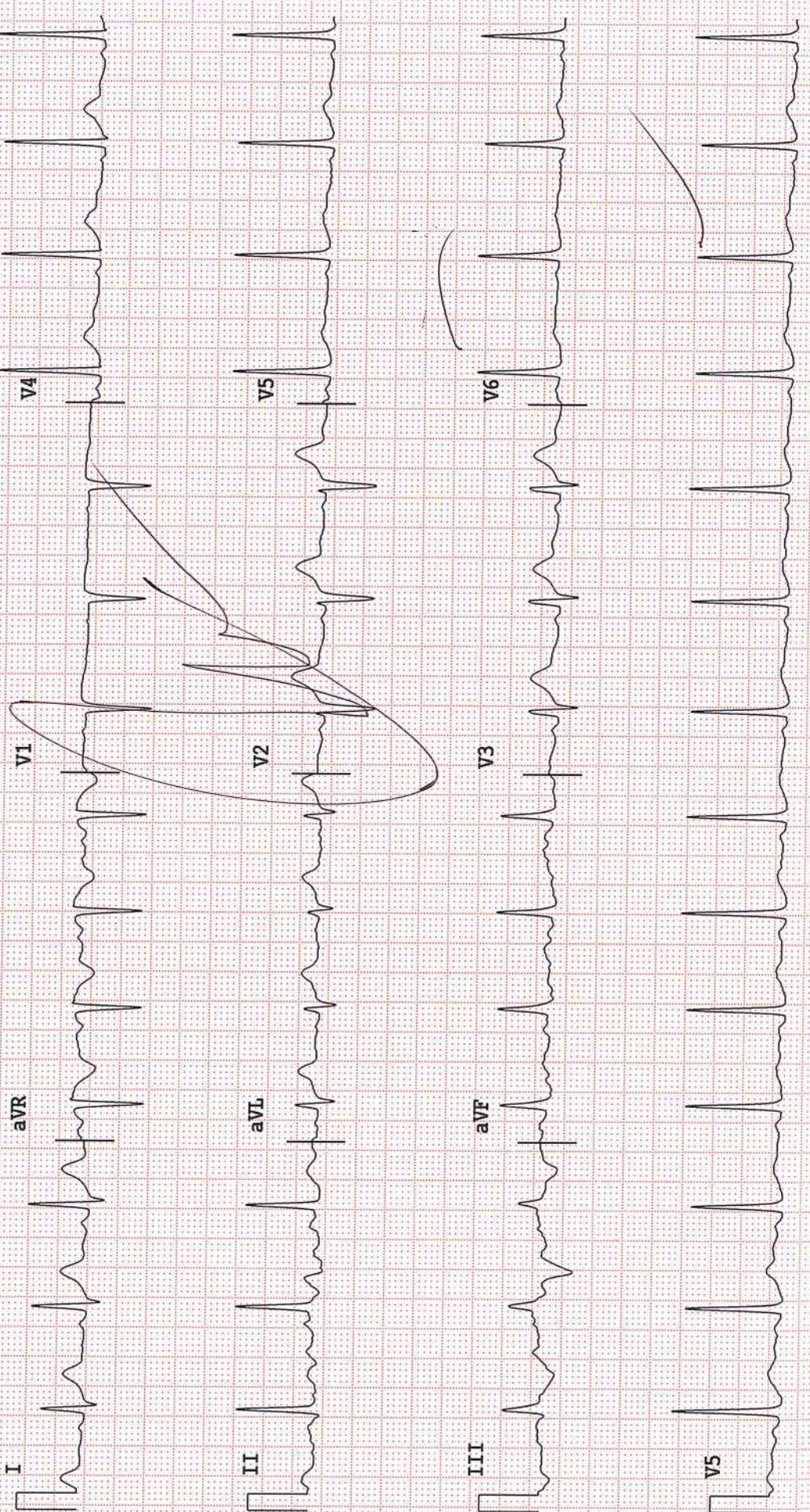
2/7/201 09:02:28

HR: 82
BP: 110/70
Age: 36 Years
Gender: Male
Race: Oriental
Height: 167 cm
Weight: 68 Kg
Medication(s): No Medication
Clin. Class: No Medication
Class: Normal
Department: MEDIKA PLAZA
Technician: Mr. Jesika
Physician: Dr. Adolf DSJP

Baseline ECG



Levels measured at 80ms Post-J Levels in mm Slope in uV/mS



Worst Case S-T Depression

Name: TN. SYAIFUL
 ID: INSPEKTINDO
 2/7/201 9:05:25

HR: 91
 BP: 110/70
 RPE: 4.5
 METs: 4.5

Phase: Exercise
 Exercise Time: 02:50
 Stage/Time: 1/02:50
 Workload: 2.7 kmh 9.9 % grade
 Protocol: Bruce

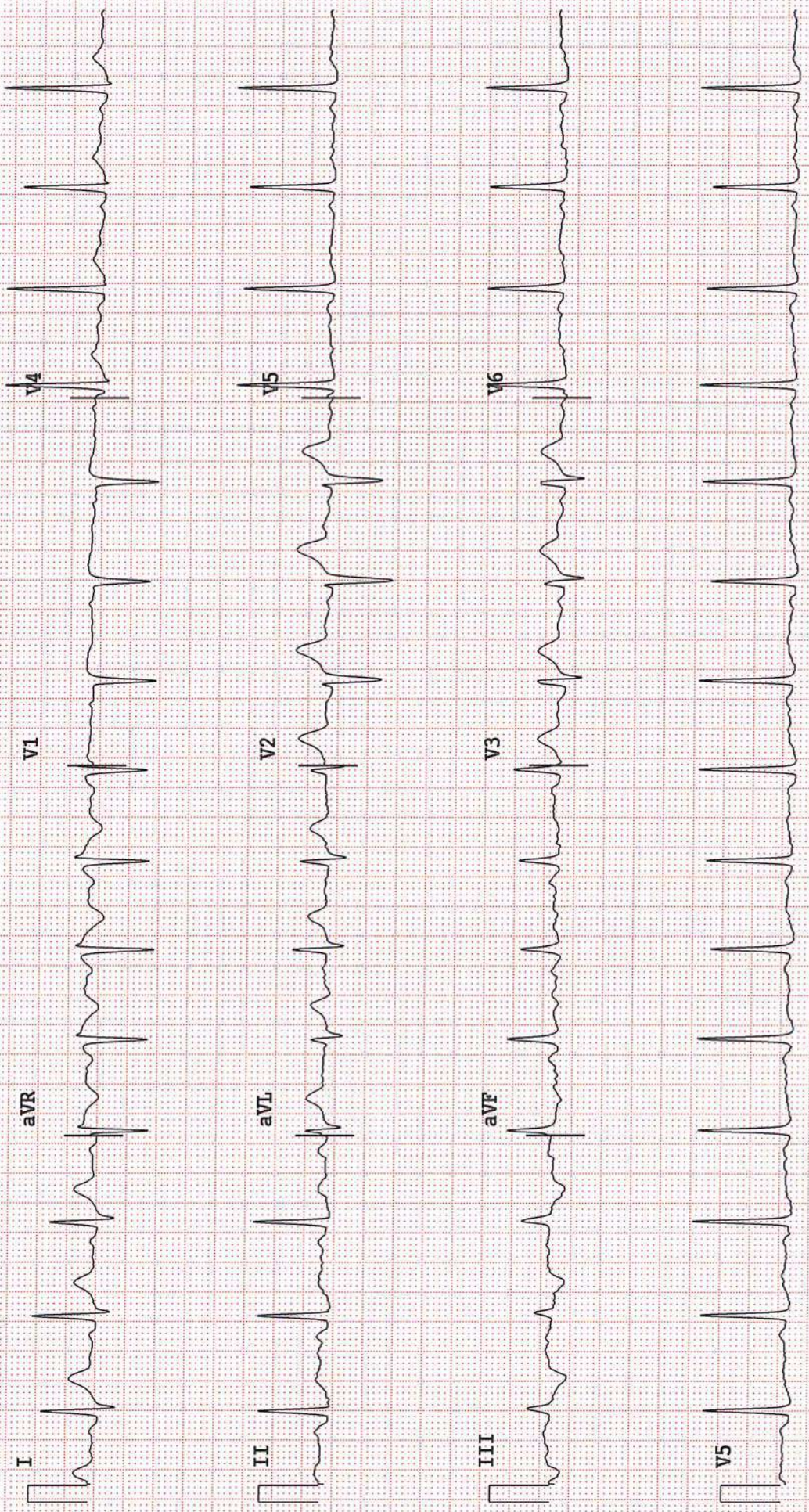
Current

Baseline



III
 L -0.4
 S -0.4
 J+80ms

III
 L -0.7
 S -0.4
 J+80ms



Worst Case S-T Depression

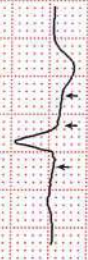2/7/201 9:08:25

Name: TN. SYAIFUL
ID: INSPEKINDO

HR: 103
BP: 120/80
RPE: 6.8
METs: 6.8
Phase: Exercise
Exercise Time: 05:50
Stage/Time: 2/02:50
Workload: 4.0 kmh 12.0 % grade
Protocol: Bruce

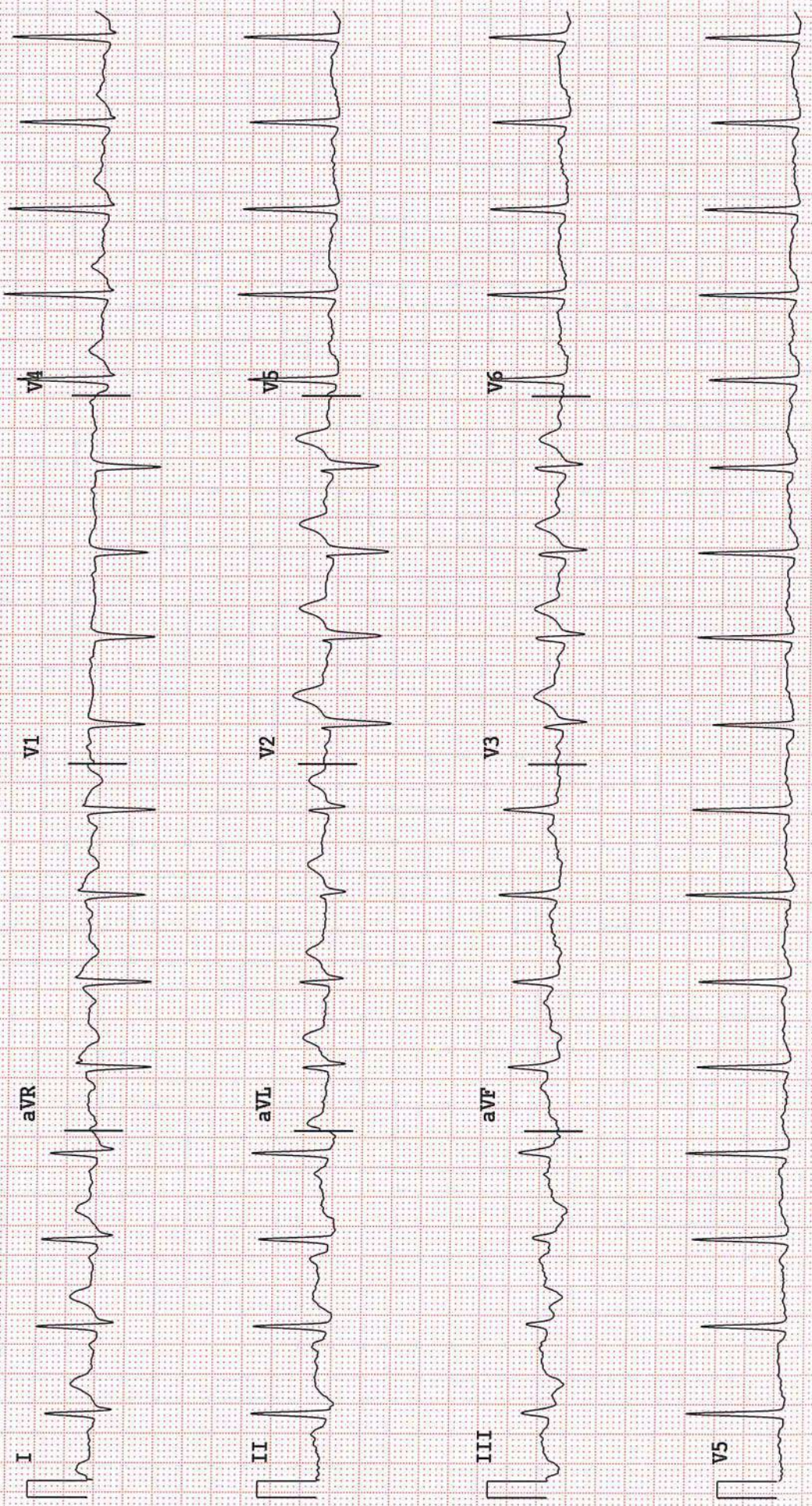
Current

Baseline



III -1.1
L -0.7
S -0.4
J+80ms

III -0.7
L -0.4
S -0.4
J+80ms



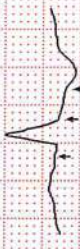Worst Case S-T Depression

Name: TN. SYAIFUL
ID: INSPKTINGDO

2/7/20 19:11:25

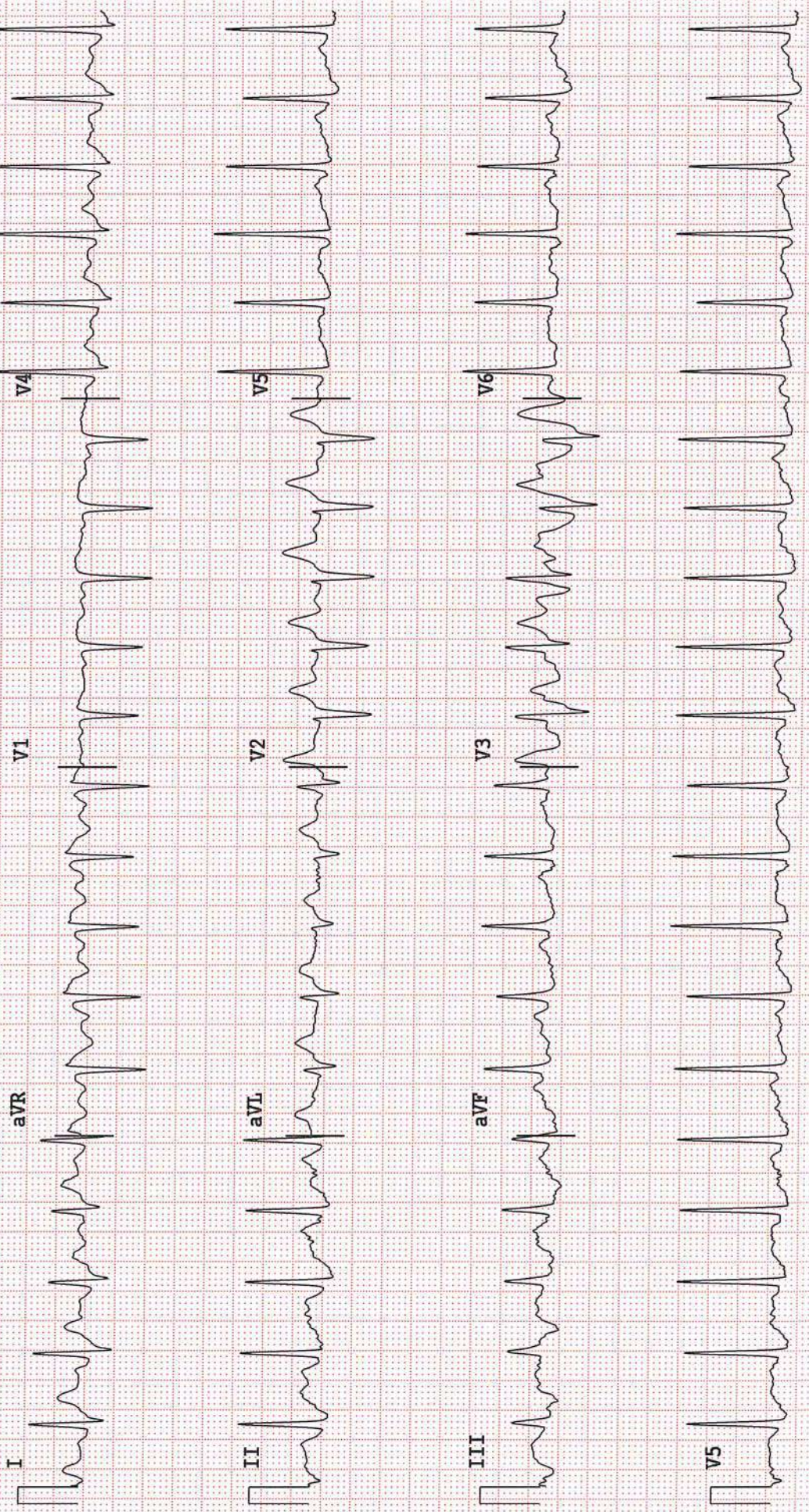
HR: 123
BP: 140/90
RPE: 10.0
METs: 10.0
Phase: Exercise
Exercise Time: 08:50
Stage/Time: 3/02:50
Workload: 5.4 kmh 13.9 % grade
Protocol: Bruce

Baseline
Current



III
L -0.7
S -0.4
J+80ms

III
L -1.5
S -1.2
J+80ms



Name: JN. SYALFUL
 ID: INSPEKTINDO
 HR: 135
 BP:
 RPE:
 METs: 10.4
 Protocol: Bruce

2/7/20 09:11:48
 Maximum Exercise
 Exercise Time: 09:13
 Stage/Time: 4/00:13
 Workload: 6.7 kmh 15.9 % grade

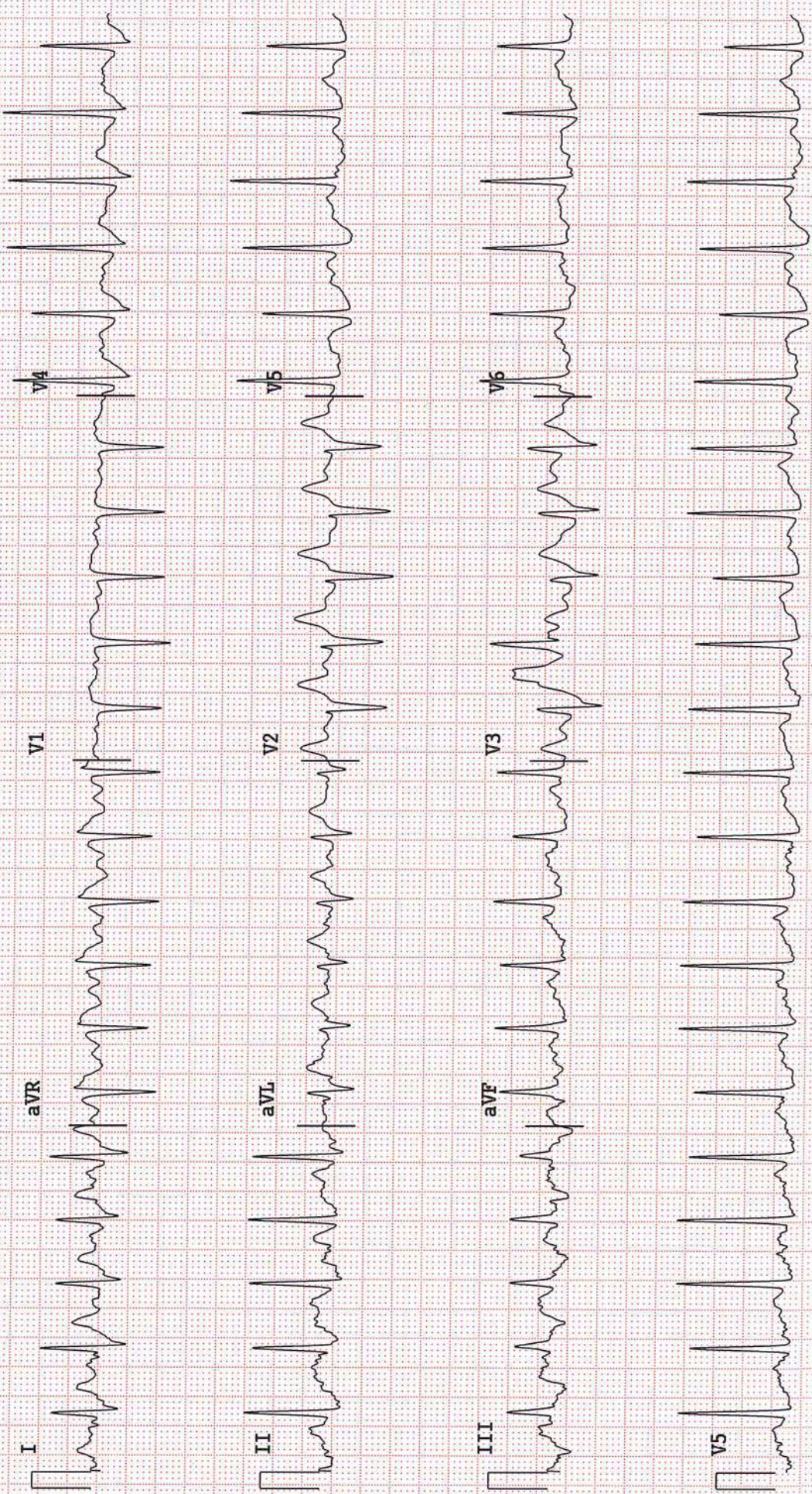
Worst Case S-T Depression
 Baseline
 Current



III
 I -0.7
 S -0.4
 J+80ms

III
 I -1.6
 S -0.8
 J+80ms

MAXIMUM EXERCISE ECG



Medication(s): No Medication
 : No Medication
 Medication(s): No Medication
 : No Medication
 Normal
 Normal
 MEDIKA PLAZA
 Nr. Jesika
 Dr. Adolf DSJP

Age: 36 Years
 Gender: Male
 Race: Oriental
 Height: 167 cm
 Weight: 68 Kg

Protocol: Bruce
 TIME PHASE KMH GRADE HR BP RPP METS ECTOPIC RPE EVENTS COMMENTS
 00:00 Exercise 0.8 0.0 72 110/70 101 4.5 5.5
 01:00 Exercise 2.7 9.9 90 120/80 123 6.8 8.5
 02:00 Exercise 2.7 9.9 90 140/90 180 10.0
 03:00 Exercise 2.7 9.9 92 135 10.4
 04:00 Exercise 4.0 12.0 95 9.0
 05:00 Exercise 4.0 12.0 102
 06:00 Exercise 4.0 12.0 103
 07:00 Exercise 5.4 13.9 119
 08:00 Exercise 5.4 13.9 128
 09:00 Exercise 5.4 13.9 129
 09:13 Max Exer. 6.7 15.9 135
 00:24 Recovery 2.0 0.0 120

S-T SEGMENT ANALYSIS:
 - Lead III first exhibit depression exceeding 03:30 of Exercise.
 - ST depression exceeded 03:30 mins.
 - 2.1mm maximum depress was exhibited at 00:1 Recovery.

SUMMARY:
 - The Bruce test was for 09:13 mins. Peak METs was 10.5.
 - A peak heart rate of 134 bpm was achieved at 09:12 mins in exercise.
 - 73% of the 184 bpm max was reached.
 - The peak BP was 140/90 (during Exercise). Baseline was 110/70.

[Handwritten Signature]
[Handwritten Signature]

MP
 PT. KARTIKA BINA MEDIKATAMA