

Certificate Of Health Assessment



Name	Age	Position	Department
SYAIFUL	37 yo	INSPECTOR	-

COMPANY :

INSPEKTINDO SINERGI PERSADA, PT

CONCLUSION

FIT TO WORK	
FIT WITH MEDICAL NOTE	✓
TEMPORARY UNFIT	
UNFIT	

Issued Date	Doctors Name	Prepared By
29 January 2021	Puteri Melati, MD PKTK : KEP.264/BINWASK3-PNK3/KK/VI/2019 SIP : 23/B.15a/31.74.04.1004/-1.779.3/e/2019	
Expired Date		Verified By
29 January 2022	dr. Muhammad Ilyas, Sp.Ok SIP : 29/B.15b/31.74.04.1004.02.009.K.1/3/-1.779.3/e/2019	 PT. KARTIKA BINA MEDIKATAMA

No. Formulir : FM-DR-008-05
 No. Revisi : 00
 Tanggal Terbit : 2 Mei 2011

Certificate Number : MP-BOP/1-20210129/127664
 MCU Validity Check
<https://mcu-validasi.medikapla.com>

PT. KARTIKA BINA MEDIKATAMA

TO WHOM IT MAY CONCERN

Kepada yang berkepentingan

This is certify that today Friday, 29 January 2021 Medika Plaza Clinic has performed urine drug screening and/or breath alcohol test to :

Dengan ini menyatakan bahwa, pada hari ini Jumat, 29 Januari 2021 Medika Plaza Clinic telah melakukan urine drug screening dan/atau breath alcohol test kepada :

SYAIFUL

With the results are as follows :
Dengan hasil sebagai berikut :

<u>Drugs Test</u> <i>Uji Obat</i>	<u>Result</u> <i>Hasil</i>		
URINE DRUGS SCREENING			
- Amphetamine	<input type="checkbox"/> Non-Negative	<input checked="" type="checkbox"/> Negative	<input type="checkbox"/> N/A
- Met-Amphetamine	<input type="checkbox"/> Non-Negative	<input checked="" type="checkbox"/> Negative	<input type="checkbox"/> N/A
- Cocain	<input type="checkbox"/> Non-Negative	<input checked="" type="checkbox"/> Negative	<input type="checkbox"/> N/A
- THC/Canabis/Marijuana	<input type="checkbox"/> Non-Negative	<input checked="" type="checkbox"/> Negative	<input type="checkbox"/> N/A
- Morphine/Opiates	<input type="checkbox"/> Non-Negative	<input checked="" type="checkbox"/> Negative	<input type="checkbox"/> N/A
- P C P/Phencyclidine	<input type="checkbox"/> Non-Negative	<input checked="" type="checkbox"/> Negative	<input type="checkbox"/> N/A
- Barbiturate	<input type="checkbox"/> Non-Negative	<input type="checkbox"/> Negative	<input checked="" type="checkbox"/> N/A
- Benzodiazepin	<input type="checkbox"/> Non-Negative	<input checked="" type="checkbox"/> Negative	<input type="checkbox"/> N/A
- Methadone	<input type="checkbox"/> Non-Negative	<input checked="" type="checkbox"/> Negative	<input type="checkbox"/> N/A
- Propoxyphene	<input type="checkbox"/> Non-Negative	<input type="checkbox"/> Negative	<input checked="" type="checkbox"/> N/A
- Oxycodone	<input type="checkbox"/> Non-Negative	<input type="checkbox"/> Negative	<input checked="" type="checkbox"/> N/A
- MDMA	<input type="checkbox"/> Non-Negative	<input type="checkbox"/> Negative	<input checked="" type="checkbox"/> N/A
- 6-MAM	<input type="checkbox"/> Non-Negative	<input type="checkbox"/> Negative	<input checked="" type="checkbox"/> N/A
BREATH ALCOHOL TEST			
- Alcohol	<input type="checkbox"/> Non-Negative	<input checked="" type="checkbox"/> Negative	<input type="checkbox"/> N/A

Jakarta, January 29, 2021



PT. KARTIKA BINA MEDIKATAMA
(dr. Dian Wahyu Tanjungsari, Sp.PK)
Clinical Patologist

HEALTH ASSESSMENT REPORT

Of

SYAIFUL
01031455

Friday, 29 January 2021

MP BELTWAY CLINIC

Beltway Office Park, Annex Building, Ground Floor

Jl. TB. Simatupang Kav.41, Jakarta Selatan 12550

Tlp : (62-21) 808 66 099, Fax : (62-21) 808 66 098

www.medikaplaza.com

MP BELTWAY CLINIC

Beltway Office Park, Annex Building, Ground Floor
Jl. TB. Simatupang Kav.41, Jakarta Selatan 12550
Tlp : (62-21) 808 66 099, Fax : (62-21) 808 66 098
www.medikaplaza.com

PATIENT DATA

MedRec.	: 01031455	EMPLOY. STATUS	: Employee
NAME	: SYAIFUL	BIRTHDATE	: 03 February 1983
EMPLOYEE No.	: -	SEX	: Male
JOB TITLE	: INSPECTOR	STATUS	: Married
COMP. NAME	: INSPEKTINDO SINERGI PERSADA, PT	NASIONALITY	: Indonesia

SUMMARY

MEDICAL FINDING :

1. Leukocytosis
2. Hypertriglyceridemia
3. Hyperuricemia
4. Non reactive Anti Hbs
5. Overweight
6. Calculus, radix, gangren pulpa, missing, and decayed teeth
7. USG abdomen : Mild fatty liver, Multiple intraluminal cholelithiasis (2-4 mm) indiameter
8. Decreasing of hearing acuity on high frequency of left ear

PERCEPTIONS OF EXPOSURE BY WORKERS :

Your fitness status is fit with medical note:

USG abdomen : Mild fatty liver, Multiple intraluminal cholelithiasis (2-4 mm) indiameter

SUGGESTION :

1. Repeat Leukocyt examination after 1 month and consultation with an Internist if still increase
2. Low fat and carbohydrate diet, exercise regularly minimal 3 times a week.
3. Low purine diet such as meats including organ meats, alcoholic beverages, beans, shrimp, scallops, some vegetables in limited amount such as:spinach, cauliflower, asparagus and mushroom
4. Need to get Hepatitis B vaccination (booster)
5. Reduce body weight gradually 0.5 Kgs/week, by doing regular exercise (aerobic/jogging), 3-4x/week, 30-45 minutes and reduce high calorie diet until maximal body weight is 69.72Kgs (present body weight is 70Kgs). Consultation with a Nutritionist for evaluation of overweight
6. Consultation with a Dentist for dental care, minimal once a year or better once in six month
7. Consultation with an Internist for further evaluation of USG abdomen : Mild fatty liver, Multiple intraluminal cholelithiasis (2-4 mm) indiameter
8. Avoid noisy environment and use earplug properly while working at noisy work environment to prevent further hearing impairment

Responsible Doctor



Puteri Melati, MD

Notes:

If you need the further information or consultation, please contact us via :

Email : - beltway.doctor@medikaplaza.com
- beltway.doctor2@medikaplaza.com

Telepon Klinik : (62-21) 8086 6000

CLINICAL EVALUATION

Name : SYAIFUL	Sex : Male	MR : 01031455	Visit : 29/01/2021
Comp. : INSPEKTINDO SINERGI PERSADA, PT		DOB : 03 February 1983	
EXAMINATION	RESULT	NOTES	

ANAMNESA**PRESENT COMPLAINT AND HISTORY OF PRESENT****ILLNESS**

Present complaint

No complaint

MEDICAL HISTORY

Allergy	No
Imunisasi	No
Surgery	No
Hospitalization	No
Disease	No

LIFE STYLE

Alcohol intake	No	
Smoking	Yes	Heavy smoker
Exercise	No	

FAMILY MEDICAL HISTORY

Diabetes Melitus	No
Hypertension	No
Heart disease	No
Lung TB	No
Kidney disease	No
Astma	No
Mental disease	No
Epilepsy	No
Cancer	No
Color blind	No
Stroke	No
Liver disease	No
Bone & joint	No
Others disease	No

WORK EXPOSURE

Noise	No
Heat Stress	No
Cold Stress	No
Vibration	No
Involving height	No
Radiation	No
Dust	No

CLINICAL EVALUATION

Name : SYAIFUL	Sex : Male	MR : 01031455	Visit : 29/01/2021
Comp. : INSPEKTINDO SINERGI PERSADA, PT		DOB : 03 February 1983	

EXAMINATION	RESULT	NOTES
Toxic chemical	No	
Irritating fluid	No	
Smoke	No	
Bacterium/Virus/Parasite	No	
Blood	No	
Animal	No	
Operating heavy mobile equipment	No	
Manual Handling	No	
Sitting continuously over 4 hours	No	
Stand continuously over 4 hours	No	
Using monitor screen more than 4 hours per day	No	
Exposure	No	
Unergonomic body positions	No	
Shift work	No	
Work is not accordance with skills and knowledge	No	
Workload does not accordance with time	No	
Work conflict	No	
Inappropriate task	No	
Career barriers	No	
Family conflict	No	
Working arround rotating machinery	No	
Administration work	No	
Handling food product	No	
Others	No	
PHYSICAL EXAMINATION		
General Apppearance	Good	
Body shape	Picnicus	
VITAL SIGN		
Body Weight	70 Kg	
Body Height	167 Cm	
BMI	25.1 Kg/m ²	
Normal Weight	51.59 - 69.72 Kg	
BMI Conclusion	Overweight	
Blood Pressure	120/80 mmHg	
Pulse	66 x/minute	
Body Temperature	36.4 °C	
RR	22	

CLINICAL EVALUATION

Name : SYAIFUL	Sex : Male	MR : 01031455	Visit : 29/01/2021
Comp. : INSPEKTINDO SINERGI PERSADA, PT		DOB : 03 February 1983	

EXAMINATION	RESULT	NOTES
Neck Circumference	36 Cm	
Arm Circumference	33 Cm	
Chest size	96 Cm	
Abdominal Circumference	93 Cm	
SKIN		
Skin	Normal	
EYE		
Left	Normal	
Right	Normal	
ENT		
Auricle	Normal	
Ear canal	Normal	
Drums	Normal	
Septum/Conchae	Normal	
Sinuses	Normal	
Pharynx	Normal	
Tonsil	Normal	
MOUTH		
Gum	Normal	
Dental	Normal	Calculus, radix , gangren pulpa, missing, and decayed teeth
NECK		
General	Normal	
Thyroid Gland	Normal	
CHEST		
Form	Normal	
Lung	Normal	
Heart	Normal	
Breast	Normal	
ABDOMEN		
Form	Flat	
Palpation	Supple	
Liver	Not Palpable	
Spleen	Not Palpable	
Kidney	No Ballotment	
-	No	
Hernia inguinal	No	

CLINICAL EVALUATION

Name : SYAIFUL

Sex : Male

MR : 01031455

Visit : 29/01/2021

Comp. : INSPEKTINDO SINERGI PERSADA, PT

DOB : 03 February 1983

EXAMINATION	RESULT	NOTES
EXTRIMITIES		
Bones,joint	Normal	
Muscles,tonus	Normal	
Fingernails	Normal	
Hand	Normal	
Foot	Normal	
RECTAL EXAMINATION		
Hemorrhoid	Negative	
Rectum	Normal	
SENSORIK EXAMINATION		
Tes Raba	Normal	
MOTORIK EXAMINATION		
Tes Grip	Normal	
REFLEX EXAMINATION		
Physiologic reflex	Normal	
Patologic reflex	Normal	
OTHERS EXAMINATION		
Coordination	Normal	
LYMPHE SYSTEM		
Submandibula	Normal	
Neck Gland	Normal	
Armpit gland	Normal	
Inguinal	Normal	

OPHTHALMOLOGY DIAGNOSTIC

Name : SYAIFUL	Sex : Male	MR : 01031455	Visit : 29/01/2021
Comp.: INSPEKTINDO SINERGI PERSADA, PT		DOB : 03 February 1983	

EXAMINATION		Right	Left
Reading		-	
Previous Glasses		-	-
Without Glasses	Distant	20/30	20/30
	Near	J1	J1
Correction	Distant	S-0.75 20/20	S-0.75 20/20
	Near	-	-
Depth Perception		-	
Tonometry		20.0 mmHg	19.0 mmHg
Funduscopy		NORMAL	NORMAL
Visual Fields		Normal	
Colour Blind Test		Normal	

Impression : Myopia simplex ODS

RADIOLOGY DIAGNOSTIC

Name : SYAIFUL	Sex : Male	MR : 01031455	Visit : 29/01/2021
Comp.: INSPEKTINDO SINERGI PERSADA, PT	DOB : 03 February 1983		

EXAMINATION

RESULT

THORAX PA

No abnormality seen in both lungs.
Normal bronchovascular markings in both hili.
The heart is normal in size and shape.
The mediastinum is not widened.
Both sinus and diaphragms are good.
No evidence of pleural effusion.

Impression

Normal heart and lungs.

RADIOLOGY DIAGNOSTIC

Name : SYAIFUL

Sex : Male

MR : 01031455

Visit : 29/01/2021

Comp.: INSPEKTINDO SINERGI PERSADA, PT

DOB : 03 February 1983

EXAMINATION

RESULT

USG ABDOMEN

LIVER:

Normal in size and contour, smooth surface, parenchyme echoes structures slight increased. No sign of SOL.

Intrahepatic vascularity and billiary tract are normal.

GALL BLADDER:

Normal in size, multiple intraluminal stones (2-4 mm in diameter).

BOTH KIDNEYS:

Normal in size, contour and surface. No sign of obstruction/ stone/ SOL.

PANCREAS:

Normal in size, contour and surface. No sign of SOL.

LIEN:

Normal in size and contour, the echoes are homogenous. No sign of SOL.

URINARY BLADDER:

Normal in size, contour and surface. No sign of stone/ SOL.

PROSTATE AND VESICULA SEMINALIS:

Normal in size and contour which are homogenous echoes and no sign of focal lesion/ SOL.

Impression

Mild fatty liver.

Multiple intraluminal cholelithiasis (2-4 mm) in diameter.

Other abdominal organs are normal.

LABORATORY RESULT

Name : SYAIFUL	MR : 01031455	Visit : 29/01/2021	#Lab : IN7334280966
Comp. : INSPEKTINDO SINERGI PERSADA, PT	Sex : Male	DOB : 03 February 1983	
EXAMINATION	RESULT	NORMAL RANGE	

HEMATOLOGI

ABO/Rh Typing "A" Rh(+) positive

Automated Blood Count

White Blood Cell (WBC)	11.6 *	3.8 - 11.0
Erythrocyte (RBC)	5.7	4.4 - 5.9
Haemoglobin	16.6	13.2 - 17.3
Hematocrit	48	40 - 52
Thrombocytes	356	150 - 440

MCV, MCH, MCHC

MCV	85	80 - 100
MCH	29	26 - 34
MCHC	34.4	32 - 36
ESR	7	0 - 10

BLD CHEMISTRY/LIPID PROFILE

Total Cholesterol	179	Normal/Desireable: <200 Borderline High: 200-239 High: >=240
HDL Cholesterol	40.4	Normal : >40 - <60 Low HDL : <40 Desireable : >=60
LDL Cholesterol	103	Optimal: <100 Near/Above Optimal: 100-129 Borderline High: 130-159 High: 160-189 Very High: >=190
Triglycerides	176 *	Normal : <150 Borderline High: 150-199 High : 200-499 Very High : >=500

BLD CHEMISTRY/KIDNEY FUNCTION

Ureum	16.0	10.0 - 50.0
Creatinine	0.9	0.6- 1.3
Uric Acid	7.59 *	3.50 - 7.20

BLD CHEMISTRY/LIVER FUNCTION

Total Bilirubin	0.60	0.1 - 1.0
Direct Bilirubin	0.14	0.0 - 0.2
Indirect Bilirubin	0.46	0.0 - 0.8

LABORATORY RESULT

Name : SYAIFUL	MR : 01031455	Visit : 29/01/2021	#Lab : IN7334280966
Comp. : INSPEKTINDO SINERGI PERSADA, PT	Sex : Male	DOB : 03 February 1983	

EXAMINATION	RESULT	NORMAL RANGE
SGOT(AST)	33	13 - 45
SGPT (ALT)	43	13 - 50
Alkaline Phosphatase	79	30 - 120
Gamma GT	29	0 - 50
Albumin	5.3	3.5 - 5.5
Globulin	2.50	2.3 - 3.5
Total Protein	7.8	6.6 - 8.7

BLD CHEMISTRY/DIABETES

Glucose Fasting	98	< 100
Glucose Urine	Negative	Negative
Keton Urine	Negative	Negative

Blood Glucose 2 PP

Blood Sugar 2 Hours PP	81	< 140
Glucose Urine	Negative	Negative
Keton Urine	Negative	Negative

SEROLOGI / IMUNOLOGI

HBsAg (Quantitative)	0.00	0.00 - 0.03
Anti Hbs (Quantitative)	0.1 *	>= 5.0

TOXICOLOGY - DRUGS SCREENING

Methadone	Negative	Negative
Phencyclidine	Negative	Negative
THC/Marijuana	Negative	Negative
Amphetamine	Negative	Negative
Benzodiazepines	Negative	Negative
Opiat	Negative	Negative
Cocain	Negative	Negative
Metamphetamine	Negative	Negative
Alcohol	Negative	Negative

URINALYSIS**Complete Urine Analysis****Macroscopic**

Color	Light Yellow	
Turbidity	Clear	Clear
Specific Gravity	1.008	1.000 - 1.030
pH	6.0	4.5 - 8.0
Leucocyte	Negative	Negative
Glucose	Negative	Negative

LABORATORY RESULT

Name : SYAIFUL	MR : 01031455	Visit : 29/01/2021	#Lab : IN7334280966
Comp. : INSPEKTINDO SINERGI PERSADA, PT	Sex : Male	DOB : 03 February 1983	

EXAMINATION	RESULT	NORMAL RANGE
Nitrit	Negative	Negative
Bilirubin	Negative	Negative
Blood	Negative	Negative
Urobilinogen	Normal	Normal
Protein	Negative	Negative
Keton	Negative	Negative
Microscopic		
RBC	0-1	0 - 1
WBC	0-1	0 - 4
Cylinder	Negative	
Epithels Squamous	0-1	5 - 15
Crystals	Negative	
Bacteria	Negative	Negative
Others	Negative	

STOOL / RECTAL SWAP

Faeces Complete

Macroscopic

Color	Brown	
Consistency	Smooth	
Mucus	Negative	Negative
Blood	Negative	Negative
Pus	Negative	Negative
Parasit	Negative	Negative
Lipid	Negative	Negative

Microscopic

RBC	0-1	0 - 1
WBC	0-1	0 - 5
Amoeba	Negative	
Ephitels	Positive	Positive
Worm Eggs	Negative	Negative
Yeast	Negative	Negative
Muscle Fiber	Negative	Negative
Others	Negative	Negative

Digestive

Amylum	Negative	Negative
Fat	Negative	
Fibers	Positive	Positive

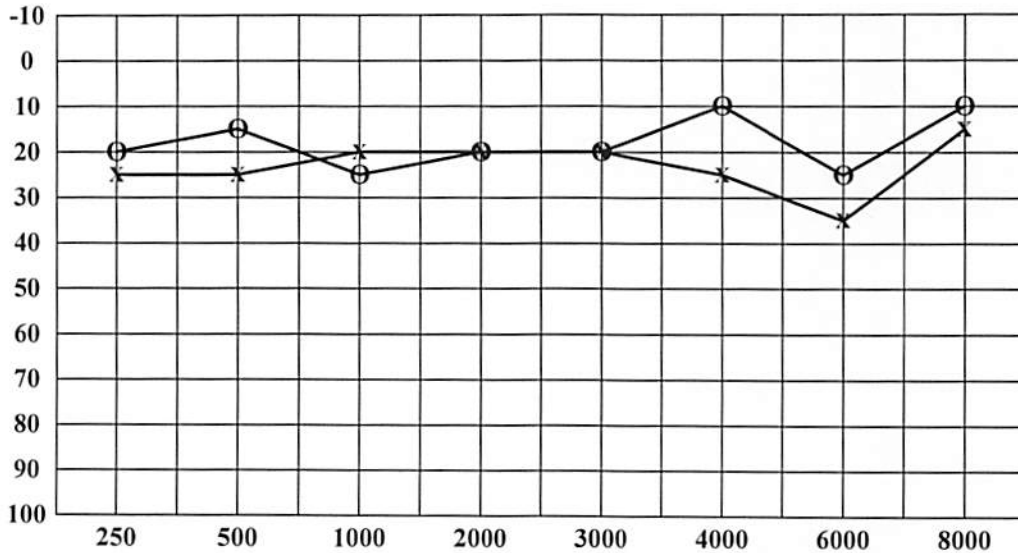
AUDIOMETRY DIAGNOSTIC

Name : SYAIFUL	Sex : Male	MR : 01031455	Visit : 29/01/2021
Comp.: INSPEKTINDO SINERGI PERSADA, PT		DOB : 03 February 1983	

RESULT

Left Ear	250	500	1000	2000	3000	4000	6000	8000
AC	25	25	20	20	20	25	35	15
BC	-	-	-	-	-	-	-	-

Right Ear	250	500	1000	2000	3000	4000	6000	8000
AC	20	15	25	20	20	10	25	10
BC	-	-	-	-	-	-	-	-



Conclusion Right Ear : Hearing threshold = 17.5 dB
(Within normal limit)

Conclusion Left Ear : Hearing threshold = 22.5 dB
(Within normal limit)
With decreasing on frequency 6000Hz

CARDIOLOGY DIAGNOSTIC

Name : SYAIFUL	Sex : Male	MR : 01031455	Visit : 29/01/2021
Comp.: INSPEKTINDO SINERGI PERSADA, PT		DOB : 03 February 1983	
EXAMINATION	RESULT	Comments :	

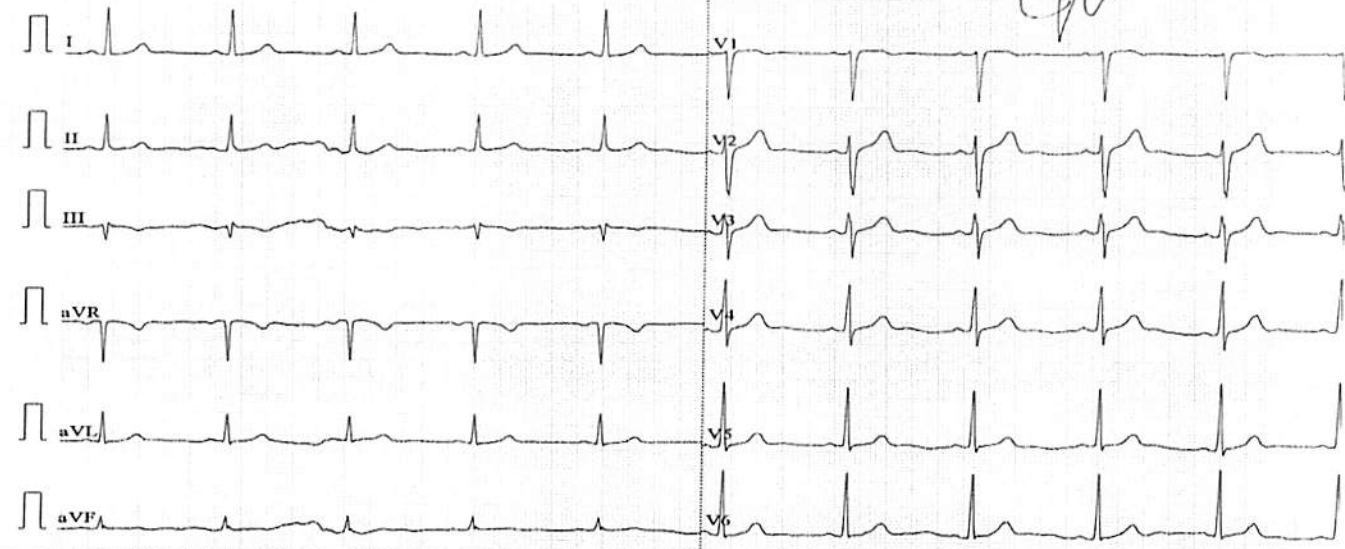
ELECTROCARDIOGRAPHY	Sinus Rythm axis (N), P wave (N), PR int 0.16" ST - T segment (N), aritmia (-)	Normal ECG
TREADMILL	Sinus Rythm axis (N), P wave (N), PR int 0.16" ST - T segment (N), aritmia (-)	Treadmill Exercise Test : Negative Cardiopulmonary Fitness Classification : Good METs : 13.4

ID: 14
SYAIFUL
Male 37Years

29-01-2021 09:35:28
HR : 61 bpm
P : 98 ms
PR : 140 ms
QRS : 88 ms
QT/QTc : 406/409 ms
P/QRS/T : 13/22/16
RV5/SV1 : 1.668/1.273 mV

Diagnosis Information:
Sinus rhythm
Normal ECG

Report Confirmed by:



0.67~100Hz AC50 25mm/s 10mm/mV 2*5.0s ♡61 SE-1200Express V2.21 Glasgow V28.6.0



SYAIFUL, MR

ID: 01031455, Born: 2/3/1983 (Male 37), 70 kg, 167 cm
Test Date: 1/29/2021 8:39:55 AM

MEDIKA PLAZA

Patient info

orn: 2/3/1983
ge: 37
ex: Male
veight: 70 kg
leight: 167 cm
moker:
acemaker:

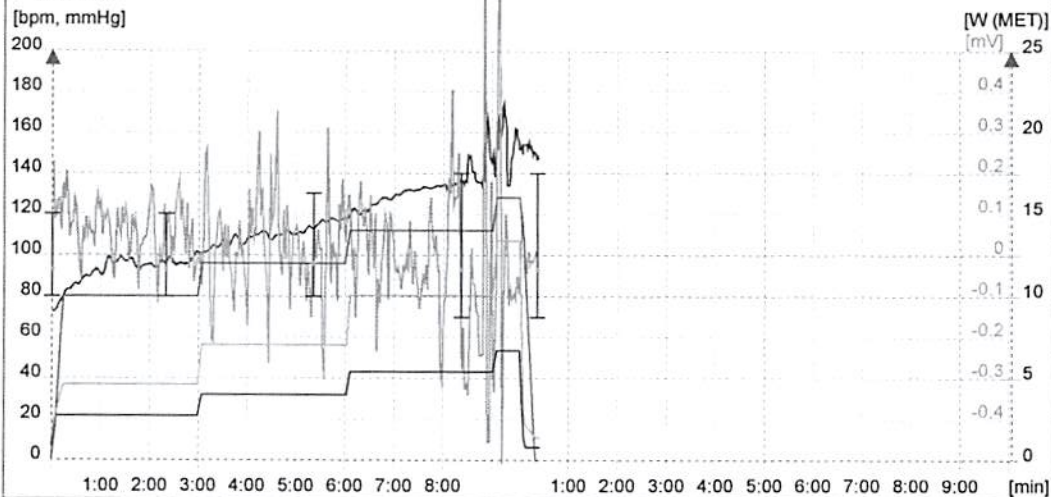
Medical history

Medications

Reason for admission

Reason for Stop

Trends



Conclusion

Syaiful

 PT. KARTIKA BINA MEDIKATAMA
Syaiful

Staff

Physician: user
Technician:

Test info

Test date: 1/29/2021
 Test time: 8:39 AM
 Stress device: BTL Treadmill
 Protocol: Bruce
 Total duration: 09:35
 Stress achieved: 6.7km/h, 16.0% (~13.4MET) = 109% predicted (~12.4MET) - for 3 sec
 HR rest: 80
 HR peak: 161 = 88% predicted (182) -- 09:3 Exercise (13.4MET)
 Handgrip test: --
 BP rest: 120/80
 BP peak:
 BP recovery: 140/70
 DP rest: 9600
 DP peak: 19222 = 2.0x DP at rest
 ST depression max: aVR -2.76mV 08:51 Exercise 10.1MET
 ST elevation max: I 2.92mV 08:51 Exercise 10.1MET
 ST/HR index: 8.7 μ V/bpm (abnormal)




SYAIFUL, MR

ID: 01031455, Born: 2/3/1983 (Male 37), 70 kg, 167 cm
Test Date: 1/29/2021 8:39:55 AM

MEDIKA PLAZA

Time: P 00:07 - Reference

Load: 1.4MET, HR: 80bpm, BP: 120/80



Filter: 0.07 Spline - 90 Adapt, ~50 [Hz]

25.00 mm/sec 10.0 mm/mV



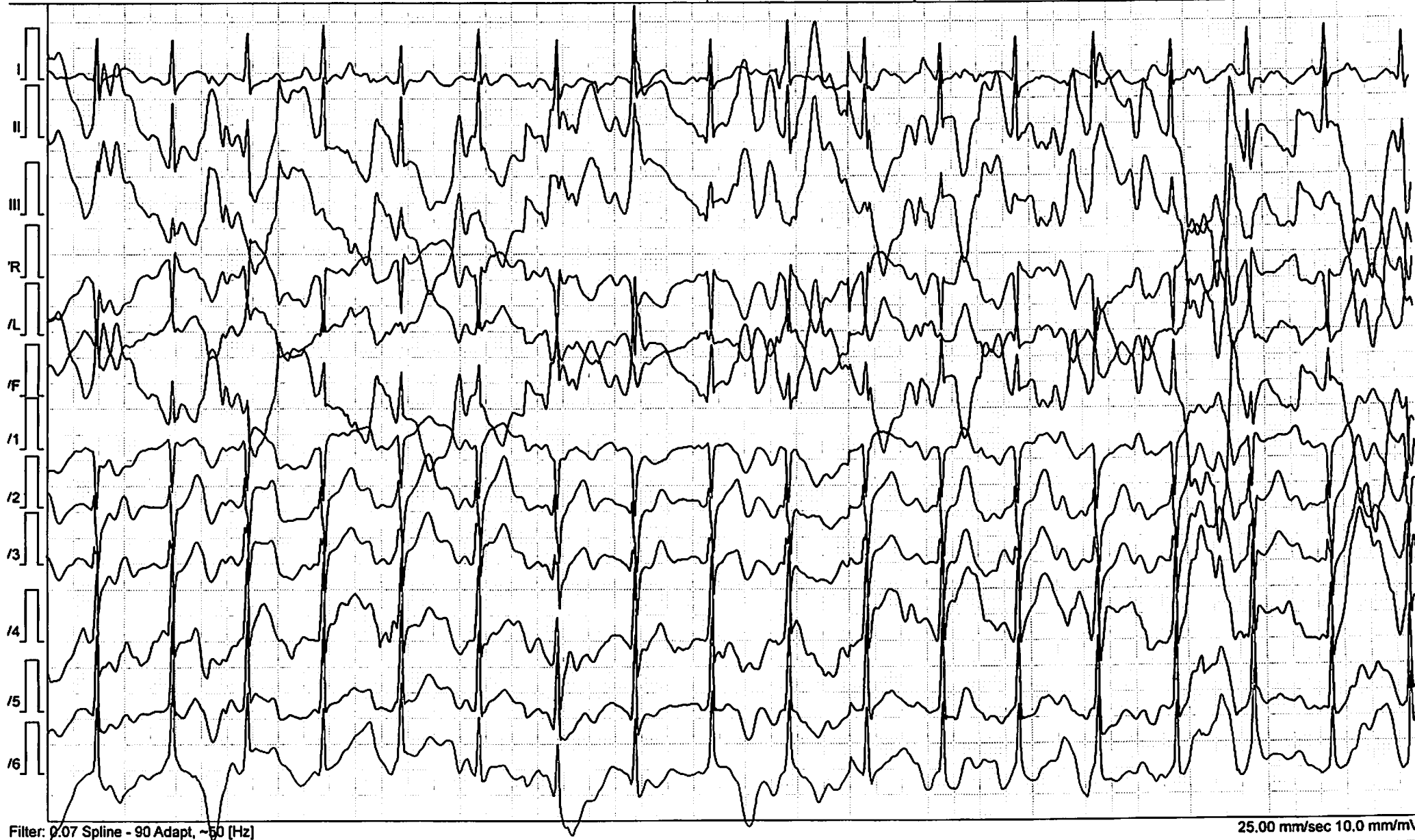SYAIFUL, MR

ID: 01031455, Born: 2/3/1983 (Male 37), 70 kg, 167 cm
Test Date: 1/29/2021 8:39:55 AM

MEDIKA PLAZA

Time: E 02:56 - E1

Load: 4.6MET, HR: 101bpm, BP: 120/80



Filter: 0.07 Spline - 90 Adapt, ~50 [Hz]

25.00 mm/sec 10.0 mm/mV




SYAIFUL, MR

ID: 01031455, Born: 2/3/1983 (Male 37), 70 kg, 167 cm
Test Date: 1/29/2021 8:39:55 AM

MEDIKA PLAZA

Time: E 05:57 - E2

Load: 7.0MET, HR: 118bpm, BP: 130/80



Filter: 0.07 Spline - 90 Adapt, ~50 [Hz]

25.08 mm/sec 10.0 mm/mV



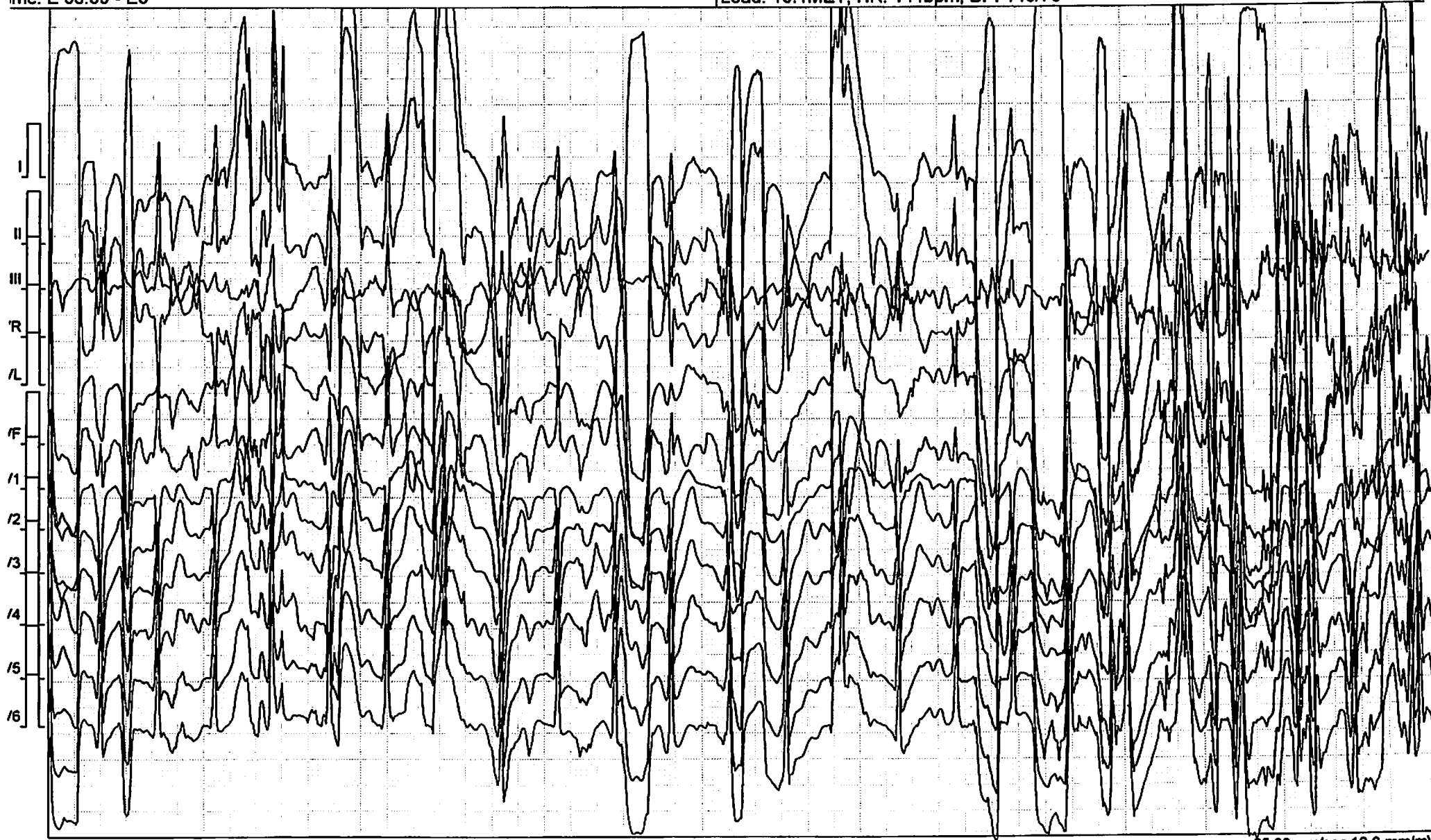
SYAIFUL, MR

ID: 01031455, Born: 2/3/1983 (Male 37), 70 kg, 167 cm
Test Date: 1/29/2021 8:39:55 AM

MEDIKA PLAZA

Time: E 08:59 - E3

Load: 10.1MET, HR: 144bpm, BP: 140/70



Filter: 0.07 Spline - 90 Adapt, ~50 [Hz]

25.00 mm/sec 10.0 mm/mV



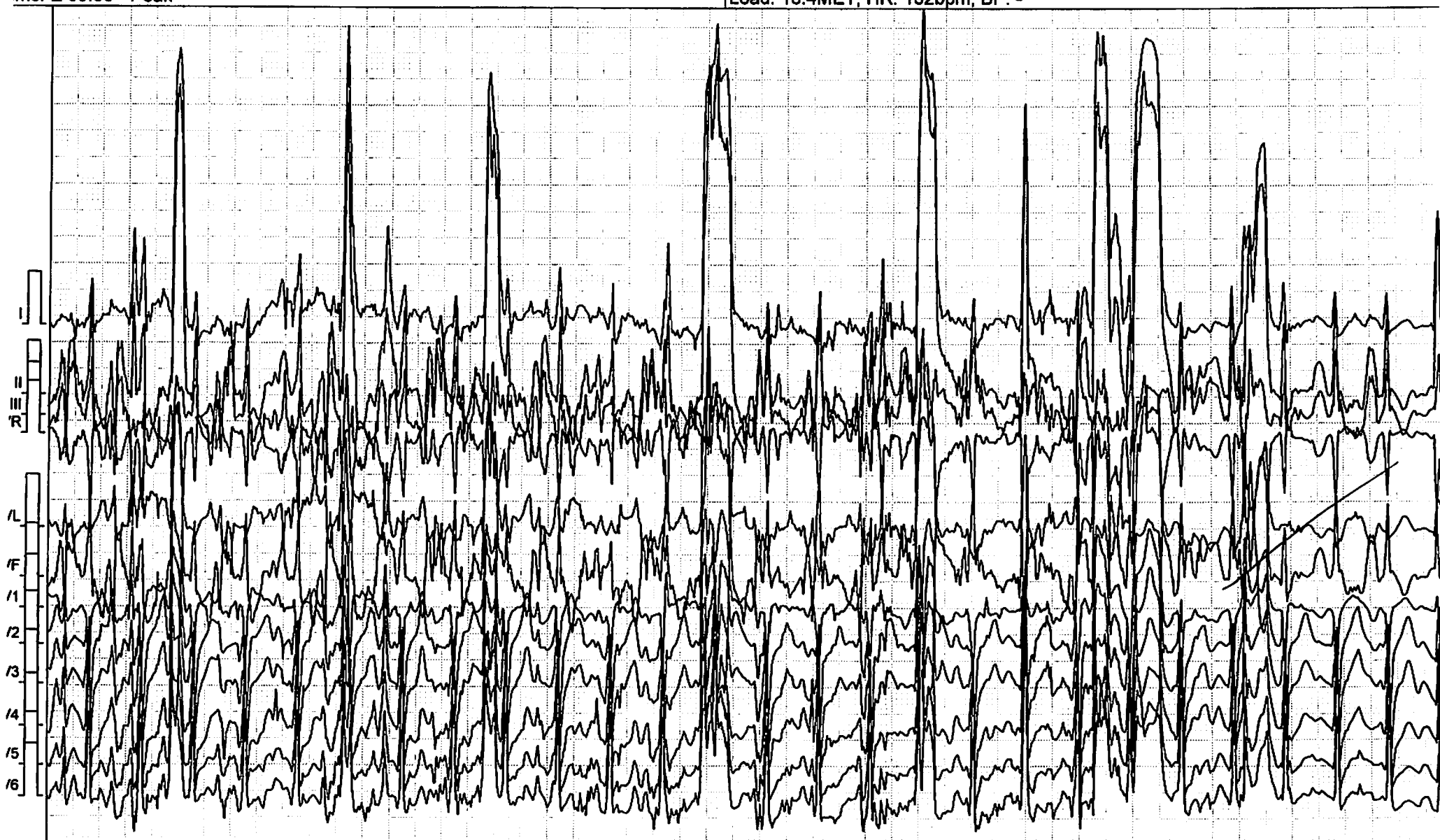
SYAIFUL, MR

ID: 01031455, Born: 2/3/1983 (Male 37), 70 kg, 167 cm
Test Date: 1/29/2021 8:39:55 AM

MEDIKA PLAZA

Time: E 09:30 - Peak

Load: 13.4MET, HR: 152bpm, BP: -



Filter: 0.07 Spline - 90 Adapt, ~50 [Hz]

25.00 mm/sec 10.0 mm/mV



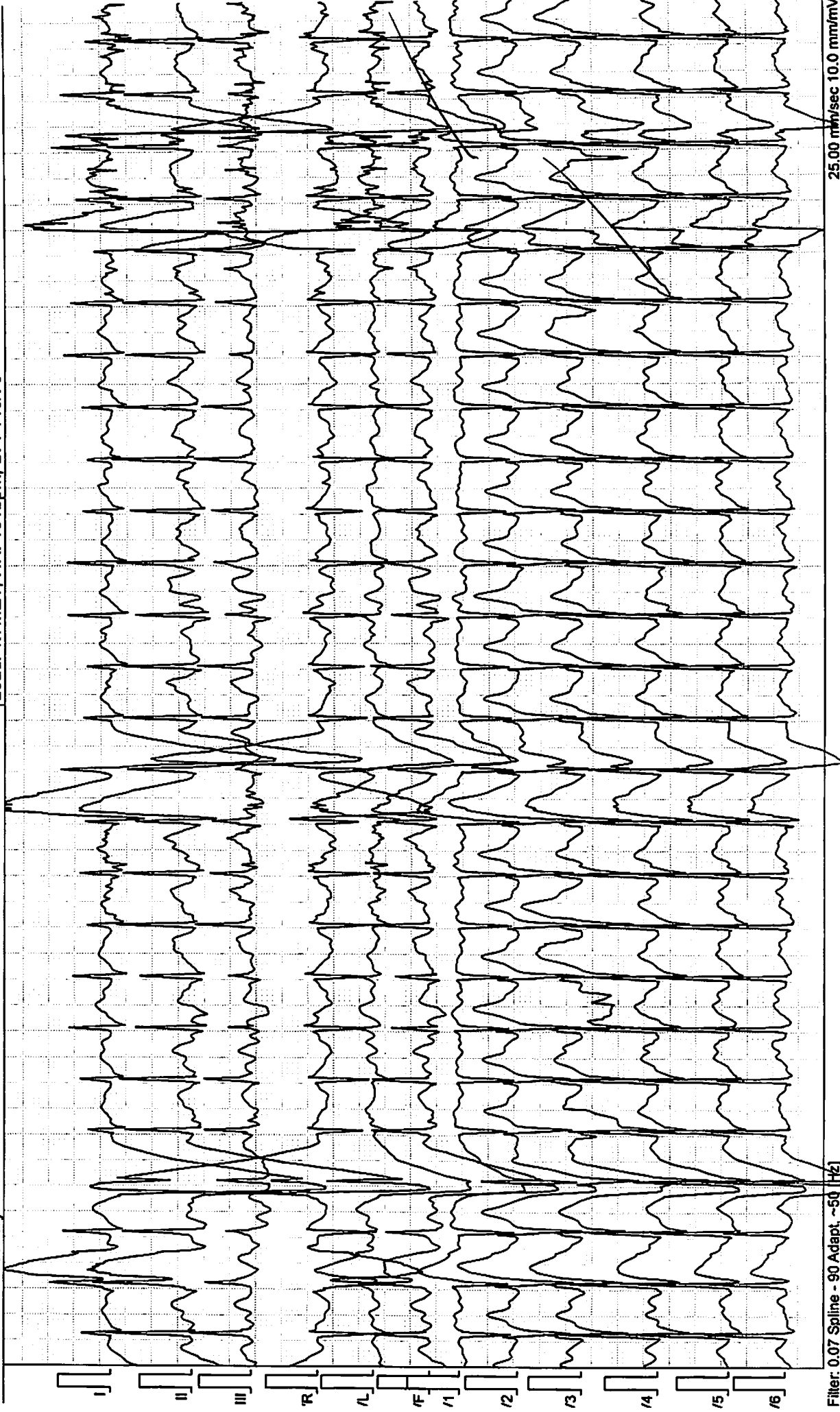
SYAIFUL, MR

ID: 01031455, Born: 23/1983 (Male 37), 70 kg, 167 cm
Test Date: 1/29/2021 8:39:55 AM

MEDIKA PLAZA

Time: R 00:10 - Recovery

Load: 1.7MET, HR: 151bpm, BP: 140/70



Filter: 0.07 Spine - 90 Adapt. ~50 Hz

25.00 mm/sec 10.0 mm/mV

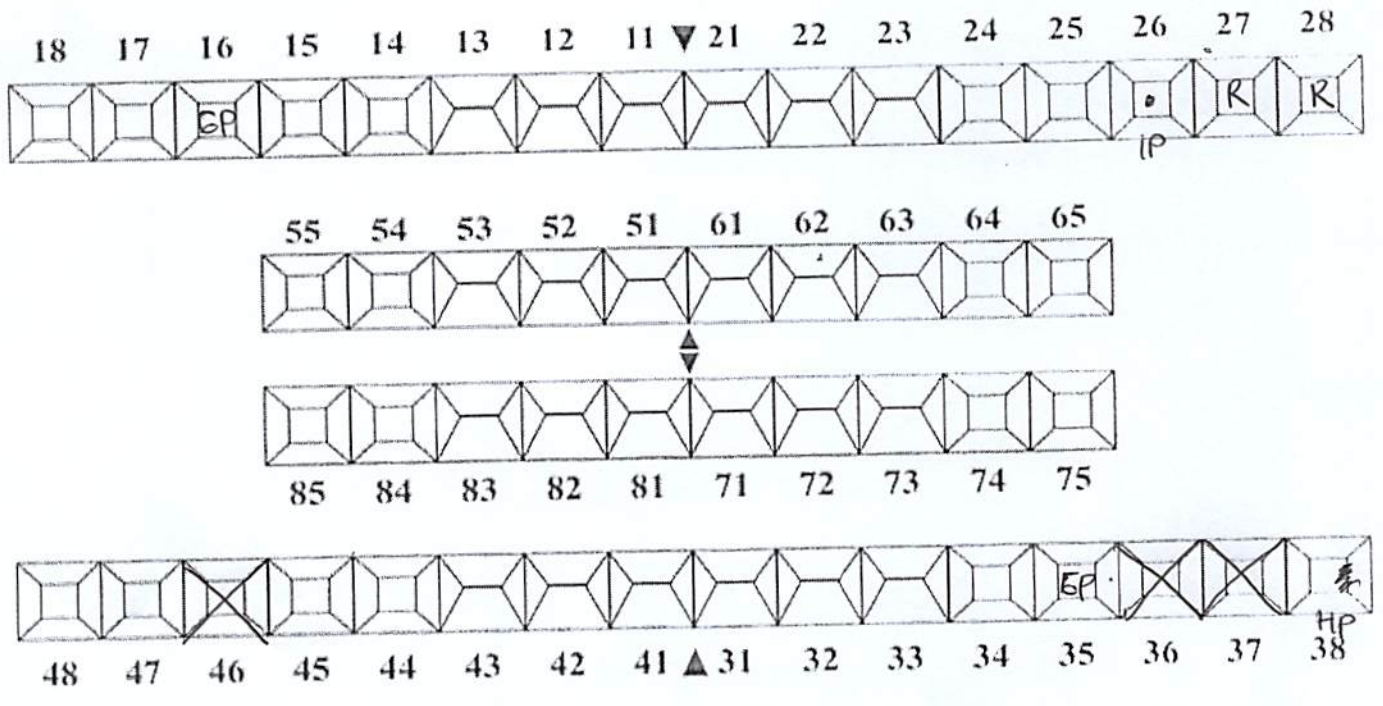
**SYAIFUL, MR**ID: 01031455, Born: 2/3/1983 (Male 37), 70 kg, 167 cm
Test Date: 1/29/2021 8:39:55 AM

MEDIKA PLAZA

Stage	Time	Load			HR bpm	BP mmHg	SpO2 %	ST Level [mV], J+: 1/8RR											
		km/h	%	MET				I	II	III	aVR	aVL	aVF	V1	V2	V3	V4	V5	V6
Reference	E 00:03	0.8	0.0	1.4	80	120/80	-	0.06	0.35	0.30	-0.19	-0.34	0.28	-0.02	0.20	0.18	0.07	0.04	-0.02
E 1 stage	E 03:01	2.7	10.0	4.6	101	120/80	-	0.06	-0.03	-0.08	-0.02	0.07	-0.09	0.08	0.09	-0.02	0.09	-0.01	-0.19
E 2 stage	E 06:02	4.0	12.0	7.0	118	130/80	-	-0.01	0.31	-0.25	0.10	0.13	-0.28	0.15	0.25	0.17	0.75	0.03	0.32
E 3 stage	E 09:04	5.4	14.0	10.1	147	140/70	-	2.92	2.63	-0.11	-2.76	1.61	1.20	1.71	2.13	2.03	1.91	0.75	0.68
E 4 peak	E 09:35	6.7	16.0	13.4	161	-	-	0.08	-0.29	-0.29	0.09	0.16	-0.22	0.25	0.21	0.10	-0.17	-0.05	-0.07
Recovery	R 00:20	0.8	16.0	2.5	151	140/70	-	0.01	-0.02	-0.04	0.00	0.04	-0.03	0.10	0.26	0.19	0.07	0.01	-0.02

DENTAL EXAMINATION

Name: Syaiful	Sex: M/F	MR :	Visit : 29/1/21
Comp.: Inspektindo Sinergi Persada		DOB :	
ODONTOGRAM			



Calculus + 1

DIAGNOSA

1. calculus
2. Gangren pulpa : 16, 35.
3. caries : 26, 38.
4. Gangren Radik : 27, 28.

TREATMENT PLANNING

1. pro scaling
2. pro ekstraksi : 26, 35, 27, 28.
3. pro Filling : 26, 38

Verified by: drg. Ilona Amalia/ drg. Fajar Sulawati/ drg. Siti Darjah/drg. Herlina

PATIENT NAME : *Tn. Syaiful*
No. RM : *01.031453*
Klinik/MCU/HCU : *ENT*

To. Dokter :
(Counsel)

Kindly please counsel for patient who has take cares of

Diagnose :
Clinik Summary :

Counsel Request :

COUNSEL/ADVISE

Finding :

*ear: tympanic membrane intact.
Nose: canal euhy, sept deviate
head = TIT no hyperemic.*

Diagnosis :

*Ordinarily: Hearing level with normal limit
being on 6000 Hz.*

Recomendation :

*- Stop smoking.
- Use ear protection.
When working in noisy area.*

Date : *29 - 1 - 2021*
Time :
EP :

Signature
MP+

DR. NERSYAHRI CHANGINA MEDIKATAMA
SIP : 13/B.155/31.74.001-1.779.301/2018

Complete Name