

EXECUTIVE MEDICAL CHECK UP



HEALTH CERTIFICATE

I. Personal Data

Date Of Examination : January 28, 2021
Full Name : **Mr. Elicohen Dima Sagala**
Sex : Male
Date Of Birth : April 1998
Nationality : Indonesian
Address : Jl. Madrid Utara No.7 Panunggangan Barat
Tangerang

II. Physical Examination

Height : 166 Cm
Weight : 75.1 Kg
Blood pressure : 110/80 mmHg
Ishihara test : Normal
Others : AVOD : 20/25, OS : 20/20

III. Laboratory Report

Hematology : Within normal limits
Biochemistry : Within normal limits
HBsAg : Non Reactive
Anti HBs : Reactive (46.35 IU/L)
TPHA : Non Reactive
Urine : Within normal limits
Alcohol (Serum) : Negative 0.0 mg/dL
Drug Abuse

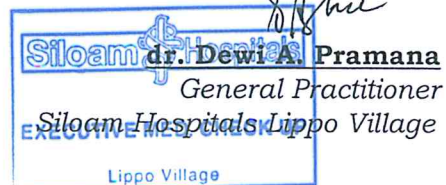
Amphetamine : Negative
Benzodiazepines : Negative
Cannabinoids : Negative
Opiat : Negative
Cocain : Negative
Metamphetamine : Negative

IV. X Ray Thorax : Within normal limits

V. Audiogram : Within normal limits

VI. ECG : Within normal limits

The examinations performed are satisfactory and do not suggest any serious medical problem.



Patient Name : ELICOHEN DIMA SAGALA	Order Time : 28-01-21 09:39
Address : JL MADRID UTARA NO 7 PANUNGGANGAN BARU	Specimen Received : 28-01-21 10:39
DOB/Sex : 01-04-1998 / Male	Print Out : 04-02-21 09:55
Ward : MCU	Lab No. : 21057571
Physician : dr. Yosia Efa	Room :
MR. No. : 00989605	Reg. No. : CPA2101280119
Clinical Info : HC	Page : 1 / 1

RUTIN

Test	Result	Unit	Reference Range
DRUG ABUSE			
Alcohol (Serum)	0.0	mg/dL	Negative : < 10 Positive : >= 10

Clinical Pathologist

Dr. David Rustandi, Sp.PK
Dr. Tandry Meriyanti, Sp.PK

NAMA & PARAF DOKTER	
TGL	JAM:

Authorized By dr. Tandry Meriyanti, Sp.PK
Authorisation Date : 04-02-21 09:42

A laboratory assessment can only be given by a doctor who has patient clinical data.
This laboratory has been verified electronically, no signature required

Patient Name : ELICOHEN DIMA SAGALA	Order Time : 28-01-21 09:31
Address : JL MADRID UTARA NO 7 PANUNGGANGAN BARU	Specimen Received : 28-01-21 10:38
DOB/Sex : 01-04-1998 / Male	Print Out : 28-01-21 14:07
Ward : MCU	Lab No. : 21057539
Physician : dr. Yosia Efa	Room :
MR. No. : 00989605	Reg. No. : CPA2101280119
Clinical Info : HC	Page : 1 / 3

RUTIN

Test	Result	Unit	Reference Range
HEMATOLOGY			
Full Blood Count			
Haemoglobin	16.00	g/dL	13.20 - 17.30
Hematocrit	46.80	%	40.00 - 52.00
Erythrocyte (RBC)	5.42	10 ⁶ /μL	4.40 - 5.90
White Blood Cell (WBC)	5.79	10 ³ /μL	3.80 - 10.60
Differential Count			
Basophil	0	%	0 - 1
Eosinophil	5	%	1 - 3
Band Neutrophil	3	%	2 - 6
Segment Neutrophil	59	%	50 - 70
Lymphocyte	26	%	25 - 40
Monocyte	7	%	2 - 8
Platelet Count	268.00	10 ³ /μL	150.00 - 440.00
ESR	1	mm/hours	0 - 15
MCV, MCH, MCHC			
MCV	86.30	fL	80.00 - 100.00
MCH	29.50	pg	26.00 - 34.00
MCHC	34.20	g/dL	32.00 - 36.00

BIOCHEMISTRY

SGOT (AST)	14	U/L	0 - 40
SGPT (ALT)	13	U/L	0 - 41
Ureum	17.0	mg/dL	<50.00
Blood Urea Nitrogen (BUN)	L 7.94	mg/dL	8.88 - 20.09

Creatinine

Creatinine	0.83	mg/dL	0.5 - 1.3
eGFR	124.9	mL/mnt/1.73 m ²	

GFR Comment

>= 60 Normal kidney function

Reff : National Kidney Foundation, 2006

* CKD EPI

Patient Name	: ELICOHEN DIMA SAGALA	Order Time	: 28-01-21 09:39
Address	: JL MADRID UTARA NO 7 PANUNGGANGAN BARU	Specimen Received	: 28-01-21 10:39
DOB/Sex	: 01-04-1998 / Male	Print Out	: 28-01-21 14:08
Ward	: MCU	Lab No.	: 21057571
Physician	: dr. Yosia Efa	Room	:
MR. No.	: 00989605	Reg. No.	: CPA2101280119
Clinical Info	: HC	Page	: 1 / 1

RUTIN

Test	Result	Unit	Reference Range
------	--------	------	-----------------

BIOCHEMISTRY

Bilirubin

Total Bilirubin	0.75	mg/dL	0.20 - 1.2
Direct Bilirubin	0.30	mg/dL	0.00 - 0.50
Indirect Bilirubin	0.45	mg/dL	0.00 - 0.70
Alkaline Phosphatase	52	U/L	40 - 150
Gamma GT	15	U/L	10.0 - 71.0

IMMUNOLOGY/SEROLOGY

HBsAg (Qualitative)	Non Reactive	Non Reactive
Test Method : ECLIA		
Anti HBs	H 46.35 Reactive	IU/L Post Vaccination : < 10.00 : no response ≥ 10.00 : less response > 100 IU/L : good response Test method : ECLIA
TPHA	Non Reactive	Non Reactive

TDM

Drug Monitoring

Amphetamine (Urine)	Negative	Negative
Benzodiazepines (Urine)	Negative	Negative
Cannabinoids	Negative	Negative
Opiat (Urine)	Negative	Negative
Cocain (Urine)	Negative	Negative
Metamphetamine (Urine)	Negative	Negative

DRUG ABUSE

Alcohol (Serum)	Pending
-----------------	---------

Clinical Pathologist

Dr. David Rustandi, Sp.PK
Dr. Tandry Meriyanti, Sp.PK

NAMA & PARAF DOKTER	
28/1/19	
TGL	JAM:

Authorized By Nia Sumartin
Authorisation Date : 28-01-21 14:07

A laboratory assessment can only be given by a doctor who has patient clinical data.
This laboratory has been verified electronically, no signature required

Patient Name	: ELICOHEN DIMA SAGALA	Order Time	: 28-01-21 09:31
Address	: JL MADRID UTARA NO 7 PANUNGGANGAN BARU	Specimen Received	: 28-01-21 10:38
DOB/Sex	: 01-04-1998 / Male	Print Out	: 28-01-21 14:07
Ward	: MCU	Lab No.	: 21057539
Physician	: dr. Yosia Efa	Room	:
MR. No.	: 00989605	Reg. No.	: CPA2101280119
Clinical Info	: HC	Page	: 2 / 3

RUTIN

Test	Result	Unit	Reference Range
Uric Acid	4.10	mg/dL	3.5 - 7.2
Total Cholesterol	154	mg/dL	Konsensus Lipid 2004 - <200 Desirable - 200 - 239 Moderate - >=240 High
HDL Cholesterol (Direct)	H 70.0	mg/dL	Konsensus Lipid 2004 - <40 Low - >=60 High
LDL Cholesterol (Direct)	71	mg/dL	Konsensus Lipid 2004 - <100 Optimal - 100-129 Near Optimal - >=130 High
Trygliceride	64	mg/dL	50 - 150
Fasting Blood Glucose	91.0 Desirable	mg/dL	Pengelolaan DM 2011 Menurut Konsensus DM 2011 < 100 Desirable 101 - 125 Moderate >= 126 High Risk Glukosa Darah Puasa Terganggu (GDPT) bila 100 <= GDP <= 126 dan GTT 2 Jam < 140

URINALYSIS

Urine Feme

Macroscopic

Color	Yellow		
Appearance	Clear	Clear	
Specific Gravity	1.005	1.000	- 1.030
pH	7.00	4.50	- 8.00
Leucocyte Esterase	Negative	cells/ μ L	Negative
Nitrit	Negative		Negative
Protein	Negative	mg/dL	Negative
Glucose	Negative	mg/dL	Negative

Patient Name : ELICOHEN DIMA SAGALA	Order Time : 28-01-21 09:31
Address : JL MADRID UTARA NO 7 PANUNGGANGAN BARU	Specimen Received : 28-01-21 10:38
DOB/Sex : 01-04-1998 / Male	Print Out : 28-01-21 14:07
Ward : MCU	Lab No. : 21057539
Physician : dr. Yosia Efa	Room :
MR. No. : 00989605	Reg. No. : CPA2101280119
Clinical Info : HC	Page : 3 / 3

RUTIN

Test	Result	Unit	Reference Range
Keton	Negative	mg/dL	Negative
Urobilinogen	0.20	mg/dL	0.10 - 1.00
Bilirubin	Negative		Negative
Occult Blood	Negative	cells/ μ L	Negative
Microscopic			
Erythrocyte	1	cells/ μ L	0 - 3
Leucocyte	2	cells/ μ L	0 - 10
Epithel	(1+)		(1+)
Casts	Negative		
Crystals	Negative		
Others	Negative		

Clinical Pathologist

Dr. David Rustandi, Sp.PK
 Dr. Tandry Meriyanti, Sp.PK


NAMA & PARAF DOKTER	
TGL	JAM:

Authorized By Nia Sumartin
 Authorisation Date : 28-01-21 14:07

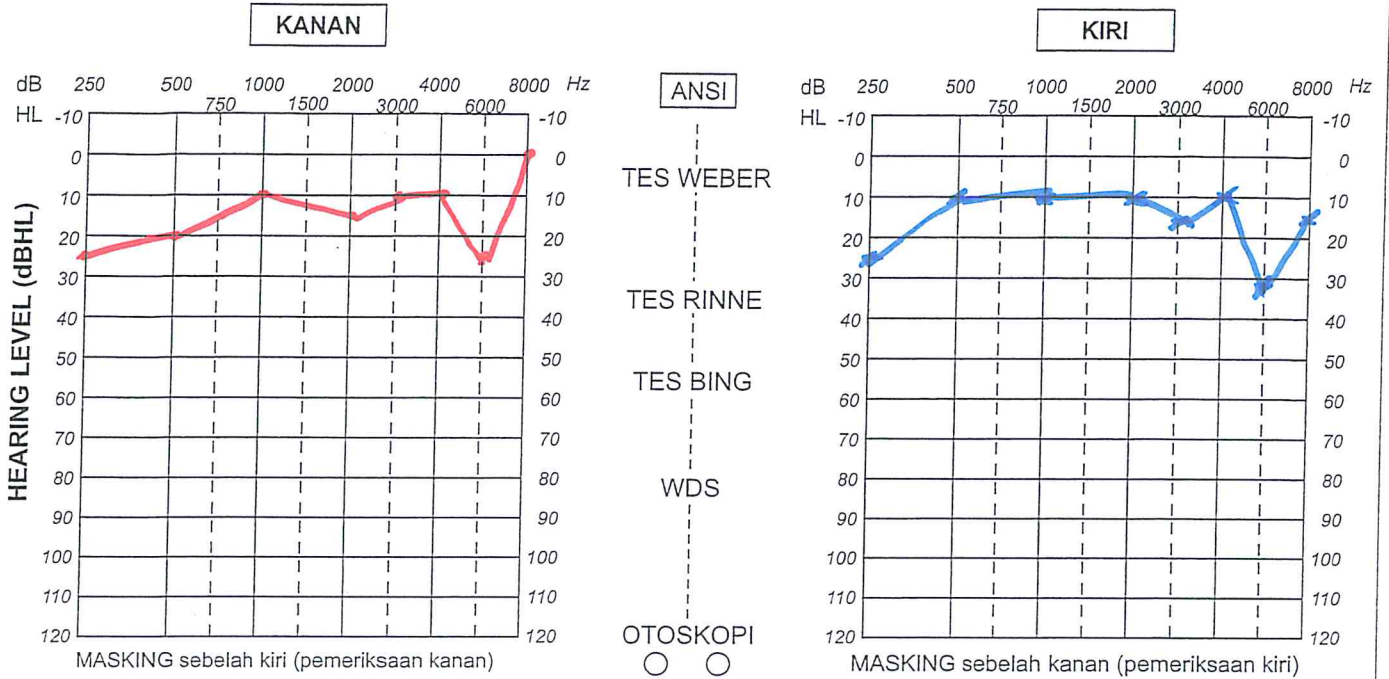
Penilaian hasil laboratorium hanya dapat diberikan oleh Dokter yang memiliki data klinis pasien.
 Laporan ini sudah diverifikasi secara elektronik, tanda tangan petugas tidak diperlukan

ELICOHEN DIMA SAGALA / Male / Ph: 081370481598
MR No: SHLV.00-98-96-05 / DOB: 01-Apr-1998 (22y 9m 27d)
CPA2101280119 / 28-Jan-2021 09:27
dr. Yosia Efa

AUDIOGRAM



FREQUENCY IN HERTZ (Hz)



AUDIOGRAM CODE

	Right	Left
AC Unmasked	○	x
AC Masked	△	□
BC Unmasked	<	>
BC Masked	[]
Forehead Masked	┌	┐

BC	↓
Forehead	∨
Unmasked	∩
Sound Field	S

NOTE :
Right : warna merah
Left : warna biru

Informasi tambahan : *Pendengaran Normal*

Tangerang, *28* / *01* / *2021*

(*[Signature]*)
nama petugas

989605 28-Jan-21 11:14:49 AM ELICOHEN DIMA SAGALA Male 751 kg 166 cm BP: 110/80 Dept: Medical Check Up

SINUS RHYTHM. ST ELEV, PROBABLE NORMAL EARLY REPOL PATTERN. normal P axis, V-rate 50-99

Rate 61
PR 144
QRSD 105
QT 404
QTc 407

--AXIS--
P 61
QRS 76
T 36

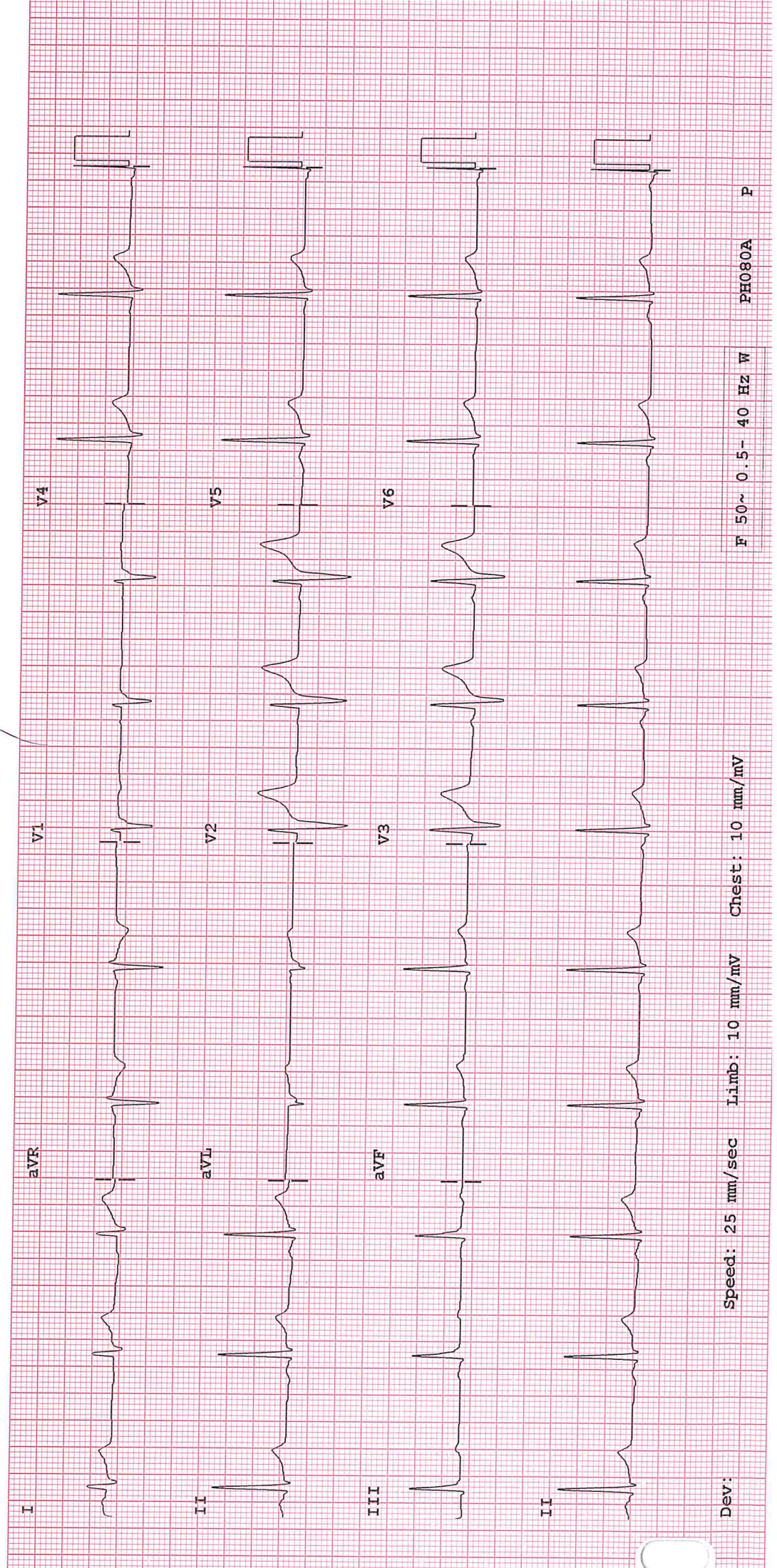


ELICOHEN DIMA SAGALA / Male / Ph: 081370481598
MR No: SHLV.00-98-96-05 / DOB: 01-Apr-1998 (22y 9m 27d)
CPA2101280119 / 28-Jan-2021 09:27
dr. Yostia Efa



NORMAL ECG -

Unconfirmed Diagnosis



Radiology Department



Patient Name	: ELICOHEN DIMA SAGALA	Patient ID	: SHLV.00989605
Sex / Age / DOB	: M / 022Y / 01/04/1998	Accession No.	: 2000027902347
Modality	: DX	Scan Date	: 28/01/2021 11:21:15
Procedure	: THORAX AP/PA	Report Date/Time	: 28/01/2021 11:48:26 (WIB)
Ref. Department	: MCU	Referring Physician	: DR. YOSIA EFA

XR - Thorax PA/AP view

Technique:

Findings:

LUNGS: Normal

MEDIASTINUM: Normal

TRACHEA AND BRONCHUS: Normal

PULMONARY HILA: Normal

PLEURA: Normal

DIAPHRAGM: Normal

HEART: CTR < 50%

AORTA: Normal

THORACIC SPINE: Normal

OTHER VISUALIZED BONES: Normal

VISUALIZED SOFT TISSUES: Normal

VISUALIZED ABDOMEN: Normal

VISUALIZED NECK: Normal

--

Impression:

Heart and lungs within normal limits, no evidence of specific process

Best Regards,

dr. Subagia Santosa Sudjono, Sp.Rad

**This document is digitally signed and hence no manual signature is required.*

Siloam Hospitals Lippo Village

Jln. Siloam No. 6 Lippo Village, 1600, Tangerang 15811

T : +62-21 8064-6900 ext. 12407, 12298 F : +62-21 546-0921

www.siloamhospitals.com

