

Certificate Of Health Assessment


Name	Age	Position	Department
SYAIFUL	33 yo	INSPECTOR	-

COMPANY :

INSPEKTINDO SINERGI PERSADA

CONCLUSION

Fit for work to the job described	✓
Fit with Medical Note (Restriction and/or Limitation)	
Unfit for work to the job described	

Date	Doctors Name	Signature
26 January 2017	Amiruddin, MD	 MP+ PT. KARTIKA BINA MEDIKATAMA

No. Formulir : FM-DR-008-05
 No. Revisi : 00
 Tanggal Terbit : 2 Mei 2011

MEDIKA PLAZA CLINIC

Kartika Chandra - Office Tower 3rd Floor
Jl. Jend. Gatot Subroto, Kav. 18-20 Jakarta Selatan 12940
Tlp : (62-21) 525 1207, Fax : (62-21) 521 0815
Appointment Hotline (62-21) 528 80088
www.medikaplaza.com

PATIENT DATA

MedRec. : 01031455	EMPLOY. STATUS : Employee
NAME : SYAIFUL	BIRTHDATE : 03 February 1983
EMPLOYEE No. :	SEX : Male
JOB TITLE : INSPECTOR	STATUS : Married
COMP. NAME : INSPEKTINDO SINERGI PERSADA	NASIONALITY : Indonesia

SUMMARY

MEDICAL FINDING :

1. Hypertriglyceridemia with fatty liver
 2. Non reactive anti HBs
 3. USG : cholelithiasis
 4. Decreasing of hearing acuity at low and high frequency of left ear
 5. Decreasing of visual acuity of both eyes
 6. Decayed, radix, missing, gangrene pulpa, calculus teeth
- Your fitness status is fit for work to the job described

SUGGESTION :

1. Low fat diet and exercise regularly minimal 3x/week
2. Need to get Hepatitis B vaccination
3. Consult to an internist for evaluation of USG : cholelithiasis
4. Avoid noisy environment or use earplug properly while working at noisy work environment to prevent further hearing impairment
5. Need to wear a glasses for distant vision
6. See a dentist for dental care minimal once a year or better once in 6 months

Responsible Doctor

Amiruddin, MD

Notes:

If you need the further information or consultation, please contact us via :

Email : - kcdoctor01@medikaplaza.com
- dr.yosephine@medikaplaza.com

Clinic Number : (021) 5251207

CLINICAL EVALUATION

Name : SYAIFUL	Sex : Male	MR : 01031455	Visit : 26/01/2017
Comp. : INSPEKTINDO SINERGI PERSADA		DOB : 03 February 1983	
EXAMINATION	RESULT	NOTES	

PHYSICAL EXAMINATION**PRESENT COMPLAINT**

Present complaint

No complaint

MEDICAL HISTORY

Alergy	No
Imunisasi	Yes
Surgery	No
Hospitalization	No
Disease	No

LIFE STYLE

Alcohol intake	No	
Smoking	Yes	12 cigs/day
Exercise	Yes	Soccer 1x/week
Appetite	Good	

FAMILY MEDICAL HISTORY

Diabetes Melitus	No
Hypertension	No
Heart disease	No
Lung TB	No
Kidney disease	No
Astma	No
Mental disease	No
Epilepsy	No
Chronic skin disease	No
Cancer	No
Color blind	No
Stroke	No
Liver disease	No
Bone & joint	No
Pulmonary disease	No
Others disease	No

WORK EXPOSURE

Noise	Yes
Heat Stress	Yes
Cold Stress	No
Vibration	No
Dust	Yes

CLINICAL EVALUATION

Name : SYAIFUL	Sex : Male	MR : 01031455	Visit : 26/01/2017
----------------	------------	---------------	--------------------

Comp.: INSPEKTINDO SINERGI PERSADA	DOB : 03 February 1983
------------------------------------	------------------------

EXAMINATION	RESULT	NOTES
Toxic chemical	No	
Iritating fluid	No	
Heat Stress	No	
Operating heavy mobile equipment	No	
Working around rotating machinery	Yes	
Requires color vision	No	
Involving height	Yes	
Administration work	Yes	
Handling food product	No	
Others	No	
GENERAL		
General Appearance	Good	
Nutrition Status	Normal	
VITAL SIGN		
Body Weight	68.2 Kg	
Body Height	167 Cm	
BMI	24.45 Kg/m ²	
Normal Weight	51.59 - 69.72 Kg	
BMI Conclusion	Normal	
Blood Pressure	120/85 mmHg	
Pulse	82 x/minute	
Body Temperature	36.6 °C	
RR	20	
Neck Circumference	-	
Arm Circumference	-	
Chest size	-	
Abdominal Circumference	-	
SKIN		
Skin	Normal	
Pale	No	
Jaundice	No	
EYE		
Left	Normal	
Right	Normal	
ENT		
Auricle	Normal	
Ear canal	Normal	

CLINICAL EVALUATION

Name : SYAIFUL	Sex : Male	MR : 01031455	Visit : 26/01/2017
Comp.: INSPEKTINDO SINERGI PERSADA		DOB : 03 February 1983	

EXAMINATION	RESULT	NOTES
Drums	Normal	
Septum/Conchae	Normal	
Sinuses	Normal	
Pharynx	Normal	
Tonsil	Normal	
MOUTH		
Gum	Normal	
Dental	Abnormal	Decayed, radix, missing, gangrene pulpa, calculus teeth
NECK		
General	Normal	
Thyroid Gland	Normal	
CHEST		
Form	Normal	
Expansion	Normal	
Lung	Normal	
Heart	Normal	
Breast	Normal	
Heart sound	Normal	
Murmurs	Normal	
ABDOMEN		
Form	Flat	
Palpation	Supple	
Liver	Not Palpable	
Spleen	Not Palpable	
Kidney	No Ballotment	
Hernia inguinal	No	
EXTRIMITIES		
Bones, joint	Normal	
Muscles, tonus	Normal	
Fingernails	Normal	
Hand	Normal	
Foot	Normal	
RECTAL EXAMINATION		
Hemorrhoid	Negative	
Rectum	Normal	
NEUROLOGICAL EXAMINATION		

CLINICAL EVALUATION

Name : SYAIFUL Sex : Male MR : 01031455 Visit : 26/01/2017

Comp.: INSPEKTINDO SINERGI PERSADA DOB : 03 February 1983

EXAMINATION	RESULT	NOTES
Motoric function	Normal	
Sensoric function	Normal	
Coordination	Normal	
Physiologic reflex	Normal	
Extra piramidal function	Normal	
Romberg Test	Not Examined	
LYMPHE SYSTEM		
Neck Gland	Normal	
Armpit gland	Normal	
Inguinal	Normal	

OPHTHALMOLOGY DIAGNOSTIC

Name : SYAIFUL		Sex : Male	MR : 01031455	Visit : 26/01/2017
Comp. : INSPEKTINDO SINERGI PERSADA			DOB : 03 February 1983	
EXAMINATION		Right	Left	
Reading		-		
Previous Glasses		-	-	
Without Glasses	Distant	20/30	20/30	
	Near	-	-	
Correction	Distant	C-0.75X90 20/20	C-0.75X90 20/20	
	Near	-	-	
Tonometry		20.0 mmHg	20.0 mmHg	
Funduscopy		NORMAL	NORMAL	
Visual Fields		-		
Colour Blind Test		Normal		

Impression : Astigmatismus miop simplex ODS

RADIOLOGY DIAGNOSTIC

Name : SYAIFUL

Sex : Male

MR : 01031455

Visit : 26/01/2017

Comp.: INSPEKTINDO SINERGI PERSADA

DOB : 03 February 1983

EXAMINATION**RESULT**

Thorax PA

No abnormality seen in both lungs.
Normal bronchovascular markings in both hili.
The heart is normal in size and shape.
The mediastinum is not widened.
Both sinus and diaphragms are good.
No evidence of pleural effusion.

Impression

Normal chest.
No evidence of specific process in both lungs.

RADIOLOGY DIAGNOSTIC**Name** : SYAIFUL**Sex** : Male**MR** : 01031455**Visit** : 26/01/2017**Comp.** : INSPEKTINDO SINERGI PERSADA**DOB** : 03 February 1983**EXAMINATION****RESULT**UPPER-LOWER ABDOMEN
SONOGRAPHY**LIVER:**

Normal in size. Liver tip is acute, there are increase attenuation of parenchymal echostructures

which are homogeneous. No sign of SOL.

Intrahepatic vascularity and biliary tract are normal.

GALL BLADDER:

Normal in size, contour and surface.

Multiple stones size +/- 4.7 mm was seen in lumen gall bladder

BOTH KIDNEYS:

Normal in size, contour and surface. No sign of obstruction/ stone/ SOL.

PANCREAS:

Normal in size, contour and surface. No sign of SOL.

LIEN:

Normal in size and contour, the echoes are homogenous. No sign of SOL.

URINARY BLADDER:

Normal in size, contour and surface. No sign of stone/ SOL.

PROSTATE AND VESICULA SEMINALIS:

Normal in size and contour which are homogenous echoes and no sign of focal lesion/ SOL.

Impression

Fatty liver

Cholelithiasis

LABORATORY RESULT

Name : SYAIFUL	MR : 01031455	Visit : 26/01/2017	#Lab : IN587033042010
Comp.: INSPEKTINDO SINERGI PERSADA	Sex : Male	DOB : 03 February 1983	
EXAMINATION	RESULT	NORMAL RANGE	

HEMATOLOGI

Automated Blood Count

White Blood Cell (WBC)	12.6 *	3.8 - 11.0
Erythrocyte (RBC)	5.6	4.4 - 5.9
Haemoglobin	16.0	13.2 - 17.3
Hematocrit	47	40 - 52
Thrombocytes	334	150 - 440

MCV, MCH, MCHC

MCV	84	80 - 100
MCH	29	26 - 34
MCHC	34.1	32 - 36
ESR	4	0 - 10

Differential Count

Basophils	0	0 - 1
Eosinophil	2	2 - 4
Bands / Stab	1 *	3 - 5
Neutrophils	44 *	50 - 70
Lymphocytes	45 *	25 - 40
Monocytes	8	2 - 8

BLD CHEMISTRY/LIPID PROFILE

Total Cholesterol	159	Normal/Desireable: <200 Borderline High: 200-239 High: >=240
HDL Cholesterol	57.0	Normal : >40 - <60 Low HDL : <40 Desireable : >=60
LDL Cholesterol	67	Optimal: <100 Near/Above Optimal: 100-129 Borderline High: 130-159 High: 160-189 Very High: >=190
T.Cholesterol/HDL Ratio	2.79	Low risk : < 3.5 Medium risk : 3.5 - 5.0 High risk : > 5.0

LABORATORY RESULT

Name : SYAIFUL	MR : 01031455	Visit : 26/01/2017	#Lab : IN587033042010
----------------	---------------	--------------------	-----------------------

Comp.: INSPEKTINDO SINERGI PERSADA	Sex : Male	DOB : 03 February 1983
------------------------------------	------------	------------------------

EXAMINATION	RESULT	NORMAL RANGE
Tryglicerides	176 *	Normal : <150 Borderline High: 150-199 High : 200-499 Very High : >=500

BLD CHEMISTRY/KIDNEY FUNCTION

Ureum	16.8	10.0 - 50.0
Creatinine	0.8	0.6- 1.3
Uric Acid	5.8	3.5 - 7.2

BLD CHEMISTRY/LIVER FUNCTION

Total Bilirubin	0.7	0.1 - 1.0
SGOT(AST)	22	13 - 45
SGPT (ALT)	33	13 - 50
Alkaline Phosphatase	75	30 - 120
Gamma GT	28	0 - 50
Albumin	5.0	3.5 - 5.5
Albumin/Globulin Ratio	2.00	1.20 - 2.20
Total Protein	7.5	6.6 - 8.7
Globulin	2.50	2.3 - 3.5

BLD CHEMISTRY/DIABETES

Fasting Glucose

Glucose Fasting	99	< 100
Glucose Urine	Negative	Negative
Keton Urine	Negative	Negative

Blood Glucose 2 PP

Blood Sugar 2 Hours PP	92	< 140
Glucose Urine	Negative	Negative
Keton Urine	Negative	Negative

SEROLOGI / IMUNOLOGI

HBsAg	Non Reactive	Non Reactive
Anti HBs	Non Reactive	
VDRL	Negative	Negative

TOXICOLOGY - DRUGS SCREENING

THC/Marijuana	Negative	Negative
MDMA	Negative	Negative
Amphetamine	Negative	Negative
Opiat	Negative	Negative
Cocain	Negative	Negative

LABORATORY RESULT

Name : SYAIFUL MR : 01031455 Visit : 26/01/2017 #Lab : IN587033042010

Comp.: INSPEKTINDO SINERGI PERSADA Sex : Male DOB : 03 February 1983

EXAMINATION	RESULT	NORMAL RANGE
Alcohol	Negative	Negative

URINALYSIS**Complete Urine Analysis****Macroscopic**

Color	Light Yellow	
Turbidity	Clear	Clear
Specific Gravity	1.014	1.000 - 1.030
pH	6.5	4.5 - 8.0
Leucocyte	Negative	Negative
Glucose	Negative	Negative
Nitrit	Negative	Negative
Bilirubin	Negative	Negative
Blood	Negative	Negative
Urobilinogen	Normal	Negative
Protein	Negative	Negative
Keton	Negative	Negative

Microscopic

RBC	0-1	0 - 1
WBC	0-1	0 - 4
Cylinder	Negative	
Epithels Squamous	0-1	5 - 15
Crystals	Negative	
Bacteria	Negative	Negative
Others	Negative	

SPIROMETRY DIAGNOSTIC

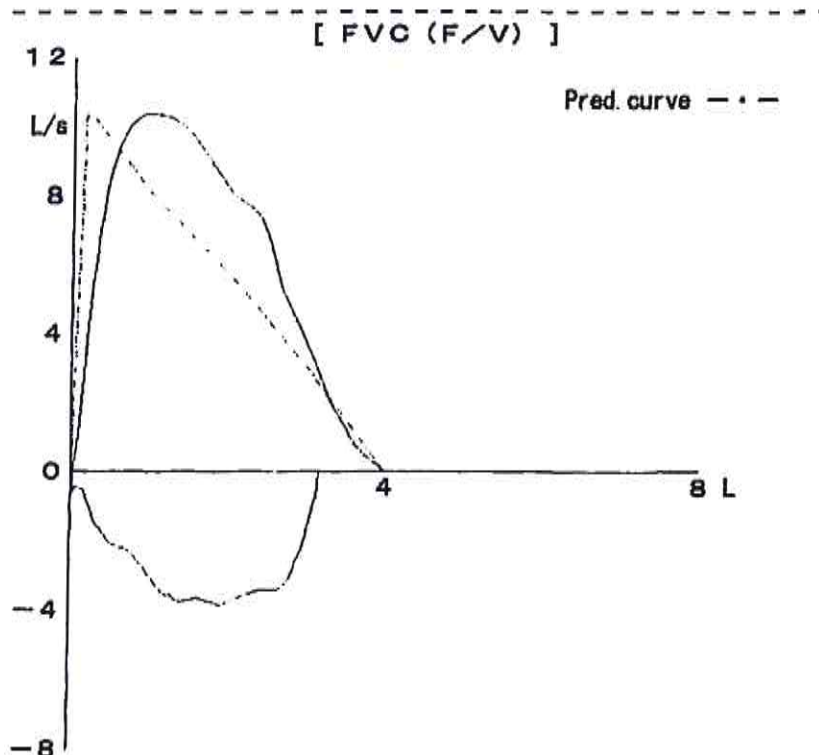
Name : SYAIFUL	Sex : Male	MR : 01031455	Visit : 26/01/2017
Comp.: INSPEKTINDO SINERGI PERSADA		DOB : 03 February 1983	

EXAMINATION	RESULT
FVC Result	: 3.96 L---> 99.0 %
FEV1 Result	: 3.77 L---> 103.0 %
FEV1/FVC Result	: 95.20 %---> 119.8 %
PEF Result	: 10.34 L/S---> 99.4 %
Indonesian Standart Result	:
Index	:
Spirometry Result	: Normal

Impression : Normal Spirometric Functions

[COPD CLASSIFICATION]

FEV1/FVC : 95.20 %
 %FEV1.0 : 103.00 %
 Stage : Normal
 Recommended treatment by GOLD:

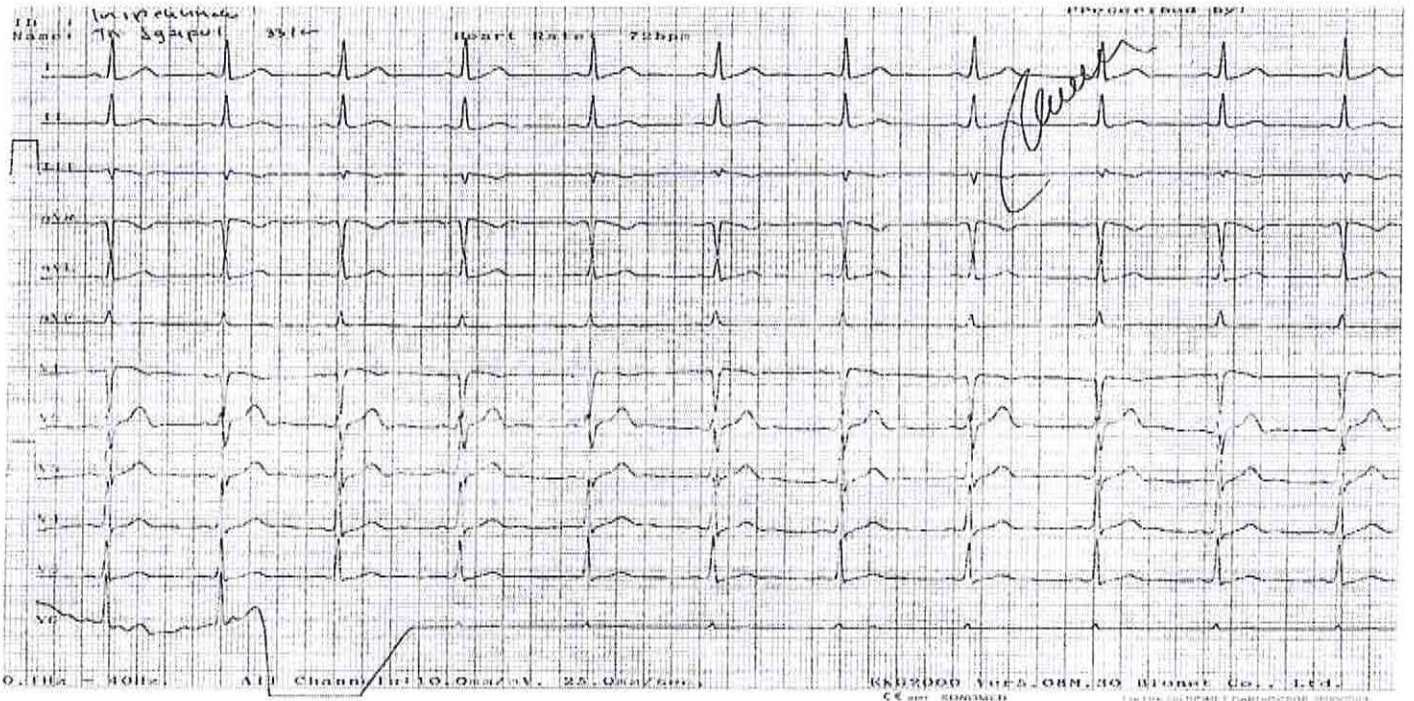


Syaiful - Inspektindo

CARDIOLOGY DIAGNOSTIC

Name : SYAIFUL	Sex : Male	MR : 01031455	Visit : 26/01/2017
Comp.: INSPEKTINDO SINERGI PERSADA		DOB : 03 February 1983	

EXAMINATION	RESULT	Comments :
TREADMILL	Sinus Rythm axis (N), P wave (N), PR int 0.16" ST - T segment (N), aritmia (-)	Treadmill Exercise Test : Negative Cardiopulmonary Fitness Classification : Good METs : 13.4
ELECTROCARDIOGRAPHY	Sinus Rythm axis (N), P wave (N), PR int 0.16" ST - T segment (N), aritmia (-)	Normal ECG






Syaiful, Mr

ID 01031455, Born: 03/02/1983(Male 33), 68 kg, 167 cm
Test Date: 26/01/2017 10:04:34

MEDIKA PLAZA



Patient info

Born: 03/02/1983
Age: 33
Sex: Male
Weight: 68 kg
Height: 167 cm
Smoker:
Pacemaker:


Medical history

Medications

Reason for Admission

Reason for Stop

Trends



Conclusion

[Handwritten signature]
 PT. KARTIKA BINA MEDIKATAMA

Staff

Attending doctor:
Technician:

Adolf Amahorseya , SpJP
Jeni , NR

Test info


Test date: 26/01/2017
 Test time: 10:04
 Stress device: BTL-Headmill
 Protocol: Brace
 Total duration: 10:04
 Stress achieved: 6,7km/h, 16,0% (~13,4MET) = 103% predicted (~13,1MET) - for 64 sec
 HR rest: 112
 HR peak: 153 = 82% predicted (186) — 10:04 Exercise (13,4MET)
 Handgrip test: —
 BP rest: 120/85
 BP peak: —
 BP recovery: —
 DP rest: 13440
 DP peak: 17684 = 1,3x DP at rest
 ST depression max: II -0,23mV 09:34 Exercise 13,4MET
 ST elevation max: V2 0,22mV 07:33 Exercise 10,1MET
 STHR index: 2,4 μ V/ppm (abnormal)



Syaiful, Mr

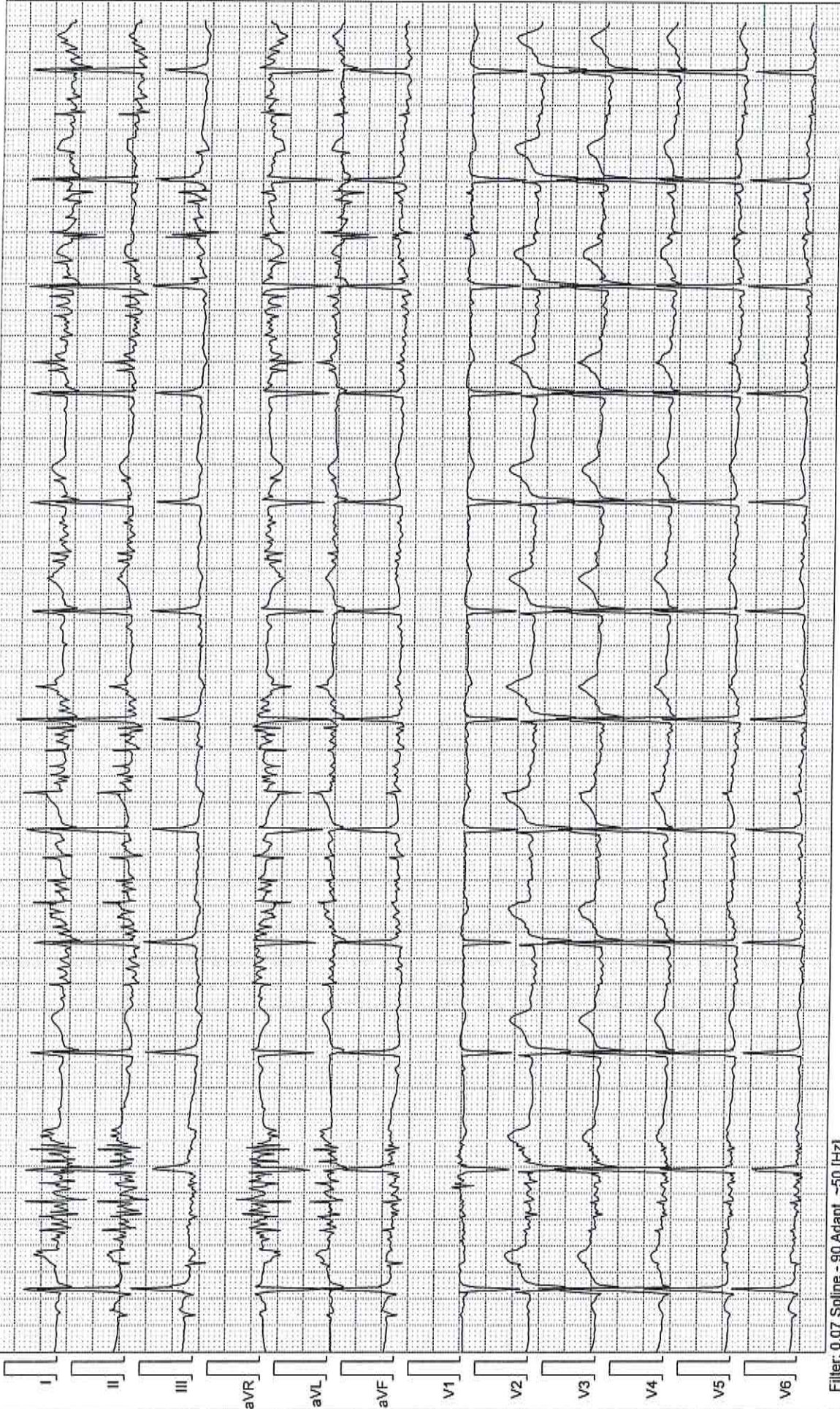
ID: 01031455, Born: 03/02/1983 (Male 33), 68 kg, 167 cm
Test Date: 26/01/2017 10:04:34

MEDIKA PLAZA



Time: P 00:07 - Reference

Load: 1,4MET, HR: 112bpm, BP: 120/85



Filter: 0.07 Spline - 90 Adapt, -50 [Hz]

MEDIKA PLAZA

25,00 mm/sec 10,0 mm/mV

CardioPoint 2.23.18524.0, DIAG 1.7.17214.0, ECG-071D-B-05775

CardioPoint - Stress Test

Page: 2



Syaiful, Mr

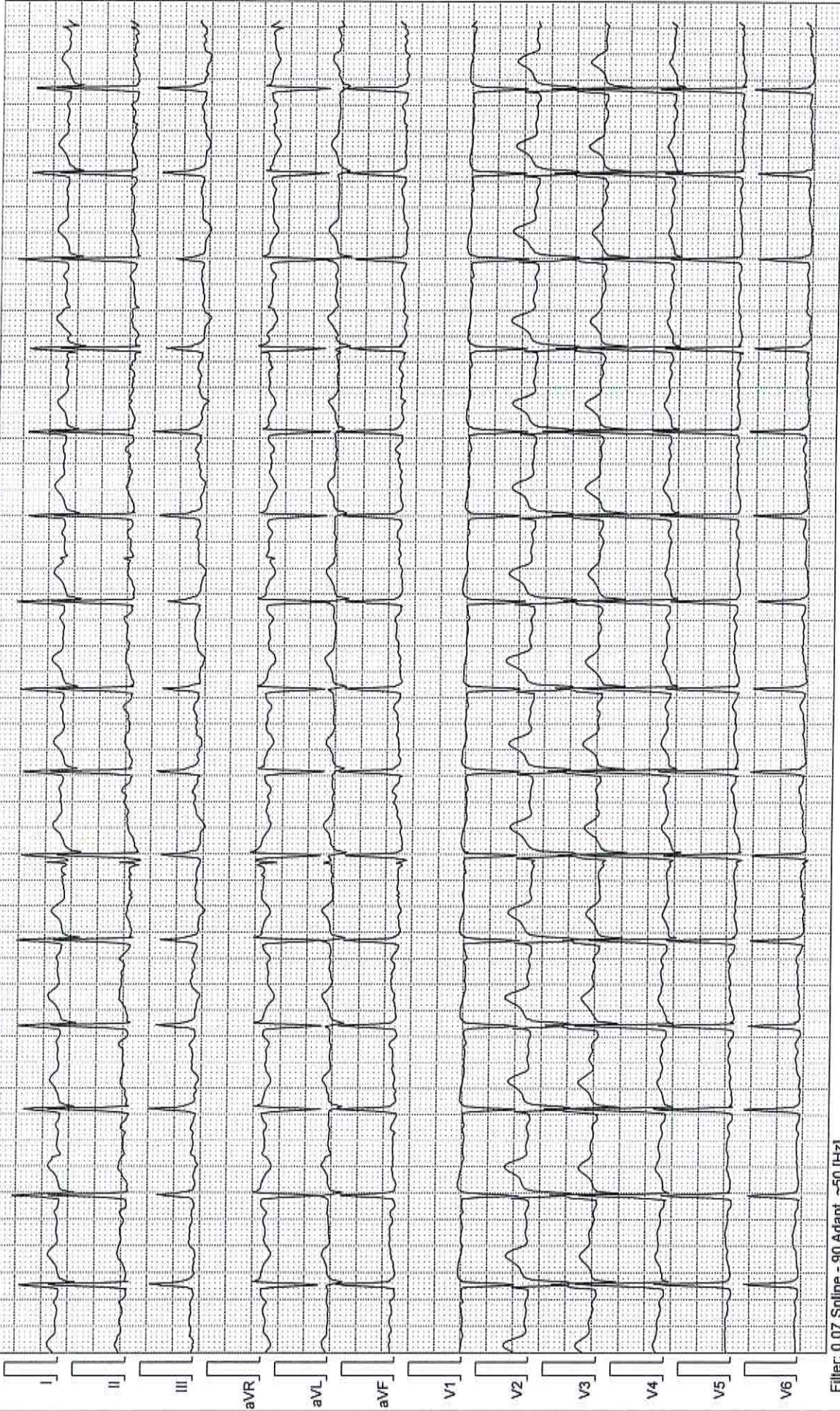
ID: 01031455, Born: 03/02/1983 (Male 33), 68 kg, 167 cm
Test Date: 26/01/2017 10:04:34

MEDIKA PLAZA



Time: E 02:56 - E1

Load: 4,6MET, HR: 91bpm, BP: 120/85



Filter: 0.07 Spline - 90 Adapt, -50 [Hz]

25,00 mm/sec 10,0 mm/mV

MEDIKA PLAZA

CardioPoint 2.23.18524.0, DIAG 1.7.17214.0, ECG:071D-B-05775

CardioPoint - Stress Test

Page: 3



Syaiful, Mr

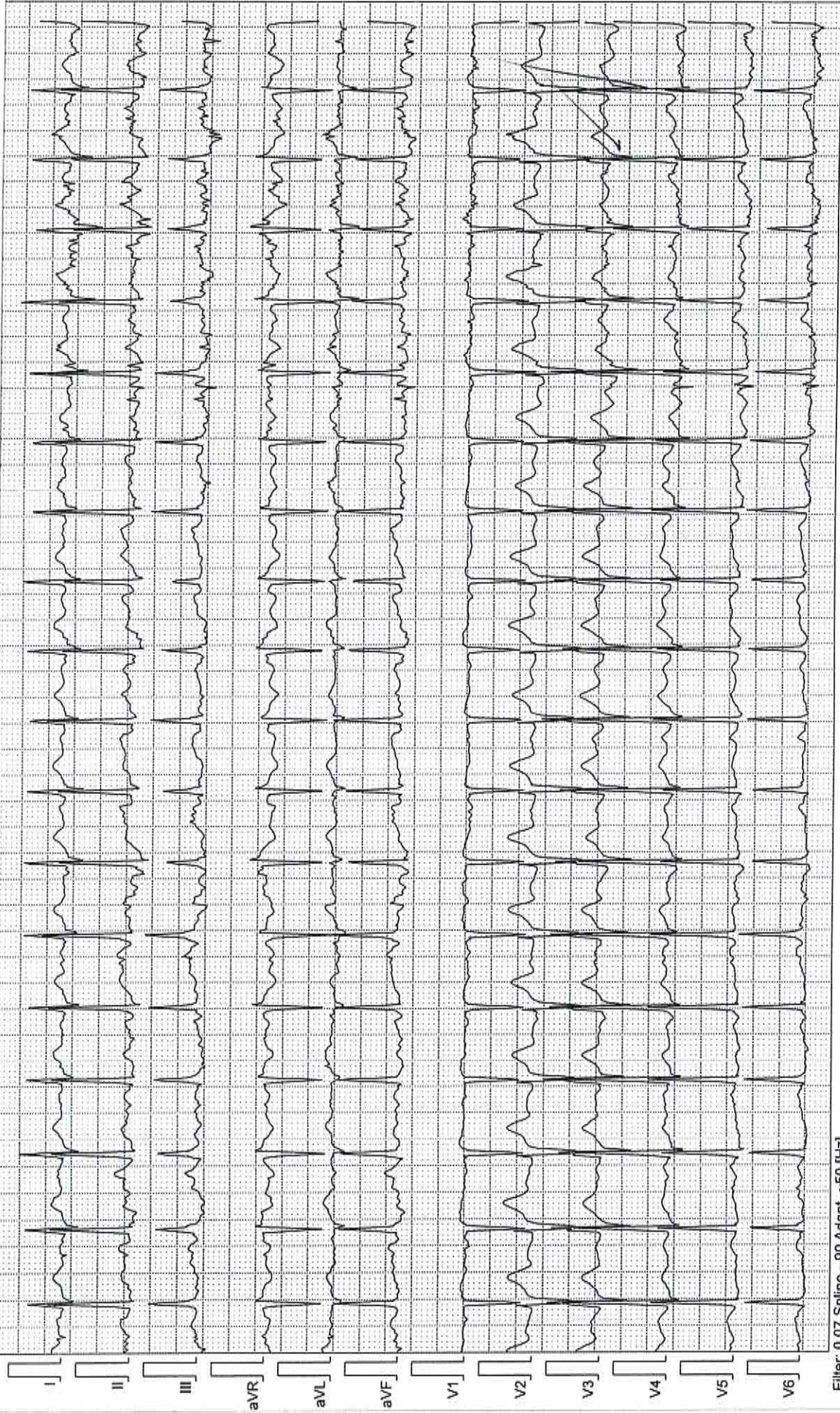
ID 01031455, Born: 03/02/1983(Male 33), 68 kg, 167 cm
Test Date: 26/01/2017 10:04:34

MEDIKA PLAZA



Time: E 05:56 - E2

Load: 7,0MET, HR: 108bpm, BP: 130/80



Filter: 0.07 Spline - 90 Adapt, -50 [Hz]

25,00 mm/Sec 10,0 mm/mV

MEDIKA PLAZA

CardioPoint 2.23.18524.0, DIAG 1.7.17214.0, ECG-071D-B-05775

CardioPoint - Stress Test

Page: 4



Syaiful, Mr

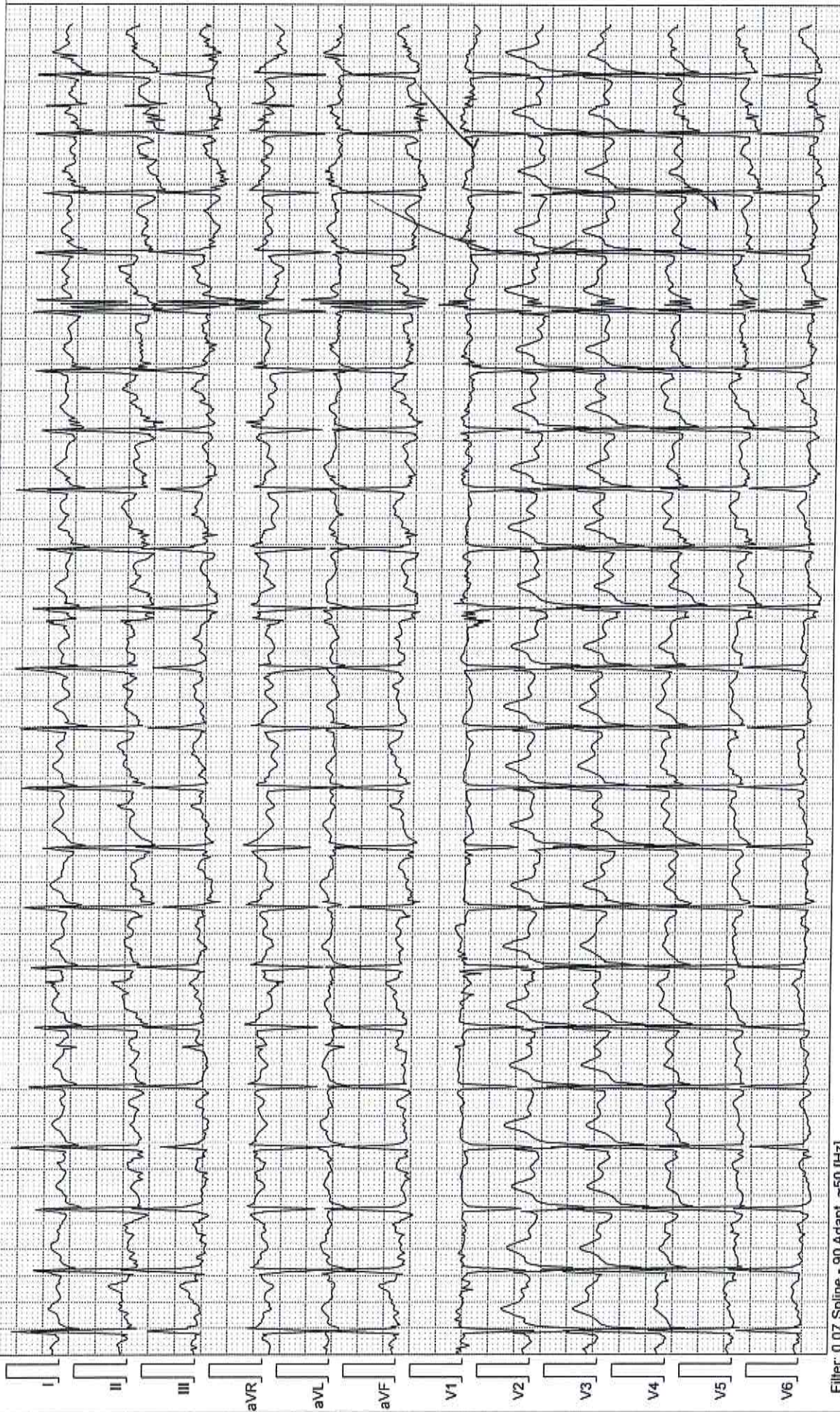
ID: 01031455, Born: 03/02/1983 (Male 33), 68 kg, 167 cm
Test Date: 26/01/2017 10:04:34

MEDIKA PLAZA



Time: E 08:55 - E3

Load: 10,1 MET, HR: 130bpm, BP: 140/90



Filter: 0.07 Spline - 90 Adapt, -50 [Hz]

25,00 mm/sec 10,0 mm/mV

MEDIKA PLAZA

CardioPoint 2.23.18524.0, DIAG 1.7.17214.0, ECG:071D-B-05775

CardioPoint - Stress Test


Page: 5



Syaiful, Mr

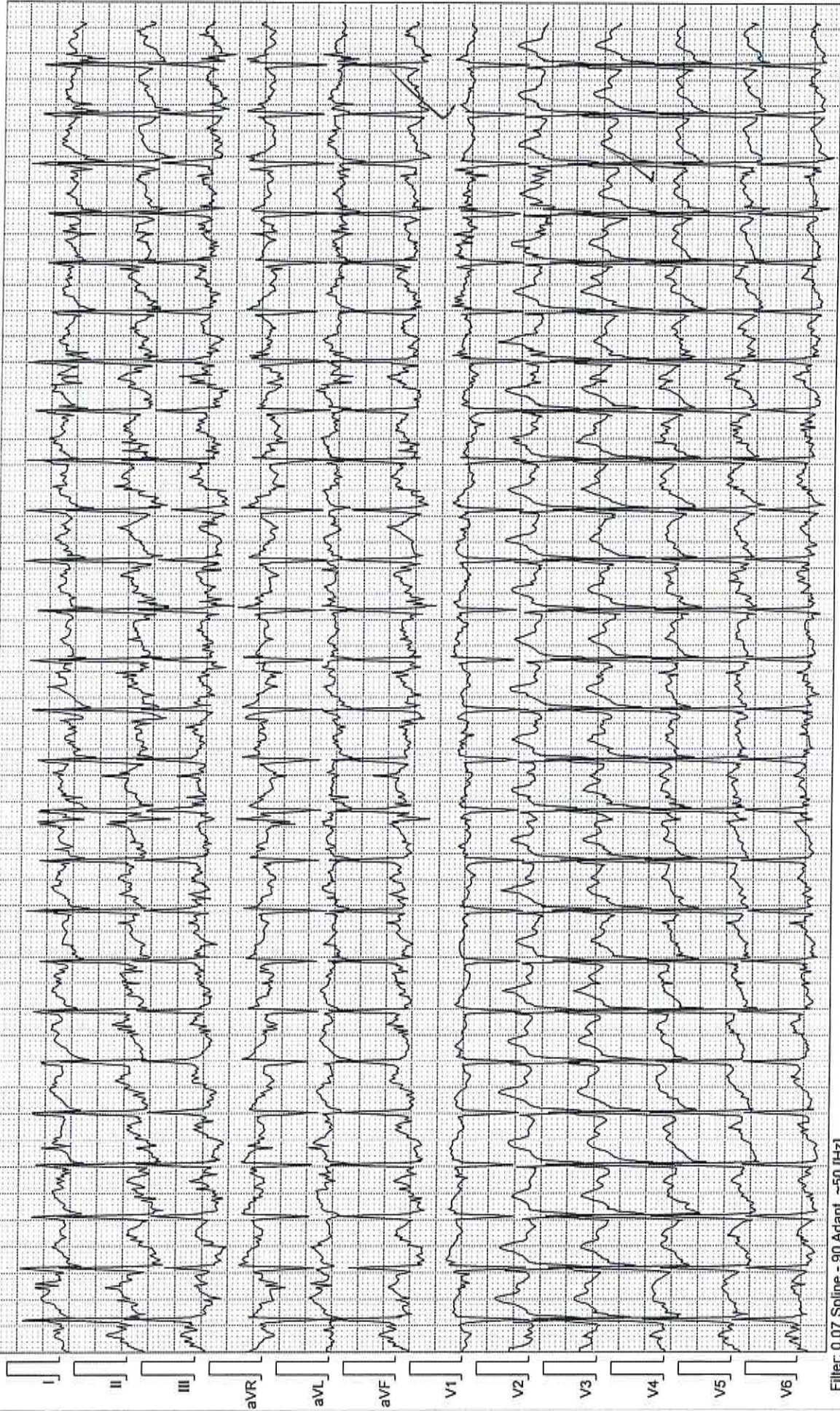
ID: 01031455, Born: 03/02/1983(Male 33), 68 kg, 167 cm
Test Date: 26/01/2017 10:04:34

MEDIKA PLAZA



Time: E 09:59 - Peak

Load: 13,4MET, HR: 154bpm, BP: -



Filter: 0.07 Spline - 90 Adapt, -50 [Hz]

25,00 mm/sec 10,0 mm/mV

MEDIKA PLAZA

CardioPoint 2.23.18524.0, DIAG 1.7.17214.0, ECG:071D-B-05775

CardioPoint - Stress Test

Page: 6



Syaiful, Mr

ID 01031455, Born: 03/02/1983(Male 33), 68 kg, 167 cm
 Test Date: 26/01/2017 10:04:34

MEDIKA PLAZA



Stage	Time	Load		HR bpm	BP mmhg	SpO2 %	ST Level [mV], J+: 1/8RR												
		km/h	%				MET	I	II	III	aVR	aVL	aVF	V1	V2	V3	V4	V5	V6
Reference	P 00:17	0,8	0,0	1,4	112	120/85	-	-0,06	-0,05	0,01	0,06	-0,02	-0,02	0,00	-0,01	-0,03	-0,03	-0,02	-0,02
E 1 step	E 03:01	2,7	10,0	4,6	90	120/85	-	0,03	0,02	0,00	-0,03	0,01	0,01	0,07	0,18	0,12	0,04	0,00	-0,02
E 2 step	E 06:01	4,0	12,0	7,0	108	130/80	-	0,02	-0,01	-0,02	0,00	0,02	-0,02	0,07	0,13	0,09	0,01	-0,02	-0,03
E 3 step	E 09:00	5,4	14,0	10,1	129	140/90	-	0,02	0,02	0,00	-0,02	0,01	0,01	0,06	0,11	0,04	-0,02	-0,02	-0,01
E 4 peak	E 10:04	6,7	16,0	13,4	153	-	-	-0,03	-0,23	-0,21	0,12	0,08	-0,22	0,14	0,12	0,04	-0,06	-0,10	-0,08



CONSULTATION SHEET

PATIENT NAME : Syaiful
 No. RM : 01031455
 Klinik/MCU/HCU : CO' E.N.T.

To, Dokter
 (Counsel)

Kindly please counsel for patient who has take cares of

Diagnose :
 Klinik Summary :

Counsel Request :

Patient had History ear discharge when he's child, & nose Injury 70 years ago

COUNSEL ADVISE

Finding :
 Ear : Membran tympanic intact post perforation Bilateral.
 Nose : Deviated septum spina Right & left.
 Throat : Posterior pharyngeal granulae hyperemic
 Audibility : Hearing threshold within normal limit.
 Decreasing in Freq. 25, 600, 8000 Hz Left ear.

Diagnosis :
 Pharyngitis chronic, deviated septum,

Reccomendation

- Stop smoking
- Avoid water activity.
- Using Ear protection when working in noisy Area

Date : 26/01/2017
Time :
EP :

Signataure

 PT. KARTIKA BINA MEDIKATAMA
 Complete Name

SURAT JAWABAN MEDIS

Kepada Yth.
dr. Eric PA Siswanto / dr. Endi B Setyawan
Di ConocoPhillips Indonesia

Berdasarkan hasil pemeriksaan kami terhadap pasien di bawah ini

Nama : Syaiful PTS 16307578
Umur : 33 thn
Jenis kelamin : Laki-laki
Pekerjaan : Karyawan PT. Slumberger

Didapatkan:

Anamnesa:

Neuralgia
Miel

Pemeriksaan Fisik:

W/O abdomen

Pemeriksaan laboratorium dan atau penunjang lainnya:

Sp. 11587 : 10/10 T6 9u

Diagnosa:

- Fatty liver
- Kolelitiasis

Terapi yang diberikan:

Udohex 3x1000
Cephalosporin 1x1000
blu April 2017

Kesimpulan terhadap kondisi klinis pasien saat ini:

Kondisi Kesehatan Pasien Stabil
Pemeriksaan Udohex 3x1000 (demon. 3x1000) efektif

Untuk dapat kembali bekerja (return to work), kami menyerahkan penilaiannya kepada dokter perusahaan yang lebih memahami aspek aspek kesehatan dan keselamatan kerja di tempat kerja yang bersangkutan.

baik
p. 10/10
Abdomen
stabil

....., 24 / 07 / 2017

Dokter Pemeriksaan

dr. dr. Ida Melani Santoso, Sp.PD.
Hp. Dokter Spesialis Penyakit Dalam
503/48/Dinkes/Sp/2015

