

Certificate Of Health Assessment



Name	Age	Position	Department
ACHMAD CHOIRONI	33 Years Old	INSPECTOR	TESTING

COMPANY :

INSPEKTINDO SINERGI PERSADA

CONCLUSION

Fit for work to the job described	✓
Fit with Medical Note (Restriction and/or Limitation)	
Unfit for work to the job described	

Date	Doctors Name	Signature
21 November 2016	Amiruddin, MD	  PT. KARTIKA BINA MEDIKATAMA

No. Formulir : FM-DR-008-05
 No. Revisi : 00
 Tanggal Terbit : 2 Mei 2011

MEDIKA PLAZA CLINIC

Kartika Chandra - Office Tower 3rd Floor
Jl. Jend. Gatot Subroto, Kav. 18-20 Jakarta Selatan 12940
Tlp : (62-21) 525 1207, Fax : (62-21) 521 0815
Appointment Hotline (62-21) 528 80088
www.medikaplaza.com

PATIENT DATA

MedRec.	: 01035755	EMPLOY. STATUS	: Employee
NAME	: ACHMAD CHOIRONI	BIRTHDATE	: 02 March 1983
EMPLOYEE No.	:	SEX	: Male
JOB TITLE	: INSPECTOR	STATUS	: Married
COMP. NAME	: INSPEKTINDO SINERGI PERSADA	NASIONALITY	: Indonesia

SUMMARY

MEDICAL FINDING :

1. Hypertriglyceridemia with fatty liver
 2. Increase ESR count
 3. Non reactive anti HBs
 4. Spirometri : Mild restrictive & mild obstructive
 5. Overweight
 6. Moderate hearing disorder of right ear & mild hearing disorder of left ear
 7. Decayed, calculus teeth
- our fitness status is fit for work to the job described

SUGGESTION :

1. Low fat and carbohydrate diet, exercise regularly minimal 3 times a week
2. Repeat ESR test 1 month later
3. You need to get Hepatitis B vaccination
4. See a pumonologist if any complaint of spirometry result. Avoid dust and fumes, use face mask while working at dusty area
5. Reduce body weight gradually 0.5 Kgs/week, by doing regular exercise (aerobic/jogging), 3-4x/week, 30-45 minutes and reduce high calorie diet until maximal body weight is 60.84 Kgs (present body weight is 67.9 Kgs)
6. Avoid noisy environment or use earplug properly while working at noisy work environment to prevent further of hearing impairment
7. See a dentist for dental care minimal once a year or better once in 6 month

Responsible Doctor

Amiruddin, MD

Notes:

you need the further information or consultation, please contact us via :

Email : - kcdoctor01@medikaplaza.com
- dr.yosephine@medikaplaza.com

Clinic Number : (021) 5251207

PRIVATE

Printed by : hanna

CLINICAL EVALUATION

Name : ACHMAD CHOIRONI

Sex : Male

MR : 01035755

Visit : 21/11/2016

Comp. : INSPEKTINDO SINERGI PERSADA

DOB : 02 March 1983

EXAMINATION

RESULT

NOTES

PHYSICAL EXAMINATION

PRESENT COMPLAINT

Present complaint

Cough 2 days

MEDICAL HISTORY

Alergy

Yes

Cold weather

Imunisasi

Yes

Surgery

Yes

Nose bone fractur surgery

Hospitalization

Yes

Nose bone fractur

Disease

No

LIFE STYLE

Alcohol intake

No

Smoking

No

Exercise

Yes

2x/week

Appetite

Good

FAMILY MEDICAL HISTORY

Diabetes Melitus

No

Father

Hypertension

No

Heart disease

No

Lung TB

No

Kidney disease

Yes

Mother

Astma

Yes

Father

Mental disease

No

Epilepsy

No

Chronic skin disease

No

Cancer

No

Color blind

No

Stroke

No

Liver disease

No

Bone & joint

No

Pulmonary disease

No

Others disease

No

WORK EXPOSURE

Noise

Yes

Heat Stress

Yes

Cold Stress

No

Vibration

Yes

Dust

Yes

CLINICAL EVALUATION

Name : ACHMAD CHOIRONI

Sex : Male

MR : 01035755

Visit : 21/11/2016

Comp. : INSPEKTINDO SINERGI PERSADA

DOB : 02 March 1983

EXAMINATION	RESULT	NOTES
Toxic chemical	Yes	
Iritating fluid	No	
Heat Stress	No	
Operating heavy mobile equipment	No	
Working arround rotating machinery	No	
Requires color vision	Yes	
Involving height	Yes	
Administration work	Yes	
Handling food product	No	
Others	No	
GENERAL		
General Appearance	Good	
Nutrition Status	Normal	
VITAL SIGN		
Body Weight	67.9 Kg	
Body Height	156 Cm	
BMI	27.9 Kg/m2	
Normal Weight	45.02 - 60.84 Kg	
BMI Conclusion	Overweight	
Blood Pressure	110/80 mmHg	
Pulse	64 x/minute	
Body Temperature	36.4 °C	
RR	20	
Neck Circumference	-	
Arm Circumference	-	
Chest size	-	
Abdominal Circumference	-	
SKIN		
Skin	Normal	
Pale	No	
Jaundice	No	
EYE		
Left	Normal	
Right	Normal	
ENT		
Auricle	Normal	
Ear canal	Normal	

CLINICAL EVALUATION

Name : ACHMAD CHOIRONI	Sex : Male	MR : 01035755	Visit : 21/11/2016
Comp. : INSPEKTINDO SINERGI PERSADA		DOB : 02 March 1983	

EXAMINATION	RESULT	NOTES
Drums	Normal	
Septum/Conchae	Normal	
Sinuses	Normal	
Pharynx	Normal	
Tonsil	Normal	
MOUTH		
Gum	Normal	
Dental	Abnormal	Decayed, calculus teeth
NECK		
General	Normal	
Thyroid Gland	Normal	
CHEST		
Form	Normal	
Expansion	Normal	
Lung	Normal	
Heart	Normal	
Breast	Normal	
Heart sound	Normal	
Murmurs	Normal	
ABDOMEN		
Form	Flat	
Palpation	Supple	
Liver	Not Palpable	
Spleen	Not Palpable	
Kidney	No Ballotment	
Hernia inguinal	No	
EXTRIMITIES		
Bones, joint	Normal	
Muscles, tonus	Normal	
Fingernails	Normal	
Hand	Normal	
Foot	Normal	
RECTAL EXAMINATION		
Hemorrhoid	Negative	
Rectum	Normal	
NEUROLOGICAL EXAMINATION		
Motoric function	Normal	

CLINICAL EVALUATION

Name : ACHMAD CHOIRONI

Sex : Male

MR : 01035755

Visit : 21/11/2016

Comp.: INSPEKTINDO SINERGI PERSADA

DOB : 02 March 1983

EXAMINATION	RESULT	NOTES
Sensoric function	Normal	
Coordination	Normal	
Physiologic reflex	Normal	
Extra piramidal function	Normal	
LYMPHE SYSTEM		
Neck Gland	Normal	
Armpit gland	Normal	
Inguinal	Normal	

OPHTHALMOLOGY DIAGNOSTIC

Name : ACHMAD CHOIRONI		Sex : Male	MR : 01035755	Visit : 21/11/2016
Comp. : INSPEKTINDO SINERGI PERSADA			DOB : 02 March 1983	
EXAMINATION		Right	Left	
Reading		-		
Previous Glasses		-		
Without Glasses	Distant	20/20	20/20	
	Near	-		
Correction	Distant	-		
	Near	-		
Tonometry		12.0 mmHg	12.0 mmHg	
Funduscopy		NORMAL	NORMAL	
Visual Fields		-		
Colour Blind Test		Normal		

pression : Excoriasi palpebra superior A/R Super cilia OD

RADIOLOGY DIAGNOSTIC

Name : ACHMAD CHOIRONI

Sex : Male

MR : 01035755

Visit : 21/11/2016

Comp. : INSPEKTINDO SINERGI PERSADA

DOB : 02 March 1983

EXAMINATION**RESULT**

Thorax PA

No abnormality seen in both lungs.
Normal bronchovascular markings in both hili.
The heart is normal in size and shape.
The mediastinum is not widened.
Both sinus and diaphragms are good.
No evidence of pleural effusion.

Impression

Normal chest.
No evidence of specific process in both lungs.

RADIOLOGY DIAGNOSTIC

Name : ACHMAD CHOIRONI	Sex : Male	MR : 01035755	Visit : 21/11/2016
Comp. : INSPEKTINDO SINERGI PERSADA	DOB : 02 March 1983		

EXAMINATION	RESULT
-------------	--------

UPPER-LOWER ABDOMEN
SONOGRAPHY

LIVER:
Normal in size. Liver tip is acute, there are increase attenuation of parenchymal echostructures which are homogeneous. No sign of SOL.
Intrahepatic vascularity and biliary tract are normal.

GALL BLADDER:
Normal in size, contour and surface. No sign of SOL/ sludge/ stone.

RIGHT KIDNEY:
Normal in size, contour and surface. No sign of obstruction/ stone/ SOL.

LEFT KIDNEY
Non visualized , suspect atropy/hypotropi

PANCREAS:
Normal in size, contour and surface. No sign of SOL.

LIEN:
Normal in size and contour, the echoes are homogenous. No sign of SOL.

URINARY BLADDER:
Normal in size, contour and surface. No sign of stone/ SOL.

PROSTATE AND VESICULA SEMINALIS:
Normal in size and contour which are homogenous echoes and no sign of focal lesion/ SOL.

Impression

Fatty liver

LABORATORY RESULT

Name : ACHMAD CHOIRONI	MR : 01035755	Visit : 21/11/2016	#Lab : IN577329992026
Comp. : INSPEKTINDO SINERGI PERSADA	Sex : Male	DOB : 02 March 1983	

EXAMINATION**RESULT****NORMAL RANGE****HEMATOLOGI****Automated Blood Count**

White Blood Cell (WBC)	9.9	3.8 - 11.0
Erythrocyte (RBC)	5.4	4.4 - 5.9
Haemoglobin	15.1	13.2 - 17.3
Hematocrit	43	40 - 52
Thrombocytes	287	150 - 440

MCV, MCH, MCHC

MCV	80	80 - 100
MCH	28	26 - 34
MCHC	35.4	32 - 36
ESR	33 *	0 - 10

Differential Count

Basophils	0	0 - 1
Eosinophil	9 *	2 - 4
Bands / Stab	1 *	3 - 5
Neutrophils	51	50 - 70
Lymphocytes	33	25 - 40
Monocytes	6	2 - 8

BLD CHEMISTRY/LIPID PROFILE

Total Cholesterol	156	Normal/Desireable: <200 Borderline High: 200-239 High: >=240
HDL Cholesterol	31.4 *	Normal : >40 - <60 Low HDL : <40 Desireable : >=60
LDL Cholesterol	88	Optimal: <100 Near/Above Optimal: 100-129 Borderline High: 120-159 High: 160-189 Very High: >=190
T.Cholesterol/HDL Ratio	4.97	Low risk : < 3.5 Medium risk : 3.5 - 5.0 High risk : > 5.0

LABORATORY RESULT

Name : ACHMAD CHOIRONI	MR : 01035755	Visit : 21/11/2016	#Lab : IN577329992026
Comp. : INSPEKTINDO SINERGI PERSADA	Sex : Male	DOB : 02 March 1983	

EXAMINATION	RESULT	NORMAL RANGE
Tryglicerides	182 *	Normal : <150 Borderline High: 150-199 High : 200-499 Very High : >=500

BLD CHEMISTRY/KIDNEY FUNCTION

Ureum	27.4	10.0 - 50.0
Creatinine	0.9	0.6- 1.3
Uric Acid	5.8	3.5 - 7.2

BLD CHEMISTRY/LIVER FUNCTION

Total Bilirubin	0.7	0.1 - 1.0
SGOT(AST)	23	13 - 45
SGPT (ALT)	27	13 - 50
Alkaline Phosphatase	50	30 - 120
Gamma GT	29	0 - 50
Albumin	4.4	3.5 - 5.5
Albumin/Globulin Ratio	1.83	1.20 - 2.20
Globulin	2.40	2.3 - 3.5
Total Protein	6.8	6.6 - 8.7

BLD CHEMISTRY/DIABETES**Fasting Glucose**

Glucose Fasting	75	< 100
Glucose Urine	Negative	Negative
Keton Urine	Negative	Negative

Blood Glucose 2 PP

Blood Sugar 2 Hours PP	64	< 140
Glucose Urine	Negative	Negative
Keton Urine	Negative	Negative

SEROLOGI / IMUNOLOGI

HBsAg	Non Reactive	Non Reactive
Anti HBs	Non Reactive	
VDRL	Negative	Negative

TOXICOLOGY - DRUGS SCREENING

THC/Marijuana	Negative	Negative
MDMA	Negative	Negative
Amphetamine	Negative	Negative
Opiat	Negative	Negative
Cocain	Negative	Negative

LABORATORY RESULT

Name : ACHMAD CHOIRONI	MR : 01035755	Visit : 21/11/2016	#Lab : IN577329992026
Comp. : INSPEKTINDO SINERGI PERSADA	Sex : Male	DOB : 02 March 1983	

EXAMINATION	RESULT	NORMAL RANGE
-------------	--------	--------------

Alcohol	Negative	Negative
---------	----------	----------

URINALYSIS**Complete Urine Analysis****Macroscopic**

Color	Light Yellow	
Turbidity	Clear	Clear
Specific Gravity	1.019	1.000 - 1.030
pH	6.0	4.5 - 8.0
Leucocyte	Negative	Negative
Glucose	Negative	Negative
Nitrit	Negative	Negative
Bilirubin	Negative	Negative
Blood	Negative	Negative
Urobilinogen	Normal	Negative
Protein	Negative	Negative
Keton	Negative	Negative

Microscopic

RBC	0-1	0 - 1
WBC	0-1	0 - 4
Cylinder	Negative	
Epithels Squamous	0-1	5 - 15
Crystals	Negative	
Bacteria	Negative	Negative
Others	Negative	

SPIROMETRY DIAGNOSTIC

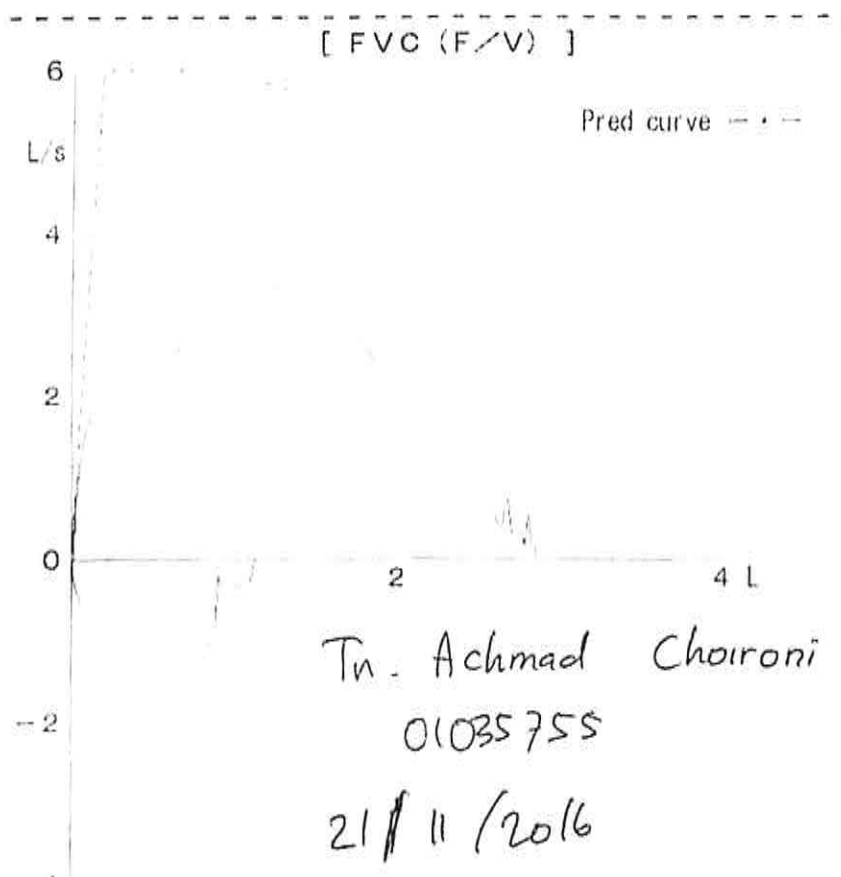
Name : ACHMAD CHOIRONI	Sex : Male	MR : 01035755	Visit : 21/11/2016
Comp. : INSPEKTINDO SINERGI PERSADA		DOB : 02 March 1983	

EXAMINATION	RESULT
FVC Result	: 2.86 L---> 76.7 %
FEV1 Result	: 2.45 L---> 74.7 %
FEV1/FVC Result	: 85.66 %---> 107.8 %
PEF Result	: 3.36 L/S---> 33.3 %
Indonesian Standart Result	:
Index	:
Spirometry Result	: Abnormal

Impression : Restriksi Paru Ringan & Obstruksi Paru Ringan

[COPD CLASSIFICATION]

FEV1/FVC : 85.66 %
 %FEV1.0 : 74.70 %
 Stage : Normal
 Recommended treatment by GOLD :



AUDIOMETRY DIAGNOSTIC

Name : ACHMAD CHOIRONI

Sex : Male

MR : 01035755

Visit : 21/11/2016

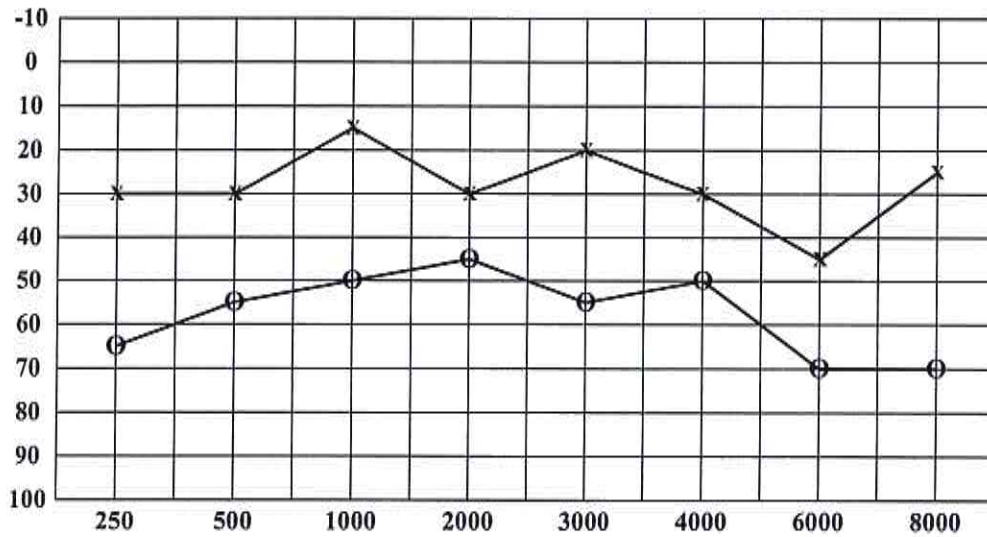
Comp. : INSPEKTINDO SINERGI PERSADA

DOB : 02 March 1983

RESULT

Left Ear	250	500	1000	2000	3000	4000	6000	8000
AC	30	30	15	30	20	30	45	25
BC	-	-	-	-	-	-	-	-

Right Ear	250	500	1000	2000	3000	4000	6000	8000
AC	65	55	50	45	55	50	70	70
BC	-	-	-	-	-	-	-	-



< : Right Ear (BC)

> : Left Ear (BC)

O : Right Ear (AC)

X : Left Ear (AC)

Conclusion Right Ear : Moderate hearing disorder = 50 dB
 With decreasing on frequency
 250Hz, 4000Hz, 6000Hz, 8000Hz

Conclusion Left Ear : Mild hearing disorder = 26.25 dB
 With decreasing on frequency 250Hz, 4000Hz,
 6000Hz

CARDIOLOGY DIAGNOSTIC

Name : ACHMAD CHOIRONI	Sex : Male	MR : 01035755	Visit : 21/11/2016
Comp. : INSPEKTINDO SINERGI PERSADA		DOB : 02 March 1983	

EXAMINATION	RESULT	Comments :
-------------	--------	------------

ELECTROCARDIOGRAPHY	Sinus Rythm axis (N), P wave (N), PR int 0.16" ST - T segment (N), aritmia (-)	Normal ECG
---------------------	---	------------

TREADMILL	Sinus Rythm axis (N), P wave (N), PR int 0.16" ST - T segment (N), aritmia (-)	Treadmill Exercise Test : Negative Cardiopulmonary Fitness Classification : Good METs : 11.8
-----------	---	---

11-21-2016 11:12

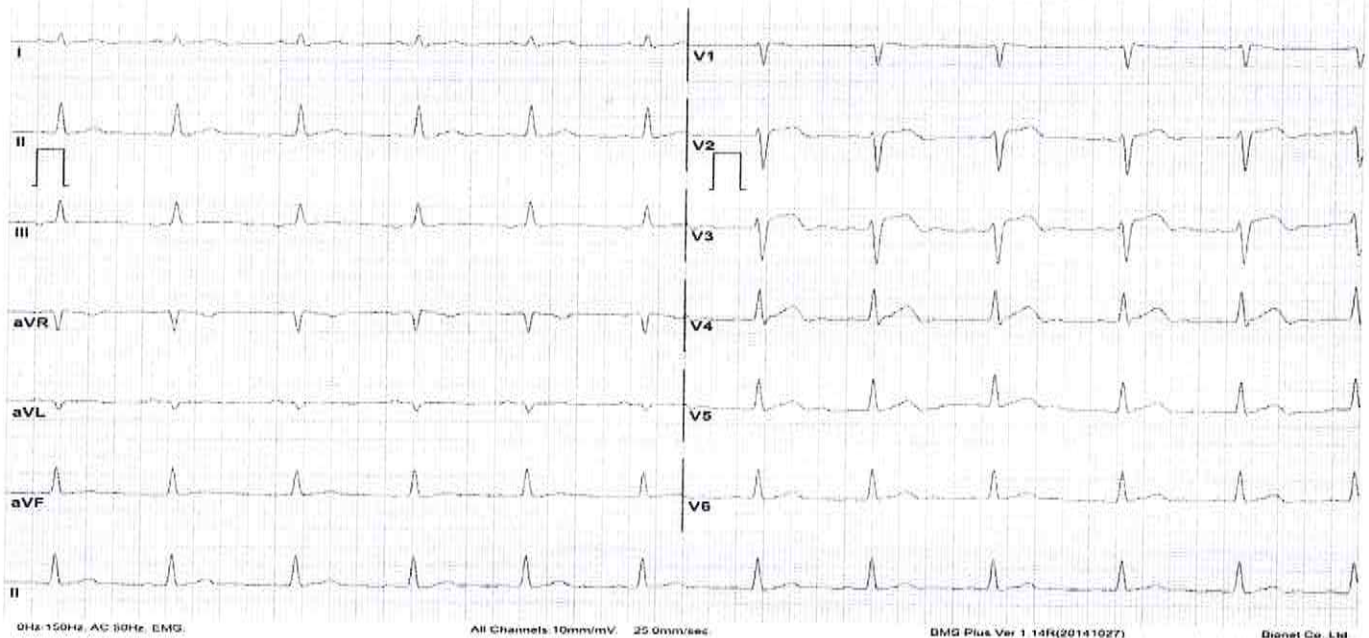
ID :
Name :
Age yrs Sex :
H : 0ft 0inch W : 0lbs

Heart Rate : 69 bpm
HR int : 162 ms
QRS dur : 98 ms
QT/QTc : 406/433 ms
P-R-T axis : -10-70-22

6Channel + 1 Rhythm Report

*** Analysis Result *** (Unconfirmed Report)
Normal Sinus Rhythm
Normal Axis
[Normal ECG]
*** Doctor's Comment ***

Hospital : MEDIKA PLAZA
Confirmed by :



Name: MR AHMAD CHOIRONI
ID: INSPEKTINDO

11/21/2016 10:40

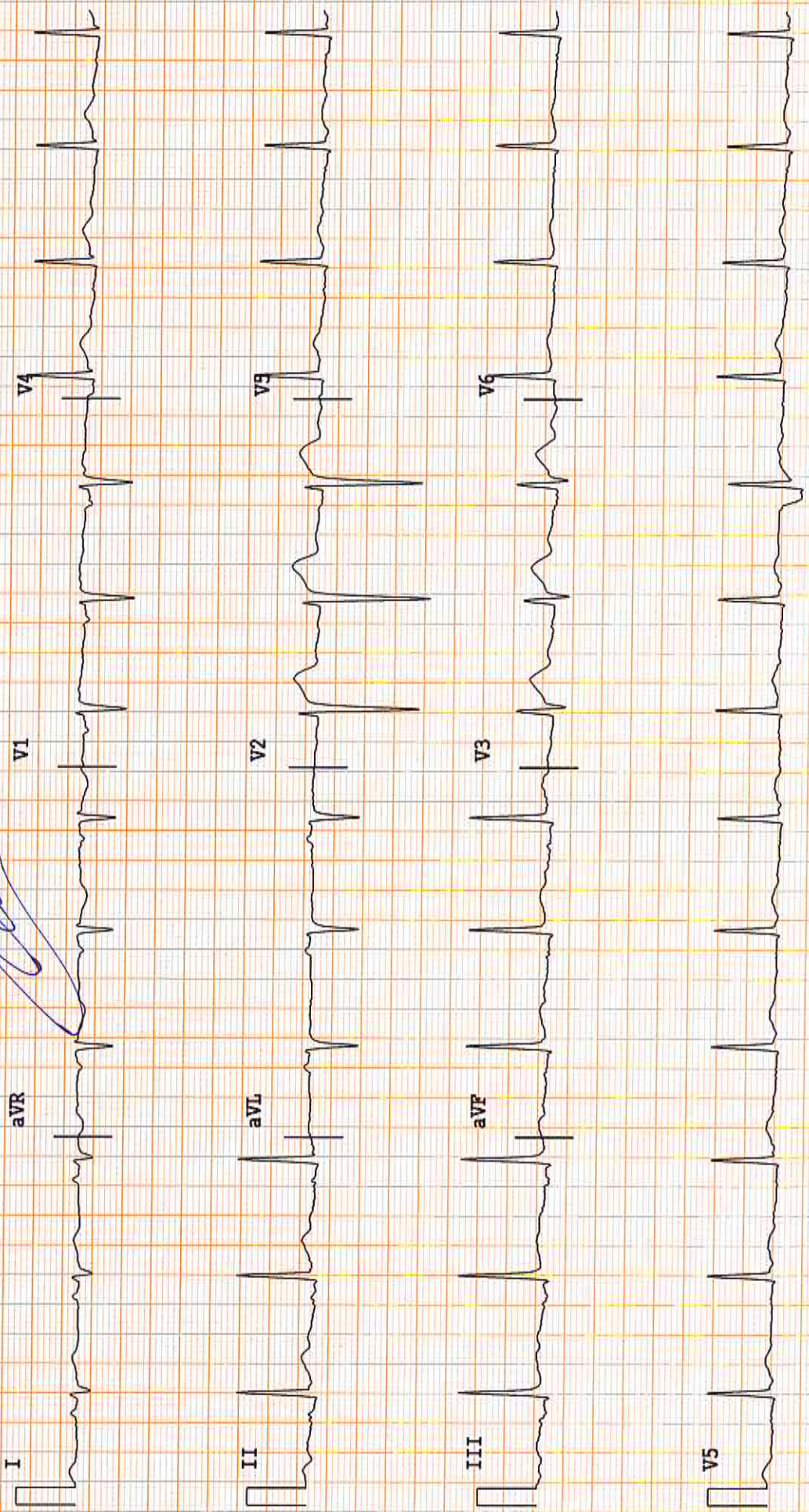
HR: 79
BP: 110/80
Medication(s): No Medication
EP: : No Medication
Age: 33 Years
Clin. Class: Normal
Gender: Male
Race: Oriental
Department: MEDIKA PLAZA
Height: 156 cm
Technician: Nr. Jeni Emil
Weight: 67 Kg
Physician: Dr. Adolf DSJP

Baseline ECG

[Handwritten Signature]

Levels measured at 80ms Post-J Levels in mm Slope in uV/mS

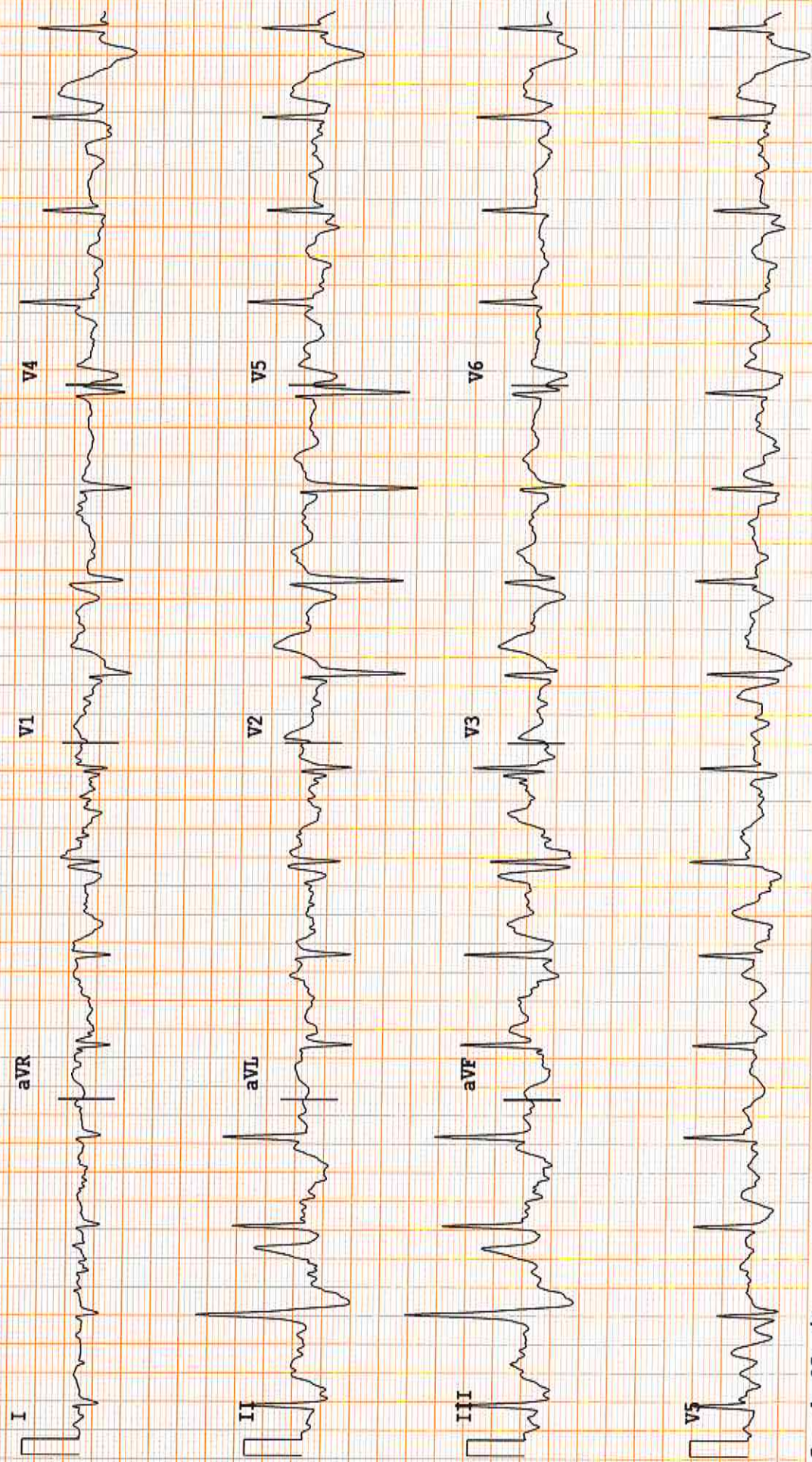
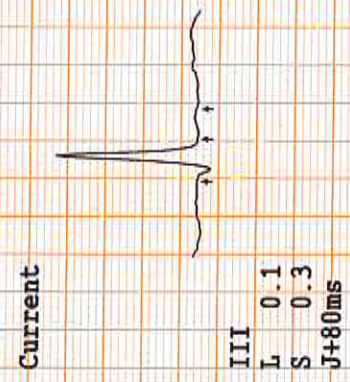
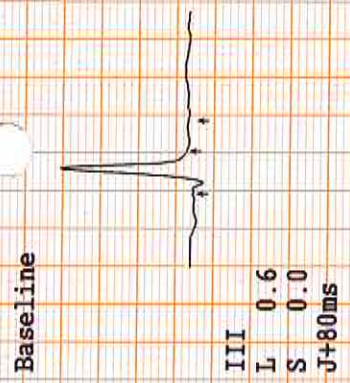
Lead	L	S	I	aVR	V1	V4
I	0.4	0.8	0.4	-0.4	0.9	1.4
II	1.0	0.6	0.8	-0.1	0.0	0.3
III	0.6	0.0	0.4	0.4	3.0	0.9
aVL	0.8	0.3	0.4	0.4	1.4	-0.1
aVF	0.6	0.0	0.4	0.8	2.7	0.5
V2	0.6	0.0	0.4	0.3	1.2	-0.1
V3	0.6	0.0	0.4	0.8	2.7	0.5
V4	0.6	0.0	0.4	0.3	1.2	-0.1



Name: MR AHMAD CHOIRONI
 ID: INSPEKTINDO
 ER: 93 Phase: Exercise
 EP: 110/80 Exercise Time: 02:50
 RPE: Stage/Time: 1/02:50
 METs: 4.5 Workload: 2.7 kmh 9.9 % grade
 Protocol: Bruce

11/21/2016 10:43

Worst Case S-T Depression



Name: MR ACHMAD CHOIRONI
ID: INSPEKTINDO

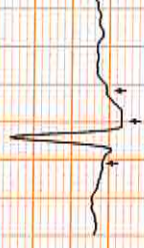
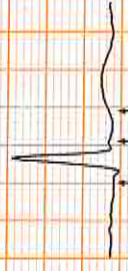
11/21/2016 10:46

HR: 105 Phase: Exercise
BP: 110/90 Exercise Time: 05:50
RPE: Stage/Time: 2/02:50
METs: 6.8 Workload: 4.0 kmh 12.0 % grade
Protocol: Bruce

Worst Case S-T Depression

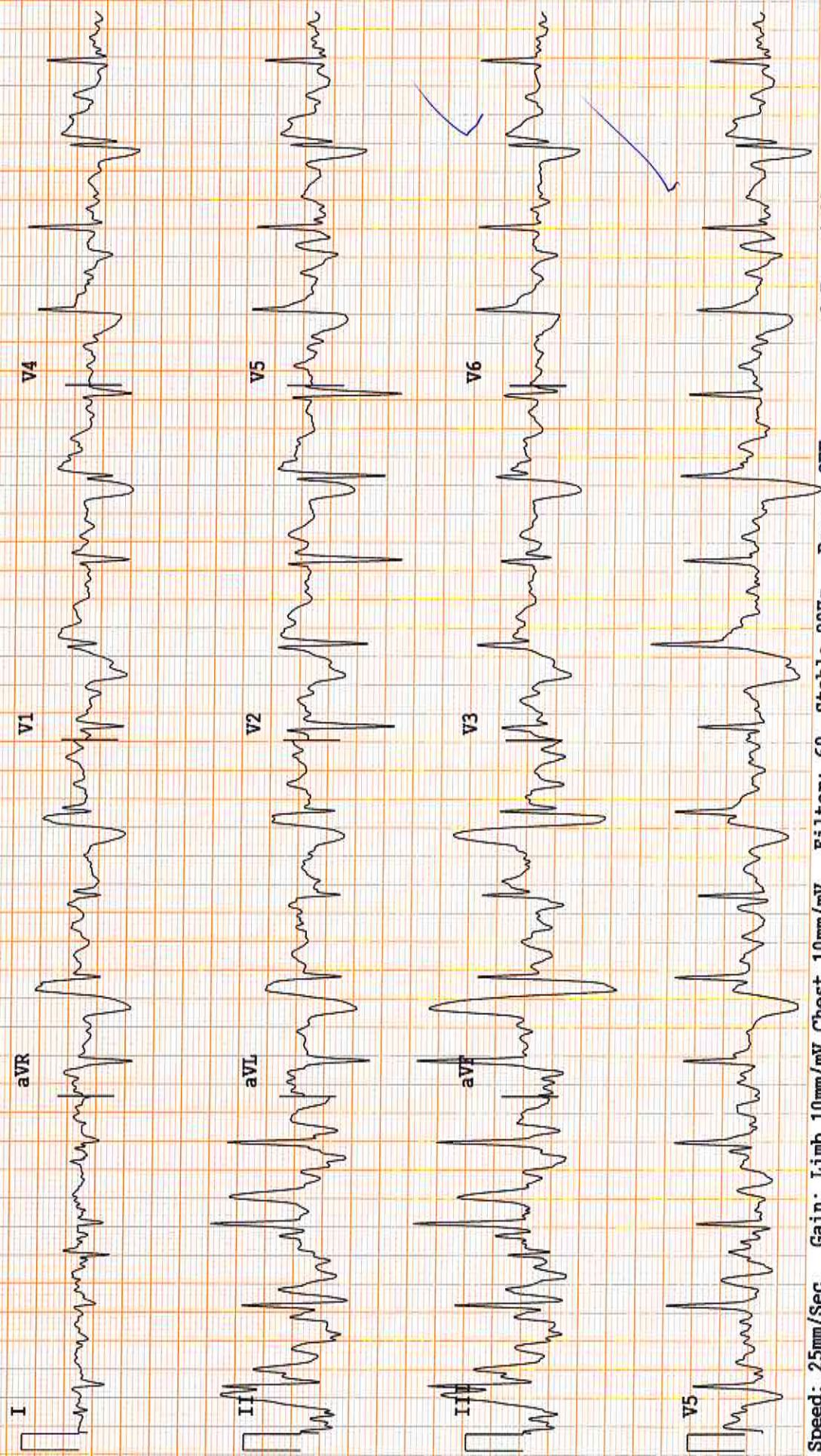Baseline

Current



V5
L 0.9
S -0.1
J+80ms

V5
L -0.4
S 3.1
J+80ms



Name: MR AHMAD CHOIRONI
ID: INSPEKTINDO

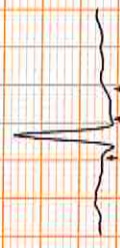
11/21/2016 10:49

Worst Case S-T Depression

HR: 127
BP: 120/90
RPE: 10.0
METs: 10.0
Phase: Exercise
Exercise Time: 08:50
Stage/Time: 3/02:50
Workload: 5.4 kmh 14.0 % grade
Protocol: Bruce

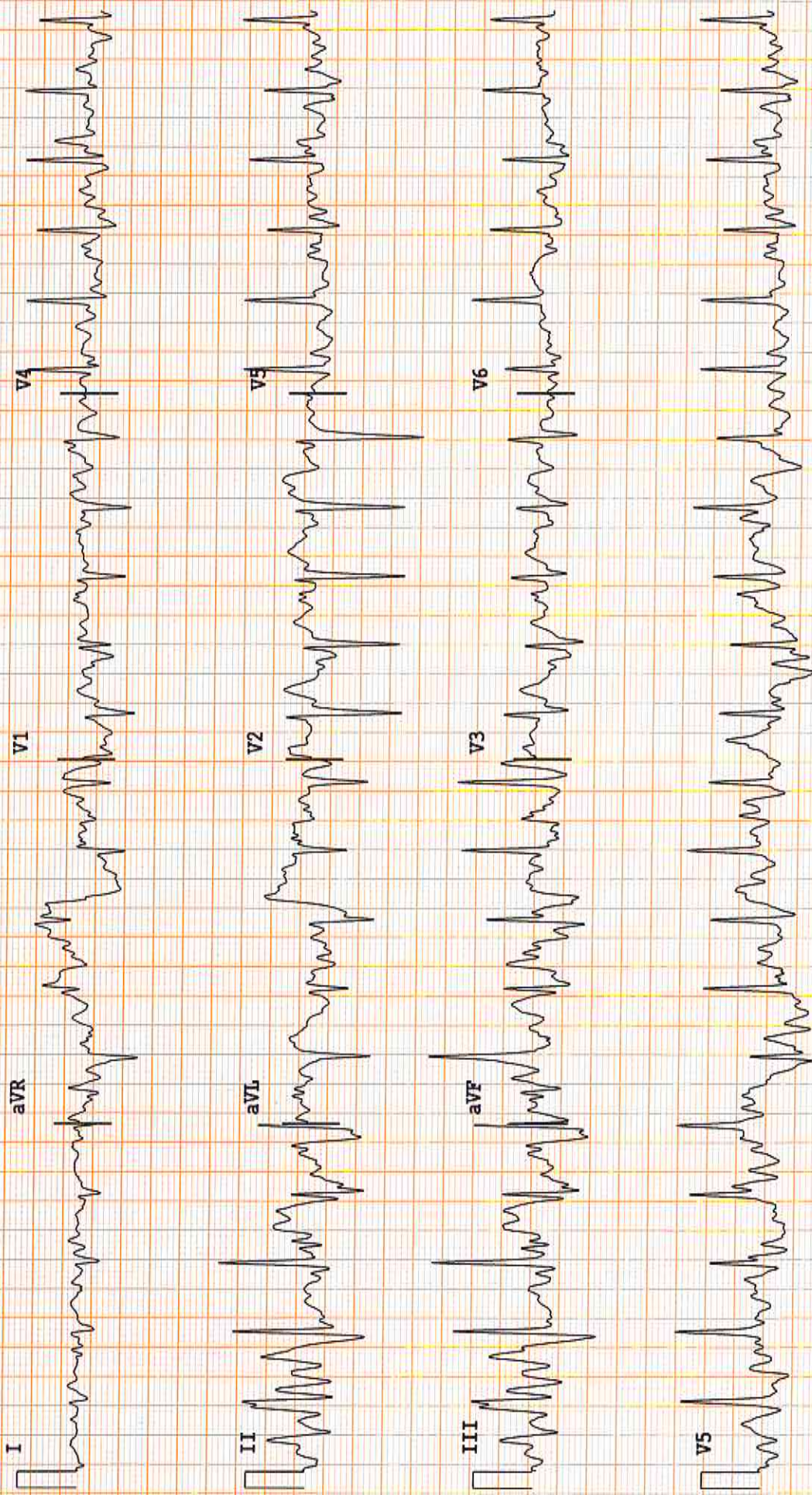Baseline

Current



V6
L 0.1
S 0.5
J+80ms

V6
L 0.5
S -0.1
J+80ms



Name: MR AHMAD CHOIRONI
 ID: INSPEKTINDO
 HR: 146
 BP: 120/90
 RPE: 11.8
 METs: 11.8

11/21/2016 10:50
 Maximum Exercise
 Exercise Time: 10:01
 Stage/Time: 4/01:01
 Workload: 6.7 kmh 16.0 % grade
 Protocol: Bruce

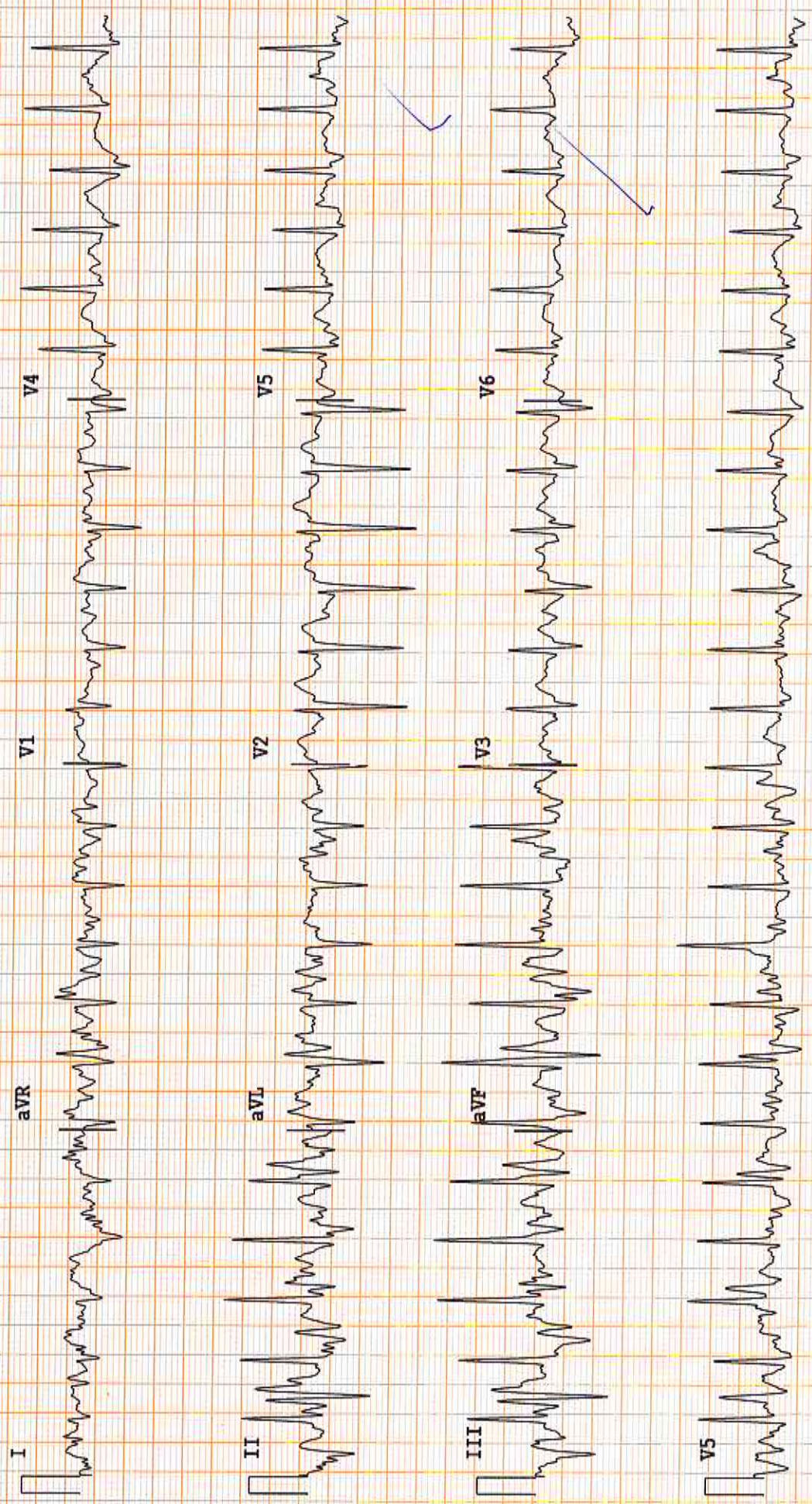
Worst Case S-T Depression

Current

III
 L 0.6
 S 0.0
 J+80ms

III
 L -2.4
 S 1.6
 J+80ms

MAXIMUM EXERCISE ECG



Name: MR ACHMAD CHOIRONI
 ID: INSPEKTINDO

FINAL REPORT TEST SUMMARY

11/21/2016 10:50

SUMMARY:

- The Bruce test ran for 10.01 mins. Peak METs was 11.8.
- A peak heart rate of 155 bpm was achieved at 10:01 mins in exercise.
- 83% of the 187 bpm max was reached.
- The peak BP was 120/90 (during Exercise). Baseline was 110/80.

S-T SEGMENT ANALYSIS:

- Lead V6 first exhibited ST depression exceeding 1mm at 00:30 of Exercise.
- ST depression exceeded 1mm for 00:50 mins.
- 2.5mm maximum depression in V6 was exhibited at 07:00 mins of Exercise.

Medication(s): No Medication
 : No Medication
 Clin. Class: Normal
 : Normal
 Department: MEDIKA PLAZA
 Technician: Nr. Jeni Emil
 Physician: Dr. Adolf DSJP

Protocol: Bruce

TIME	PHASE	KMH	GRADE	HR	BP	RPP	METS	ECTOPIC	RPE	EVENTS	COMMENTS
00:00	Exercise	0.6	0.0	80	110/80	88	1.0				
01:00	Exercise	2.7	9.9		110/80		2.1				
02:00	Exercise	2.7	9.9	93			4.4			2	
03:00	Exercise	2.7	9.9	93	110/80	102	4.5				
04:00	Exercise	4.0	12.0	102	110/80	112	5.7				
05:00	Exercise	4.0	12.0	106			6.8				
06:00	Exercise	4.0	12.0	103	110/90	113	6.8				
07:00	Exercise	5.4	14.0	116			8.5			1	
08:00	Exercise	5.4	14.0	121			10.0				
09:00	Exercise	5.4	14.0	126	120/90	151	10.0				
10:00	Exercise	6.7	16.0	155	120/90	186	11.8			1	
10:01	Max Exer.	6.7	16.0	155	120/90	186	11.8				
00:25	Recovery	2.0	0.0	136			9.5				

[Handwritten Signature]
 PT. SARTIKA BINA M. DIKATANA



CONSULTATION SHEET

PATIENT NAME : Achmad Chaironi
 No. RM : 01035755
 Klinik/MCU/HCU : CO'E-A.T

To. Dokter :
 (Counsel)

Kindly please counsel for patient who has take cares of

Diagnose :
 Clinic Summary :

Counsel Request :

COUNSEL ADVISE

Finding : Left & right ear: normal
 nose: normal
 Throat: normal

Diagnosis : Ear, nose & Throat within normal limit

Recomendation :

Date : 21/11/2016

Time :

EP :

PT. KARTIKA BINA MEDIKATAMA

dr. Ervin Amouzegar
 ENT Specialist
 Complete Name

Formulir Number : FM - DR - 008 - 02

Revisi Number : 00

Date : 2 Mei 2011