


Medical Screening Questionnaire And Examination Record

Surname: PARJULIAN NAPIYULLI		Forenames: TAMBAK.		
Address: Karet Kanya 3 No 7		Tel No: 021-5271313		
Date of Birth: 27 JULY 1974				
GP's Name:				
GP's Address:				
Date of Last Offshore Medical: April 2019		Offshore Occupation/Job Title :		
Emergency Response Role :				
Social / Occupational History		Yes	No	Comments
(1)	Do you smoke? If so, how many per day?	✓		1 pack / 12 per
(2)	If an ex-smoker, when did you give up?		-	
(3)	Average weekly alcohol consumption: state quantity and type.		✓	
(4)	Have you been exposed to any known occupational hazard such as noise, radiation, dusts, asbestos, chemicals or lead?	✓		
(5)	Do you use protective clothing, safety glasses or hearing protection?	✓		
(6)	Have you ever developed any medical condition in connection with your occupation? If so, please give details eg hearing loss/skin condition/wheeze/backache/muscle strain/blood disease?		✓	
(7)	Have you suffered any industrial injury? If so, please give details:		✓	
(8)	Have you ever had any previous audiometric screening? Was this normal? State when and where.		✓	
(9)	Have you ever had any previous lung function screening? Was this normal? State when and where.		✓	
(10)	Have you ever been rejected from employment on medical ground?		✓	
(11)	Have you ever received compensation, or is there any industrial claim pending?		✓	
(12)	Have you ever been medivaced from an offshore installation?		✓	
Examining Physician's comments :				

* Source : Medical Aspects of Fitness for Work Offshore Guidance for Examining Physicians Oil & Gas UK, March 2008

**Medical Screening Questionnaire And
 Examination Record (cont'd)**

Do you have, or have you been diagnosed as suffering from any of the following? <i>(Please circle and elaborate)</i>			
Please circle and elaborate			
(1) Chest pain/heart pain	Yes	No	
(2) High blood pressure / stroke	Yes	No	
(3) Asthma / Epilepsy/Diabetes	Yes	No	
(4) Peptic ulcer disease	Yes	No	
(5) Kidney disease (eg stones)	Yes	No	
(6) Psychiatric disorder (eg anxiety, depression)	Yes	No	
(7) Tuberculosis	Yes	No	
(8) Cancer	Yes	No	
Do any of your immediate family (parents/brothers/sisters) have a history of any of the above conditions? Please specify :			

Do you currently have any of the following?			
(1) Backache/joint or muscular pain	Yes	No	
(2) Hernia/rupture	Yes	No	
(3) Visual impairment	Yes	No	
(4) Perforated eardrum / discharge from ear	Yes	No	
(5) Recurrent indigestion	Yes	No	
(6) Jaundice/hepatitis/gall bladder disease	Yes	No	
(7) Change in bowel habit/diarrhoea	Yes	No	
(8) Blood in stools/piles/haemorrhoids	Yes	No	
(9) Shortness of breath/coughing up blood	Yes	No	
(10) Recurrent bronchitis/pneumonia	Yes	No	
(11) Blood in urine/kidney complications/stones	Yes	No	
(12) Headaches/migraine/dizziness	Yes	No	
Physician's comments :			
I certify that the above information is correct :			
 14/3 2020			
Signed : [Employee]			

* Source : Medical Aspects of Fitness for Work Offshore Guidance for Examining Physicians Oil & Gas UK, March 2008

**Medical Screening Questionnaire And
 Examination Record (cont'd)**

Medical Examination

To Be Completed By Examining Physician

Photographic ID :	Passport number :	
	Driver's license number :	
	Other :	

Height	Weight	BMI	BP	Pulse	FEV ₁	FVC	FEV ₁ /FVC	Urinalysis		
								Protein	Blood	Glucose
171 cm	82.5 kg	28.21 kg/m ²	112/80 mmHg	60/ min	2.46 L	2.88 L	85.42 %	(-)	(-)	(-)

Vision Distance			Vision Near			Colour		VDU
L	Aided L	Both	L	Aided L	Both	Normal	Abnormal	
L			L			✓		
20/25			33					
R			R			✓		
20/30			33					

	Normal	Abnormal	Comments
Audiometric Screening	✓		
Substance Abuse Screening	✓		
Stool Culture (Catering Crew)			
Further investigations			
Blood tests		✓	Hypertriglyceridemia, hyperuricemia
Chest X-Ray	✓		
Electrocardiograph (ECG) / Treadmill	✓		
Spirometry		✓	Mild restrictive & mild obstructive
USG	✓		

* Source : Medical Aspects of Fitness for Work Offshore Guidance for Examining Physicians Oil & Gas UK, March 2008

**Medical Screening Questionnaire And
 Examination Record (cont'd)**

	Normal	Abnormal	Comments
1. Eyes/pupils	✓		Radiex, missing, and calculus teeth
2. Ear, nose and throat	✓		
3. Teeth		✓	
4. Lungs/chest	✓		
5. Cardiovascular	✓		
6. Abdomen	✓		
7. Hernial orifices	✓		
8. Genitourinary	✓		
9. Musculoskeletal	✓		
10. Skin	✓		
11. Varicose veins	✓		
12. Neurological	✓		
Physician to comment on any abnormalities :			

Certification	Comment/Reason
Fit for offshore work as per Oil & Gas UK guidelines	✓
Fit for restricted offshore work following discussion with operating company's medical adviser	
Temporarily unfit for offshore work	
Permanently unfit for offshore work	

Physician's signature : dr. RESTU NATASYA FACHRINI
 Print name : SIP : 40/B/15a/31/73/04/1004/02/01**K3/44-1/779.3/2019
 Date of examination : 16/03/2020


PT. KARTIKA BINA MEDIKATAMA

* Source : Medical Aspects of Fitness for Work Offshore Guidance for Examining Physicians Oil & Gas UK, March 2008

Unrestricted Offshore Work Certificate

Medical Certificate of Fitness for Offshore Work

(Issued in accordance with Oil and gas UK Guidelines)

Name :	TAMBOK PARSAULIAN NAPITUPULU
Date of Birth :	27 July 1974
Employing Company Name :	INSPEKTINDO SINERGI PERSADA, PT
Occupation :	INSPECTOR
<p>This individual has been examined in accordance with Oil & Gas UK Guidelines and is Medical Fit for Unrestricted To The Job Described At Offshore Work</p>	
Examining Physician Name :	dr. Frans Denis Martogi
Oil & Gas UK PIN No. :	OGUK/2017/2465
Date of Examination :	16 March 2020
Date of Expiry of Certificate :	16 March 2022
Signed :	

PT. KARTIKA BINA MEDIKATAMA

PT. KARTIKA BINA MEDIKATAMA

TO WHOM IT MAY CONCERN

Kepada yang berkepentingan

This is certify that today Monday, 16 March 2020 Medika Plaza Clinic has performed urine drug screening and/or breath alcohol test to :

Dengan ini menyatakan bahwa, pada hari ini Senin, 16 Maret 2020 Medika Plaza Clinic telah melakukan urine drug screening dan/atau breath alcohol test kepada :

TAMBOK PARSAULIAN NAPITUPULU

With the results are as follows :

Dengan hasil sebagai berikut :

<u>Drugs Test</u> <i>Uji Obat</i>	<u>Result</u> <i>Hasil</i>		
URINE DRUGS SCREENING			
- Amphetamine	<input type="checkbox"/> Non-Negative	<input checked="" type="checkbox"/> Negative	<input type="checkbox"/> N/A
- Met-Amphetamine	<input type="checkbox"/> Non-Negative	<input checked="" type="checkbox"/> Negative	<input type="checkbox"/> N/A
- Cocain	<input type="checkbox"/> Non-Negative	<input checked="" type="checkbox"/> Negative	<input type="checkbox"/> N/A
- THC/Canabis/Marijuana	<input type="checkbox"/> Non-Negative	<input checked="" type="checkbox"/> Negative	<input type="checkbox"/> N/A
- Morphine/Opiates	<input type="checkbox"/> Non-Negative	<input checked="" type="checkbox"/> Negative	<input type="checkbox"/> N/A
- P C P/Phencyclidine	<input type="checkbox"/> Non-Negative	<input checked="" type="checkbox"/> Negative	<input type="checkbox"/> N/A
- Barbiturate	<input type="checkbox"/> Non-Negative	<input type="checkbox"/> Negative	<input checked="" type="checkbox"/> N/A
- Benzodiazepin	<input type="checkbox"/> Non-Negative	<input checked="" type="checkbox"/> Negative	<input type="checkbox"/> N/A
- Methadone	<input type="checkbox"/> Non-Negative	<input checked="" type="checkbox"/> Negative	<input type="checkbox"/> N/A
- Propoxyphene	<input type="checkbox"/> Non-Negative	<input type="checkbox"/> Negative	<input checked="" type="checkbox"/> N/A
- Oxycodone	<input type="checkbox"/> Non-Negative	<input type="checkbox"/> Negative	<input checked="" type="checkbox"/> N/A
- MDMA	<input type="checkbox"/> Non-Negative	<input type="checkbox"/> Negative	<input checked="" type="checkbox"/> N/A
- 6-MAM	<input type="checkbox"/> Non-Negative	<input type="checkbox"/> Negative	<input checked="" type="checkbox"/> N/A
BREATH ALCOHOL TEST			
- Alcohol	<input type="checkbox"/> Non-Negative	<input checked="" type="checkbox"/> Negative	<input type="checkbox"/> N/A

Jakarta, March 16, 2020


PT. KARTIKA BINA MEDIKATAMA
 (dr. Esther Poerwantoro, Sp.PK)
 Clinical Patologist

HEALTH ASSESSMENT REPORT

Of

TAMBOK PARSAULIAN NAPITUPULU
01022516

Monday, 16 March 2020

MP BELTWAY CLINIC

Beltway Office Park, Annex Building, Ground Floor
Jl. TB. Simatupang Kav.41, Jakarta Selatan 12550
Tlp : (62-21) 808 66 099, Fax : (62-21) 808 66 098
www.medikaplaza.com

MP BELTWAY CLINIC

Beltway Office Park, Annex Building, Ground Floor
Jl. TB. Simatupang Kav.41, Jakarta Selatan 12550
Tlp : (62-21) 808 66 099, Fax : (62-21) 808 66 098
www.medikaplaza.com

PATIENT DATA

MedRec.	: 01022516	EMPLOY. STATUS	: Employee
NAME	: TAMBOK PARSAULIAN NAPITUPULU	BIRTHDATE	: 27 July 1974
EMPLOYEE No.	: -	SEX	: Male
JOB TITLE	: INSPECTOR	STATUS	: Married
COMP. NAME	: INSPEKTINDO SINERGI PERSADA, PT	NASIONALITY	: Indonesia

SUMMARY

MEDICAL FINDING :

1. Hypertriglyceridemia
 2. Hyperuricemia
 3. Non reactive Anti HBs
 4. Overweight
 5. Radix, missing, and calculus teeth
 6. Decreasing of visual acuity of both eyes
 7. Spirometry: Mild Restrictive & Mild Obstructive
- Your fitness status is fit for unrestricted to the job described at offshore work.


PERCEPTIONS OF EXPOSURE BY WORKERS :

- Noise
- Vibration
- Dust
- Others (Offshore)

SUGGESTION :

1. Low fat and carbohydrate diet, exercise regularly minimal 3 times a week
2. Low purine diet such as meats including organ meats, alcoholic beverages, beans, shrimp, scallops, some vegetables in limited amount such as: spinach, cauliflower, asparagus and mushroom
3. Need to get Hepatitis B vaccination (booster)
4. Reduce body weight gradually 0.5 Kgs/week, by doing regular exercise (aerobic/jogging), 3-4x/week, 30-45 minutes and reduce high calorie diet until maximal body weight is 73.10 Kgs (present body weight is 82.5 Kgs). Consultation with a Nutritionist for evaluation of overweight
5. Consultation with a Dentist for dental care, minimal once a year or better once in six month
6. You need to wear glasses for distant and near vision
7. Avoid dust and fumes and use face mask while working at dusty area. Consult to a Pulmonologist if any complaint of spirometry result

Responsible Doctor


Restu Natasya Fachrini, MD

Notes:

If you need the further information or consultation, please contact us via :

- Email : - beltway.doctor@medikaplaza.com
- beltway.doctor2@medikaplaza.com
- Telepon Klinik : (62-21) 8086 6000

CLINICAL EVALUATION

Name : TAMBOK PARSAULIAN NAPITUPULU Sex : Male MR : 01022516 Visit : 16/03/2020
Comp.: INSPEKTINDO SINERGI PERSADA, PT DOB : 27 July 1974

EXAMINATION	RESULT	NOTES
-------------	--------	-------

ANAMNESA

PRESENT COMPLAINT AND HISTORY OF PRESENT

ILLNESS

Present complaint

No complaint

MEDICAL HISTORY

Allergy	No
Imunisasi	Yes
Surgery	No
Hospitalization	No
Disease	No

LIFE STYLE

Alcohol intake	No
Smoking	Yes Moderate smoker
Exercise	No

FAMILY MEDICAL HISTORY

Diabetes Melitus	No
Hypertension	No
Heart disease	No
Lung TB	No
Kidney disease	No
Astma	No
Mental disease	No
Epilepsy	No
Cancer	No
Color blind	No
Stroke	No
Liver disease	No
Bone & joint	No
Others disease	No

WORK EXPOSURE

Noise	Yes
Heat Stress	No
Cold Stress	No
Vibration	Yes
Involving height	No
Radiation	No
Dust	Yes

CLINICAL EVALUATION

Name : TAMBOK PARSAULIAN NAPITUPULU	Sex : Male	MR : 01022516	Visit : 16/03/2020
Comp.: INSPEKTINDO SINERGI PERSADA, PT		DOB : 27 July 1974	

EXAMINATION	RESULT	NOTES
Toxic chemical	No	
Irritating fluid	No	
Smoke	No	
Bacterium/Virus/Parasite	No	
Blood	No	
Animal	No	
Operating heavy mobile equipment	No	
Manual Handling	No	
Sitting continuously over 4 hours	No	
Stand continuously over 4 hours	No	
Using monitor screen more than 4 hours per day	No	
Exposure	No	
Unergonomic body positions	No	
Shift work	No	
Work is not accordance with skills and knowledge	No	
Workload does not accordance with time	No	
Work conflict	No	
Inappropriate task	No	
Career barriers	No	
Family conflict	No	
Working around rotating machinery	No	
Administration work	No	
Handling food product	No	
Others	Yes	Offshore
PHYSICAL EXAMINATION		
General Appearance	Good	
Body shape	Picnicus	
VITAL SIGN		
Body Weight	82.5 Kg	
Body Height	171 Cm	
BMI	28.21 Kg/m ²	
Normal Weight	54.10 - 73.10 Kg	
BMI Conclusion	Overweight	
Blood Pressure	110/80 mmHg	
Pulse	60 x/minute	
Body Temperature	36.5 °C	
RR	18	

CLINICAL EVALUATION

Name : TAMBOK PARSAULIAN NAPITUPULU	Sex : Male	MR : 01022516	Visit : 16/03/2020
Comp.: INSPEKTINDO SINERGI PERSADA, PT		DOB : 27 July 1974	

EXAMINATION	RESULT	NOTES
Neck Circumference	39 Cm	
Arm Circumference	33 Cm	
Chest size	95 Cm	
Abdominal Circumference	92 Cm	
SKIN		
Skin	Normal	
EYE		
Left	Normal	
Right	Normal	
ENT		
Auricle	Normal	
Ear canal	Normal	
Drums	Normal	
Septum/Conchae	Normal	
Sinuses	Normal	
Pharynx	Normal	
Tonsil	Normal	
MOUTH		
Gum	Normal	
Dental	Abnormal	Radix, missing, and calculus teeth
NECK		
General	Normal	
Thyroid Gland	Normal	
CHEST		
Form	Normal	
Lung	Normal	
Heart	Normal	
Breast	Normal	
ABDOMEN		
Form	Flat	
Palpation	Supple	
Liver	Not Palpable	
Spleen	Not Palpable	
Kidney	No Ballotment	
-	No	
Hernia inguinal	No	
EXTRIMITIES		

CLINICAL EVALUATION

Name : TAMBOK PARSAULIAN NAPITUPULU	Sex : Male	MR : 01022516	Visit : 16/03/2020
Comp.: INSPEKTINDO SINERGI PERSADA, PT		DOB : 27 July 1974	

EXAMINATION	RESULT	NOTES
Bones, joint	Normal	
Muscles, tonus	Normal	
Fingernails	Normal	
Hand	Normal	
Foot	Normal	
RECTAL EXAMINATION		
Hemorrhoid	Negative	
Rectum	Normal	
SENSORIK EXAMINATION		
Tes Raba	Normal	
MOTORIK EXAMINATION		
Tes Grip	Normal	
REFLEX EXAMINATION		
Physiologic reflex	Normal	
Patologic reflex	Normal	
OTHERS EXAMINATION		
Coordination	Normal	
LYMPHE SYSTEM		
Submandibula	Normal	
Neck Gland	Normal	
Armpit gland	Normal	
Inguinal	Normal	

OPHTHALMOLOGY DIAGNOSTIC

Name : TAMBOK PARSAULIAN NAPITUPULU	Sex : Male	MR : 01022516	Visit : 16/03/2020
Comp.: INSPEKTINDO SINERGI PERSADA, PT		DOB : 27 July 1974	

EXAMINATION		Right	Left
Reading		-	-
Previous Glasses		-	-
Without Glasses	Distant	20/30	20/25
	Near	J3	J3
Correction	Distant	S-0.75 20/20	S-0.50 20/20
	Near	S+1.50 J1	S+1.50 J1
Depth Perception		-	-
Tonometry		20.0 mmHg	20.0 mmHg
Funduscopy		NORMAL	NORMAL
Visual Fields		-	-
Colour Blind Test		Normal	

Impression : Myopia simplex ODS
 Presbyopia

RADIOLOGY DIAGNOSTIC

Name : TAMBOK PARSAULIAN NAPITUPULU

Sex : Male

MR : 01022516

Visit : 16/03/2020

Comp. : INSPEKTINDO SINERGI PERSADA, PT

DOB : 27 July 1974

EXAMINATION

RESULT

THORAX PA

No abnormality seen in both lungs.
Normal bronchovascular markings in both hili.
The heart is normal in size and shape.
The mediastinum is not widened.
Both sinus and diaphragms are good.
No evidence of pleural effusion.

Impression

Normal chest.
No evidence of specific process in both lungs.

RADIOLOGY DIAGNOSTIC

Name : TAMBOK PARSAULIAN NAPITUPULU

Sex : Male

MR : 01022516

Visit : 16/03/2020

Comp.: INSPEKTINDO SINERGI PERSADA, PT

DOB : 27 July 1974

EXAMINATION

RESULT

USG ABDOMEN

LIVER:

Normal in size and contour, smooth surface, echoes structure parenchyme which are homogenous. No sign of SOL.

Intrahepatic vascularity and billiary tract are normal.

GALL BLADDER:

Normal in size, contour and surface. No sign of SOL/ sludge/ stone.

RIGHT KIDNEY :

Normal in size, contour and surface. No sign of obstruction/ stone/ SOL.

LEFT KIDNEY:

Normal in size, contour and surface. No sign of obstruction/ stone/ SOL.

PANCREAS:

Normal in size, contour and surface. No sign of SOL.

LIEN:

Normal in size and contour, the echoes are homogenous. No sign of SOL.

URINARY BLADDER:

Normal in size, contour and surface. No sign of stone/ SOL.

PROSTATE AND VESICULA SEMINALIS:

Normal in size and contour which are homogenous echoes and no sign of focal lesion/ SOL.

Impression

Normal sonography

LABORATORY RESULT

Name : TAMBOK PARSAULIAN NAPITUPULU	MR : 01022516	Visit : 16/03/2020	#Lab : IN69862870055
Comp.: INSPEKTINDO SINERGI PERSADA, PT	Sex : Male	DOB : 27 July 1974	

EXAMINATION	RESULT	NORMAL RANGE
-------------	--------	--------------

HEMATOLOGI

ABO/Rh Typing "B" Rh(+) positive

Automated Blood Count

White Blood Cell (WBC)	8.4	3.8 - 11.0
Erythrocyte (RBC)	4.8	4.4 - 5.9
Haemoglobin	15.4	13.2 - 17.3
Hematocrit	44	40 - 52
Thrombocytes	293	150 - 440

MCV, MCH, MCHC

MCV	91	80 - 100
MCH	32	26 - 34
MCHC	35.2	32 - 36
ESR	6	0 - 10

Differential Count

Basophils	1	0 - 1
Eosinophil	5 *	2 - 4
Bands / Stab	3	3 - 5
Neutrophils	47 *	50 - 70
Lymphocytes	41 *	25 - 40
Monocytes	3	2 - 8

BLD CHEMISTRY/LIPID PROFILE

Total Cholesterol	196	Normal/Desireable: <200 Borderline High: 200-239 High: >=240
HDL Cholesterol	42.1	Normal : >40 - <60 Low HDL : <40 Desireable : >=60
LDL Cholesterol	123	Optimal: <100 Near/Above Optimal: 100-129 Borderline High: 130-159 High: 160-189 Very High: >=190
Triglycerides	153 *	Normal : <150 Borderline High: 150-199 High : 200-499 Very High : >=500

BLD CHEMISTRY/KIDNEY FUNCTION

LABORATORY RESULT

Name : TAMBOK PARSAULIAN NAPITUPULU	MR : 01022516	Visit : 16/03/2020	#Lab : IN6986287005
Comp.: INSPEKTINDO SINERGI PERSADA, PT	Sex : Male	DOB : 27 July 1974	

EXAMINATION	RESULT	NORMAL RANGE
Ureum	25.8	10.0 - 50.0
Creatinine	1.3	0.6 - 1.3
Uric Acid	7.64 *	3.50 - 7.20

BLD CHEMISTRY/LIVER FUNCTION

Total Bilirubin	0.60	0.1 - 1.0
Direct Bilirubin	0.18	0.0 - 0.2
Indirect Bilirubin	0.42	0.0 - 0.8
SGOT(AST)	19	13 - 45
SGPT (ALT)	21	13 - 50
Alkaline Phosphatase	93	30 - 120
Gamma GT	33	0 - 50
Albumin	4.6	3.5 - 5.5
Globulin	2.80	2.3 - 3.5
Total Protein	7.4	6.6 - 8.7

BLD CHEMISTRY/DIABETES

Glucose Fasting	95	< 100
Glucose Urine	Negative	Negative
Keton Urine	Negative	Negative

Blood Glucose 2 PP

Blood Sugar 2 Hours PP	76	< 140
Glucose Urine	Negative	Negative
Keton Urine	Negative	Negative

SEROLOGI / IMUNOLOGI

HBsAg (Quantitative)	0.00	0.00 - 0.03
Anti Hbs (Quantitative)	1.2 *	>= 5.0

TOXICOLOGY - DRUGS SCREENING

Methadone	Negative	Negative
Phencyclidine	Negative	Negative
THC/Marijuana	Negative	Negative
Amphetamine	Negative	Negative
Benzodiazepines	Negative	Negative
Opiat	Negative	Negative
Cocain	Negative	Negative
Metamphetamine	Negative	Negative
Alcohol	Negative	Negative

URINALYSIS**Complete Urine Analysis**

LABORATORY RESULT

Name : TAMBOK PARSAULIAN NAPITUPULU	MR : 01022516	Visit : 16/03/2020	#Lab : IN69862870055
Comp. : INSPEKTINDO SINERGI PERSADA, PT	Sex : Male	DOB : 27 July 1974	

EXAMINATION	RESULT	NORMAL RANGE
-------------	--------	--------------

Macroscopic

Color	Yellow	
Turbidity	Clear	Clear
Specific Gravity	1.026	1.000 - 1.030
pH	5.5	4.5 - 8.0
Leucocyte	Negative	Negative
Glucose	Negative	Negative
Nitrit	Negative	Negative
Bilirubin	Negative	Negative
Blood	Negative	Negative
Urobilinogen	Normal	Normal
Protein	Negative	Negative
Keton	Negative	Negative

Microscopic

RBC	0-1	0 - 1
WBC	0-1	0 - 4
Cylinder	Negative	
Epithels Squamous	0-1	5 - 15
Crystals	Negative	
Bacteria	Negative	Negative
Others	Negative	

STOOL / RECTAL SWAP

Faeces Complete

Macroscopic

Color	Brown	
Consistency	Smooth	
Mucus	Negative	Negative
Blood	Negative	Negative
Pus	Negative	Negative
Parasitologi Faeces	Negative	Negative
Lipid	Negative	Negative

Microscopic

RBC	0-1	0 - 1
WBC	0-1	0 - 5
Amoeba	Negative	
Ephitels	Positive	Positive
Worm Eggs	Negative	Negative

LABORATORY RESULT

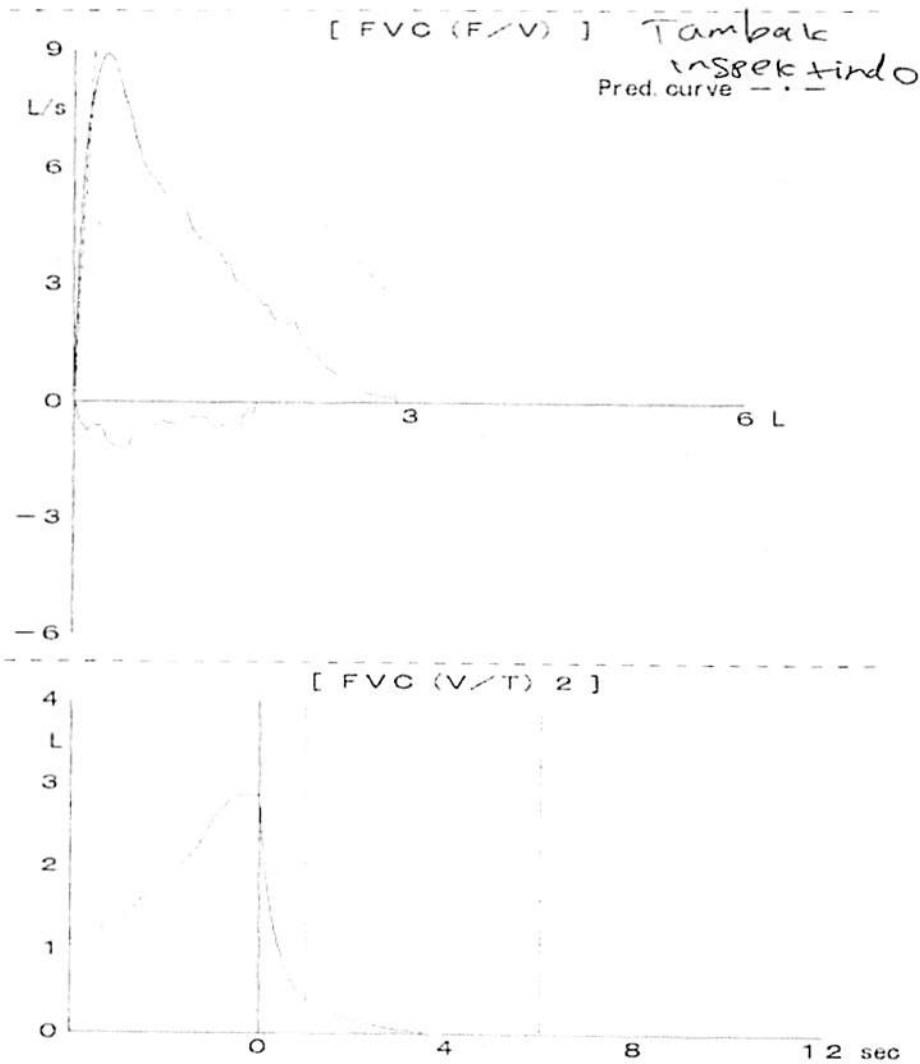
Name : TAMBOK PARSAULIAN NAPITUPULU	MR : 01022516	Visit : 16/03/2020	#Lab : IN6986287005
Comp. : INSPEKTINDO SINERGI PERSADA, PT	Sex : Male	DOB : 27 July 1974	

EXAMINATION	RESULT	NORMAL RANGE
Yeast	Negative	Negative
Muscle Fiber	Negative	Negative
Others	Negative	Negative
Digestive		
Amylum	Negative	Negative
Fat	Negative	
Fibers	Positive	Positive

SPIROMETRY DIAGNOSTIC

Name : TAMBOK PARSAULIAN NAPITUPULU	Sex : Male	MR : 01022516	Visit : 16/03/2020
Comp. : INSPEKTINDO SINERGI PERSADA, PT	DOB : 27 July 1974		

EXAMINATION	RESULT
FVC Result	: 2.88 L---> 74.6 %
FEV1 Result	: 2.46 L---> 72.4 %
FEV1/FVC Result	: 85.42 %---> 113.9 %
PEF Result	: 8.78 L/S---> 84.6 %
Indonesian Standart Result	:
Index	:
Spirometry Result	: Abnormal
Impression	: Mild Restrictive & Mild Obstructive



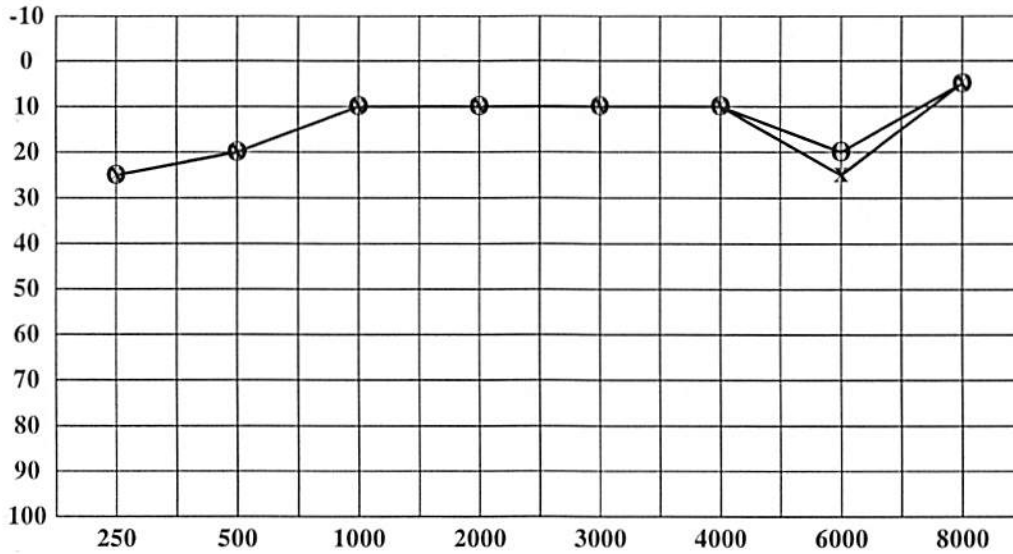
AUDIOMETRY DIAGNOSTIC

Name : TAMBOK PARSAULIAN NAPITUPULU	Sex : Male	MR : 01022516	Visit : 16/03/2020
Comp. : INSPEKTINDO SINERGI PERSADA, PT		DOB : 27 July 1974	

RESULT

Left Ear	250	500	1000	2000	3000	4000	6000	8000
AC	25	20	10	10	10	10	25	5
BC	-	-	-	-	-	-	-	-

Right Ear	250	500	1000	2000	3000	4000	6000	8000
AC	25	20	10	10	10	10	20	5
BC	-	-	-	-	-	-	-	-



< : Right Ear (BC)
> : Left Ear (BC)

O : Right Ear (AC)
X : Left Ear (AC)

Conclusion Right Ear : Hearing threshold = 12.5 dB
(Within normal limit)

Conclusion Left Ear : Hearing threshold = 12.5 dB
(Within normal limit)

CARDIOLOGY DIAGNOSTIC

Name : TAMBOK PARSAULIAN NAPITUPULU	Sex : Male	MR : 01022516	Visit : 16/03/2020
Comp.: INSPEKTINDO SINERGI PERSADA, PT		DOB : 27 July 1974	

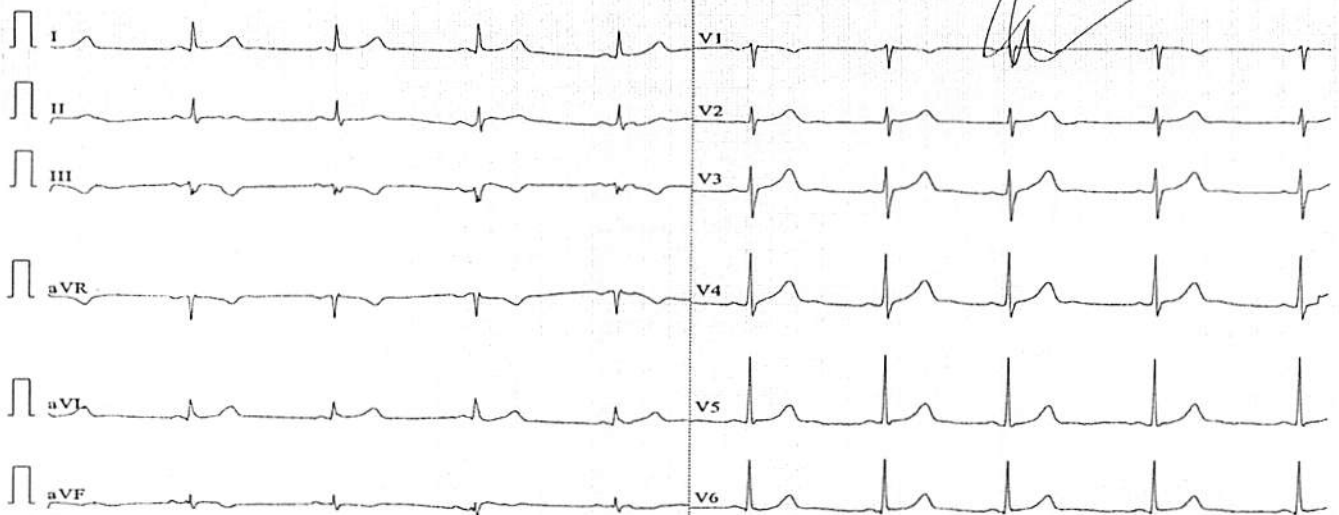
EXAMINATION	RESULT	Comments :
ELECTROCARDIOGRAPHY	Sinus Rythm axis (N), P wave (N), PR int 0.16" ST - T segment (N), aritmia (-)	Normal ECG
TREADMILL	Sinus Rythm axis (N), P wave (N), PR int 0.16" ST - T segment (N), aritmia (-)	Treadmill Exercise Test : Negative Cardiopulmonary Fitness Classification : Good METs : 13.4

ID: 16
TAMBOK P
Male 45Years

16-03-2020 09:44:24
HR : 55 bpm
P : 118 ms
PR : 142 ms
QRS : 92 ms
QT/QTc : 452/433 ms
P/QRS/T : 40/11/-5
RV5/SV1 : 1.817/0.560 mV

Diagnosis Information:
Sinus bradycardia with sinus arrhythmia
Inferior T wave abnormality is nonspecific
Borderline ECG

Report Confirmed by: 



0.67~100Hz AC50 25mm/s 10mm/mV 2*5.0s ♥55 SE-1200Express V2.21 Glasgow V28.6.0



TAMBOK PARSAULIAN NAPITUPULU, MR

ID: 01022516, Born: 7/27/1974 (Male 45), 82 kg, 171 cm
Test Date: 3/16/2020 9:13:37 AM


MEDIKA PLAZA

Patient info

born: 7/27/1974
age: 45
sex: Male
weight: 82 kg
height: 171 cm
smoker:
pacemaker:

Medical history

Trends



Conclusion

Medications

Reason for admission

Reason for Stop

Staff

Physician:
Technician:

user

Test info

Test date: 3/16/2020
 Test time: 9:13 AM
 Stress device: BTL Treadmill Emergency
 Protocol: Bruce
 Total duration: 10:22
 Stress achieved: 6.7km/h, 16.0% (~13.4MET) = 123% predicted (~11.3MET) - for 6 sec
 HR rest: 59
 HR peak: 160 = 92% predicted (174) --- 10.2 Exercise (13.4MET)

Handgrip test: ---
 BP rest: 120/80
 BP peak: ---
 BP recovery: 140/90

DP rest: 7080
 DP peak: 19535 = 2.8x DP at rest
 ST depression max: V5 -1.44mV 10:11 Exercise 13.4MET
 ST elevation max: III 1.41mV 05:48 Exercise 7.0MET
 ST/HR index: 3.3 μ V/bpm (abnormal)

[Handwritten Signature]
 Dr. Kartika Dinda




TAMBOK PARSAULIAN NAPITUPULU, MR

ID: 01022516, Born: 7/27/1974 (Male 45), 82 kg, 171 cm
Test Date: 3/16/2020 9:13:37 AM

MEDIKA PLAZA

Time: P 00:05 - Reference

Load: 1.4MET, HR: 59bpm, BP: 120/80



Filter: 0.07 Spline - 90 Adapt, -50 [Hz]

Medika Plaza Clinic

BTL CardioPoint 2.30.33006.0, DIAG: 2.0.2.0; ECG: BTL-08 ECG, SN: 071D-B-05775

25.00 mm/sec 10.0 mm/mV BTL CardioPoint - Stress Test

Page




TAMBOK PARSALIAN NAPITUPULU, MR

ID: 01022516, Born: 7/27/1974 (Male 45), 82 kg, 171 cm
Test Date: 3/16/2020 9:13:37 AM

MEDIKA PLAZA

Time: E 03:01 - E1

Load: 4.6MET, HR: 84bpm, BP: 120/80



Filter: 0.07 Spline - 90 Adapt, -50 [Hz]

25.00 mm/sec 10.0 mm/mV



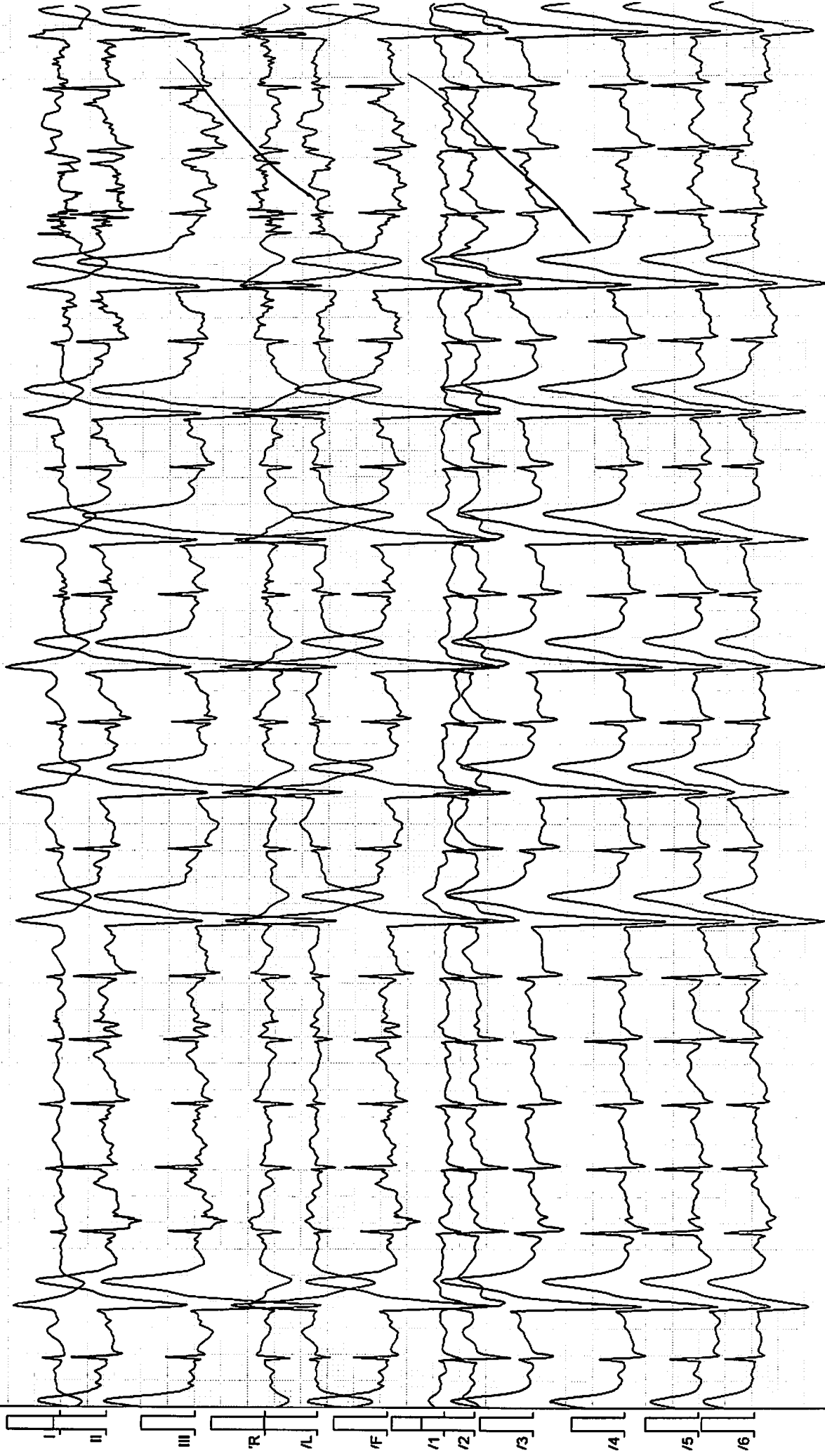
TAMBOK PARSAULIAN NAPITUPULU, MR

ID: 01022516, Born: 7/27/1974 (Male 45), 82 kg, 171 cm
Test Date: 3/16/2020 9:13:37 AM

MEDIKA PLAZA

Time: E 06:08 - E2

Load: 7.0MET, HR: 139bpm, BP: 130/80



Filter: 0.07 Spline - 90 Adapt. -50 [Hz]

edika Plaza Clinic

BTL CardioPoint 2.30.33006.0, DIAG: 2.0.2.0; ECG: BTL-08 ECG, SN: 071D-B-05775

25.00 mm/sec 10.0 mm/mV

Page



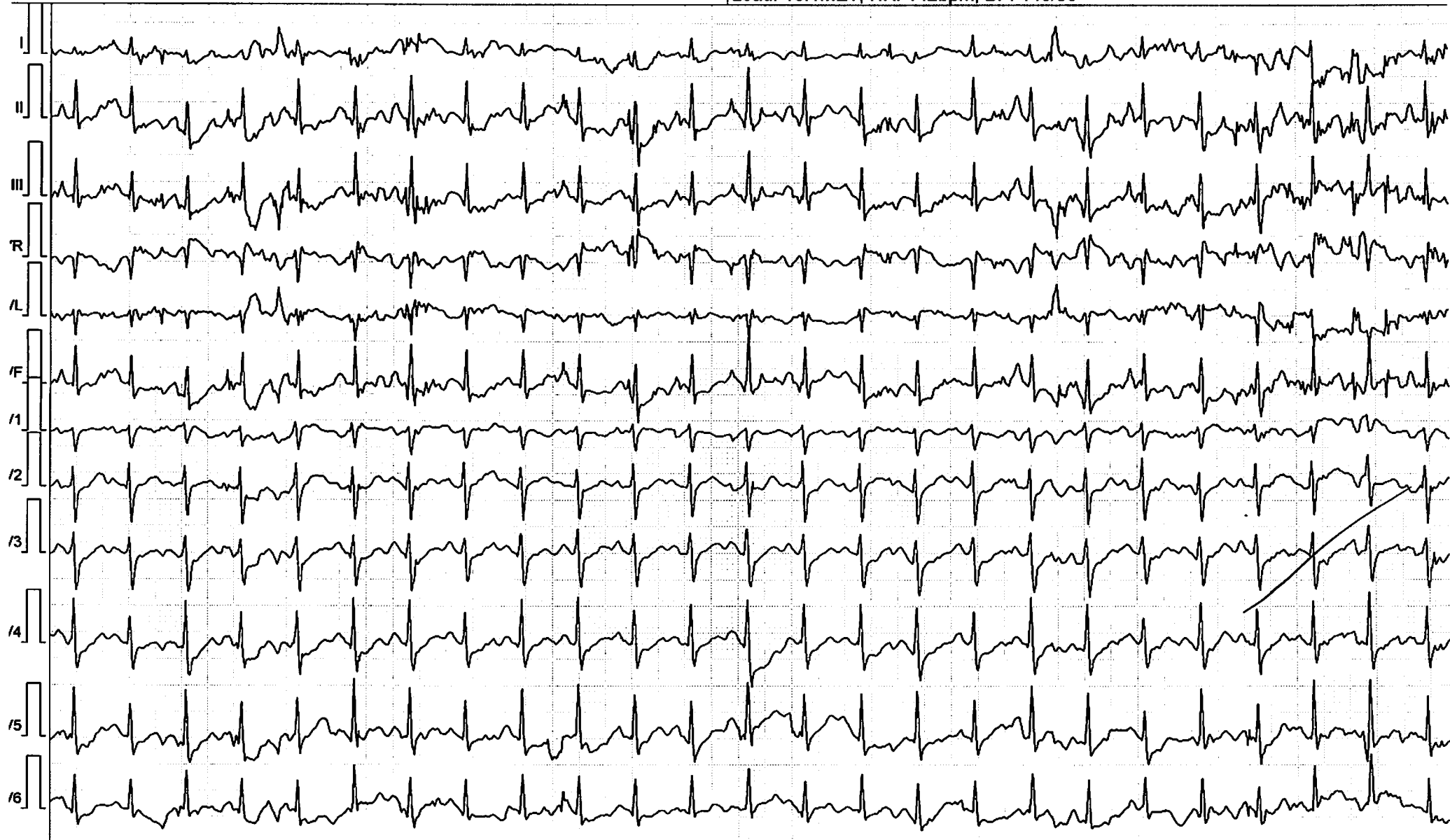
TAMBOK PARSAULIAN NAPITUPULU, MR

ID: 01022516, Born: 7/27/1974 (Male 45), 82 kg, 171 cm
Test Date: 3/16/2020 9:13:37 AM

MEDIKA PLAZA

me: E 09:14 - E3

Load: 10.1MET, HR: 142bpm, BP: 140/90



Filter: 0.07 Spline - 90 Adapt, ~50 [Hz]

25.00 mm/sec 10.0 mm/mV




TAMBOK PARSALIAN NAPITUPULU, MR

ID: 01022516, Born: 7/27/1974 (Male 45), 82 kg, 171 cm
Test Date: 3/16/2020 9:13:37 AM

MEDIKA PLAZA

me: E 10:17 - Peak

Load: 13.4MET, HR: 161bpm, BP: -



Filter: 0.07 Spline - 90 Adapt. -50 [Hz]

edika Plaza Clinic

BTL CardioPoint 2.30.33006.0, DIAG: 2.0.2.0; ECG: BTL-08 ECG, SN: 071D-B-05775

25.00 mm/sec 10.0 mm/mV

Page

BTL CardioPoint - Stress Test




TAMBOK PARSALIAN NAPITUPULU, MR

ID: 01022516, Born: 7/27/1974 (Male 45), 82 kg, 171 cm
Test Date: 3/16/2020 9:13:37 AM

MEDIKA PLAZA

Time: R 00:10 - Recovery

Load: 1.8MET, HR: 159bpm, BP: 140/90



Filter: 0.07 Spline - 90 Adapt. -50 [Hz]

Medika Plaza Clinic

BTL CardioPoint 2.30.33006.0, DIAG: 2.0.2.0; ECG: BTL-08 ECG, SN: 071D-B-05775

25.00 mm/sec 10.0 mm/mV

BTL CardioPoint - Stress Test Page

**TAMBOK PARSAULIAN NAPITUPULU, MR**ID: 01022516, Born: 7/27/1974 (Male 45), 82 kg, 171 cm
Test Date: 3/16/2020 9:13:37 AM

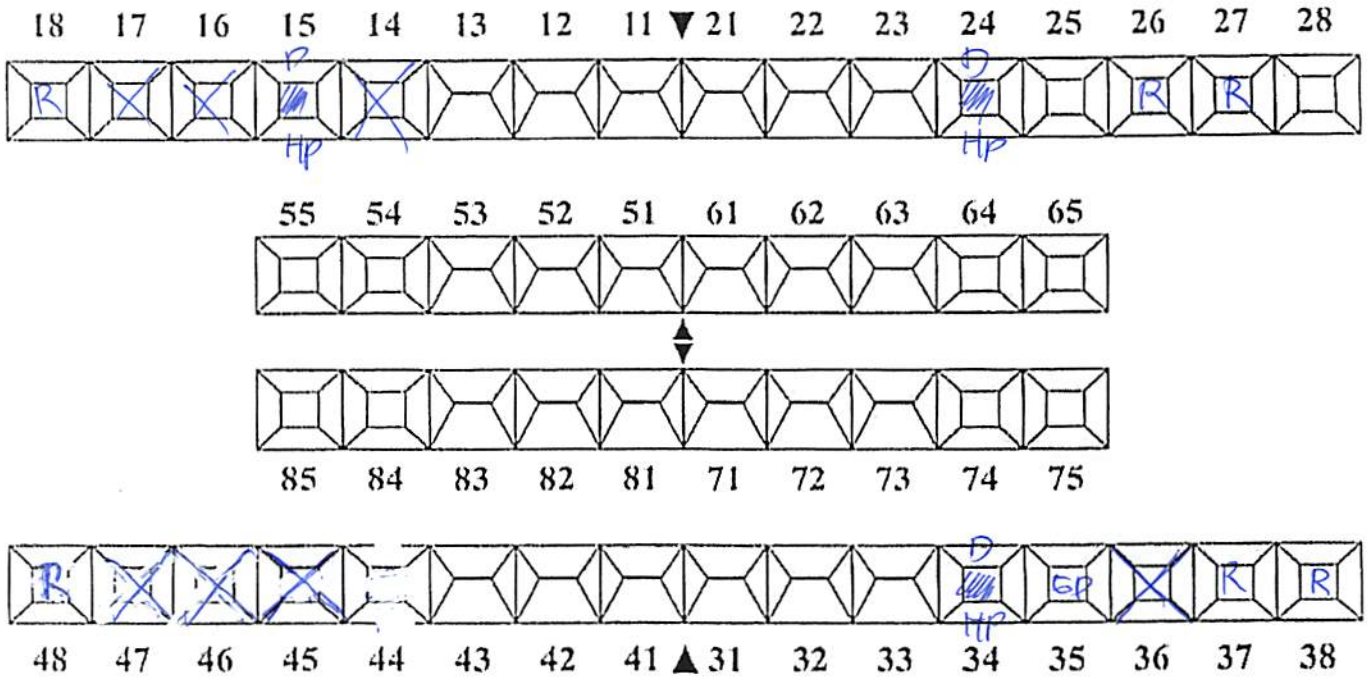
MEDIKA PLAZA

Stage	Time	Load			HR bpm	BP mmHg	SpO2 %	ST Level [mV], J+: 100ms User edited J position											
		km/h	%	MET				I	II	III	aVR	aVL	aVF	V1	V2	V3	V4	V5	V6
Reference	E 00:03	0.8	0.0	1.4	59	120/80	-	0.05	0.00	-0.09	-0.03	0.07	-0.02	0.04	0.11	0.05	0.07	0.09	0.01
E 1 stage	E 03:06	2.7	10.0	4.6	86	120/80	-	0.05	0.04	-0.02	-0.05	0.04	0.01	-0.01	0.12	0.07	0.08	0.11	0.04
E 2 stage	E 06:13	4.0	12.0	7.0	137	130/80	-	0.04	-0.11	-0.14	0.05	0.08	-0.13	0.01	-0.02	-0.02	-0.03	0.13	0.08
E 3 stage	E 09:19	5.4	14.0	10.1	142	140/90	-	-0.03	-0.07	-0.07	0.05	0.03	-0.06	0.00	0.04	-0.04	-0.14	-0.03	-0.05
E 4 peak	E 10:23	6.7	16.0	13.4	160	-	-	-0.21	0.06	0.23	0.07	-0.19	0.17	-0.14	0.02	-0.13	-0.22	-1.44	-0.33
Recovery	R 00:20	0.8	16.0	2.5	159	140/90	-	0.08	-0.04	-0.02	0.02	0.02	-0.04	-0.02	0.04	-0.02	-0.06	-0.03	-0.03

DENTAL EXAMINATION

Name : Tambok Parsaulian Napitupali	Sex : M / F	MR :	Visit :
Comp. : Inspektindo Smergi		DOB :	

ODONTOGRAM



calculus +

DIAGNOSA

OH +

 18, 26, 27, 37, 38, 48 : radix

 17, 16, 36, 45, 46, 47 : missing

 15, 24, 34 : caries

TREATMENT PLANNING

scaling & polishing .

 18, 26, 27, 37, 38, 48 : exo

 17, 16, 36, 45, 46, 47 : protesa .

 15, 24, 34 : filling

Verified by: drg. Ilona Amalia/ drg. Fajar Sulawati /drg. Siti Darjah/drg. Herlina

Fajra 16/03/2020

CONSULTATION SHEET

PATIENT NAME : Mr. TAMBOK PARSULIAN
No. RM : 01022516
Klinik/ MCU / HCU : 0. ENT

To. Dokter :
(Counsel)

Kindly please counsel for patient who has take cares of

Diagnose :
Clinik Summary :

Counsel Request :

COUNSEL ADVISE

Ear : right > tympanic membrane intact
left
Audiometry : normal

Finding : Nose > normal
Throat
neck region : no lymph node

Diagnosis : ENT examination normal

Recomendation : ~~E~~

Date : 16 MARCH 2020

Time :

EP :

Signature
PT. KA

dr. MERIZIANA CHRISTIANE, Sp.THT-KL

SIP : 13/B.15b/31.74.04/1.779.3/e/2018

Complete Name