

Certificate Of Health Assessment

Name	Age	Position	Department
ACHMAD CHOIRONI	35 yo	INSPECTOR	TESTING

COMPANY :

INSPEKTINDO SINERGI PERSADA


CONCLUSION

Fit for work to the job described

Fit with Medical Note (Restriction and/or Limitation)

✓

Unfit for work to the job described

Date	Doctors Name	Signature
01 December 2018	Restu Natasya Fachrini, MD	

No. Formulir : FM-DR-008-05
No. Revisi : 00
Tanggal Terbit : 2 Mei 2011

TO WHOM IT MAY CONCERN

Kepada yang berkepentingan

This is certify that today Saturday, 01 December 2018 Medika Plaza Clinic has performed urine drug screening and/or breath alcohol test to :

Dengan ini menyatakan bahwa, pada hari ini Sabtu, 01 Desember 2018 Medika Plaza Clinic telah melakukan urine drug screening dan/atau breath alcohol test kepada :


ACHMAD CHOIRONI

With the results are as follows :

Dengan hasil sebagai berikut :

<u>Drugs Test</u> <i>Uji Obat</i>	<u>Result</u> <i>Hasil</i>		
URINE DRUGS SCREENING			
- Amphetamine	<input type="checkbox"/> Non-Negative	<input checked="" type="checkbox"/> Negative	<input type="checkbox"/> N/A
- Met-Amphetamine	<input type="checkbox"/> Non-Negative	<input checked="" type="checkbox"/> Negative	<input type="checkbox"/> N/A
- Cocain	<input type="checkbox"/> Non-Negative	<input checked="" type="checkbox"/> Negative	<input type="checkbox"/> N/A
- THC/Canabis/Marijuana	<input type="checkbox"/> Non-Negative	<input checked="" type="checkbox"/> Negative	<input type="checkbox"/> N/A
- Morphine/Opiates	<input type="checkbox"/> Non-Negative	<input checked="" type="checkbox"/> Negative	<input type="checkbox"/> N/A
- P C P/Phencyclidine	<input type="checkbox"/> Non-Negative	<input type="checkbox"/> Negative	<input checked="" type="checkbox"/> N/A
- Barbiturate	<input type="checkbox"/> Non-Negative	<input type="checkbox"/> Negative	<input checked="" type="checkbox"/> N/A
- Benzodiazepin	<input type="checkbox"/> Non-Negative	<input checked="" type="checkbox"/> Negative	<input type="checkbox"/> N/A
- Methadone	<input type="checkbox"/> Non-Negative	<input checked="" type="checkbox"/> Negative	<input type="checkbox"/> N/A
- Propoxyphene	<input type="checkbox"/> Non-Negative	<input type="checkbox"/> Negative	<input checked="" type="checkbox"/> N/A
- Oxycodone	<input type="checkbox"/> Non-Negative	<input type="checkbox"/> Negative	<input checked="" type="checkbox"/> N/A
- MDMA	<input type="checkbox"/> Non-Negative	<input type="checkbox"/> Negative	<input checked="" type="checkbox"/> N/A
- 6-MAM	<input type="checkbox"/> Non-Negative	<input type="checkbox"/> Negative	<input checked="" type="checkbox"/> N/A
BREATH ALCOHOL TEST			
- Alcohol	<input type="checkbox"/> Non-Negative	<input checked="" type="checkbox"/> Negative	<input type="checkbox"/> N/A

Jakarta, December 01, 2018



(dr. Esther Poerwantoro, Sp.PK)

Clinical Patologist

HEALTH ASSESSMENT REPORT

Of

ACHMAD CHOIRONI
01035755

Saturday, 01 December 2018

MP BELTWAY CLINIC

Beltway Office Park, Annex Building, Ground Floor
Jl. TB. Simatupang Kav.41, Jakarta Selatan 12550
Tlp : (62-21) 808 66 099, Fax : (62-21) 808 66 098
www.medikaplaza.com

MP BELTWAY CLINIC

Beltway Office Park, Annex Building, Ground Floor
Jl. TB. Simatupang Kav.41, Jakarta Selatan 12550
Tlp : (62-21) 808 66 099, Fax : (62-21) 808 66 098
www.medikaplaza.com

PATIENT DATA

MedRec.	: 01035755	EMPLOY. STATUS	: Employee
NAME	: ACHMAD CHOIRONI	BIRTHDATE	: 02 March 1983
EMPLOYEE No.	:	SEX	: Male
JOB TITLE	: INSPECTOR	STATUS	: Married
COMP. NAME	: INSPEKTINDO SINERGI PERSADA	NASIONALITY	: Indonesia

SUMMARY


MEDICAL FINDING :

1. Hypertriglyceridemia (has been prescribed medication)
 2. Overweight
 3. Calculus, gangren pulpa, decayed, radix teeth
 4. Moderate conductive hearing loss of right ear
- Your fitness status is fit with medical note:
Moderate hearing loss of right ear

SUGGESTION :

1. Low fat and carbohydrate diet, exercise regularly minimal 3 times a week.
2. Reduce body weight gradually 0.5 Kgs/week, by doing regular exercise (aerobic/jogging), 3-4x/week, 30-45 minutes and reduce high calorie diet until maximal body weight is 60.84Kgs (present body weight is 69.8Kgs). See a Clinical Nutrition Specialist for evaluation of Overweight
3. See a dentist for dental care, minimal once a year or better once in six month
4. Avoid noisy environment and use earplug properly while working at noisy work environment to prevent further hearing impairment. Consult to an ENT for further evaluation of Moderate hearing loss of right ear

Responsible Doctor



Restu Natasya Fachrini, MD

Notes:

If you need the further information or consultation, please contact us via :

Email : - beltway.doctor@medikaplaza.com
- beltway.doctor2@medikaplaza.com
Telepon Klinik : (62-21) 8086 6000

CLINICAL EVALUATION

Name : ACHMAD CHOIRONI	Sex : Male	MR : 01035755	Visit : 01/12/2018
Comp. : INSPEKTINDO SINERGI PERSADA		DOB : 02 March 1983	
EXAMINATION	RESULT	NOTES	

ANAMNESA

PRESENT COMPLAINT AND HISTORY OF PRESENT

ILLNESS

Present complaint No Complaint

MEDICAL HISTORY

Alergy	No	
Imunisasi	Yes	
Surgery	Yes	Fracture septum nasal
Hospitalization	Yes	Due to surgery
Disease	No	

LIFE STYLE

Alcohol intake	No	
Smoking	No	
Exercise	Yes	Futsall 1x/week

FAMILY MEDICAL HISTORY

Diabetes Melitus	No
Hypertension	No
Heart disease	No
Lung TB	No
Kidney disease	No
Astma	No
Mental disease	No
Epilepsy	No
Cancer	No
Color blind	No
Stroke	No
Liver disease	No
Bone & joint	No
Others disease	No

WORK EXPOSURE

Noise	No
Heat Stress	No
Cold Stress	No
Vibration	No
Involving height	No
Radiation	No
Dust	Yes

CLINICAL EVALUATION

Name : ACHMAD CHOIRONI

Sex : Male

MR : 01035755

Visit : 01/12/2018

Comp.: INSPEKTINDO SINERGI PERSADA

DOB : 02 March 1983

EXAMINATION	RESULT	NOTES
Toxic chemical	No	
Irritating fluid	No	
Smoke	No	
Bacterium/Virus/Parasite	No	
Blood	No	
Animal	No	
Operating heavy mobile equipment	No	
Manual Handling	No	
Sitting continuously over 4 hours	No	
Stand continuously over 4 hours	No	
Using monitor screen more than 4 hours per day	No	
Exposure	No	
Unergonomic body positions	No	
Shift work	No	
Work is not accordance with skills and knowledge	No	
Workload does not accordance with time	No	
Work conflict	No	
Inappropriate task	No	
Career barriers	No	
Family conflict	No	
Working around rotating machinery	No	
Administration work	No	
Handling food product	No	
Others	Yes	Onshore/offshore
PHYSICAL EXAMINATION		
General Appearance	Good	
Body shape	Athleticus	
VITAL SIGN		
Body Weight	69.8 Kg	
Body Height	156 Cm	
BMI	28.68 Kg/m2	
Normal Weight	45.02 - 60.84 Kg	
BMI Conclusion	Overweight	
Blood Pressure	100/80 mmHg	
Pulse	78 x/minute	
Body Temperature	35.8 °C	
RR	19	

CLINICAL EVALUATION

Name : ACHMAD CHOIRONI	Sex : Male	MR : 01035755	Visit : 01/12/2018
Comp. : INSPEKTINDO SINERGI PERSADA		DOB : 02 March 1983	

EXAMINATION	RESULT	NOTES
Neck Circumference	41 Cm	
Arm Circumference	28 Cm	
Chest size	89 Cm	
Abdominal Circumference	84 Cm	
SKIN		
Skin	Normal	
EYE		
Left	Normal	
Right	Normal	
ENT		
Auricle	Normal	
Ear canal	Normal	
Drums	Normal	
Septum/Conchae	Normal	
Sinuses	Normal	
Pharynx	Normal	
Tonsil	Normal	
MOUTH		
Gum	Normal	
Dental	Abnormal	Calculus, Gangren pulpa, Decayed, Radix teeth
NECK		
General	Normal	
Thyroid Gland	Normal	
CHEST		
Form	Normal	
Lung	Normal	
Heart	Normal	
Breast	Normal	
ABDOMEN		
Form	Flat	
Palpation	Supple	
Liver	Not Palpable	
Spleen	Not Palpable	
Kidney	No Ballotment	
-	No	
Hernia inguinal	No	
EXTRIMITIES		

CLINICAL EVALUATION

Name : ACHMAD CHOIRONI

Sex : Male

MR : 01035755

Visit : 01/12/2018

Comp. : INSPEKTINDO SINERGI PERSADA

DOB : 02 March 1983

EXAMINATION	RESULT	NOTES
Bones,joint	Normal	
Muscles,tonus	Normal	
Fingernails	Normal	
Hand	Normal	
Foot	Normal	
RECTAL EXAMINATION		
Hemorrhoid	Negative	
Rectum	Normal	
SENSORIK EXAMINATION		
Tes Raba	Normal	
MOTORIK EXAMINATION		
Tes Grip	Normal	
REFLEX EXAMINATION		
Physiologic reflex	Normal	
Patologic reflex	Normal	
OTHERS EXAMINATION		
Coordination	Normal	
LYMPHE SYSTEM		
Submandibula	Normal	
Neck Gland	Normal	
Armpit gland	Normal	
Inguinal	Normal	

OPHTHALMOLOGY DIAGNOSTIC

Name : ACHMAD CHOIRONI	Sex : Male	MR : 01035755	Visit : 01/12/2018
Comp. : INSPEKTINDO SINERGI PERSADA		DOB : 02 March 1983	

EXAMINATION		Right	Left
Reading		-	-
Previous Glasses		-	-
Without Glasses	Distant	20/20	20/20
	Near	J1	J1
Correction	Distant	-	-
	Near	-	-
		-	-
Tonometry		-	-
Funduscopy		-	-
Visual Fields		-	
Colour Blind Test		Normal	

Impression :

RADIOLOGY DIAGNOSTIC

Name : ACHMAD CHOIRONI

Sex : Male

MR : 01035755

Visit : 01/12/2018

Comp. : INSPEKTINDO SINERGI PERSADA

DOB : 02 March 1983

EXAMINATION

RESULT

THORAX PA

No abnormality seen in both lungs.
Normal bronchovascular markings in both hili.
The heart is normal in size and shape.
The mediastinum is not widened.
Both sinus and diaphragms are good.
No evidence of pleural effusion.
There are 11 left costae without first th costae.

Impression

Normal heart.
No evidence of specific process in both lungs.

SPIROMETRY DIAGNOSTIC

Name : ACHMAD CHOIRONI

Sex : Male

MR : 01035755

Visit : 01/12/2018

Comp. : INSPEKTINDO SINERGI PERSADA

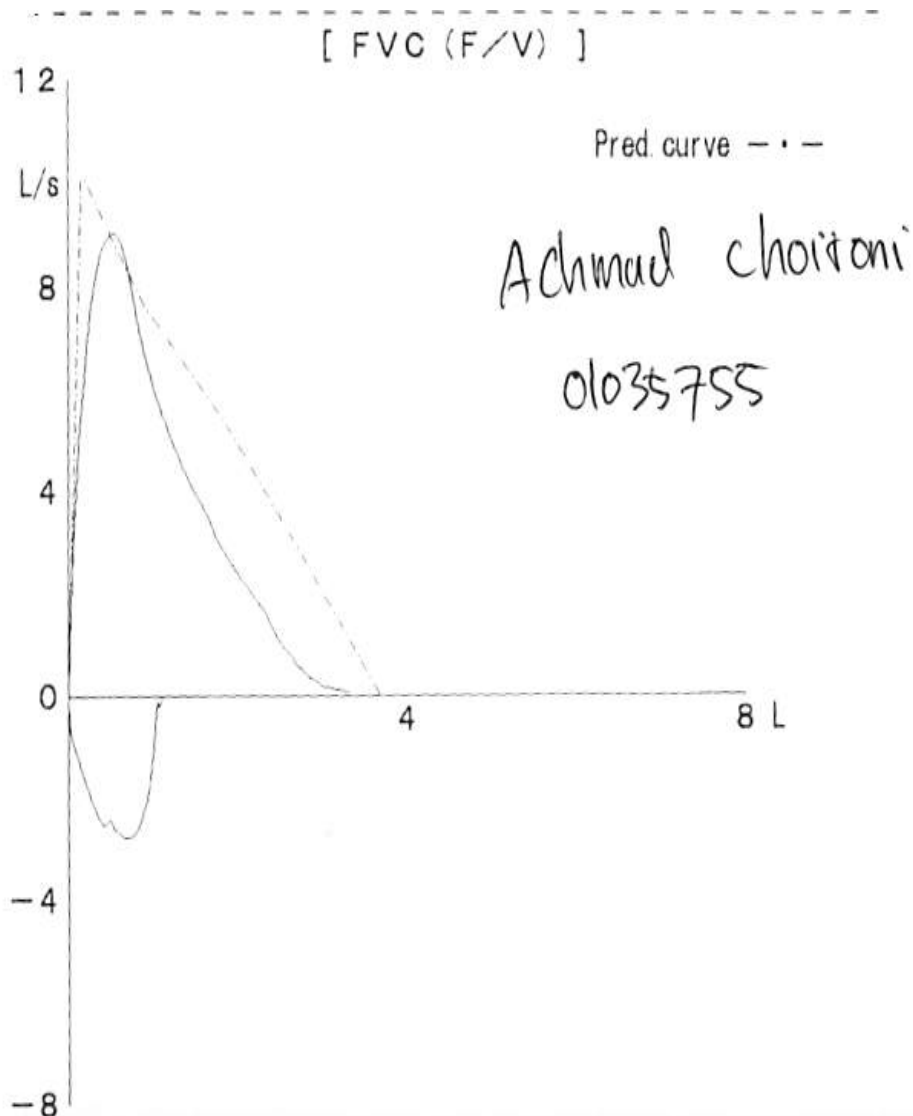
DOB : 02 March 1983

EXAMINATION

RESULT

FVC Result : 3.32 L---> 89.7 %
FEV1 Result : 2.73 L---> 85.0 %
FEV1/FVC Result : 82.23 %---> 104.4 %
PEF Result : 9.00 L/S---> 89.1 %
Indonesian Standart Result :
Index :
Spirometry Result : Normal

Impression : Normal Spirometric Functions

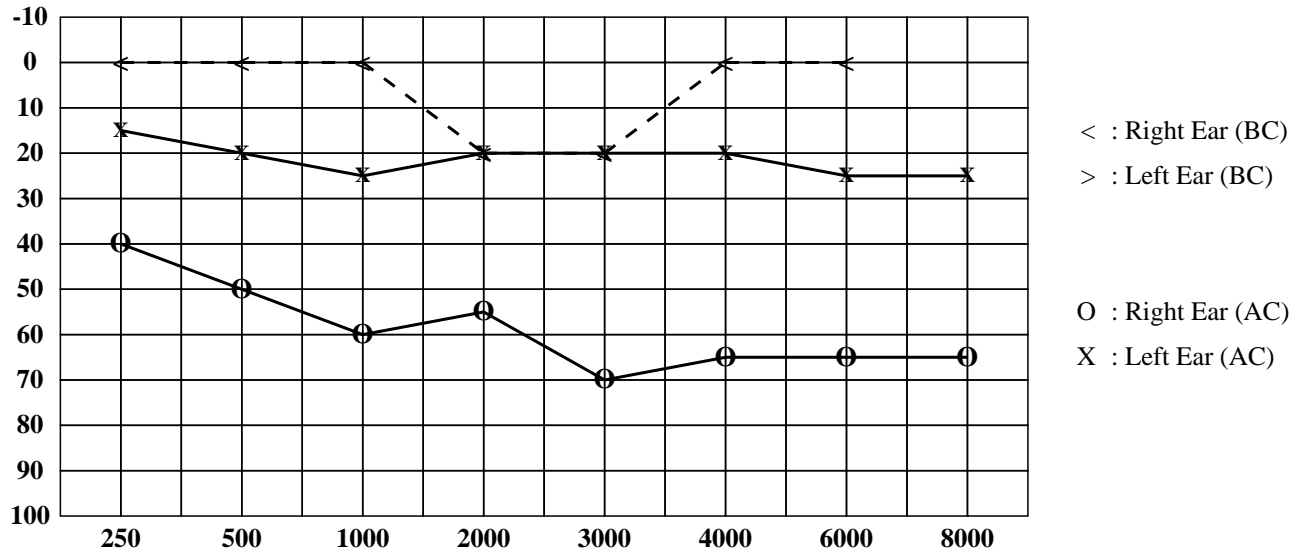


AUDIOMETRY DIAGNOSTIC

Name : ACHMAD CHOIRONI	Sex : Male	MR : 01035755	Visit : 01/12/2018
Comp. : INSPEKTINDO SINERGI PERSADA		DOB : 02 March 1983	

RESULT

Left Ear	250	500	1000	2000	3000	4000	6000	8000	Right Ear	250	500	1000	2000	3000	4000	6000	8000
AC	15	20	25	20	20	20	25	25	AC	40	50	60	55	70	65	65	65
BC	-	-	-	-	-	-	-	-	BC	0	0	0	20	20	0	0	-



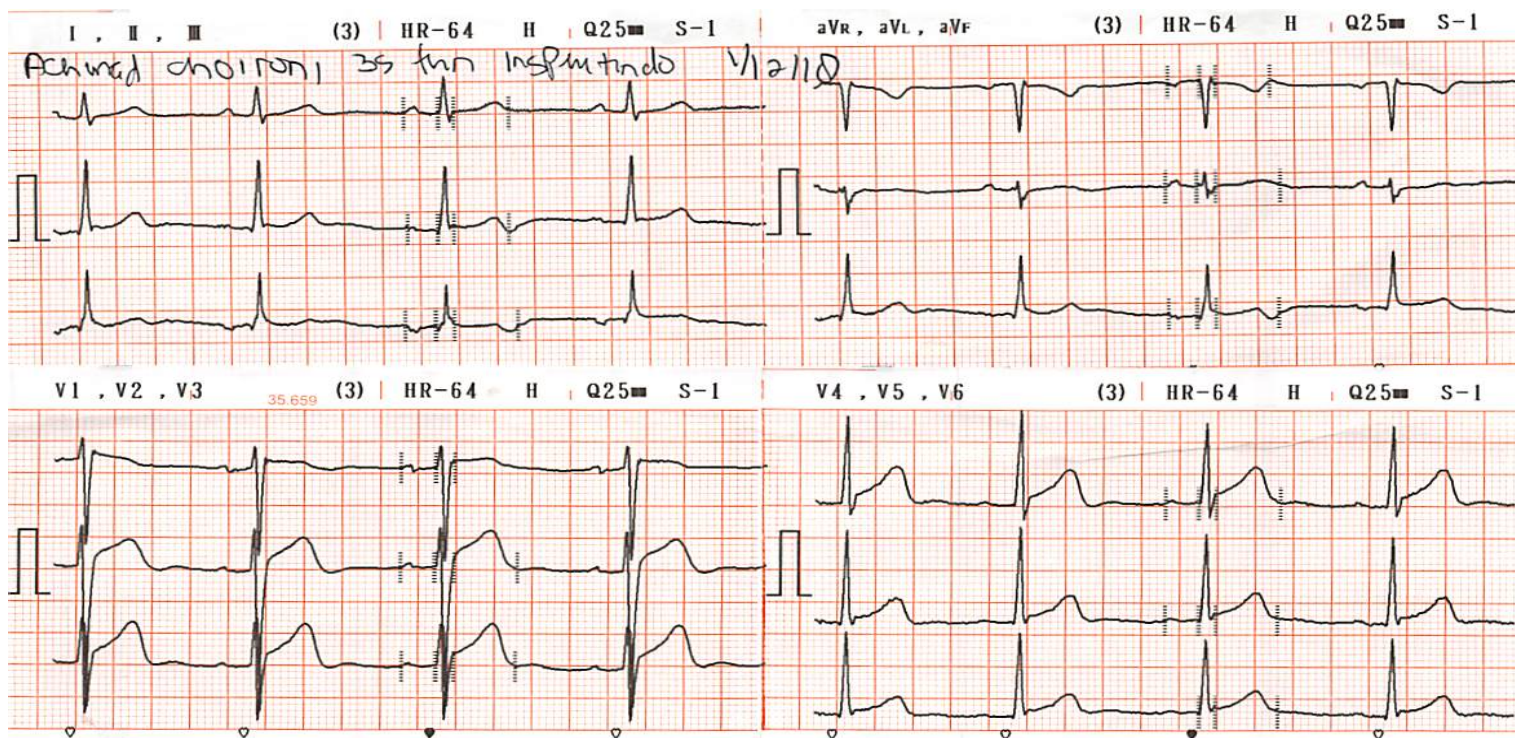
Conclusion Right Ear : Moderate conductive hearing loss = 57.5 dB
 With decreasing on frequency
 250Hz, 4000Hz, 6000Hz, 8000Hz

Conclusion Left Ear : Hearing threshold = 21.25 dB
 (Within normal limit)

CARDIOLOGY DIAGNOSTIC

Name : ACHMAD CHOIRONI	Sex : Male	MR : 01035755	Visit : 01/12/2018
Comp.: INSPEKTINDO SINERGI PERSADA		DOB : 02 March 1983	

EXAMINATION	RESULT	Comments :
ELECTROCARDIOGRAPHY	Sinus Rythm axis (N), P wave (N), PR int 0.16" ST - T segment (N), aritmia (-)	Normal ECG
TREADMILL	Sinus Rythm axis (N), P wave (N), PR int 0.16" ST - T segment (N), aritmia (-)	Treadmill Exercise Test : Negative Cardiopulmonary Fitness Classification : Good METs : 10.7



LABORATORY RESULT

Name : ACHMAD CHOIRONI	MR : 01035755	Visit : 01/12/2018	#Lab : IN651427485125
Comp. : INSPEKTINDO SINERGI PERSADA	Sex : Male	DOB : 02 March 1983	

EXAMINATION	RESULT	NORMAL RANGE
-------------	--------	--------------

HEMATOLOGI

ABO/Rh Typing "A" Rh(+) positive

Automated Blood Count

White Blood Cell (WBC)	11.3 *	3.8 - 11.0
Erythrocyte (RBC)	5.5	4.4 - 5.9
Haemoglobin	15.6	13.2 - 17.3
Hematocrit	45	40 - 52
Thrombocytes	291	150 - 440

MCV, MCH, MCHC

MCV	82	80 - 100
MCH	29	26 - 34
MCHC	34.6	32 - 36
ESR	26 *	0 - 10

Differential Count

Basophils	0	0 - 1
Eosinophil	7 *	2 - 4
Bands / Stab	2 *	3 - 5
Neutrophils	54	50 - 70
Lymphocytes	31	25 - 40
Monocytes	6	2 - 8

BLD CHEMISTRY/LIPID PROFILE

Total Cholesterol	195	Normal/Desireable: <200 Borderline High: 200-239 High: >=240
HDL Cholesterol	44.4	Normal : >40 - <60 Low HDL : <40 Desireable : >=60
LDL Cholesterol	110	Optimal: <100 Near/Above Optimal: 100-129 Borderline High: 130-159 High: 160-189 Very High: >=190
Tryglicerides	204 *	Normal : <150 Borderline High: 150-199 High : 200-499 Very High : >=500

BLD CHEMISTRY/KIDNEY FUNCTION

LABORATORY RESULT

Name : ACHMAD CHOIRONI	MR : 01035755	Visit : 01/12/2018	#Lab : IN651427485125
Comp. : INSPEKTINDO SINERGI PERSADA	Sex : Male	DOB : 02 March 1983	

EXAMINATION	RESULT	NORMAL RANGE
Ureum	25.0	10.0 - 50.0
Creatinine	1.0	0.6- 1.3
Uric Acid	6.3	3.5 - 7.2

BLD CHEMISTRY/LIVER FUNCTION

SGOT(AST)	20	13 - 45
SGPT (ALT)	22	13 - 50
Alkaline Phosphatase	53	30 - 120
Gamma GT	18	0 - 50

BLD CHEMISTRY/DIABETES

Glucose Fasting	89	< 100
Glucose Urine	Negative	Negative
Keton Urine	Negative	Negative

Blood Glucose 2 PP

Blood Sugar 2 Hours PP	83	< 140
Glucose Urine	Negative	Negative
Keton Urine	Negative	Negative

TOXICOLOGY - DRUGS SCREENING

Methadone	Negative	Negative
THC/Marijuana	Negative	Negative
Amphetamine	Negative	Negative
Benzodiazepines	Negative	Negative
Opiat	Negative	Negative
Cocain	Negative	Negative
Metamphetamine	Negative	Negative
Alcohol	Negative	Negative

URINALYSIS**Complete Urine Analysis****Macroscopic**

Color	Colorless	
Turbidity	Clear	Clear
Specific Gravity	1.011	1.000 - 1.030
pH	6.0	4.5 - 8.0
Leucocyte	Negative	Negative
Glucose	Negative	Negative
Nitrit	Negative	Negative
Bilirubin	Negative	Negative
Blood	Negative	Negative

LABORATORY RESULT

Name : ACHMAD CHOIRONI

MR : 01035755

Visit : 01/12/2018

#Lab : IN651427485125

Comp. : INSPEKTINDO SINERGI PERSADA

Sex : Male

DOB : 02 March 1983

EXAMINATION	RESULT	NORMAL RANGE
Urobilinogen	Normal	Normal
Protein	Negative	Negative
Keton	Negative	Negative
Microscopic		
RBC	0-1	0 - 1
WBC	0-1	0 - 4
Cylinder	Negative	
Epithels Squamous	0-1	5 - 15
Crystals	Negative	
Bacteria	Negative	Negative
Others	Negative	

STOOL / RECTAL SWAP**Faeces Complete****Macroscopic**

Color	Brown	
Consistency	Smooth	
Mucus	Negative	Negative
Blood	Negative	Negative
Pus	Negative	Negative
Parasitologi Faeces	Negative	Negative
Lipid	Negative	Negative

Microscopic

RBC	0-1	0 - 1
WBC	0-2	0 - 5
Amoeba	Negative	
Ephitels	Positive	Positive
Worm Eggs	Negative	Negative
Yeast	Negative	Negative
Muscle Fiber	Negative	Negative
Others	Negative	Negative

Digestive

Amylum	Negative	Negative
Fat	Negative	
Fibers	Positive	Positive

X-RAY FILM

Name : ACHMAD CHOIRONI

Sex : Male

MR : 01035755

Visit : 01/12/2018

Comp. : INSPEKTINDO SINERGI PERSADA

DOB : 02 March 1983

ID : 01035755

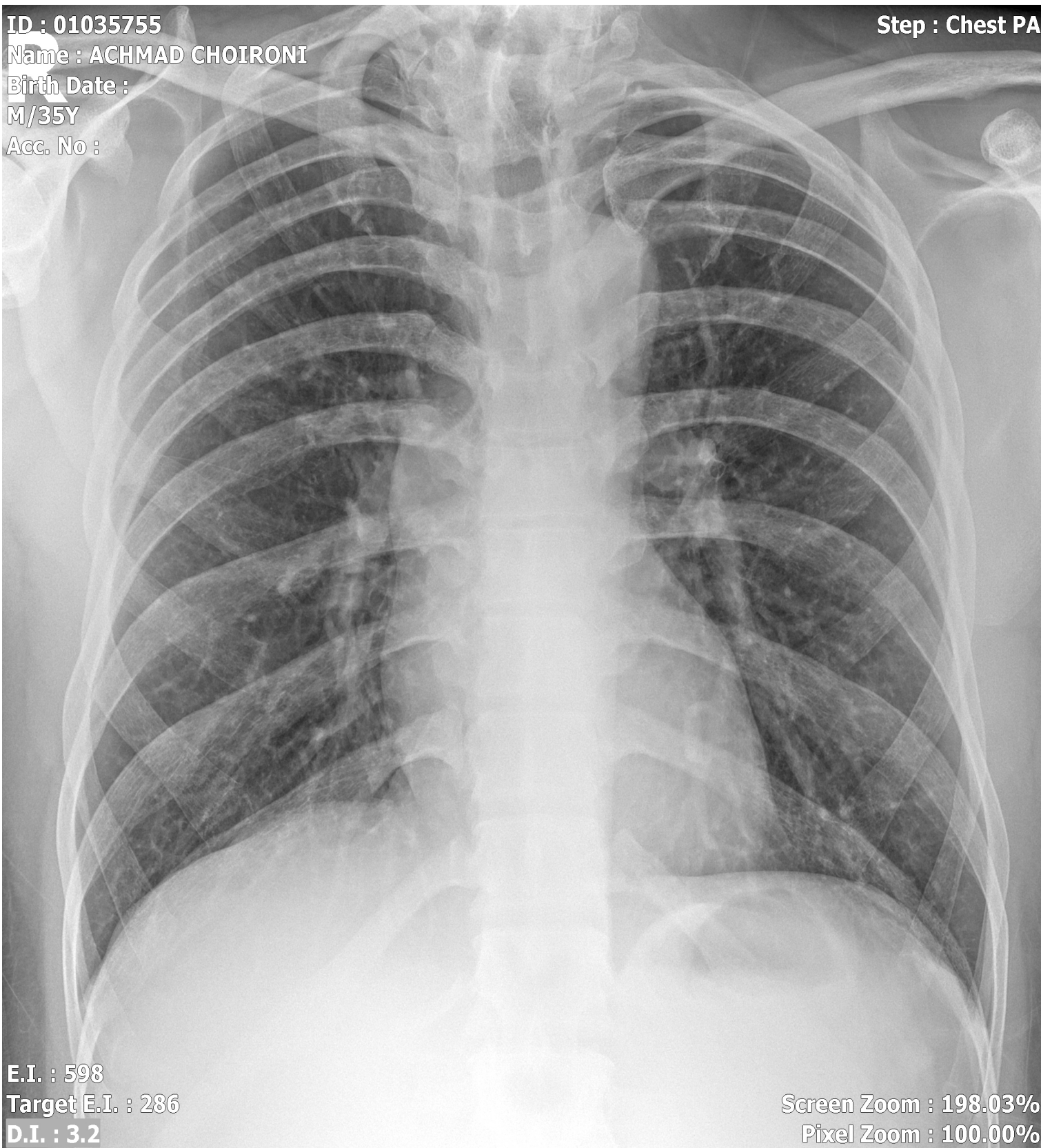
Name : ACHMAD CHOIRONI

Birth Date :

M/35Y

Acc. No :

Step : Chest PA



E.I. : 598

Target E.I. : 286

D.I. : 3.2

Screen Zoom : 198.03%

Pixel Zoom : 100.00%