

**Certificate Of Health Assessment**




Name	Age	Position	Department
AJAT SUDRAJAT	34 yo	ASST.INSPECTOR	-

**COMPANY :**

**INSPEKTINDO SINERGI PERSADA, PT**

**CONCLUSION**

FIT TO WORK	
FIT WITH MEDICAL NOTE	✓
TEMPORARY UNFIT	
UNFIT	

Issued Date	Doctors Name	Prepared By
26 February 2021	<b>Puteri Melati, MD</b> <small>PKTK : KEP.264/BINWASK3-PNK3/KK/VI/2019</small> <small>SIP : 23/B.15a/31.74.04.1004/-1.779.3/e/2019</small>	 
Expired Date		Verified By
26 February 2022	<b>dr. Muhammad Ilyas, Sp.Ok</b> <small>SIP : 29/B.15b/31.74.04.1004.02.009.K.1/3/-1.779.3/e/2019</small>	 <small>PT. KARTIKA BINA MEDIKATAMA</small>

No. Formulir : FM-DR-008-05  
 No. Revisi : 00  
 Tanggal Terbit : 2 Mei 2011

Certificate Number : MP-BOP/1-20210226/128204  
 MCU Validity Check  
<https://mcu-validasi.medikaplaza.com>

# **HEALTH ASSESSMENT REPORT**

*Of*

**AJAT SUDRAJAT**  
**01004054**

**Friday, 26 February 2021**

## **MP BELTWAY CLINIC**

Beltway Office Park, Annex Building, Ground Floor  
Jl. TB. Simatupang Kav.41, Jakarta Selatan 12550  
Tlp : (62-21) 808 66 099, Fax : (62-21) 808 66 098  
[www.medikaplaza.com](http://www.medikaplaza.com)

## MP BELTWAY CLINIC

Beltway Office Park, Annex Building, Ground Floor  
Jl. TB. Simatupang Kav.41, Jakarta Selatan 12550  
Tlp : (62-21) 808 66 099, Fax : (62-21) 808 66 098  
www.medikaplaza.com

### PATIENT DATA

MedRec.	: 01004054	EMPLOY. STATUS	: Employee
NAME	: AJAT SUDRAJAT	BIRTHDATE	: 25 May 1986
EMPLOYEE No.	:	SEX	: Male
JOB TITLE	: ASST.INSPECTOR	STATUS	: Single
COMP. NAME	: INSPEKTINDO SINERGI PERSADA, PT	NASIONALITY	: Indonesia

### SUMMARY

#### MEDICAL FINDING :

1. Dyslipidemia
2. Hyperuricemia
3. Increase fasting blood sugar
4. Overweight
5. Calculus, decayed, missing, and stain teeth
6. Decreasing of hearing acuity on high frequency of right ear

Your fitness status is fit with medical note:

Dyslipidemia

#### PERCEPTIONS OF EXPOSURE BY WORKERS :

- Others

#### SUGGESTION :

1. Low fat and carbohydrate diet and exercise regularly minimal 3 times a week. Consultation with an Internist for further evaluation of dyslipidemia
2. Low purine diet such as meats including organ meats, alcoholic beverages, beans, shrimp, scallops, some vegetables in limited amount such as: spinach, cauliflower, asparagus and mushroom
3. Low sugar diet and repeat blood glucose examination 1 month later. Consultation with an Internist if blood glucose still increase
4. Reduce body weight gradually 0.5 Kgs/week, by doing regular exercise (aerobic/jogging), 3-4x/week, 30-45 minutes and reduce high calorie diet until maximal body weight is 73.96 Kgs (present body weight is 87.6 Kgs). Consultation with a Nutritionist for evaluation of overweight
5. Consultation with a Dentist for dental care, minimal once a year or better once in six month
6. Avoid noisy environment and use earplug properly while working at noisy work environment to prevent further hearing impairment

#### Responsible Doctor



Puleri Mejati, MD

#### Notes:

If you need the further information or consultation, please contact us via :

Email : - beltway.doctor@medikaplaza.com  
- beltway.doctor2@medikaplaza.com

Telepon Klinik : (62-21) 8086 6099

PRIVATE

Printed by : reysti

**CLINICAL EVALUATION**

<b>Name</b> : AJAT SUDRAJAT	<b>Sex</b> : Male	<b>MR</b> : 01004054	<b>Visit</b> : 26/02/2021
<b>Comp.</b> : INSPEKTINDO SINERGI PERSADA, PT		<b>DOB</b> : 25 May 1986	
<b>EXAMINATION</b>	<b>RESULT</b>	<b>NOTES</b>	

**ANAMNESIS****PRESENT COMPLAINT AND HISTORY OF PRESENT****ILLNESS**

Present complaint

No complaint

**MEDICAL HISTORY**

Alergy

No

Imunisasi

Yes

Surgery

Yes

Appendectomy

Hospitalization

No

Disease

No

**LIFE STYLE**

Alcohol intake

No

Smoking

Yes

Moderate smoker

Exercise

Yes

Basketball

**FAMILY MEDICAL HISTORY**

Diabetes Melitus

No

Hypertension

No

Heart disease

No

Lung TB

No

Kidney disease

No

Astma

No

Mental disease

No

Epilepsy

No

Cancer

No

Color blind

No

Stroke

No

Liver disease

No

Bone &amp; joint

No

Others disease

No

**WORK EXPOSURE**

Noise

No

Heat Stress

No

Cold Stress

No

Vibration

No

Involving height

No

Radiation

No

Dust

No

## CLINICAL EVALUATION

Name : AJAT SUDRAJAT	Sex : Male	MR : 01004054	Visit : 26/02/2021
Comp. : INSPEKTINDO SINERGI PERSADA, PT		DOB : 25 May 1986	
EXAMINATION	RESULT	NOTES	

Toxic chemical	No
Irritating fluid	No
Smoke	No
Bacterium/Virus/Parasite	No
Blood	No
Animal	No
Operating heavy mobile equipment	No
Manual Handling	No
Sitting continuously over 4 hours	No
Stand continuously over 4 hours	No
Using monitor screen more than 4 hours per day	No
Exposure	No
Unergonomic body positions	No
Shift work	No
Work is not accordance with skills and knowledge	No
Workload does not accordance with time	No
Work conflict	No
Inappropriate task	No
Career barriers	No
Family conflict	No
Working around rotating machinery	No
Administration work	No
Handling food product	No
Others	Yes

### PHYSICAL EXAMINATION

General Appearance	Good
Body shape	Picnicus

### VITAL SIGN

Body Weight	87.6 Kg
Body Height	172 Cm
BMI	29.61 Kg/m <sup>2</sup>
Normal Weight	54.73 - 73.96 Kg
BMI Conclusion	Overweight
Blood Pressure	100/70 mmHg
Pulse	72 x/minute
Body Temperature	36.2 °C
RR	20

## CLINICAL EVALUATION

Name : AJAT SUDRAJAT	Sex : Male	MR : 01004054	Visit : 26/02/2021
Comp.: INSPEKTINDO SINERGI PERSADA, PT		DOB : 25 May 1986	

EXAMINATION	RESULT	NOTES
Neck Circumference	35 Cm	
Arm Circumference	36 Cm	
Chest size	100 Cm	
Abdominal Circumference	100 Cm	
<b>SKIN</b>		
Skin	Normal	
<b>EYE</b>		
Left	Normal	
Right	Normal	
<b>ENT</b>		
Auricle	Normal	
Ear canal	Normal	
Drums	Normal	
Septum/Conchae	Normal	
Sinuses	Normal	
Pharynx	Normal	
Tonsil	Normal	
<b>MOUTH</b>		
Gum	Normal	
Dental	Abnormal	Calculus, decayed, missing, and stain teeth
<b>NECK</b>		
General	Normal	
Thyroid Gland	Normal	
<b>CHEST</b>		
Form	Normal	
Lung	Normal	
Heart	Normal	
Breast	Normal	
<b>ABDOMEN</b>		
Form	Flat	
Palpation	Supple	
Liver	Not Palpable	
Spleen	Not Palpable	
Kidney	No Ballotment	
-	No	
Hernia inguinal	No	
<b>EXTRIMITIES</b>		

## CLINICAL EVALUATION

Name : AJAT SUDRAJAT	Sex : Male	MR : 01004054	Visit : 26/02/2021
Comp.: INSPEKTINDO SINERGI PERSADA, PT		DOB : 25 May 1986	
EXAMINATION	RESULT	NOTES	

Bones, joint	Normal
Muscles, tonus	Normal
Fingernails	Normal
Hand	Normal
Foot	Normal

### RECTAL EXAMINATION

Hemorrhoid	Negative
Rectum	Normal

### SENSORIK EXAMINATION

Tes Raba	Normal
----------	--------

### MOTORIK EXAMINATION

Tes Grip	Normal
----------	--------

### REFLEX EXAMINATION

Physiologic reflex	Normal
Patologic reflex	Normal

### OTHERS EXAMINATION

Coordination	Normal
--------------	--------

### LYMPHE SYSTEM

Submandibula	Normal
Neck Gland	Normal
Armpit gland	Normal
Inguinal	Normal

## OPHTHALMOLOGY DIAGNOSTIC

Name : AJAT SUDRAJAT		Sex : Male	MR : 01004054	Visit : 26/02/2021
Comp.: INSPEKTINDO SINERGI PERSADA, PT			DOB : 25 May 1986	
EXAMINATION		Right	Left	
Reading		-		
Previous Glasses		-	-	
Without Glasses	Distant	20/20	20/20	
	Near	J1	J1	
Correction	Distant	-	-	
	Near	-	-	
Depth Perception		-		
Tonometry		16.0 mmHg	15.0 mmHg	
Funduscopy		NORMAL	NORMAL	
Visual Fields		-		
Colour Blind Test		Normal		

Impression :



**RADIOLOGY DIAGNOSTIC****Name** : AJAT SUDRAJAT**Sex** : Male**MR** : 01004054**Visit** : 26/02/2021**Comp.**: INSPEKTINDO SINERGI PERSADA, PT**DOB** : 25 May 1986**EXAMINATION****RESULT**

THORAX PA

No abnormality seen in both lungs.  
Normal bronchovascular markings in both hili.  
The heart is normal in size and shape.  
The mediastinum is not widened.  
Both sinus and diaphragms are good.  
No evidence of pleural effusion.

Impression

Normal heart and lungs

## LABORATORY RESULT

Name : AJAT SUDRAJAT	MR : 01004054	Visit : 26/02/2021	#Lab : IN733129153204
Comp.: INSPEKTINDO SINERGI PERSADA, PT	Sex : Male	DOB : 25 May 1986	
EXAMINATION	RESULT	NORMAL RANGE	

### HEMATOLOGI

ABO/Rh Typing "O" Rh(+) positive

#### Automated Blood Count

White Blood Cell (WBC)	9.6	3.8 - 11.0
Erythrocyte (RBC)	6.0 *	4.4 - 5.9
Haemoglobin	17.3	13.2 - 17.3
Hematocrit	50	40 - 52
Thrombocytes	313	150 - 440

#### MCV, MCH, MCHC

MCV	80	80 - 100
MCH	29	26 - 34
MCHC	35.7	32 - 36
ESR	10	0 - 10

#### Differential Count

Basophils	1	0 - 1
Eosinophil	2	2 - 4
Bands / Stab	3	3 - 5
Neutrophils	58	50 - 70
Lymphocytes	32	25 - 40
Monocytes	4	2 - 8

### BLD CHEMISTRY/LIPID PROFILE

Total Cholesterol	250 *	Normal/Desireable: <200 Borderline High: 200-239 High: >=240
HDL Cholesterol	51.9	Normal : >40 - <60 Low HDL : <40 Desireable : >=60
LDL Cholesterol	108	Optimal: <100 Near/Above Optimal: 100-129 Borderline High: 130-159 High: 160-189 Very High: >=190
Triglycerides	451 *	Normal : <150 Borderline High: 150-199 High : 200-499 Very High : >=500

### BLD CHEMISTRY/KIDNEY FUNCTION

## LABORATORY RESULT

Name : AJAT SUDRAJAT	MR : 01004054	Visit : 26/02/2021	#Lab : IN733129153204
Comp.: INSPEKTINDO SINERGI PERSADA, PT	Sex : Male	DOB : 25 May 1986	

EXAMINATION	RESULT	NORMAL RANGE
Ureum	15.8	10.0 - 50.0
Creatinine	0.9	0.6- 1.3
Uric Acid	7.53 *	3.50 - 7.20

### BLD CHEMISTRY/LIVER FUNCTION

SGOT(AST)	23	13 - 45
SGPT (ALT)	31	13 - 50
Gamma GT	40	0 - 50

### BLD CHEMISTRY/DIABETES

Glucose Fasting	102 *	< 100
Glucose Urine	Negative	Negative
Keton Urine	Negative	Negative

### URINALYSIS

#### Complete Urine Analysis

##### Macroscopic

Color	Yellow	
Turbidity	Clear	Clear
Specific Gravity	1.021	1.000 - 1.030
pH	6.0	4.5 - 8.0
Leucocyte	Negative	Negative
Glucose	Negative	Negative
Nitrit	Negative	Negative
Bilirubin	Negative	Negative
Blood	Negative	Negative
Urobilinogen	Normal	Normal
Protein	Negative	Negative
Keton	Negative	Negative

##### Microscopic

RBC	0-1	0 - 1
WBC	0-1	0 - 4
Cylinder	Negative	
Epithels Squamous	0-1	5 - 15
Crystals	Negative	
Bacteria	Negative	Negative
Others	Negative	

### STOOL / RECTAL SWAP

#### Faeces Complete

##### Macroscopic

**LABORATORY RESULT**

Name : AJAT SUDRAJAT

MR : 01004054

Visit : 26/02/2021

#Lab : IN733129153204

Comp. : INSPEKTINDO SINERGI PERSADA, PT

Sex : Male

DOB : 25 May 1986

EXAMINATION	RESULT	NORMAL RANGE
Color	Brown	
Consistency	Smooth	
Mucus	Negative	Negative
Blood	Negative	Negative
Pus	Negative	Negative
Parasit	Negative	Negative
Lipid	Negative	Negative
<b>Microscopic</b>		
RBC	0-1	0 - 1
WBC	0-1	0 - 5
Amoeba	Negative	
Ephitels	Positive	Positive
Worm Eggs	Negative	Negative
Yeast	Negative	Negative
Muscle Fiber	Negative	Negative
Others	Negative	Negative
<b>Digestive</b>		
Amylum	Negative	Negative
Fat	Negative	
Fibers	Positive	Positive

# AUDIOMETRY DIAGNOSTIC

Name : AJAT SUDRAJAT

Sex : Male

MR : 01004054

Visit : 26/02/2021

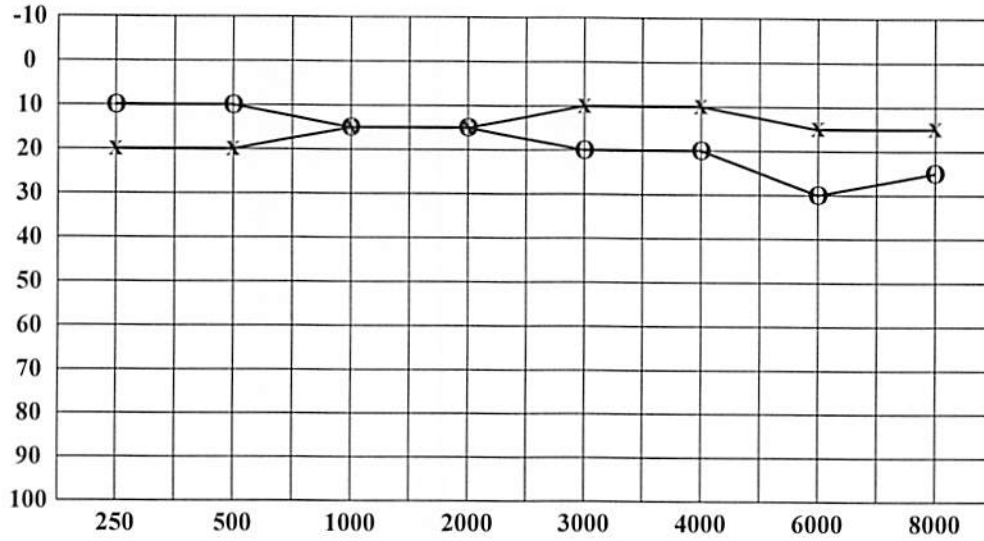
Comp.: INSPEKTINDO SINERGI PERSADA, PT

DOB : 25 May 1986

## RESULT

Left Ear	250	500	1000	2000	3000	4000	6000	8000
AC	20	20	15	15	10	10	15	15
BC	-	-	-	-	-	-	-	-

Right Ear	250	500	1000	2000	3000	4000	6000	8000
AC	10	10	15	15	20	20	30	25
BC	-	-	-	-	-	-	-	-



< : Right Ear (BC)

> : Left Ear (BC)

O : Right Ear (AC)

X : Left Ear (AC)

Conclusion Right Ear : Hearing threshold = 15 dB  
(Within normal limit)  
With decreasing on frequency 6000Hz

Conclusion Left Ear : Hearing threshold = 15 dB  
(Within normal limit)

# CARDIOLOGY DIAGNOSTIC


Name : AJAT SUDRAJAT	Sex : Male	MR : 01004054	Visit : 26/02/2021
Comp.: INSPEKTINDO SINERGI PERSADA, PT		DOB : 25 May 1986	

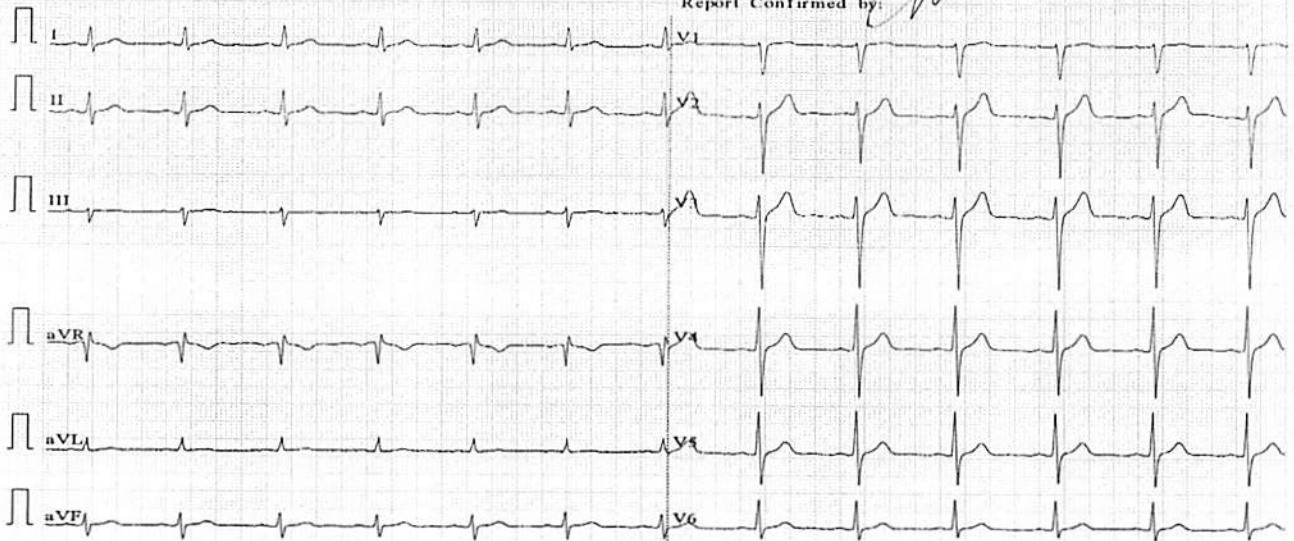
EXAMINATION	RESULT	Comments :
ELECTROCARDIOGRAPHY	Sinus Rythm axis ( N ), P wave ( N ), PR int 0.16" ST - T segment ( N ), aritmia (-)	Normal ECG

ID: 18  
AJAT SUDRAJAT  
Male 34Years

26-02-2021 09:41:30  
HR : 76 bpm  
P : 122 ms  
PR : 156 ms  
QRS : 88 ms  
QT/QTc : 350/394 ms  
P/QRS/T : 43/3/43  
RV5/SV1 : 1.242/0.824 mV

Diagnosis Information:  
Sinus rhythm  
Normal ECG

Report Confirmed by: 



0.67-100Hz AC50 25mm/s 10mm/mV 2\*5.0s ♥76 SE-1200Expressa V2.21 Glasgow V28.6.0