

Certificate Of Health Assessment

Name	Age	Position	Department
SYAIFUL	39 yo	INSPECTOR	-

COMPANY :

INSPEKTINDO SINERGI PERSADA

CONCLUSION


FIT TO WORK

FIT WITH MEDICAL NOTE

✓

TEMPORARY UNFIT

UNFIT

Issued Date	Doctors Name	Prepared By
26 December 2022	Yosephine Simanungkalit, MD PKTK : KEP.043/BINWASK3-PNK3 KK/II/2018 SIP : I/B.15a/31.74.02.1004/-1.779.3/e/2019 PT. KARTIKA BINA MEDIKATAMA	 PT. KARTIKA BINA MEDIKATAMA
Expired Date		
26 December 2023		

No. Formulir : FM-DR-008-05

No. Revisi : 00

Tanggal Terbit : 2 Mei 2011

Certificate Number : MP-WTC2/2-20221226/1004

MCU Validity Check

<https://mcu-validasi.medikaplaza.com>

PT. KARTIKA BINA MEDIKATAMA

HEAD OFFICE : BELTWAY OFFICE PARK, TOWER C, 2nd Floor, Jl. TB. Simatupang Kav 41. Jakarta Selatan 12550, Phone : +62 21 808 66 088, Fax : +62 21 808 66 089

BELTWAY CLINIC : BELTWAY OFFICE PARK, ANNEX BUILDING, Ground Floor, Jl. TB. Simatupang Kav 41. Jakarta Selatan 12550, Phone : +62 21 808 66 099, Fax : +62 21 808 66 098

WTC 2 CLINIC : World Trade Center 2, Lower Ground Floor, Jl. Jend. Sudirman Kav 29. Jakarta Selatan 12920, Phone : +62 21 295 22 611, Fax : +62 21 295 22 610

www.medikaplaza.com

TO WHOM IT MAY CONCERN

Kepada yang berkepentingan

This is certify that today Monday, 26 December 2022 Medika Plaza Clinic has performed urine drug screening and/or breath alcohol test to :

Dengan ini menyatakan bahwa, pada hari ini Senin, 26 Desember 2022 Medika Plaza Clinic telah melakukan urine drug screening dan/atau breath alcohol test kepada :

SYAIFUL

With the results are as follows :
Dengan hasil sebagai berikut :

<u>Drugs Test</u> <i>Uji Obat</i>	<u>Result</u> <i>Hasil</i>		
URINE DRUGS SCREENING			
- Amphetamine	<input type="checkbox"/> Non-Negative	<input checked="" type="checkbox"/> Negative	<input type="checkbox"/> N/A
- Met-Amphetamine	<input type="checkbox"/> Non-Negative	<input checked="" type="checkbox"/> Negative	<input type="checkbox"/> N/A
- Cocain	<input type="checkbox"/> Non-Negative	<input checked="" type="checkbox"/> Negative	<input type="checkbox"/> N/A
- THC/Canabis/Marijuana	<input type="checkbox"/> Non-Negative	<input checked="" type="checkbox"/> Negative	<input type="checkbox"/> N/A
- Morphine/Opiates	<input type="checkbox"/> Non-Negative	<input checked="" type="checkbox"/> Negative	<input type="checkbox"/> N/A
- P C P/Phencyclidine	<input type="checkbox"/> Non-Negative	<input checked="" type="checkbox"/> Negative	<input type="checkbox"/> N/A
- Barbiturate	<input type="checkbox"/> Non-Negative	<input type="checkbox"/> Negative	<input checked="" type="checkbox"/> N/A
- Benzodiazepin	<input type="checkbox"/> Non-Negative	<input checked="" type="checkbox"/> Negative	<input type="checkbox"/> N/A
- Methadone	<input type="checkbox"/> Non-Negative	<input checked="" type="checkbox"/> Negative	<input type="checkbox"/> N/A
- Propoxyphene	<input type="checkbox"/> Non-Negative	<input type="checkbox"/> Negative	<input checked="" type="checkbox"/> N/A
- Oxycodone	<input type="checkbox"/> Non-Negative	<input type="checkbox"/> Negative	<input checked="" type="checkbox"/> N/A
- MDMA	<input type="checkbox"/> Non-Negative	<input type="checkbox"/> Negative	<input checked="" type="checkbox"/> N/A
- 6-MAM	<input type="checkbox"/> Non-Negative	<input type="checkbox"/> Negative	<input checked="" type="checkbox"/> N/A
BREATH ALCOHOL TEST			
- Alcohol	<input type="checkbox"/> Non-Negative	<input checked="" type="checkbox"/> Negative	<input type="checkbox"/> N/A

Jakarta, December 26, 2022



PT. KARTIKA BINA MEDIKATAMA
(dr. Vivi Surjaningsih, Sp.PK)
Clinical Patologist

PT. KARTIKA BINA MEDIKATAMA

HEALTH ASSESSMENT REPORT

Of

SYAIFUL
01084977

Monday, 26 December 2022

MP WTC 2 CLINIC

World Trade Centre 2, Lower Ground Floor
Jl. Jend. Sudirman, Kav. 29 Jakarta Selatan 12920
Tlp : (62-21) 295 22 611, Fax : (62-21) 295 22 611
www.medikaplaza.com

MP WTC 2 CLINIC

World Trade Centre 2, Lower Ground Floor
Jl. Jend. Sudirman, Kav. 29 Jakarta Selatan 12920
Tlp : (62-21) 295 22 611, Fax : (62-21) 295 22 611
www.medikaplaza.com

PATIENT DATA

MedRec.	: 01084977	EMPLOY. STATUS	: Employee
NAME	: SYAIFUL	BIRTHDATE	: 03 February 1983
EMPLOYEE No.	: -	SEX	: Male
JOB TITLE	: INSPECTOR	STATUS	: Married
COMP. NAME	: INSPEKTINDO SINERGI PERSADA	NASIONALITY	: INDONESIA

SUMMARY

MEDICAL FINDING :

1. Leucocytosis
2. Hypercholesterolemia with fatty liver
3. Increased fasting blood sugar
4. Non-reactive anti HBs
5. Decreasing of hearing acuity on low frequency of both ears
6. Abdominal USG: gall bladder stone
7. Decreasing of visual acuity of both eyes
8. Suspect ocular hypertension on the right eye
9. Tonsil hypertrophy T2/T2
10. Decayed, radix, missing, and calculus teeth

Your fitness status is fit with medical note:

1. Leucocytosis
2. Abdominal USG: gall bladder stone
3. Suspect ocular hypertension on the right eye

SUGGESTION :

1. Consultation with an Internist for further evaluation of leucocytosis
2. Low fat diet and exercise regularly minimum 3x/week. Repeat abdominal USG 6 months later and consultation with an Internist to evaluate fatty liver
3. Low sugar diet and repeat blood glucose examination 1 month later. Consultation with an Internist if blood glucose still increase
4. Need to get Hepatitis B vaccination (booster)
5. Avoid noisy environment and use earplug properly while working at noisy work environment to prevent further hearing impairment
6. Consultation with a Surgeon for further evaluation of Abdominal USG: gall bladder stone
7. You need to wear glasses for distant vision
8. Consultation with an Ophthalmologist for further evaluation of Suspect ocular hypertension on the right eye
9. Consultation with an ENT specialist if any complaint of Tonsil hypertrophy T2/T2
10. Consultation with a Dentist for dental care, minimal once a year or better once in six month

Responsible Doctor



Yosephine Shmanungkalit, MD

Notes:

If you need the further information or consultation, please contact us via :

Email : - dr.yunianti@medikaplaza.com
- shezarina.pratita@medikaplaza.com
- aloisia.sari@medikaplaza.com
- Shani.Fuad@medikaplaza.com

Telepon Klinik : (62-21) 295 22 611

CLINICAL EVALUATION

Name : SYAIFUL	Sex : Male	MR : 01084977	Visit : 26/12/2022
Comp. : INSPEKTINDO SINERGI PERSADA		DOB : 03 February 1983	

EXAMINATION	RESULT	NOTES
-------------	--------	-------

ANAMNESA

PRESENT COMPLAINT AND HISTORY OF PRESENT

ILLNESS

Present complaint No complaint

MEDICAL HISTORY

Alergy	No
Imunisasi	Yes
Surgery	No
Hospitalization	No
Disease	No

LIFE STYLE

Alcohol intake	No	
Smoking	Yes	Mild smoker
Exercise	Yes	Futsal/ running, 1x/week

FAMILY MEDICAL HISTORY

Diabetes Melitus	No
Hypertension	No
Heart disease	No
Lung TB	No
Kidney disease	No
Astma	No
Mental disease	No
Epilepsy	No
Cancer	No
Color blind	No
Stroke	No
Liver disease	No
Bone & joint	No
Others disease	No

WORK EXPOSURE

Noise	Yes	Wearing PPE
Heat Stress	No	
Cold Stress	No	
Vibration	Yes	
Involving height	Yes	
Radiation	No	
Dust	Yes	Wearing PPE

CLINICAL EVALUATION

Name : SYAIFUL	Sex : Male	MR : 01084977	Visit : 26/12/2022
Comp. : INSPEKTINDO SINERGI PERSADA		DOB : 03 February 1983	

EXAMINATION	RESULT	NOTES
Toxic chemical	No	
Irritating fluid	No	
Smoke	Yes	Wearing PPE
Bacterium/Virus/Parasite	No	
Blood	No	
Animal	No	
Operating heavy mobile equipment	No	
Manual Handling	No	
Sitting continuously over 4 hours	No	
Stand continuously over 4 hours	No	
Using monitor screen more than 4 hours per day	No	
Exposure	No	
Unergonomic body positions	No	
Shift work	No	
Work is not accordance with skills and knowledge	No	
Workload does not accordance with time	No	
Work conflict	No	
Inappropriate task	No	
Career barriers	No	
Family conflict	No	
Working around rotating machinery	Yes	
Administration work	No	
Handling food product	No	
Others	Yes	Inspector (Field Work, Onshore and Offshore, 2012)

PHYSICAL EXAMINATION

General Appearance	Good
Body shape	Athleticus

VITAL SIGN

Body Weight	69.3 Kg
Body Height	167 Cm
BMI	24.84 Kg/m ²
Normal Weight	51.59 - 69.72 Kg
BMI Conclusion	Normal
Blood Pressure	120/80 mmHg
Pulse	78 x/minute
Body Temperature	36.8 °C

CLINICAL EVALUATION

Name : SYAIFUL	Sex : Male	MR : 01084977	Visit : 26/12/2022
Comp. : INSPEKTINDO SINERGI PERSADA		DOB : 03 February 1983	

EXAMINATION	RESULT	NOTES
RR	20	
Neck Circumference	36 Cm	
Arm Circumference	28 Cm	
Chest size	93 Cm	
Abdominal Circumference	86 Cm	
SKIN		
Skin	Normal	
EYE		
Left	Normal	
Right	Normal	
ENT		
Auricle	Normal	
Ear canal	Normal	
Drums	Normal	
Septum/Conchae	Normal	
Sinuses	Normal	
Pharynx	Normal	
Tonsil	Abnormal	Tonsil hypertrophy T2/T2
MOUTH		
Gum	Normal	
Dental	Abnormal	Decayed, radix, missing, and calculus teeth
NECK		
General	Normal	
Thyroid Gland	Normal	
CHEST		
Form	Normal	
Lung	Normal	
Heart	Normal	
Breast	Normal	
ABDOMEN		
Form	Flat	
Palpation	Supple	
Liver	Not Palpable	
Spleen	Not Palpable	
Kidney	No Ballotment	
Nyeri Ketok (CVA)	No	
Hernia inguinal	No	

CLINICAL EVALUATION

Name : SYAIFUL	Sex : Male	MR : 01084977	Visit : 26/12/2022
Comp. : INSPEKTINDO SINERGI PERSADA		DOB : 03 February 1983	

EXAMINATION	RESULT	NOTES
EXTRIMITIES		
Bones,joint	Normal	
Muscles,tonus	Normal	
Fingernails	Normal	
Hand	Normal	
Foot	Normal	
RECTAL EXAMINATION		
Hemorrhoid	Negative	
Rectum	Not Examined	
SENSORIK EXAMINATION		
Tes Raba	Normal	
MOTORIK EXAMINATION		
Tes Grip	Normal	
REFLEX EXAMINATION		
Physiologic reflex	Normal	
Patologic reflex	Normal	
OTHERS EXAMINATION		
Coordination	Normal	
LYMPHE SYSTEM		
Submandibula	Normal	
Neck Gland	Normal	
Armpit gland	Normal	
Inguinal	Normal	

OPHTHALMOLOGY DIAGNOSTIC

Name : SYAIFUL Sex : Male MR : 01084977 Visit : 26/12/2022

Comp. : INSPEKTINDO SINERGI PERSADA DOB : 03 February 1983

EXAMINATION		Right	Left
Reading		-	
Previous Glasses		-	-
Without Glasses	Distant	20/30	20/50
	Near	J1	J1
Correction	Distant	C-0.75X90 20/20	C-1.25X90 20/20
	Near	-	-
Depth Perception		-	
Tonometry		24.0 mmHg	19.0 mmHg
Funduscopy		NORMAL	NORMAL
Visual Fields		Normal	
Colour Blind Test		Normal	

Impression : Astigmatism myopia simplex ODS
Suspect ocular hypertension OD

RADIOLOGY DIAGNOSTIC

Name : SYAIFUL

Sex : Male

MR : 01084977

Visit : 26/12/2022

Comp. : INSPEKTINDO SINERGI PERSADA

DOB : 03 February 1983

EXAMINATION

RESULT

THORAX PA

No abnormality seen in both lungs.
Normal bronchovascular markings in both hili.
The heart is normal in size and shape.
The mediastinum is not widened.
Both sinuses and diaphragms are good.
No evidence of pleural effusion.
No abnormality of chest skeletal.

Impression

Normal Chest x-ray

RADIOLOGY DIAGNOSTIC

Name : SYAIFUL

Sex : Male

MR : 01084977

Visit : 26/12/2022

Comp. : INSPEKTINDO SINERGI PERSADA

DOB : 03 February 1983

EXAMINATION**RESULT**

USG ABDOMEN

LIVER:

Normal in size and contour, smooth surface, hyperechoic homogeneous parenchymal structure.

No sign of SOL.

Intrahepatic vascularity and biliary tract are normal.

GALL BLADDER:

Normal in size, contour and surface. No sign of SOL/ sludge.

Multiple stones diameter 0.55cm, 0.61cm and 0.62cm at gall bladder lumen.

RIGHT KIDNEY :

Normal in size, contour and surface. No sign of obstruction/ stone/ SOL.

LEFT KIDNEY:

Normal in size, contour and surface. No sign of obstruction/ stone/ SOL.

PANCREAS:

Normal in size, contour and surface. No sign of SOL.

LIEN:

Normal in size and contour, the echoes are homogeneous. No sign of SOL.

URINARY BLADDER:

Normal in size, contour and surface. No sign of stone/ SOL.

PROSTATE AND VESICULA SEMINALIS:

Normal in size and contour which are homogeneous echoes and no sign of focal lesion/ SOL.

Impression

Fatty Liver.

Gall Bladder stones.

LABORATORY RESULT

Name : SYAIFUL	MR : 01084977	Visit : 26/12/2022	#Lab : IN80002599000
Comp. : INSPEKTINDO SINERGI PERSADA	Sex : Male	DOB : 03 February 1983	
EXAMINATION	RESULT	NORMAL RANGE	

HEMATOLOGI

ABO/Rh Typing "A" Rh(+) positive

Automated Blood Count

White Blood Cell (WBC)	14.5 *	3.8 - 11.0
Erythrocyte (RBC)	5.6	4.4 - 5.9
Haemoglobin	16.3	13.2 - 17.3
Hematocrit	49	40 - 52
Thrombocytes	409	150 - 440

MCV, MCH, MCHC

MCV	86	80 - 100
MCH	29	26 - 34
MCHC	33.6	32 - 36
ESR	11 *	0 - 10

Differential Count

Basophils	0	0 - 1
Eosinophil	1 *	2 - 4
Bands / Stab	3	3 - 5
Neutrophils	70	50 - 70
Lymphocytes	19 *	25 - 40
Monocytes	7	2 - 8

BLD CHEMISTRY/LIPID PROFILE

Total Cholesterol	196	Normal/Desireable: <200 Borderline High: 200-239 High: >=240
HDL Cholesterol	33.4 *	Normal : >40 - <60 Low HDL : <40 Desireable : >=60
LDL Cholesterol	134 *	Optimal: <100 Near/Above Optimal: 100-129 Borderline High: 130-159 High: 160-189 Very High: >=190
Triglyerides	142	Normal : <150 Borderline High: 150-199 High : 200-499 Very High : >=500

BLD CHEMISTRY/KIDNEY FUNCTION

LABORATORY RESULT

Name : SYAIFUL MR : 01084977 Visit : 26/12/2022 #Lab : IN80002599000

Comp. : INSPEKTINDO SINERGI PERSADA Sex : Male DOB : 03 February 1983

EXAMINATION	RESULT	NORMAL RANGE
Ureum	12.3	10.0 - 50.0
Creatinine	0.81	0.60 - 1.30
Uric Acid	6.50	3.50 - 7.20

BLD CHEMISTRY/LIVER FUNCTION

Total Bilirubin	0.46	0.1 - 1.0
Direct Bilirubin	0.16	0.0 - 0.2
Indirect Bilirubin	0.30	0.0 - 0.8
SGOT(AST)	26	13 - 45
SGPT (ALT)	31	13 - 50
Alkaline Phosphatase	68	30 - 120
Gamma GT	27	0 - 50
Albumin	4.9	3.5 - 5.5
Globulin	3.00	2.3 - 3.5
Total Protein	7.9	6.6 - 8.7

BLD CHEMISTRY/DIABETES

Glucose Fasting	105 *	< 100
Glucose Urine	Negative	Negative
Keton Urine	Negative	Negative

Blood Glucose 2 PP

Blood Sugar 2 Hours PP	82	< 140
Glucose Urine	Negative	Negative
Keton Urine	Negative	Negative

SEROLOGI / IMUNOLOGI

HBsAg (Quantitative)	0.00	0.00 - 0.03
Anti Hbs (Quantitative)	0.2 *	>= 5.0

TOXICOLOGY - DRUGS SCREENING

Methadone	Negative	Negative
Phencyclidine	Negative	Negative
THC/Marijuana	Negative	Negative
Amphetamine	Negative	Negative
Benzodiazepines	Negative	Negative
Opiat	Negative	Negative
Cocain	Negative	Negative
Metamphetamine	Negative	Negative
Alcohol	Negative	Negative

URINALYSIS**Complete Urine Analysis**

LABORATORY RESULT

Name : SYAIFUL	MR : 01084977	Visit : 26/12/2022	#Lab : IN80002599000
Comp. : INSPEKTINDO SINERGI PERSADA	Sex : Male	DOB : 03 February 1983	
EXAMINATION	RESULT	NORMAL RANGE	

Macroscopic

Color	Yellow	
Turbidity	Clear	Clear
Specific Gravity	1.010	1.000 - 1.030
pH	6.0	4.5 - 8.0
Leucocyte	Negative	Negative
Glucose	Negative	Negative
Nitrit	Negative	Negative
Bilirubin	Negative	Negative
Blood	Negative	Negative
Urobilinogen	Normal	Normal
Protein	Negative	Negative
Keton	Negative	Negative

Microscopic

RBC	0-1	0 - 1
WBC	0-1	0 - 4
Cylinder	Negative	
Epithels Squamous	0-1	5 - 15
Crystals	Negative	
Bacteria	Negative	Negative
Others	Negative	

STOOL / RECTAL SWAP

Faeces Complete

Macroscopic

Color	Brown	
Consistency	Smooth	
Mucus	Negative	Negative
Blood	Negative	Negative
Pus	Negative	Negative
Parasit	Negative	Negative
Lipid	Negative	Negative

Microscopic

RBC	0-1	0 - 1
WBC	0-1	0 - 5
Amoeba	Negative	
Ephitels	Positive	Positive
Worm Eggs	Negative	Negative

LABORATORY RESULT

Name : SYAIFUL	MR : 01084977	Visit : 26/12/2022	#Lab : IN80002599000
----------------	---------------	--------------------	----------------------

Comp. : INSPEKTINDO SINERGI PERSADA	Sex : Male	DOB : 03 February 1983
-------------------------------------	------------	------------------------

EXAMINATION	RESULT	NORMAL RANGE
Yeast	Negative	Negative
Muscle Fiber	Negative	Negative
Others	Negative	Negative
Digestive		
Amylum	Negative	Negative
Fat	Negative	
Fibers	Positive	Positive

SPIROMETRY DIAGNOSTIC

Name : SYAIFUL	Sex : Male	MR : 01084977	Visit : 26/12/2022
Comp. : INSPEKTINDO SINERGI PERSADA		DOB : 03 February 1983	

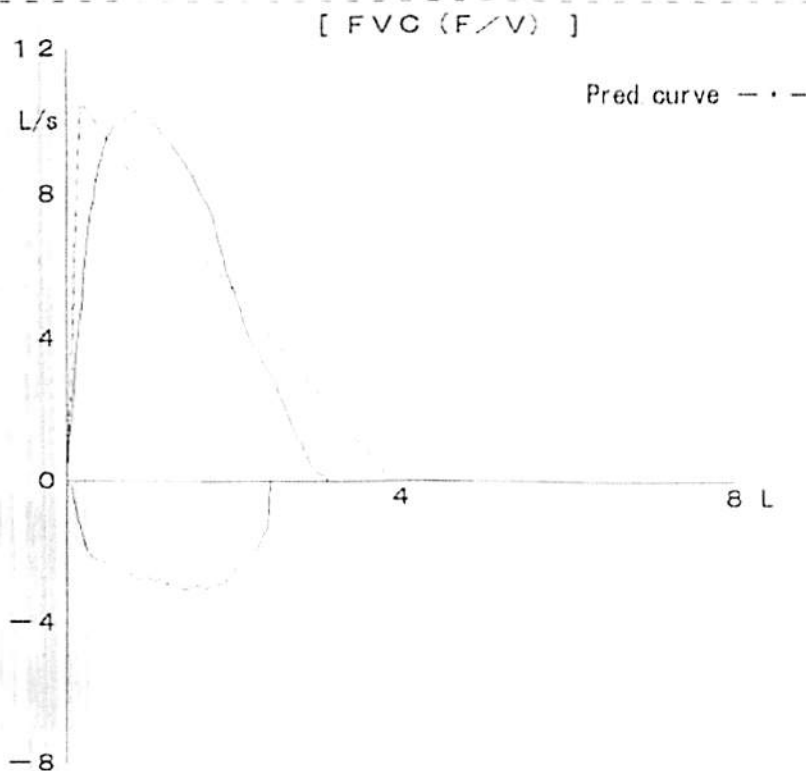
EXAMINATION	RESULT
FVC Result	: 3.14 L---> 80.9 %
FEV1 Result	: 3.00 L---> 86.7 %
FEV1/FVC Result	: 95.54 %---> 123.7 %
PEF Result	: 10.26 L/S---> 98.6 %
Indonesian Standart Result	:
Index	:
Spirometry Result	: Normal

Impression : Normal Spirometric Functions

[COPD CLASSIFICATION]

FEV1/FVC	95.54 %
%FEV1 0	86.70 %
Stage	Normal
Recommended treatment by GOLD	

Syaitul



AUDIOMETRY DIAGNOSTIC

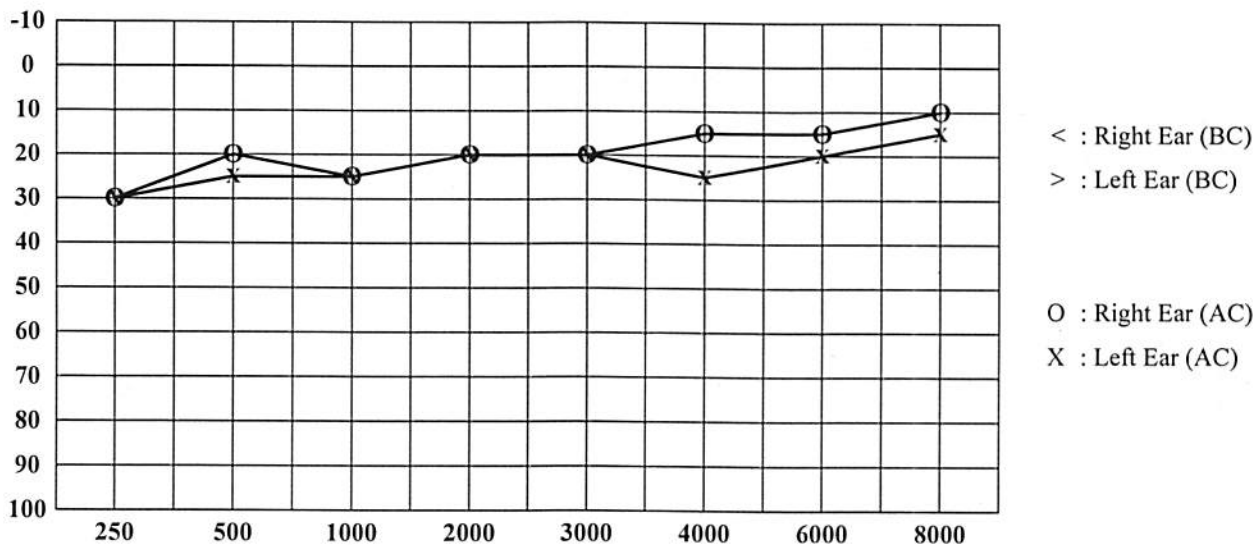
Name : SYAIFUL Sex : Male MR : 01084977 Visit : 26/12/2022

Comp. : INSPEKTINDO SINERGI PERSADA DOB : 03 February 1983

RESULT

Left Ear	250	500	1000	2000	3000	4000	6000	8000
AC	30	25	25	20	20	25	20	15
BC	-	-	-	-	-	-	-	-

Right Ear	250	500	1000	2000	3000	4000	6000	8000
AC	30	20	25	20	20	15	15	10
BC	-	-	-	-	-	-	-	-



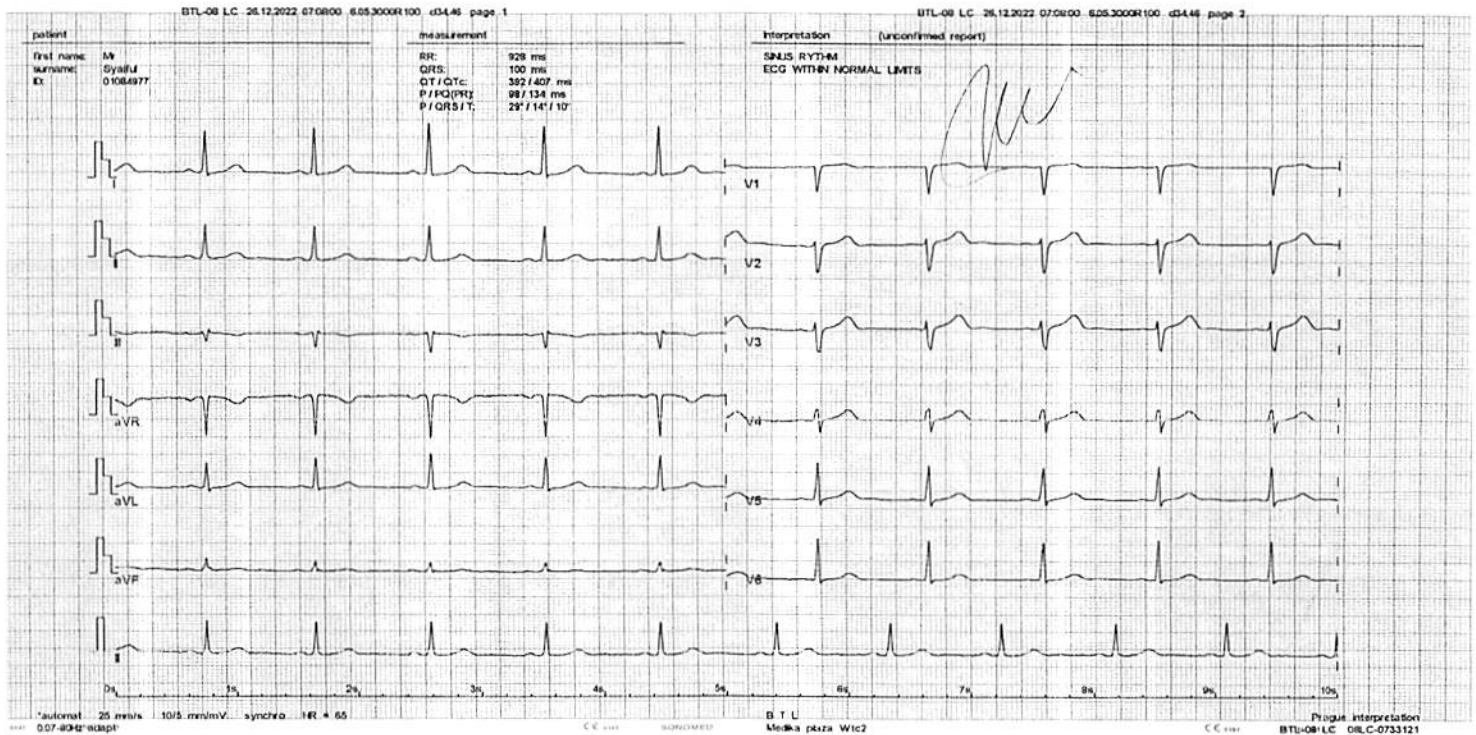
Conclusion Right Ear : Hearing threshold = 20 dB
 (Within normal limit)
 With decreasing on frequency 250Hz

Conclusion Left Ear : Hearing threshold = 23.75 dB
 (Within normal limit)
 With decreasing on frequency 250Hz

CARDIOLOGY DIAGNOSTIC

Name : SYAIFUL	Sex : Male	MR : 01084977	Visit : 26/12/2022
Comp. : INSPEKTINDO SINERGI PERSADA		DOB : 03 February 1983	

EXAMINATION	RESULT	Comments :
ELECTROCARDIOGRAPHY	Sinus Rythm axis (N), P wave (N), PR int 0.16" ST - T segment (N), aritmia (-)	Normal ECG
TREADMILL	Sinus Rythm axis (N), P wave (N), PR int 0.16" ST - T segment (N), aritmia (-)	Treadmill Exercise Test : Negative Cardiopulmonary Fitness Classification : Good METs : 13.4



SYAIFUL MR
Patient ID: 01084977
26.12.2022
9:12:02am

12-LEAD REPORT

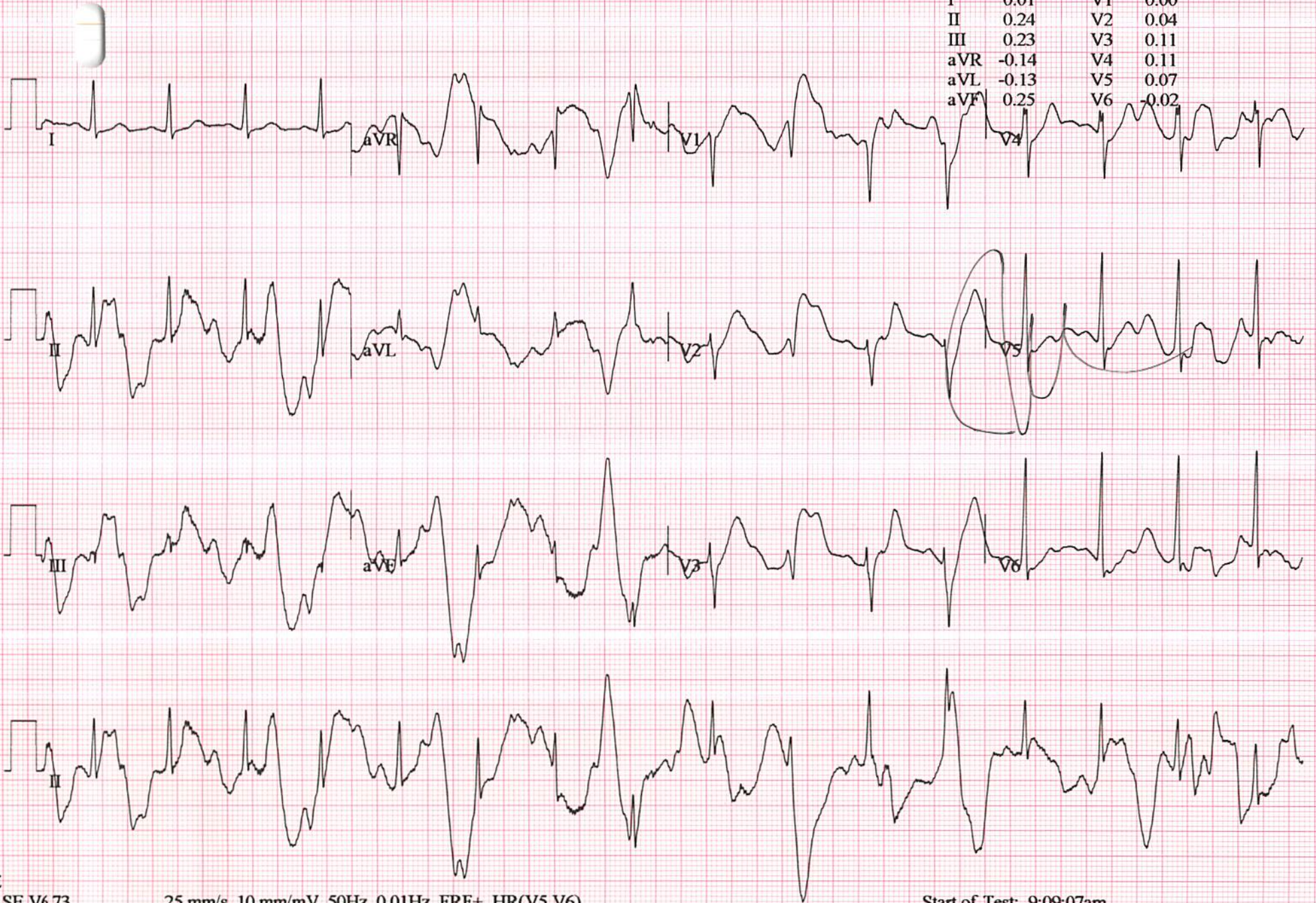
98 bpm
120/80 mmHg

EXERCISE
STAGE 1
02:50

BRUCE
2.7 km/h
10.0 %

MEDIKA PLAZA
Measured at 60ms Post J
Auto Points

Lead	ST(mV)	Lead	ST(mV)
I	0.01	V1	0.00
II	0.24	V2	0.04
III	0.23	V3	0.11
aVR	-0.14	V4	0.11
aVL	-0.13	V5	0.07
aVF	0.25	V6	-0.02



GE
CASE V6.73

25 mm/s 10 mm/mV 50Hz 0.01Hz FRF+ HR(V5,V6)

Start of Test: 9:09:07am

SYAIFUL MR
Patient ID: 01084977
26.12.2022
9:15:02am

12-LEAD REPORT

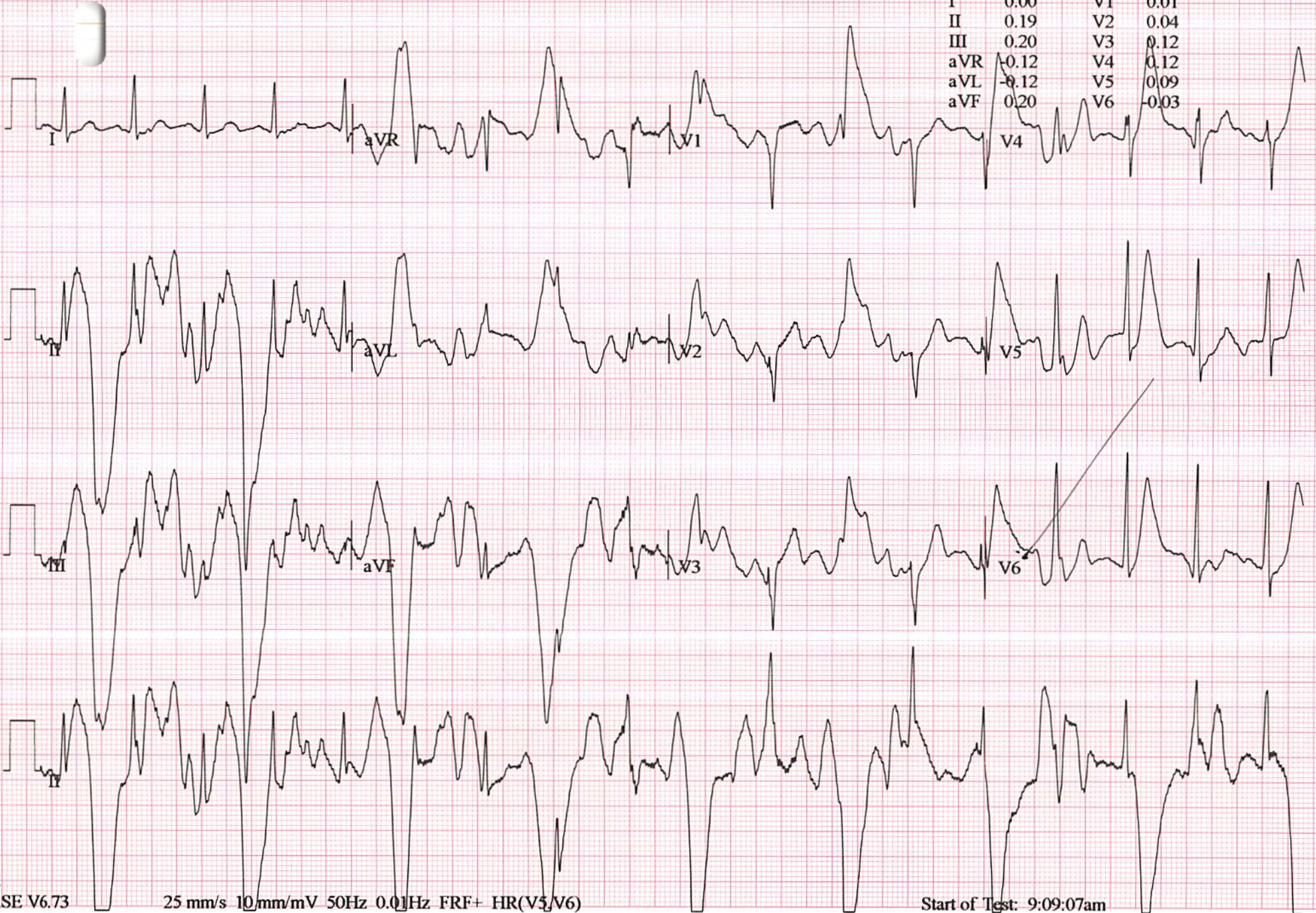
108 bpm
130/80 mmHg

EXERCISE
STAGE 2
05:50

BRUCE
4.0 km/h
12.0%

MEDIKA PLAZA
Measured at 60ms Post J
Auto Points

Lead	ST(mV)	Lead	ST(mV)
I	0.00	V1	0.01
II	0.19	V2	0.04
III	0.20	V3	0.12
aVR	-0.12	V4	0.12
aVL	-0.12	V5	0.09
aVF	0.20	V6	-0.03



GE
CASE V6.73

25 mm/s 10mm/mV 50Hz 0.01Hz FRF+ HR(V5,V6)

Start of Test: 9:09:07am

SYAIFUL MR
Patient ID: 01084977
26.12.2022
9:18:02am

12-LEAD REPORT

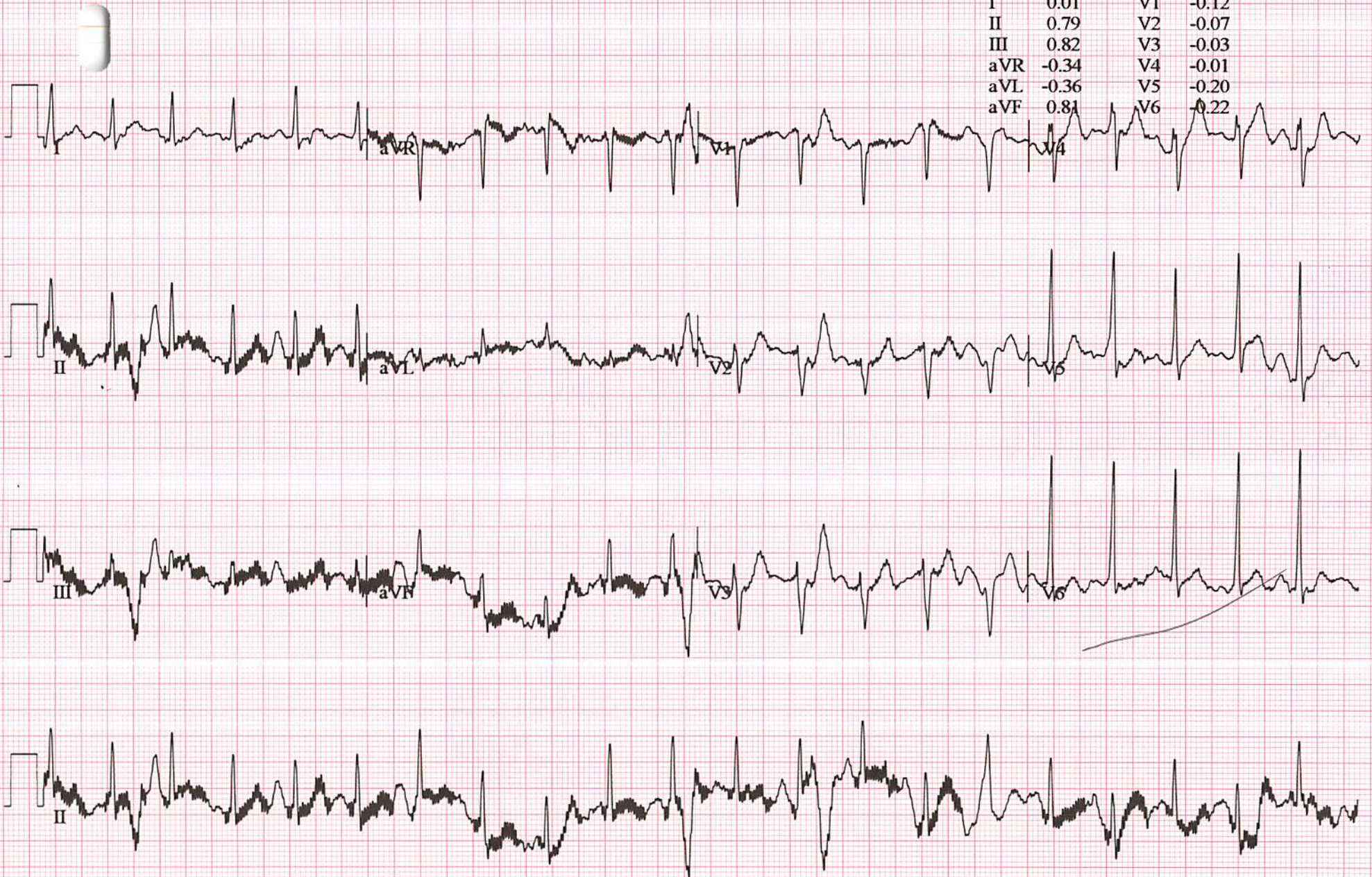
127 bpm
140/80 mmHg

EXERCISE
STAGE 3
08:50

BRUCE
5.5 km/h
14.0 %

MEDIKA PLAZA
Measured at 60ms Post J
Auto Points

Lead	ST(mV)	Lead	ST(mV)
I	0.01	V1	-0.12
II	0.79	V2	-0.07
III	0.82	V3	-0.03
aVR	-0.34	V4	-0.01
aVL	-0.36	V5	-0.20
aVF	0.81	V6	-0.22



GE
CASE V6.73

25 mm/s 10 mm/mV 50Hz 0.01Hz FRF+ HR(V6,V5)

Start of Test: 9:09:07am

SYAIFUL MR
Patient ID: 01084977
26.12.2022
9:19:41am

12-LEAD REPORT (PEAK EXERCISE)

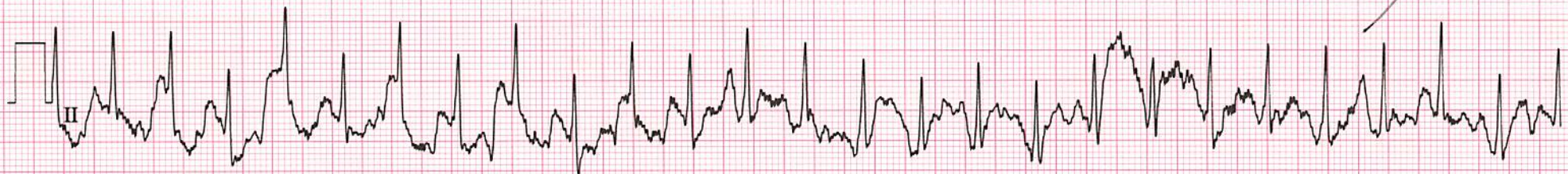
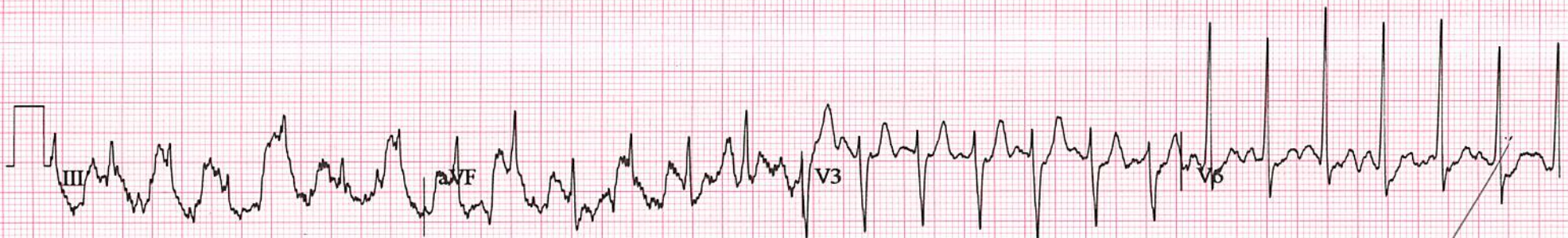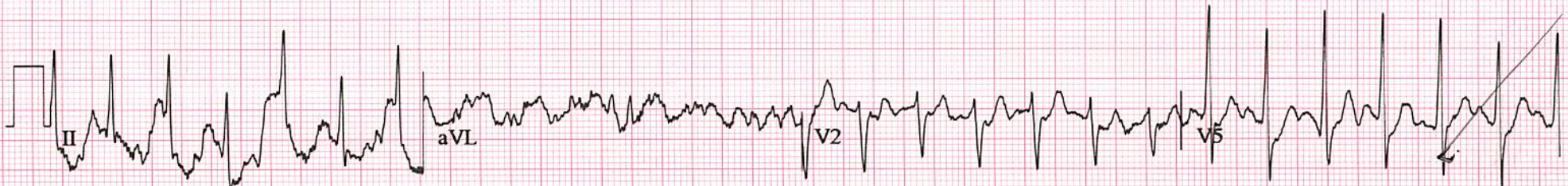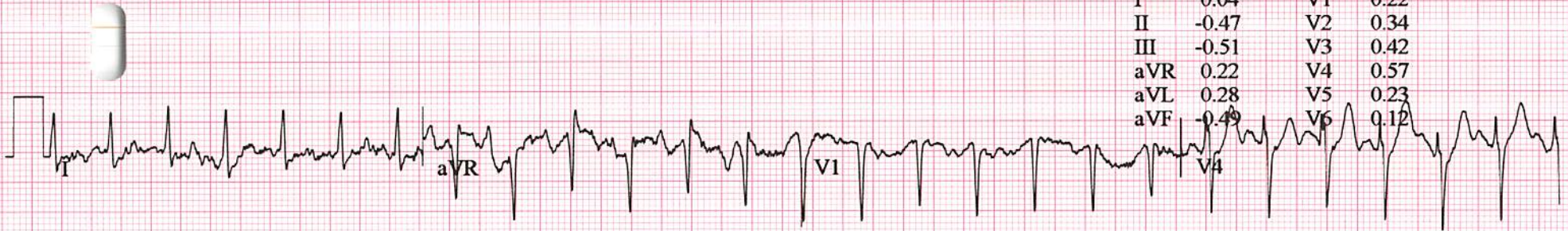155 bpm

EXERCISE
STAGE 4
10:29

BRUCE
6.8 km/h
16.0 %

MEDIKA PLAZA
Measured at 60ms Post J
Auto Points

Lead	ST(mV)	Lead	ST(mV)
I	0.04	V1	0.22
II	-0.47	V2	0.34
III	-0.51	V3	0.42
aVR	0.22	V4	0.57
aVL	0.28	V5	0.23
aVF	-0.49	V6	0.12



MEDIKA PLAZA

--
Jakarta SelatanStation
Telephone:**EXERCISE STRESS TEST REPORT**Patient Name: SYAIFUL, MR
Patient ID: 01084977
Height: 167 cm
Weight: 69 kgDOB: 03.02.1983
Age: 39yrs
Gender: Male
Race: AsianStudy Date: 26.12.2022
Test Type: --
Protocol: BRUCEReferring Physician: --
Attending Physician: --
Technician: --Medications:
--Medical History:
--Reason for Exercise Test:
--Exercise Test Summary


Phase Name	Stage Name	Time in Stage	Speed (km/h)	Grade (%)	HR (bpm)	BP (mmHg)	Comment
PRETEST	SUPINE	00:02					
	STANDING	00:02	0.00	0.00			
	HYPERV.	00:02	0.00	0.00			
	WARM-UP	00:03	0.00	0.00	69		
EXERCISE	STAGE 1	03:00	2.70	10.00	98	120/80	
	STAGE 2	03:00	4.00	12.00	108	130/80	
	STAGE 3	03:00	5.50	14.00	129	140/80	
	STAGE 4	01:29	6.80	16.00	155		
RECOVERY		00:32	2.20	0.00	142	140/80	

The patient exercised according to the BRUCE for 10:28 min:s, achieving a work level of Max. METS: 13.50. The resting heart rate of 69 bpm rose to a maximal heart rate of 157 bpm. This value represents 86 % of the maximal, age-predicted heart rate. The resting blood pressure of --/-- mmHg, rose to a maximum blood pressure of 140/80 mmHg. The exercise test was stopped due to --.

Interpretation
--Conclusions
--

Physician

Technician



PT. KARTIKA BINA MEDIKATAMA

Tanggal Kunjungan : 26/12/2022

No. Registrasi : 20221226-1004

Rekam Medis : 01084977

Nama : SYAIFUL

Jenis Kelamin : Male

Tanggal Lahir : 03 February 1983

S : MCU

O :

18	17	16	15	14	13	12	11	21	22	23	24	25	26	27	28
	R	R												R	

		X										R	X	X	D
48	47	46	45	44	43	42	41	31	32	33	34	35	36	37	38

A : CALCULUS ++

Radix (R) : 17,16,27,35

Decay/caries : 38

Missing teeth : 36,37,46

P : Pro Scalling + Polishing RA/RB

Pro Extractie : 17,16,27,35

Pro filling : 38

Pro GTS : 36,37,46

Diperiksa Oleh,

 PT. KARTIKA BINA MEDIKATAMA

Dokter
Djuanda

PATIENT NAME : Syariful
No. RM : 0108977
Ethnik/MCU/HEU : CO. ENT

To. Dokter :
(Counsel)

Kindly please counsel for patient who has take cares of

Diagnose :
Clinik Summary :

Counsel Request :

COUNSEL ADVISE

Finding :

Diagnosis :

Recomendation :

S. lache
karun us tehy, luter, lue,
ur eshl, de
Wh. sh. la. lach, luter, lat yang
gik

Date : 26-12-2012
Time :
EP :

23, 7020
M. waj

Signature

dr. Muh. Fajar Ramadhan Irsyal, SpTHT-KL

E.N.T

Complete Name

Formulir Number : FM - DR - 008 - 02
Revisi Number : 00
Date : 07 Juli 2017

PT. PARTIKA BINA MEDIKATAMA

A. Sahi
lab. er pul
l. l. l. l. l.
l. l. l. l. l.
l. l. l. l. l.