

TO WHOM IT MAY CONCERN

Kepada yang berkepentingan

This is certify that today Monday, 10 February 2020 Medika Plaza Clinic has performed urine drug screening and/or breath alcohol test to :

Dengan ini menyatakan bahwa, pada hari ini Senin, 10 Februari 2020 Medika Plaza Clinic telah melakukan urine drug screening dan/atau breath alcohol test kepada :

SYAIFUL

With the results are as follows :
Dengan hasil sebagai berikut :

Drugs Test <i>Uji Obat</i>	Result <i>Hasil</i>		
URINE DRUGS SCREENING			
- Amphetamine	<input type="checkbox"/> Non-Negative	<input checked="" type="checkbox"/> Negative	<input type="checkbox"/> N/A
- Met-Amphetamine	<input type="checkbox"/> Non-Negative	<input checked="" type="checkbox"/> Negative	<input type="checkbox"/> N/A
- Cocain	<input type="checkbox"/> Non-Negative	<input checked="" type="checkbox"/> Negative	<input type="checkbox"/> N/A
- THC/Canabis/Marijuana	<input type="checkbox"/> Non-Negative	<input checked="" type="checkbox"/> Negative	<input type="checkbox"/> N/A
- Morphine/Opiates	<input type="checkbox"/> Non-Negative	<input checked="" type="checkbox"/> Negative	<input type="checkbox"/> N/A
- P C P/Phencyclidine	<input type="checkbox"/> Non-Negative	<input checked="" type="checkbox"/> Negative	<input type="checkbox"/> N/A
- Barbiturate	<input type="checkbox"/> Non-Negative	<input type="checkbox"/> Negative	<input checked="" type="checkbox"/> N/A
- Benzodiazepin	<input type="checkbox"/> Non-Negative	<input checked="" type="checkbox"/> Negative	<input type="checkbox"/> N/A
- Methadone	<input type="checkbox"/> Non-Negative	<input checked="" type="checkbox"/> Negative	<input type="checkbox"/> N/A
- Propoxyphene	<input type="checkbox"/> Non-Negative	<input type="checkbox"/> Negative	<input checked="" type="checkbox"/> N/A
- Oxycodone	<input type="checkbox"/> Non-Negative	<input type="checkbox"/> Negative	<input checked="" type="checkbox"/> N/A
- MDMA	<input type="checkbox"/> Non-Negative	<input type="checkbox"/> Negative	<input checked="" type="checkbox"/> N/A
- 6-MAM	<input type="checkbox"/> Non-Negative	<input type="checkbox"/> Negative	<input checked="" type="checkbox"/> N/A
BREATH ALCOHOL TEST			
- Alcohol	<input type="checkbox"/> Non-Negative	<input checked="" type="checkbox"/> Negative	<input type="checkbox"/> N/A

Jakarta, February 10, 2020



PT. KARTIKA BINA MEDIKATAMA
(dr. Esther Poerwanto, Sp.PK)
Clinical Patologist

Certificate Of Health Assessment

Name	Age	Position	Department
SYAIFUL	37 yo	INSPECTOR	-

COMPANY :

INSPEKTINDO SINERGI PERSADA, PT

CONCLUSION



FIT TO WORK

FIT WITH MEDICAL NOTE

✓

TEMPORARY UNFIT

UNFIT

Issued Date	Doctors Name	Prepared By
10 February 2020	Rezkha Amalia, MD <i>PKTK : KEP.476/BINWASK3-PNK3/KK/XII/2018</i> <i>SIP : 54/B.15a/31.74.04.1004/-1.779.3/e/2018</i>	
Expired Date	dr. Muhammad Ilyas, Sp.Ok <i>SIP : 29/B.15b/31.74.04.1004.02.009.K.1/3/-1.779.3/e/2019</i>	Verified By  PT. KARTIKA BINA MEDIKATAMA
29 February 2020		

No. Formulir : FM-DR-008-05

No. Revisi : 00

Tanggal Terbit : 2 Mei 2011

Certificate Number : MP-BOP/1-20200210/121355

MCU Validity Check

<https://mcu-validasi.medikaplaza.com>

HEALTH ASSESSMENT REPORT

Of

SYAIFUL
01031455

Monday, 10 February 2020

MP BELTWAY CLINIC

Beltway Office Park, Annex Building, Ground Floor

Jl. TB. Simatupang Kav.41, Jakarta Selatan 12550

Tlp : (62-21) 808 66 099, Fax : (62-21) 808 66 098

www.medikaplaza.com

MP BELTWAY CLINIC

Beltway Office Park, Annex Building, Ground Floor
Jl. TB. Simatupang Kav.41, Jakarta Selatan 12550
Tlp : (62-21) 808 66 099, Fax : (62-21) 808 66 098
www.medikaplaza.com

PATIENT DATA

MedRec. : 01031455	EMPLOY. STATUS : Employee
NAME : SYAIFUL	BIRTHDATE : 03 February 1983
EMPLOYEE No. : -	SEX : Male
JOB TITLE : INSPECTOR	STATUS : Married
COMP. NAME : INSPEKTINDO SINERGI PERSADA, PT	NASIONALITY : Indonesia

SUMMARY

MEDICAL FINDING :

1. Leukocytosis
2. Hypertriglyceridemia
3. Non reactive Anti HBs
4. Leukocyturia (+1)
5. Overweight
6. Decayed, missing, impacted, gangrene pulpa, stain, and calculus teeth
7. Decreasing of visual acuity of both eyes
8. Ocular hypertension of both eyes
9. USG Adomen: Mild fatty liver, Intraluminal Sludge of gallbladder
10. Decreasing of hearing acuity on high frequency of left ear


Your fitness status is fit with medical note:

1. Hypertriglyceridemia
2. Ocular hypertension of both eyes
3. USG Abdomen: Intraluminal Sludge of gallbladder

SUGGESTION :

1. Repeat Leukocyt examination after 1 month and consultation with an Internist if still increase
2. Low fat and carbohydrate diet, exercise regularly minimal 3 times a week. Consultation with an Internist for further evaluation of hypertriglyceridemia
3. Need to get Hepatitis B vaccination (booster)
4. Drink more water at least 2lt/day (8-10 glasses/day). Repeat urinalysis after 2 weeks and consultation with an Internist / Urologist if crystaluria persist
5. Reduce body weight gradually 0.5 Kgs/week, by doing regular exercise (aerobic/jogging), 3-4x/week, 30-45 minutes and reduce high calorie diet until maximal body weight is 69.72 Kgs (present body weight is 70.5 Kgs). Consultation with a Nutritionist for evaluation of overweight
6. Consultation with a Dentist for dental care, minimal once a year or better once in six month
7. You need to wear the glasses for distant vision
8. Consultation with an Ophthalmologist for further evaluation of ocular hypertension of both eyes
9. Low fat diet and exercise regularly minimum 3x/week. Repeat abdominal USG 6 months later and consultation with an Internist to evaluate Intraluminal Sludge of gallbladder
10. Avoid noisy environment and use earplug properly while working at noisy work environment to prevent further hearing impairment

Responsible Doctor


Rezka Analla, MD

Notes:

If you need the further information or consultation, please contact us via :

Email : - beltway.doctor@medikaplaza.com
- beltway.doctor2@medikaplaza.com
Telepon Klinik : (62-21) 8086 6000

CLINICAL EVALUATION

Name : SYAIFUL	Sex : Male	MR : 01031455	Visit : 10/02/202
Comp. : INSPEKTINDO SINERGI PERSADA, PT		DOB : 03 February 1983	
EXAMINATION	RESULT	NOTES	

ANAMNESA

PRESENT COMPLAINT AND HISTORY OF PRESENT

ILLNESS

Present complaint

No complaint

MEDICAL HISTORY

Alergy	No
Imunisasi	Yes
Surgery	No
Hospitalization	No
Disease	No

LIFE STYLE

Alcohol intake	No
Smoking	Yes Mild smoker
Exercise	Yes Badminton 1x/week

FAMILY MEDICAL HISTORY

Diabetes Melitus	No
Hypertension	No
Heart disease	No
Lung TB	No
Kidney disease	No
Astma	No
Mental disease	No
Epilepsy	No
Cancer	No
Color blind	No
Stroke	No
Liver disease	No
Bone & joint	No
Others disease	No

WORK EXPOSURE

Noise	No
Heat Stress	No
Cold Stress	No
Vibration	No
Involving height	No
Radiation	No
Dust	No

CLINICAL EVALUATION

Name : SYAIFUL

Sex : Male

MR : 01031455

Visit : 10/02/202

Comp. : INSPEKTINDO SINERGI PERSADA, PT

DOB : 03 February 1983

EXAMINATION	RESULT	NOTES
Toxic chemical	No	
Irritating fluid	No	
Smoke	No	
Bacterium/Virus/Parasite	No	
Blood	No	
Animal	No	
Operating heavy mobile equipment	No	
Manual Handling	No	
Sitting continuously over 4 hours	No	
Stand continuously over 4 hours	Yes	
Using monitor screen more than 4 hours per day	No	
Exposure	No	
Unergonomic body positions	No	
Shift work	No	
Work is not accordance with skills and knowledge	No	
Workload does not accordance with time	No	
Work conflict	No	
Inappropriate task	No	
Career barriers	No	
Family conflict	No	
Working arround rotating machinery	No	
Administration work	No	
Handling food product	No	
Others	Yes	Offshore
PHYSICAL EXAMINATION		
General Appearance	Good	
Body shape	Picnicus	
VITAL SIGN		
Body Weight	70.5 Kg	
Body Height	167 Cm	
BMI	25.27 Kg/m2	
Normal Weight	51.59 - 69.72 Kg	
BMI Conclusion	Overweight	
Blood Pressure	120/80 mmHg	
Pulse	66 x/minute	
Body Temperature	36.1 °C	
RR	18	

CLINICAL EVALUATION

Name : SYAIFUL

Sex : Male

MR : 01031455

Visit : 10/02/202

Comp. : INSPEKTINDO SINERGI PERSADA, PT

DOB : 03 February 1983

EXAMINATION	RESULT	NOTES
Neck Circumference	32 Cm	
Arm Circumference	24 Cm	
Chest size	83 Cm	
Abdominal Circumference	86 Cm	
SKIN		
Skin	Normal	
EYE		
Left	Normal	
Right	Normal	
ENT		
Auricle	Normal	
Ear canal	Normal	
Drums	Normal	
Septum/Conchae	Normal	
Sinuses	Normal	
Pharynx	Normal	
Tonsil	Normal	
MOUTH		
Gum	Normal	
Dental	Abnormal	Decayed, missing, impacted, gangrene pulpa, stain, and calculus teeth
NECK		
General	Normal	
Thyroid Gland	Normal	
CHEST		
Form	Normal	
Lung	Normal	
Heart	Normal	
Breast	Normal	
ABDOMEN		
Form	Flat	
Palpation	Supple	
Liver	Not Palpable	
Spleen	Not Palpable	
Kidney	No Ballotment	
-	No	
Hernia inguinal	No	

CLINICAL EVALUATION

Name : SYAIFUL

Sex : Male

MR : 01031455

Visit : 10/02/202

Comp. : INSPEKTINDO SINERGI PERSADA, PT

DOB : 03 February 1983

EXAMINATION	RESULT	NOTES
EXTRIMITIES		
Bones, joint	Normal	
Muscles, tonus	Normal	
Fingernails	Normal	
Hand	Normal	
Foot	Normal	
RECTAL EXAMINATION		
Hemorrhoid	Negative	
Rectum	Normal	
SENSORIK EXAMINATION		
Tes Raba	Normal	
MOTORIK EXAMINATION		
Tes Grip	Normal	
REFLEX EXAMINATION		
Physiologic reflex	Normal	
Patologic reflex	Normal	
OTHERS EXAMINATION		
Coordination	Normal	
LIMPHE SYSTEM		
Submandibula	Normal	
Neck Gland	Normal	
Armpit gland	Normal	
Inguinal	Normal	

OPHTHALMOLOGY DIAGNOSTIC

Name : SYAIFUL	Sex : Male	MR : 01031455	Visit : 10/02/202
Comp. : INSPEKTINDO SINERGI PERSADA, PT		DOB : 03 February 1983	

EXAMINATION		Right	Left
Reading		-	
Previous Glasses		-	-
Without Glasses	Distant	20/30	20/50
	Near	J1	J1
Correction	Distant	S-0.75 20/20	S-1.50 20/20
	Near	-	-
Depth Perception		-	
Tonometry		28.0 mmHg	21.0 mmHg
Funduscopy		NORMAL	NORMAL
Visual Fields		Normal	
Colour Blind Test		Normal	

Impression : Myopia simplex ODS
Hypertensi ocular OD

RADIOLOGY DIAGNOSTIC

Name : SYAIFUL

Sex : Male

MR : 01031455

Visit : 10/02/202

Comp. : INSPEKTINDO SINERGI PERSADA, PT

DOB : 03 February 1983

EXAMINATION

RESULT

THORAX PA

No abnormality seen in both lungs.
Normal bronchovascular markings in both hili.
The heart is normal in size and shape.
The mediastinum is not widened.
Both sinus and diaphragms are good.
No evidence of pleural effusion.

Impression

Normal chest.
No evidence of specific process in both lungs.

RADIOLOGY DIAGNOSTIC

Name : SYAIFUL	Sex : Male	MR : 01031455	Visit : 10/02/202
Comp. : INSPEKTINDO SINERGI PERSADA, PT		DOB : 03 February 1983	

EXAMINATION

RESULT

USG ABDOMEN

LIVER:

Normal in size and contour, smooth surface, echoes structure parenchyme which are homogenous. No sign of SOL.

Intrahepatic vascularity and billiary tract are normal.

GALL BLADDER:

Normal in size. Sludge intraluminal. Normal gallbladder wall.

RIGHT KIDNEY :

Normal in size, contour and surface. No sign of obstruction/ stone/ SOL.

LEFT KIDNEY:

Normal in size, contour and surface. No sign of obstruction/ stone/ SOL.

PANCREAS:

Normal in size, contour and surface. No sign of SOL.

LIEN:

Normal in size and contour, the echoes are homogenous. No sign of SOL.

URINARY BLADDER:

Normal in size, contour and surface. No sign of stone/ SOL.

PROSTATE AND VESICULA SEMINALIS:

Normal in size and contour which are homogenous echoes and no sign of focal lesion/ SOL.

Impression

Mild fatty liver.

Intraluminal Sludge of gallbladder.

Other abdominal organs are normal.

Name : SYAIFUL

Comp.: INSPEKTINDO SINERGI PERSADA, PT

EXAMINATION

HEMATOLOGI

ABO/Rh Typing

Automated Blood Count

White Blood Cell (WBC)

Erythrocyte (RBC)

Haemoglobin

Hematocrit

Thrombocytes

MCV, MCH, MCHC

MCV

MCH

MCHC

ESR

Differential Count

Basophils

Eosinophil

Bands / Stab

Neutrophils

Lymphocytes

Monocytes

BLD CHEMISTRY/LIPID PROFILE

Total Cholesterol

HDL Cholesterol

LDL Cholesterol

Triglycerides

BLD CHEMISTRY/KIDNEY FUNCTION

Verified by : dr. Esther Poerwantoro, Sp.PK

PRIVATE

Printed by : reusi

Nama :

Umur :

Alamat :

LAB NO: 20002400

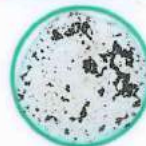

SYAIFUL
01031456-L
03-02-83
INSPEKTINDO SINERGI PERSADA

GOL DARAH

A

Rh +/-Pos



anti : A



anti : B



anti : AB



anti : Rh

5.7

3.8 - 11.0

16.5

4.4 - 5.9

50

13.2 - 17.3

357

40 - 52

88

150 - 440

29

80 - 100

33.1

26 - 34

7

32 - 36

0

0 - 10

3

0 - 1

2 *

2 - 4

44 *

3 - 5

42 *

50 - 70

9 *

25 - 40

2 - 8

190

Normal/Desireable: <200

Borderline High: 200-239

High: >=240

34.7 *

Normal : >40 - <60

Low HDL : <40

Desireable : >=60

84

Optimal: <100

Near/Above Optimal: 100-129

Borderline High: 130-159

High: 160-189

Very High: >=190

355 *

Normal : <150

Borderline High: 150-199

High : 200-499

Very High : >=500

LABORATORY RESULT

Name : SYAIFUL	MR : 01031455	Visit : 10/02/2020	#Lab : IN6949331303
Comp. : INSPEKTINDO SINERGI PERSADA, PT	Sex : Male	DOB : 03 February 1983	

EXAMINATION	RESULT	NORMAL RANGE
-------------	--------	--------------

HEMATOLOGI

ABO/Rh Typing "A" Rh(+) positive

Automated Blood Count

White Blood Cell (WBC)	12.8 *	3.8 - 11.0
Erythrocyte (RBC)	5.7	4.4 - 5.9
Haemoglobin	16.5	13.2 - 17.3
Hematocrit	50	40 - 52
Thrombocytes	357	150 - 440

MCV, MCH, MCHC

MCV	88	80 - 100
MCH	29	26 - 34
MCHC	33.1	32 - 36
ESR	7	0 - 10

Differential Count

Basophils	0	0 - 1
Eosinophil	3	2 - 4
Bands / Stab	2 *	3 - 5
Neutrophils	44 *	50 - 70
Lymphocytes	42 *	25 - 40
Monocytes	9 *	2 - 8

BLD CHEMISTRY/LIPID PROFILE

Total Cholesterol	190	Normal/Desireable: <200 Borderline High: 200-239 High: >=240
HDL Cholesterol	34.7 *	Normal : >40 - <60 Low HDL : <40 Desireable : >=60
LDL Cholesterol	84	Optimal: <100 Near/Above Optimal: 100-129 Borderline High: 130-159 High: 160-189 Very High: >=190
Triglycerides	355 *	Normal : <150 Borderline High: 150-199 High : 200-499 Very High : >=500

BLD CHEMISTRY/KIDNEY FUNCTION

LABORATORY RESULT

Name : SYAIFUL	MR : 01031455	Visit : 10/02/2020	#Lab : IN6949331303
Comp. : INSPEKTINDO SINERGI PERSADA, PT	Sex : Male	DOB : 03 February 1983	

EXAMINATION	RESULT	NORMAL RANGE
Ureum	13.3	10.0 - 50.0
Creatinine	1.0	0.6- 1.3
Uric Acid	7.07	3.50 - 7.20

BLD CHEMISTRY/LIVER FUNCTION

Total Bilirubin	0.40	0.1 - 1.0
Direct Bilirubin	0.15	0.0 - 0.2
Indirect Bilirubin	0.25	0.0 - 0.8
SGOT(AST)	26	13 - 45
SGPT (ALT)	39	13 - 50
Alkaline Phosphatase	79	30 - 120
Gamma GT	29	0 - 50
Albumin	5.0	3.5 - 5.5
Globulin	2.60	2.3 - 3.5
Total Protein	7.6	6.6 - 8.7

BLD CHEMISTRY/DIABETES

Glucose Fasting	98	< 100
Glucose Urine	Negative	Negative
Keton Urine	Negative	Negative

Blood Glucose 2 PP

Blood Sugar 2 Hours PP	101	< 140
Glucose Urine	Negative	Negative
Keton Urine	Negative	Negative

SEROLOGI / IMUNOLOGI

HBsAg (Quantitative)	0.00	0.00 - 0.03
Anti Hbs (Quantitative)	0.5 *	>= 5.0

TOXICOLOGY - DRUGS SCREENING

Methadone	Negative	Negative
Phencyclidine	Negative	Negative
THC/Marijuana	Negative	Negative
Amphetamine	Negative	Negative
Benzodiazepines	Negative	Negative
Opiat	Negative	Negative
Cocain	Negative	Negative
Metamphetamine	Negative	Negative
Alcohol	Negative	Negative

URINALYSIS

Complete Urine Analysis

LABORATORY RESULT

Name : SYAIFUL	MR : 01031455	Visit : 10/02/2020	#Lab : IN6949331303
Comp. : INSPEKTINDO SINERGI PERSADA, PT	Sex : Male	DOB : 03 February 1983	

EXAMINATION	RESULT	NORMAL RANGE
-------------	--------	--------------

Macroscopic

Color	Colorless	
Turbidity	Clear	Clear
Specific Gravity	1.007	1.000 - 1.030
pH	6.0	4.5 - 8.0
Leucocyte	Positive 1 (75)	Negative
Glucose	Negative	Negative
Nitrit	Negative	Negative
Bilirubin	Negative	Negative
Blood	Negative	Negative
Urobilinogen	Normal	Normal
Protein	Negative	Negative
Keton	Negative	Negative

Microscopic

RBC	0-1	0 - 1
WBC	1-3	0 - 4
Cylinder	Negative	
Epithels Squamous	0-2	5 - 15
Crystals	Negative	
Bacteria	Negative	Negative
Others	Negative	

STOOL / RECTAL SWAP

Faeces Complete

Macroscopic

Color	Yellow	
Consistency	Smooth	
Mucus	Negative	Negative
Blood	Negative	Negative
Pus	Negative	Negative
Parasitologi Faeces	Negative	Negative
Lipid	Negative	Negative

Microscopic

RBC	0-1	0 - 1
WBC	0-1	0 - 5
Amoeba	Negative	
Ephitels	Positive	Positive
Worm Eggs	Negative	Negative

LABORATORY RESULT

Name : SYAIFUL	MR : 01031455	Visit : 10/02/2020	#Lab : IN6949331303
Comp. : INSPEKTINDO SINERGI PERSADA, PT	Sex : Male	DOB : 03 February 1983	

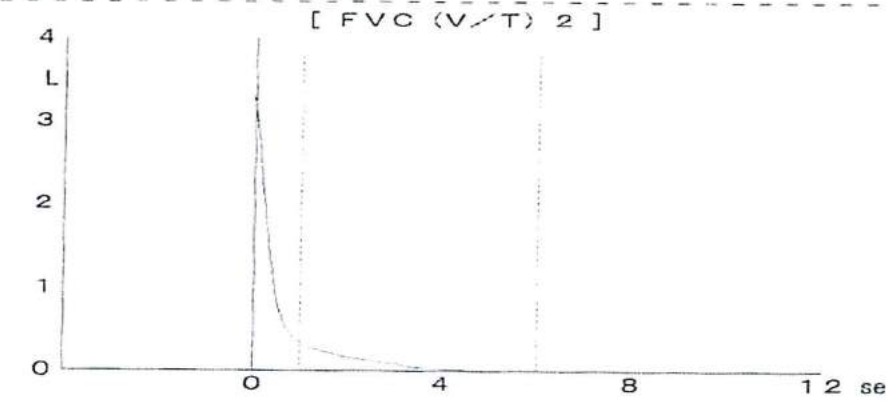
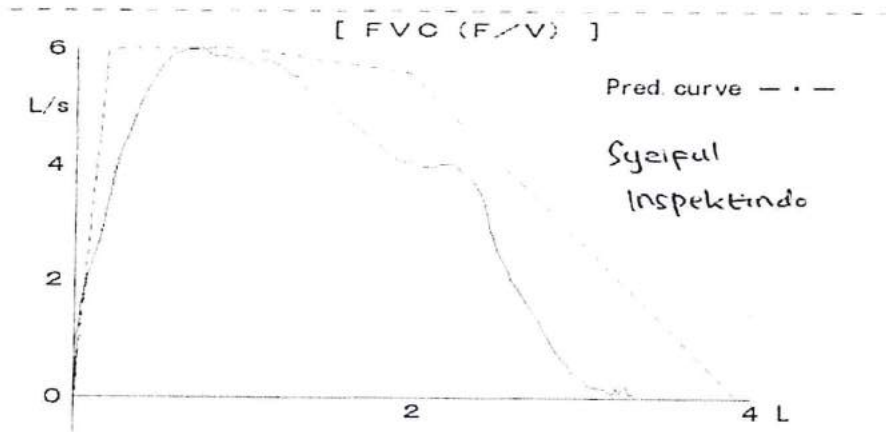
EXAMINATION	RESULT	NORMAL RANGE
Yeast	Negative	Negative
Muscle Fiber	Negative	Negative
Others	Negative	Negative
Digestive		
Amylum	Negative	Negative
Fat	Negative	
Fibers	Positive	Positive

SPIROMETRY DIAGNOSTIC

Name : SYAIFUL	Sex : Male	MR : 01031455	Visit : 10/02/202
Comp. : INSPEKTINDO SINERGI PERSADA, PT		DOB : 03 February 1983	

EXAMINATION	RESULT
FVC Result	: 3.32 L---> 84.7 %
FEV1 Result	: 2.97 L---> 84.4 %
FEV1/FVC Result	: 89.46 %---> 114.7 %
PEF Result	: 5.98 L/S---> 57.4 %
Indonesian Standart Result	:
Index	:
Spirometry Result	: Normal

Impression : Normal Spirometric Functions



AUDIOMETRY DIAGNOSTIC

Name : SYAIFUL

Sex : Male

MR : 01031455

Visit : 10/02/202

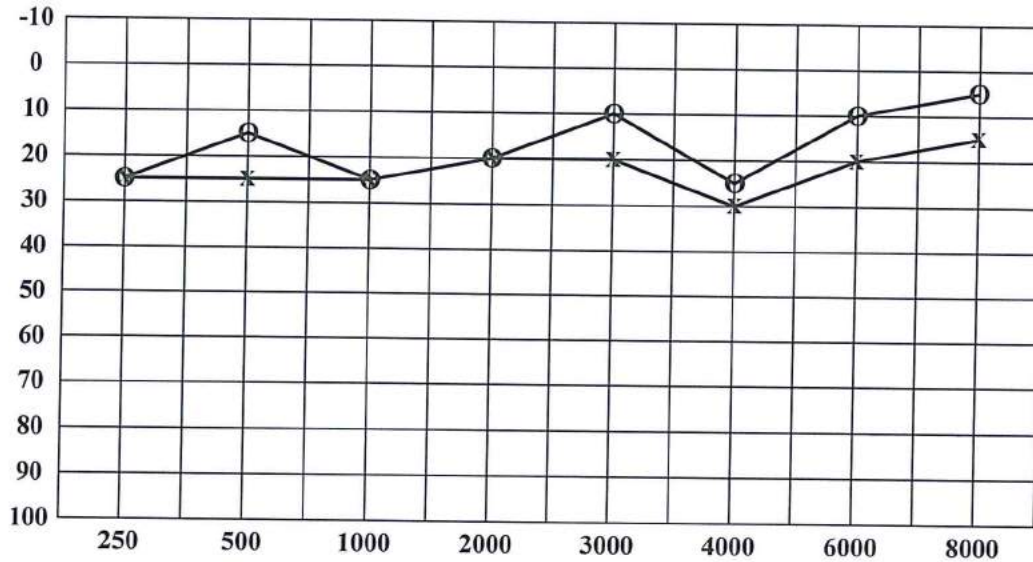
Comp. : INSPEKTINDO SINERGI PERSADA, PT

DOB : 03 February 1983

RESULT

Left Ear	250	500	1000	2000	3000	4000	6000	8000
AC	25	25	25	20	20	30	20	15
BC	-	-	-	-	-	-	-	-

Right Ear	250	500	1000	2000	3000	4000	6000	8000
AC	25	15	25	20	10	25	10	5
BC	-	-	-	-	-	-	-	-



< : Right Ear (BC)

> : Left Ear (BC)

O : Right Ear (AC)

X : Left Ear (AC)

Conclusion Right Ear : Hearing threshold = 21.25 dB
(Within normal limit)

Conclusion Left Ear : Hearing threshold = 25 dB
(Within normal limit)
With decreasing on frequency 4000Hz

CARDIOLOGY DIAGNOSTIC

Name : SYAIFUL	Sex : Male	MR : 01031455	Visit : 10/02/202
Comp. : INSPEKTINDO SINERGI PERSADA, PT		DOB : 03 February 1983	

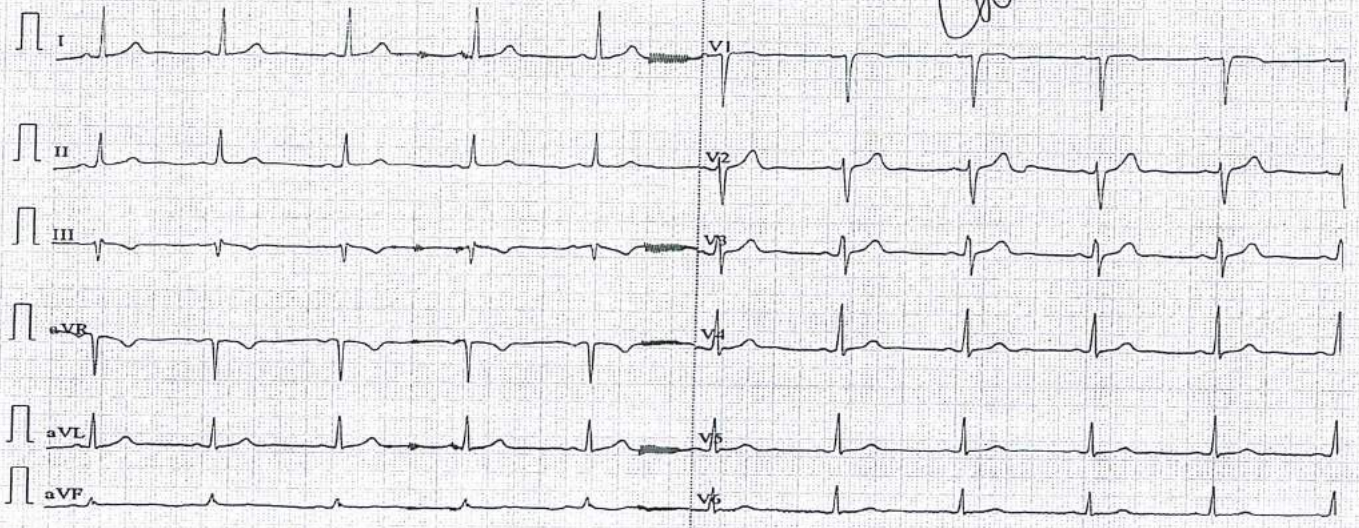
EXAMINATION	RESULT	Comments :
ELECTROCARDIOGRAPHY	Sinus Rythm axis (N), P wave (N), PR int 0.16" ST - T segment (N), aritmia (-)	Normal ECG
TREADMILL	Sinus Rythm axis (N), P wave (N), PR int 0.16" ST - T segment (N), aritmia (-)	Treadmill Exercise Test : Negative Cardiopulmonary Fitness Classification : Good METs : 13.4

ID: 50
SYAIFUL
Male: 37Years

10-02-2020 10:58:51
HR : 62 bpm
P : 108 ms
PR : 142 ms
QRS : 86 ms
QT/QTc : 396/403 ms
P/QRS/T : 14/15/4
RV5/SV1 : 0.988/1.369 mV

Diagnosis Information:
Sinus rhythm
Normal ECG

Report Confirmed by: 



0.67~100Hz AC50 25mm/s 10mm/mV 2*5.0s 62 SE-1200Express V2.21 Glasgow V28.6.0



SYAIFUL, MR

ID: 01031455, Born: 2/3/1983 (Male 37), 70.5 kg, 167 cm
Test Date: 2/10/2020 11:10:32 AM

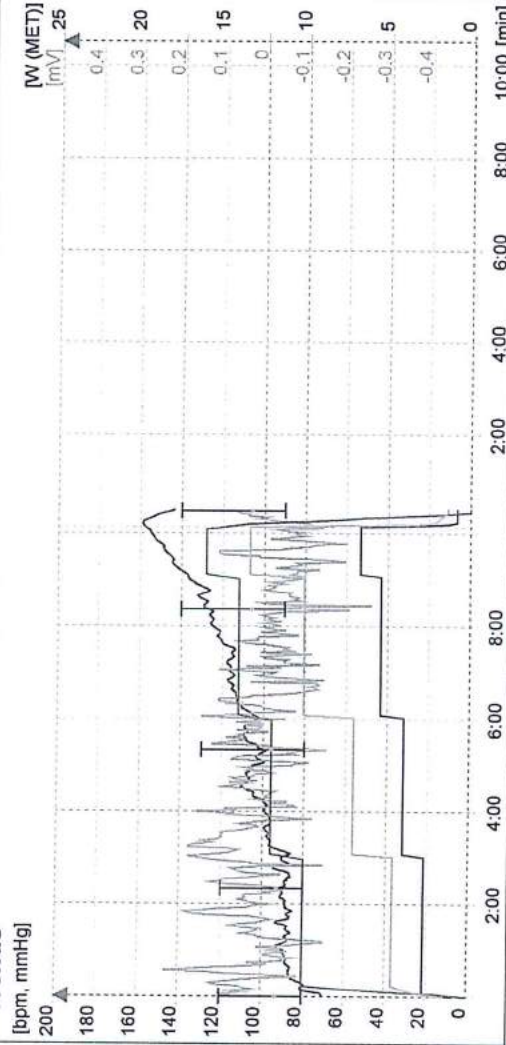
MEDIKATAMA

Patient info

born: 2/3/1983
age: 37
sex: Male
weight: 70.5 kg
height: 167 cm
smoker:
pacemaker:

Medical history

Trends



Conclusion

[Handwritten signature]
[Handwritten signature]

PT. KARTIKA BINA MEDIKATAMA

Medications

Reason for admission

Reason for Stop

Staff

Physician: user
Technician:

Test info

Test date: 2/10/2020
 Test time: 11:10 AM
 Stress device: BTL Treadmill Emergency
 Protocol: Bruce
 Total duration: 10:08
 Stress achieved: 6.7 km/h, 16.0% (~13.4 MET) = 109% predicted (~12.4 MET) - for 1 sec
 HR rest: 71
 HR peak: 155 = 85% predicted (182) --- 10:0 Exercise (13.4 MET)
 Handgrip test: 120/80
 BP rest: 140/90
 BP recovery:
 DP rest: 8520
 DP peak: 17722 = 2.1 x DP at rest
 ST depression max: aVF -1.02 mV 07:00 Exercise
 ST elevation max: aVF 0.63 mV 07:14 Exercise
 ST/HR index: 3.1 $\mu\text{V}/\text{bpm}$ (abnormal)



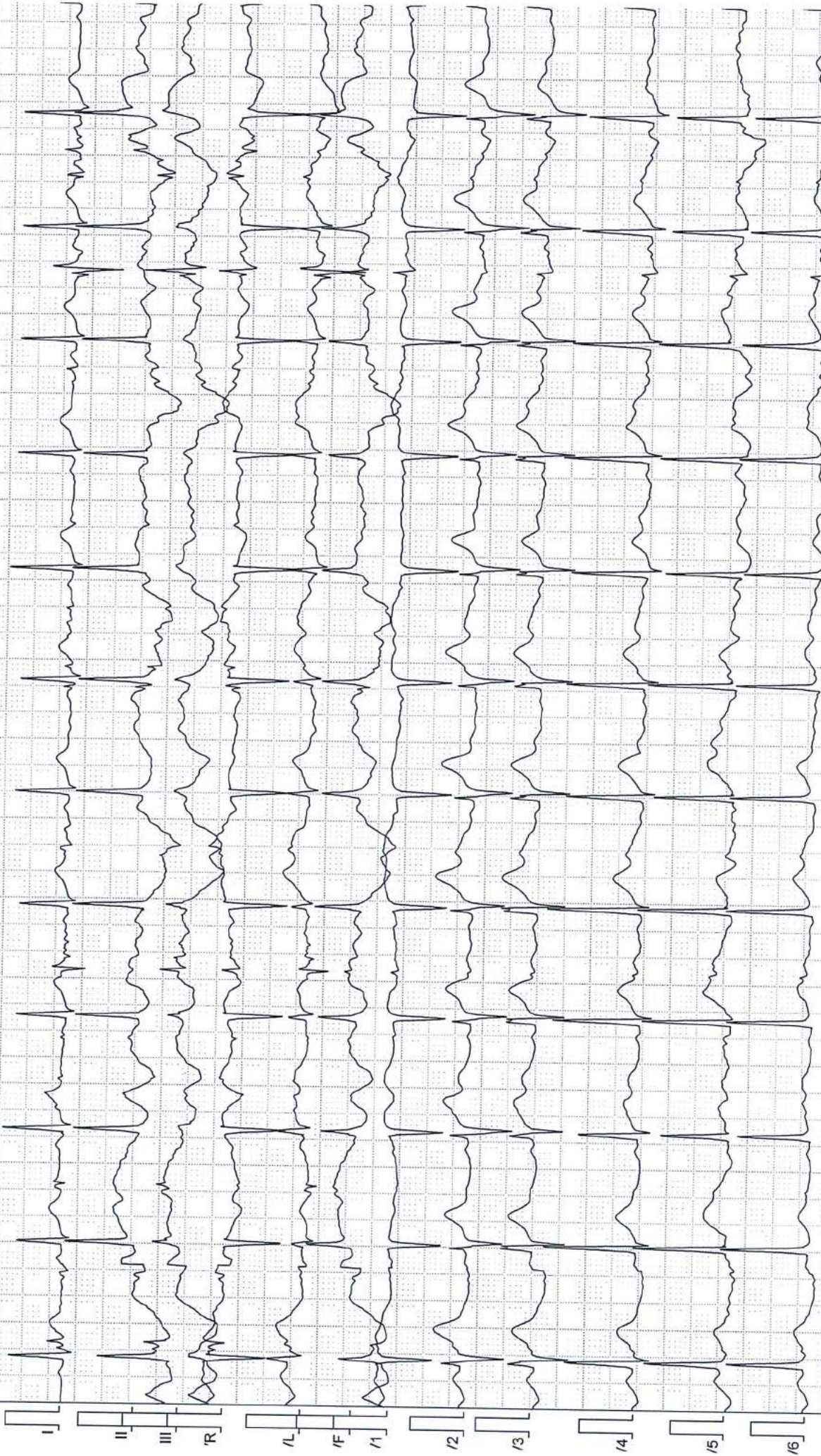
SYAIFUL, MR

ID: 01031455, Born: 2/3/1983 (Male 37), 70.5 kg, 173.7 cm
Test Date: 2/10/2020 11:10:32 AM

MEDIKAZA

Time: P 00:07 - Reference

Load: 1.4MET, HR: 71bpm, BP: 120/80



Filter: 0.07 Spline - 90 Adapt, ~50 [Hz]

edika Plaza Clinic

BTL CardioPoint 2.30.33006.0, DIAG: 2.0.2.0; ECG: BTL-08 ECG, SN: 071D-B-05775

25.00 mm/sec 10.0 mm/mV
BTL CardioPoint - Stress Test Page



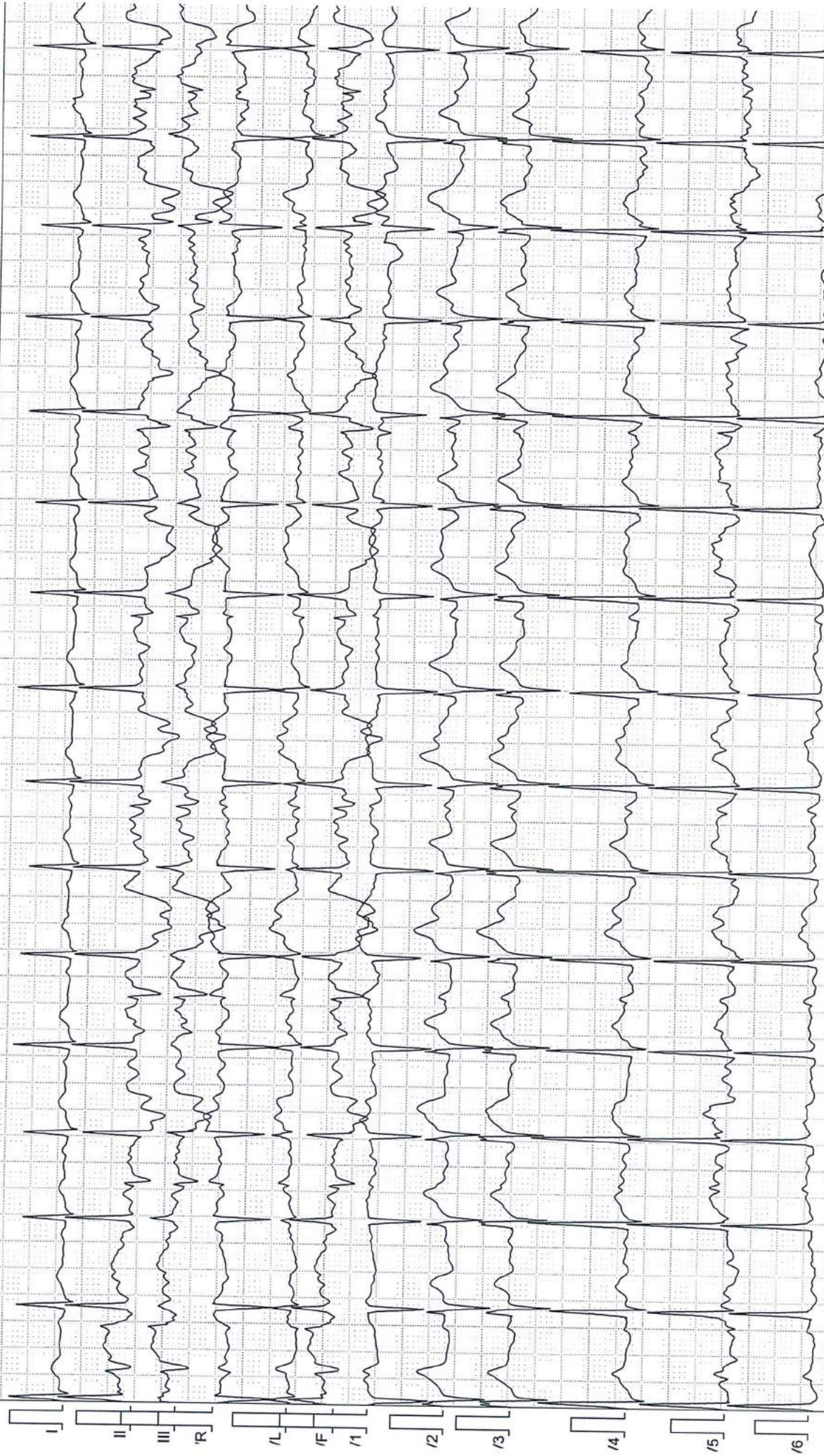
SYAIFUL, MR

ID: 01031455, Born: 2/3/1983 (Male 37), 70.5 kg, 177 cm
Test Date: 2/10/2020 11:10:32 AM

MEDIK AZA

Time: E 02:56 - E1

Load: 4.6MET, HR: 91bpm, BP: 120/80



Filter: 0.07 Spline - 90 Adapt, -50 [Hz]

edika Plaza Clinic

BTL CardioPoint 2.30.33006.0, DIAG: 2.0.2.0; ECG: BTL-08 ECG, SN: 071D-B-05775

25.00 mm/sec 10.0 mm/mV

Page

BTL CardioPoint - Stress Test



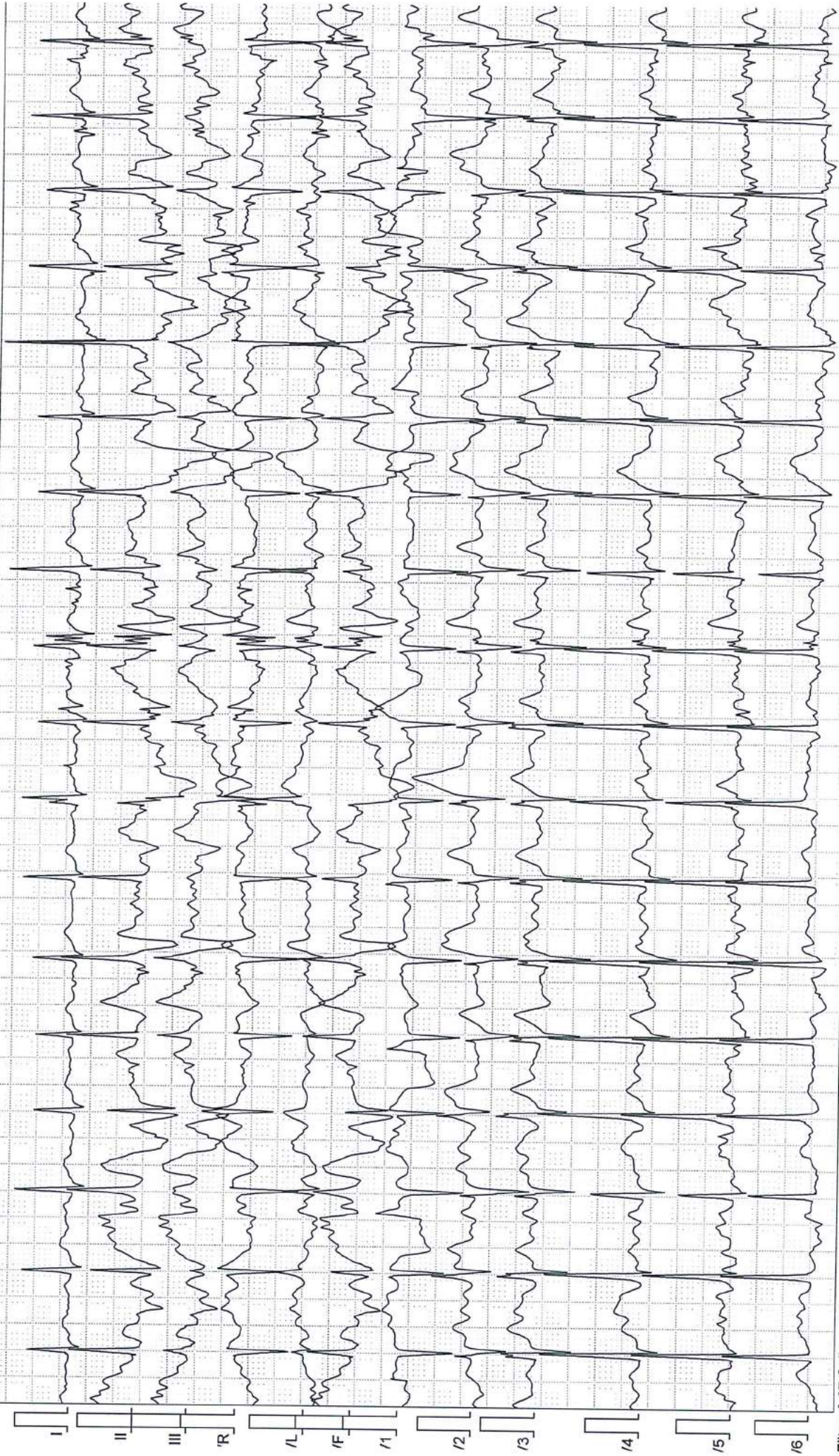
SYAIFUL, MR

ID: 01031455, Born: 2/3/1983 (Male 37), 70.5 kg, 177 cm
Test Date: 2/10/2020 11:10:32 AM

MEDIK  AZA

Time: E 05:57 - E2

Load: 7.0MET, HR: 102bpm, BP: 130/80



Filter: 0.07 Spine - 90 Adapt, ~50 [Hz]

edika Plaza Clinic

25.00 mm/sec 10.0 mm/mV



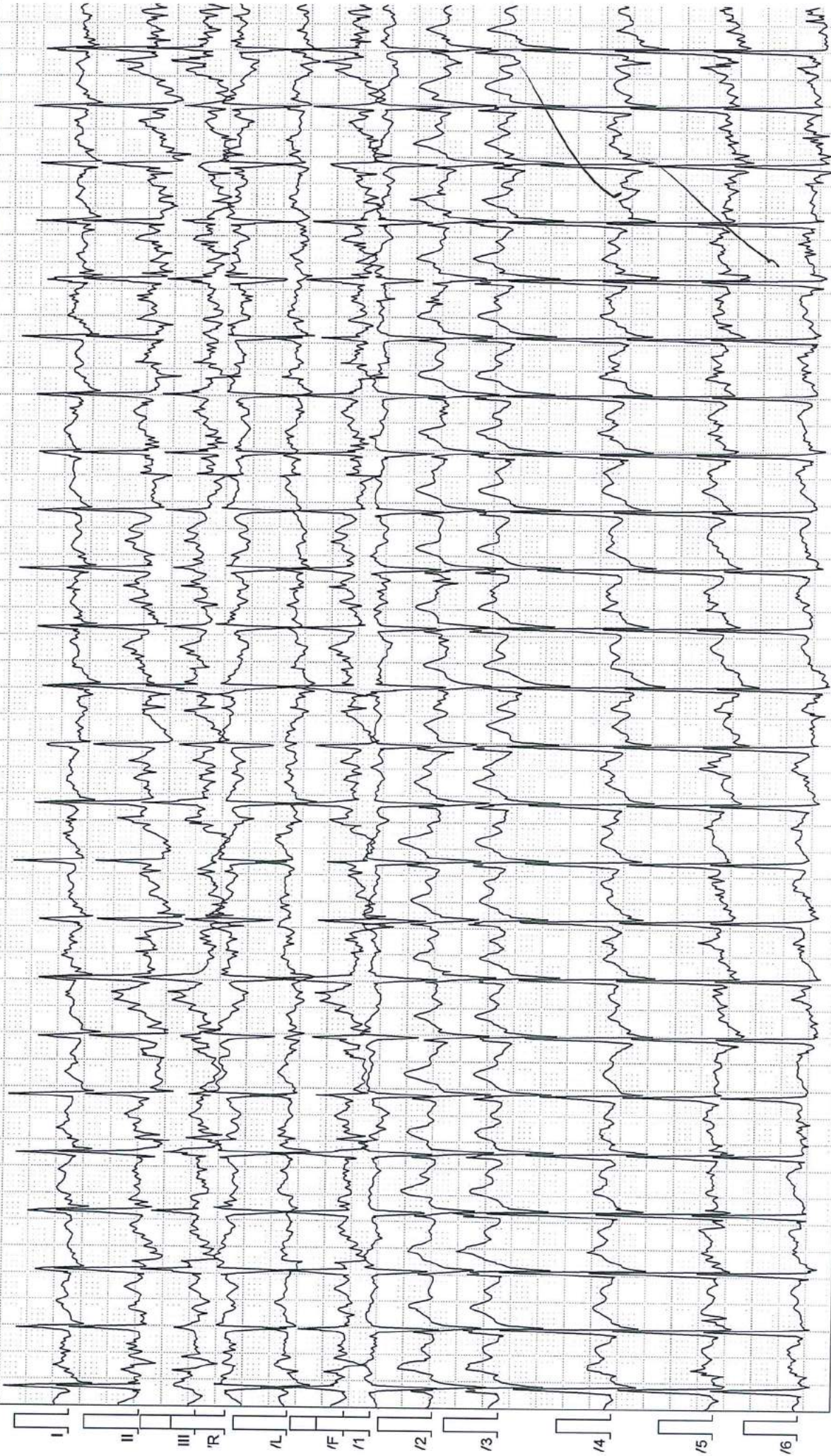
SYAIFUL, MR

ID: 01031455, Borr: 2/3/1983 (Male 37), 70.5 Kg, 167 cm
Test Date: 2/10/2020 11:10:32 AM

MEDIK AZA

Time: E 08:58 - E3

Load: 10.1MET, HR: 137bpm, BP: 140/90



Filter: 0.07 Spline - 90 Adapt, ~50 [Hz]

25.00 mm/sec 10.0 mm/mV

edika Plaza Clinic

BTL CardioPoint 2.30.33006.0, DIAG: 2.0.2.0; ECG: BTL-08 ECG, SN: 071D-B-05775

BTL CardioPoint - Stress Test

Page




SYAIFUL, MR

ID: 01031455, Born: 2/3/1983 (Male 37), 70.5 kg, 167 cm
Test Date: 2/10/2020 11:10:32 AM

MEDIK  ZA

Time: E 10:03 - Peak

Load: 13.4MET, HR: 157bpm, BP: -



Filter: 0.07 Spline - 90 Adapt, ~50 [Hz]

edika Plaza Clinic

BTL CardioPoint 2.30.33006.0, DIAG: 2.0.2.0; ECG: BTL-08 ECG, SN: 071D-B-05775

BTL CardioPoint - Stress Test

25.00 mm/sec 10.0 mm/mV

Page



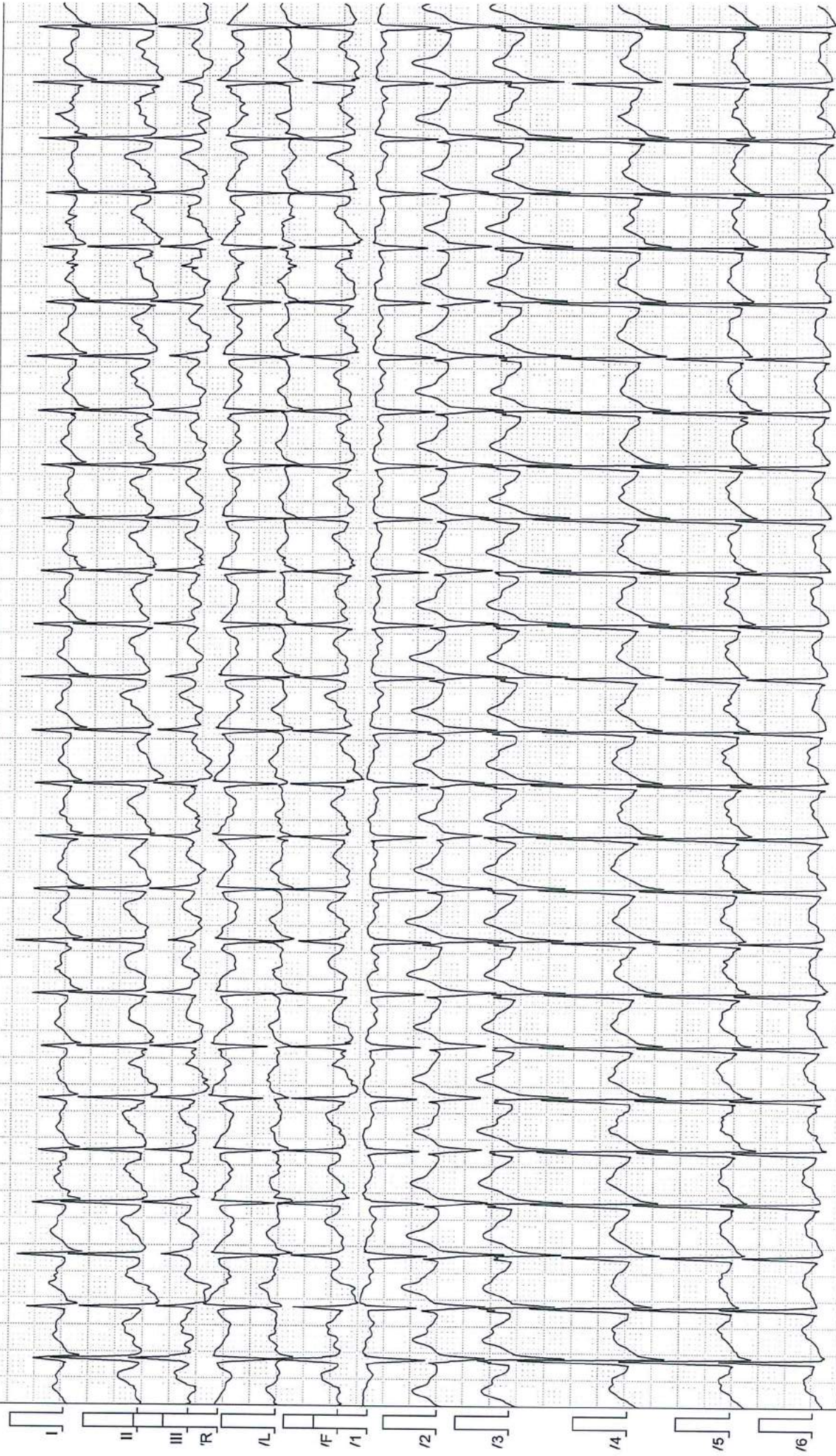
SYAIFUL, MR

ID: 01031455, Born: 2/3/1983 (Male 37), 70.5 kg, 1.67 cm
Test Date: 2/10/2020 11:10:32 AM

MEDIK  AZA

Time: R 00:10 - Recovery

Load: 1.7MET, HR: 152bpm, BP: 140/90



Filter: 0.07 Spline - 90 Adapt, ~50 [Hz]

25.00 mm/sec 10.0 mm/mV



SYAIFUL, MR

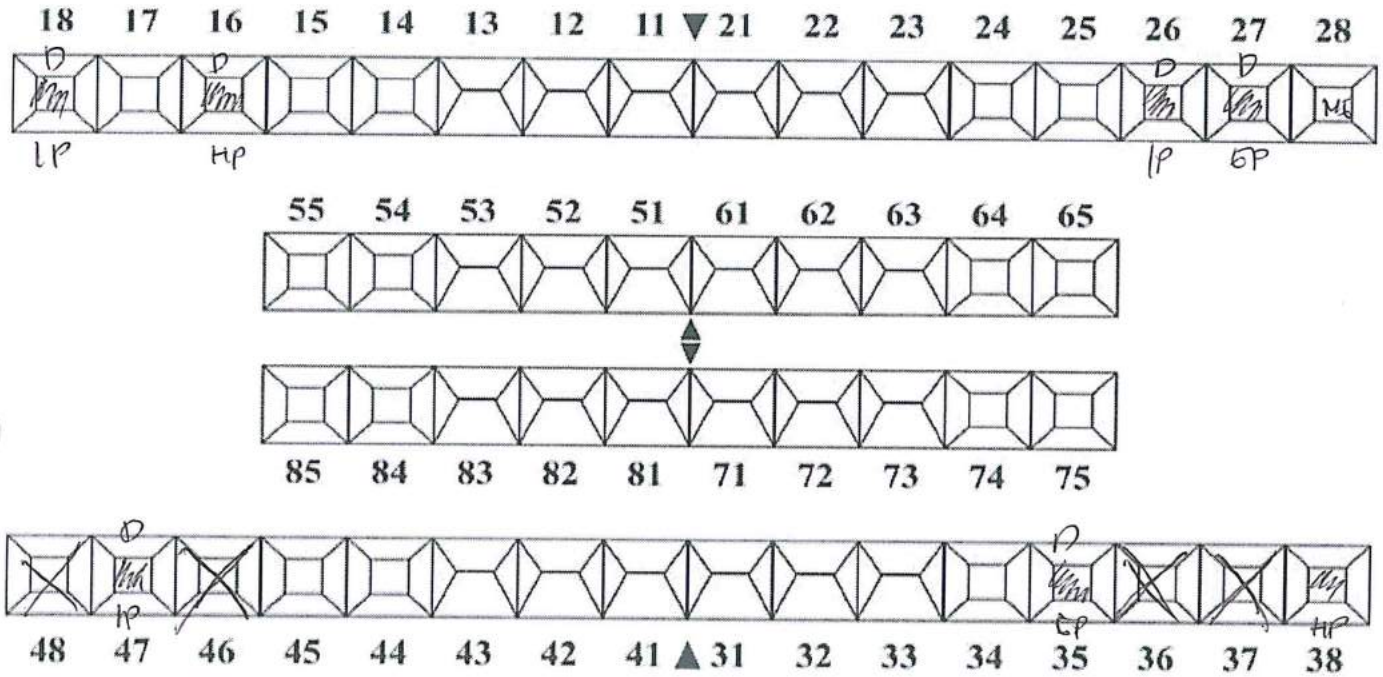
ID: 01031455, Born: 2/3/1983 (Male 37), 70.5 Kg, 167 cm
Test Date: 2/10/2020 11:10:32 AM

MEDIK  AZA

Stage	Time	Load		HR bpm	BP mmHg	SpO2 %	ST Level [mV], J+: 100ms User edited J position											
		km/h	%				MET	I	II	III	aVR	aVL	aVF	V1	V2	V3	V4	V5
Reference	E 00:03	0.8	0.0	1.4	71	-	0.09	-0.10	-0.34	0.01	0.14	-0.19	0.10	0.27	0.28	0.20	0.13	0.11
E 1 stage	E 03:01	2.7	10.0	4.6	89	-	0.04	-0.02	-0.03	-0.01	0.04	-0.11	0.08	0.20	0.26	0.17	0.15	0.05
E 2 stage	E 06:02	4.0	12.0	7.0	105	-	0.02	0.01	-0.16	-0.04	-0.07	-0.17	0.09	0.11	0.12	0.01	-0.05	-0.05
E 3 stage	E 09:03	5.4	14.0	10.1	135	-	0.00	-0.30	-0.90	0.10	0.16	-1.02	0.01	0.24	0.29	0.11	-0.03	-0.05
E 4 peak	E 10:08	6.7	16.0	13.4	155	-	-0.08	-0.16	-0.14	0.09	0.00	-0.16	0.09	0.16	0.13	-0.06	-0.14	-0.05
Recovery	R 00:20	0.8	16.0	2.5	152	-	0.02	-0.06	-0.06	0.02	0.06	-0.07	0.08	0.25	0.28	0.15	0.07	0.01

DENTAL EXAMINATION

Name : Saiful	Sex : M / F	MR :	Visit :
Comp. : inspektmd Sinergi		DOB :	
ODONTOGRAM			



Calculus dan stain

DIAGNOSA

OH ++, stain ++, calculus +
 18, 16, 26, 27, 38, 47 : caries
 27, 35 : GP

TREATMENT PLANNING

scaling & polishing
 18, 16, 26, 27, 38, 47 : filling
 27, 35 : EXO

Verified by: drg. Ilona Amalia/drg. Fajar Sulawati/drg. Siti Darjah/drg. Herlina

Fajar
 10/02/2020

PATIENT NAME : Tn Syaiful
 No. RM : inspektor
 Klinik/MCU/HCU : ENT

To. Dokter (Counsel) :

Kindly please counsel for patient who has take cares of

Diagnose :
 Klinik Summary :

Counsel Request :

COUNSEL ADVISE

Finding :

Eae: tympanum Intact post perforated, no drum
 Ears: clear eum, no secret, Sph devent
 Both normal

Diagnosis :

Thud
 Xrdiometry: T, T, Pharynx granule
 Heard with ear and none link.
 because of growth left ear
 Sph devent, Chronic pharyngitis

Recommendation :

- Stop smoking
- Dry eae protect
- What wacky in now
- Are
- Avoid Heavy Head set
 for lay period ← High Heels

Date : 10/2/20

Time :

EP

PT. KARTIKA BINA MEDIKATAMA

Signature

dr. MERISTIANA CHRISTIANE, Sp.THT

SIP: 13/E-150/31.74.04/1.779.3/e/2018

Complete Name

Formulir Number : FM - DR - 008 - 02
 Revisi Number : 00
 Date : 07 Juli 2017



RECEIVED
REVIEWED
PROCESSED

Med-Track
 SCHLUMBERGER PHYSICAL
 Confidential Medical

PRE EMPLOYMENT
Job Propose Office :
Field :
PERIODIC CHECK UP

Dear Schlumberger Employee

Your Med-Track physical will be handled only by trained and competent health professionals. The information contained in this medical report can be essential in saving your life when you are living or working abroad. In order to process your medical data, we now require that you sign a Consent Form authorizing Medical Provider-MP and the Schlumberger Medical Department to access your information.

Yo do, however, have the possibility of not releasing this medical data.

- If you have chosen not to authorize the release of your medical data, please fill in only page 1 and 2, dated and signed and return to Medical Provider-MP.
- If you have chosen to authorize the release of your medical data, please fill in the appropriate pages as indicated and return the entire Med-track report to Medical Provider-MP.

Do not forget to select and to sign the appropriate consent form depending on whether you have performed your Med-track physical in an Medical Provider-MP center or another center of your choice.

Thank you for cooperation

Schlumberger Medical Department and Medical Provider-MP

TO BE COMPLETED BY THE EMPLOYEE

PLEASE WRITE IN CLEAR CAPITAL LETTERS IN ENGLISH

LAST NAME
 (as appears in LDAP) SYAIFUL FIRST NAME.....

SEX Male (BIRTH DATE (day/month/year) 03/02/1983)

HOME PHONE..... NATIONALITY Indonesia

HOME ADDRESS Jl. Lumbu Limur II^A NO 281 BESI

Email address.....

CLEARLY INDICATED YOUR COMPANY INFORMATION-PUT AN "X" IN THE CORRESPONDING BOX BELOW :

Business segment :.....

(ex: WS, WG, etc.) Country of assignment.....

MEA..... EAF International Commuter

LAM..... SLR International Mobile

NAM..... Home country Mobile

GIN/EMPLOYEE NUMBER..... GeoMobile

POSITION/ Job Tittle..... Other (HCR, HCC, etc):.....

PLEASE ANSWER ALL THE QUESTIONS ON THIS PAGE

TO BE COMPLETED BY THE EMPLOYEE

BLOOD TYPE :

(If known)

PAST MEDICAL HISTORY DO YOU HAVE OR HAVE YOU HAD

(Check "Yes" or "no" column or put a "?" if uncertain)

	HAVE YOU EVER BEEN	YES	NO		HAVE YOU EVER BEEN	YES	NO		HAVE YOU EVER BEEN	YES	NO		
1	Sinus Trouble		✓	21	Cancer		✓	41	Rejected for employment or insurance for medical reasons				
2	Neck Swelling/glands		✓	22	Heart disease		✓					✓	
3	Difficulty in vision		✓	23	Rheumatic fever		✓	42		Awarded benefits for industrial injury		✓	
4	Any ear discharge		✓	24	Abnormal heartbeat		✓						
5	Asthma/bronchitis		✓	25	High blood pressure		✓	43	Treated for a mental condition		✓		
6	Hayfever/other allergy		✓	26	Stroke		✓	44	Treated for drinking problem/ drug abuse		✓		
7	Any skin trouble		✓	27	Serious chest pain		✓						
8	Tuberculosis		✓	28	Any blood disease		✓	45	Exposed to : Mercury Radioactivity Toxic chemicals Excess noise		✓		
9	Shortness of breath		✓	29	Kidney disease		✓						✓
10	Coughed blood		✓	30	Painful passage of urine		✓						✓
11	Abdominal pain		✓	31	Blood in urine		✓				✓		
12	Stomach ulcer		✓	32	Diabetes		✓				✓		
13	Recurrent indigestion		✓	33	Headache/migraine		✓		FOR WOMAN ONLY				
14	Jaundice/hepatitis		✓	34	Dizziness/fainting		✓	46	An abnormal smear		✓		
15	Gall bladder disease		✓	35	Epilepsy		✓						
16	Marked change in bowel habits		✓	36	Joints/Spinal trouble		✓	47	A gynecological treatment		✓		
17	Blood in stool		✓	37	Surgical operation		✓						
18	Change in weight		✓	38	Accident/Fracture		✓						
19	Varicose veins		✓	39	Tropical disease		✓	48	Are you pregnant		✓		
20	Lump in breast		✓	40	Fear of heights		✓						

You have answered "yes" to questions 37,38 or 39 or if you have or had an illness not mentioned above please detail in ENGLISH and in clear Capital letters :

.....
.....

Medication taken regularly :

.....

Do you take preventive malaria medication when in high malaria risk areas?	YES <input type="checkbox"/>	NO <input type="checkbox"/>
If yes, which medication?		

Allergies to medication :

DATE OF LAST VACCINATIONS : (day/month/year)

Polio/...../..... Hepatitis B/...../..... Hepatitis A/...../.....

Tetanus/...../..... Yellow fever...../...../..... Thypoid...../...../.....

Other..... Date/...../..... Other..... Date/...../.....

Alcohol consumption : Number of glasses per day : Tobacco : Number of cigarettes per day : *+ 10 stick/day*

TO BE COMPLETED BY THE EXAMINING PHYSICIAN

PLEASE WRITE IN CLEAR CAPITAL LETTERS IN ENGLISH OR TYPE WHENEVER POSSIBLE (NO ABBREVIATIONS PLEASE)

DRUG TESTING for pre-employment meicals only			
Not performed <input type="checkbox"/>	Performed <input checked="" type="checkbox"/>	Positive <input type="checkbox"/>	Negative <input checked="" type="checkbox"/>

PLEASE UP DATE VACCINATIONS : Indicate Only vaccinations performed during this examination

POLIO HEPATITIS B HEPATITIS A TETANUS YELLOW FEVER THYPOID

OTHER VACCINATIONS PERFORMED :

Please make sure patient has correct malaria protection when travelling to high malaria risk areas

MEDICAL EXAMINATION

IF ABNORMAL, PLEASE DETAIL

	Normal	abnormal	
1. Eyes and pupils	(n)	a
2. Ear/Nose/Throat	(n)	a
3. Teeth and mouth	n	(a)	Delayed, missing, impacted, gangrene pulps, stain, calculus teeth
4. Lungs and chest	(n)	a
5. Cardiovascular	(n)	a
6. Abdo, Viscera	(n)	a
7. Hemial orifices	(n)	a
8. Anus and rectum	(n)	a
9. Genito-urinary	(n)	a
10. Extremities	(n)	a
11. Musculo-skeletal	(n)	a
12. Skin/varicose vns	(n)	a
13. Neurological/Mental fitness	(n)	a
14. Breast	(n)	a

HEIGHT 167cm	WEIGHT 70,5	BLOOD PRESSURE 120/80	PULSE 64x	HEARING			VISION		WITH GLASSES	COLOR VISION
				R	n ✓	a ^o	Distant	20/20 20/50	Yes <input type="checkbox"/>	Normal
				L	n	a ✓	Near	31 R 31 L	No <input checked="" type="checkbox"/>	

Decreasing of hearing acuity on high freq. of left ear.

TO BE COMPLETED BY THE EXAMINING PHYSICIAN

CLINICAL EXAMINATION

ECG (n) a.....
 Chest X ray (n) a.....

BLOOD ANALYSIS

RBC..... 5.7..... M/mm ³	SGOT..... 26..... IU/L
WBC..... 12.8..... M/mm ³	SGPT..... 39..... IU/L
NEUTRO..... 49..... %	GAMMA GT..... 29..... IU/L
EOSINO..... 3..... %	GLYCEMIA..... 98..... (mmol/l)
BASO..... 0..... %	CHOLESTEROL TOTAL..... 190..... mg/dL
LYMPHO..... 42..... %	HDL..... 34.7..... mg/dL
MONO..... 9..... %	LDL..... 89..... mg/dL
HEMATOCIT..... 50..... %	CREATININE..... 1.0..... mg/dL
HEMOGLOBIN..... 14.5..... g/dl	URIC ACID..... 7.07..... mg/dL
SR (Sedimentation rate)..... 7.....	TRIGLYCERIDES..... 355..... mg/Dl

BLOOD TYPE A +

CONCLUSION : FIT IN ALL AREAS YES NO

MUST BE REASSESSED : YES NO

(If you answer No, please detail your reasons)

Detail :
 - Hypertriglyceridemia
 - Ocular hypertension of both eyes
 - USG abd : Intraluminal sludge of GB

DOCTOR'S SIGNATURE 
--

MEDICAL CENTER STAMP/SEAL  PT. KARTIKA BINA MEDIKATAMA

Date of medical examination (day/month/year)...../...../.....

EXAMINING PHYSICIAN'S FULL NAME AND ADDRESS

Name :

Address: **dr. REZKHA AMALIA**

Email : **SIP. 54/B.15a/31.74.04.1004-1.779.3/e/2018**



TO BE COMPLETED BY THE EXAMINING PHYSICIAN

Med Track Plus Exam

Only for high mobility employees (IM,IC,GM.HCM) over 40 years of age

If you are over 40 years of age, Schlumberger offers you the possibility of performing a more in-depth health assessment every 3 years in order to check your general wellness. Med track plus should be performed at the same time as your usual Med Track exam.

The Med Track Plus health assessment targets in particular the increased cancer and cardiovascular risks inherent to people over 40 years of age. Tests designated below in Med-Track Plus are only recommended and not mandatory.

EYES :

Tonometry Right eye (Glaucoma testing).....20.0.....mmHg
Tonometry Left eye (Glaucoma testing).....20.0.....mmHg

CONDITIONAL BLOOD TEST :

PSA.....ng/ml TSH.....UI
CEA.....µg/l Alkali phosphatase.....79.....UI

IF ABNORMAL, PLEASE DETAIL

LUNGS/Functional Respiratory testing (n) a

ABDOMINAL AND PELVIC ECHOGRAPHY n a

CARDIOVASCULAR RISK FACTORS :

Stress test (n) a

Carotid Echo-Doppler n a

Cardiac Echography n a

FOR MEN ONLY :

Prostate Echography n a

FOR WOMAN ONLY :

Mammogram n a

PAP Smear n a

Doctor's additional comments or conclusions :

USG Abdomen : mild fatty liver, intraluminal sludge of gallbladder

PROCURATION

RELEASE OF MEDICAL INFORMATION, PHYSICAL EXAMINATION, DIAGNOSTIC AND MEDICAL TREATMENT

The undersigned is :

Name : SYAIFUL

DOB : 03-02-1983

Employee Number:

Date of visit : 10-02-2020

(Next called The Giver of Authorization), hereby authorize to :

Medika Plaza Clinic, Kartika Chandra Hotel 3rd Floor, Jl. Jend Gatot Subroto kav 18-20 Jakarta 12060

(Next called The Recipient of Authorization) :

SPECIAL

To provide Medical information of me, either orally or in writing in accordance with The Policies in Medika Plaza Clinic to :

Individual/Company Name :


Company address :

And willing to do Physical examination, Diagnostic and Medical Treatment.

In connection with the affairs of the above, it is hereby relieve the Recipient Authorization of any claim or Legal Consequences of Third Parties.

Jakarta, 10-02 ~~2018~~ 2020

The Giver of Authorization


(SYAIFUL)

Name & Signature