

Certificate Of Health Assessment




Name	Age	Position	Department
ARI CAHYADI	40 yo	ASST. INSPECTOR	-

COMPANY :

INSPEKTINDO SINERGI PERSADA, PT

CONCLUSION

FIT TO WORK	
FIT WITH MEDICAL NOTE	✓
TEMPORARY UNFIT	
UNFIT	

Issued Date	Doctors Name	Prepared By
10 June 2022	Yosephine Simanungkalit, MD <small>PKTK : KEP.043/BINWASK3-PNK3/KK/II/2018 SIP : 1/B.15a/31.74.02.1004/-1.779.3/e/2019</small>	 
Expired Date		Verified By
10 June 2023	dr. Muhammad Ilyas, Sp.Ok <small>SIP : 29/B.15b/31.74.04.1004.02.009.K.1/3/-1.779.3/e/2019</small>	PT. KARTIKA BINA MEDIKATAMA 

No. Formulir : FM-DR-008-05
 No. Revisi : 00
 Tanggal Terbit : 2 Mei 2011

Certificate Number : MP-BOP/1-20220610/137410
 MCU Validity Check
<https://mcu-validasi.medikapla.com>

TO WHOM IT MAY CONCERN

Kepada yang berkepentingan

This is certify that today Friday, 10 June 2022 Medika Plaza Clinic has performed urine drug screening and/or breath alcohol test to :

Dengan ini menyatakan bahwa, pada hari ini Jumat, 10 Juni 2022 Medika Plaza Clinic telah melakukan urine drug screening dan/atau breath alcohol test kepada :

ARI CAHYADI

With the results are as follows :
Dengan hasil sebagai berikut :

Drugs Test <i>Uji Obat</i>	Result <i>Hasil</i>		
URINE DRUGS SCREENING			
- Amphetamine	<input type="checkbox"/> Non-Negative	<input checked="" type="checkbox"/> Negative	<input type="checkbox"/> N/A
- Met-Amphetamine	<input type="checkbox"/> Non-Negative	<input checked="" type="checkbox"/> Negative	<input type="checkbox"/> N/A
- Cocain	<input type="checkbox"/> Non-Negative	<input checked="" type="checkbox"/> Negative	<input type="checkbox"/> N/A
- THC/Canabis/Marijuana	<input type="checkbox"/> Non-Negative	<input checked="" type="checkbox"/> Negative	<input type="checkbox"/> N/A
- Morphine/Opiates	<input type="checkbox"/> Non-Negative	<input checked="" type="checkbox"/> Negative	<input type="checkbox"/> N/A
- P C P/Phencyclidine	<input type="checkbox"/> Non-Negative	<input checked="" type="checkbox"/> Negative	<input type="checkbox"/> N/A
- Barbiturate	<input type="checkbox"/> Non-Negative	<input type="checkbox"/> Negative	<input checked="" type="checkbox"/> N/A
- Benzodiazepin	<input type="checkbox"/> Non-Negative	<input checked="" type="checkbox"/> Negative	<input type="checkbox"/> N/A
- Methadone	<input type="checkbox"/> Non-Negative	<input checked="" type="checkbox"/> Negative	<input type="checkbox"/> N/A
- Propoxyphene	<input type="checkbox"/> Non-Negative	<input type="checkbox"/> Negative	<input checked="" type="checkbox"/> N/A
- Oxycodone	<input type="checkbox"/> Non-Negative	<input type="checkbox"/> Negative	<input checked="" type="checkbox"/> N/A
- MDMA	<input type="checkbox"/> Non-Negative	<input checked="" type="checkbox"/> Negative	<input type="checkbox"/> N/A
- 6-MAM	<input type="checkbox"/> Non-Negative	<input type="checkbox"/> Negative	<input checked="" type="checkbox"/> N/A
BREATH ALCOHOL TEST			
- Alcohol	<input type="checkbox"/> Non-Negative	<input checked="" type="checkbox"/> Negative	<input type="checkbox"/> N/A

Jakarta, June 10, 2022



PT. KARTIKA BINA MEDIKATAMA
(dr. Petty Atmadja, Sp.PK)

Clinical Patologist

HEALTH ASSESSMENT REPORT

Of

ARI CAHYADI

01.00079742

Friday, 10 June 2022

MP BELTWAY CLINIC

Beltway Office Park, Annex Building, Ground Floor

Jl. TB. Simatupang Kav.41, Jakarta Selatan 12550

Tlp : (62-21) 808 66 099, Fax : (62-21) 808 66 098

www.medikaplaza.com

MP BELTWAY CLINIC

Beltway Office Park, Annex Building, Ground Floor
Jl. TB. Simatupang Kav.41, Jakarta Selatan 12550
Tlp : (62-21) 808 66 099, Fax : (62-21) 808 66 098
www.medikaplaza.com

PATIENT DATA

MedRec.	: 01.00079742	EMPLOY. STATUS	: Employee
NAME	: ARI CAHYADI	BIRTHDATE	: 09 April 1982
EMPLOYEE No.	: -	SEX	: Male
JOB TITLE	: ASST. INSPECTOR	STATUS	: Married
COMP. NAME	: INSPEKTINDO SINERGI PERSADA, PT	NASIONALITY	: INDONESIA

SUMMARY

MEDICAL FINDING :

1. Dyslipidemia
2. Hyperuricemia
3. Increase Gamma GT level
4. Non reactive Anti HBs
5. Decreasing of visual acuity of both eyes
6. Partial colour blindness
7. Decreasing of hearing acuity on high frequency of left ear
8. Abdominal USG : Fatty liver. Cholelithiasis multiple
9. Spirometry : Mild Restrictive & Mild Obstructive
10. Obesity
11. Missing, calculus, radix and decayed teeth


Your fitness status is fit with medical note:

1. Decreasing of visual acuity of both eyes
2. Abdominal USG : Cholelithiasis multiple
3. Obesity

SUGGESTION :

1. Low fat and carbohydrate diet and exercise regularly minimal 3 times a week.
2. Low purine diet such as meats including organ meats, alcoholic beverages, beans, shrimp, scallops, some vegetables in limited amount such as: spinach, cauliflower, asparagus and mushroom
3. Take enough rest minimal 8 hours/day. Repeat SGOT and SGPT examination 1 month later and consult to an Internist if still increase
4. Need to get Hepatitis B vaccination (booster)
5. You need to wear glasses for both vision. Consultation with an Ophthalmologist for further evaluation of Decreasing of visual acuity of both eyes
6. Avoid working which need an accurate colour differentiation.
7. Avoid noisy environment and use earplug properly while working at noisy work environment to prevent further hearing impairment
8. Low fat diet and exercise regularly minimum 3x/week. Repeat abdominal USG 6 months later and Consultation with an Internist for further evaluation of Abdominal USG : Cholelithiasis multiple
9. Avoid dust and fumes and use face mask while working at dusty area. Consult to a Pulmonologist if any complaint of spirometry result
10. Reduce body weight gradually 0.5 Kgs/week, by doing regular exercise (aerobic/jogging), 3-4x/week, 30-45 minutes and reduce high calorie diet until maximal body weight is 66.42Kgs (present body weight is 86.4Kgs). Consultation with a Nutritionist for evaluation of obesity
11. Consultation with a Dentist for dental care, minimal once a year or better once in six month

Responsible Doctor



Yosephine Smanungkalit, MD

Notes:

If you need the further information or consultation, please contact us via :

- Email : - enjelita@medikaplaza.com
- Rezkha.Amalia@medikaplaza.com
- Puteri.Melati@medikaplaza.com

PRIVATE

Printed by : reysti

Telepon Klinik : (62-21) 8086 6099

PRIVATE

Printed by : reysti

CLINICAL EVALUATION

Name : ARI CAHYADI	Sex : Male	MR : 01.00079742	Visit : 10/06/2022
Comp. : INSPEKTINDO SINERGI PERSADA, PT		DOB : 09 April 1982	
EXAMINATION	RESULT	NOTES	

ANAMNESA**PRESENT COMPLAINT AND HISTORY OF PRESENT****ILLNESS**

Present complaint

No complaint

MEDICAL HISTORY

Alergy	No
Imunisasi	Yes
Surgery	No
Hospitalization	No
Disease	No

LIFE STYLE

Alcohol intake	No	
Smoking	No	Mild smoker
Exercise	Yes	Jogging 2x/week

FAMILY MEDICAL HISTORY

Diabetes Melitus	No
Hypertension	No
Heart disease	No
Lung TB	No
Kidney disease	No
Astma	No
Mental disease	No
Epilepsy	No
Cancer	No
Color blind	No
Stroke	No
Liver disease	No
Bone & joint	No
Others disease	No

WORK EXPOSURE

Noise	No
Heat Stress	No
Cold Stress	No
Vibration	No
Involving height	No
Radiation	No
Dust	No

CLINICAL EVALUATION

Name : ARI CAHYADI	Sex : Male	MR : 01.00079742	Visit : 10/06/2022
Comp.: INSPEKTINDO SINERGI PERSADA, PT		DOB : 09 April 1982	

EXAMINATION	RESULT	NOTES
Toxic chemical	No	
Irritating fluid	No	
Smoke	No	
Bacterium/Virus/Parasite	No	
Blood	No	
Animal	No	
Operating heavy mobile equipment	No	
Manual Handling	No	
Sitting continuously over 4 hours	No	
Stand continuously over 4 hours	No	
Using monitor screen more than 4 hours per day	No	
Exposure	No	
Unergonomic body positions	No	
Shift work	No	
Work is not accordance with skills and knowledge	No	
Workload does not accordance with time	No	
Work conflict	No	
Inappropriate task	No	
Career barriers	No	
Family conflict	No	
Working arround rotating machinery	No	
Administration work	No	
Handling food product	No	
Others	Yes	Offshore & onshore
PHYSICAL EXAMINATION		
General Appearance	Good	
Body shape	Picnicus	
VITAL SIGN		
Body Weight	86.4 Kg	
Body Height	163 Cm	
BMI	32.51 Kg/m ²	
Normal Weight	49.15 - 66.42 Kg	
BMI Conclusion	Obesity	
Blood Pressure	120/80 mmHg	
Pulse	70 x/minute	
Body Temperature	36.4 °C	
RR	17	

CLINICAL EVALUATION

Name : ARI CAHYADI	Sex : Male	MR : 01.00079742	Visit : 10/06/2022
Comp. : INSPEKTINDO SINERGI PERSADA, PT		DOB : 09 April 1982	
EXAMINATION	RESULT	NOTES	

Neck Circumference	39 Cm
Arm Circumference	35 Cm
Chest size	100 Cm
Abdominal Circumference	90 Cm

SKIN

Skin	Normal
------	--------

EYE

Left	Normal
Right	Normal

ENT

Auricle	Normal
Ear canal	Normal
Drums	Normal
Septum/Conchae	Normal
Sinuses	Normal
Pharynx	Normal
Tonsil	Normal

MOUTH

Gum	Normal	
Dental	Abnormal	Missing, calculus, radix and decayed teeth

NECK

General	Normal
Thyroid Gland	Normal

CHEST

Form	Normal
Lung	Normal
Heart	Normal
Breast	Normal

ABDOMEN

Form	Flat
Palpation	Supple
Liver	Not Palpable
Spleen	Not Palpable
Kidney	No Ballotment
Nyeri Ketok (CVA)	No
Hernia inguinal	No

EXTRIMITIES

CLINICAL EVALUATION

Name : ARI CAHYADI

Sex : Male

MR : 01.00079742

Visit : 10/06/2022

Comp. : INSPEKTINDO SINERGI PERSADA, PT

DOB : 09 April 1982

EXAMINATION	RESULT	NOTES
Bones, joint	Normal	
Muscles, tonus	Normal	
Fingernails	Normal	
Hand	Normal	
Foot	Normal	
RECTAL EXAMINATION		
Hemorrhoid	Negative	
Rectum	Normal	
SENSORIK EXAMINATION		
Tes Raba	Normal	
MOTORIK EXAMINATION		
Tes Grip	Normal	
REFLEX EXAMINATION		
Physiologic reflex	Normal	
Patologic reflex	Normal	
OTHERS EXAMINATION		
Coordination	Normal	
LIMPHE SYSTEM		
Submandibula	Normal	
Neck Gland	Normal	
Armpit gland	Normal	
Inguinal	Normal	
MUSKULOSKLETAL EXAMINATION		
Lhermitte Test	Negative	
Spurling Test	Negative	
Neers Test	Negative	
Yergason Test	Negative	
Phalen Test	Negative	
Tinel Test	Negative	
Finkelstein Test	Negative	
Straight Leg Raise Test	Negative	

OPHTHALMOLOGY DIAGNOSTIC

Name : ARI CAHYADI	Sex : Male	MR : 01.00079742	Visit : 10/06/2022
Comp. : INSPEKTINDO SINERGI PERSADA, PT		DOB : 09 April 1982	

EXAMINATION		Right	Left
Reading		-	
Previous Glasses		-	-
Without Glasses	Distant	20/70	20/100
	Near	J2	J2
Correction	Distant	S-1.75 20/20	S-2.00 20/20
	Near	S+1.00 J1	S+1.00 J1
Depth Perception		-	
Tonometry		16.0 mmHg	19.0 mmHg
Funduscopy		NORMAL	NORMAL
Visual Fields		Normal	
Colour Blind Test		Partial Colour Blindness	

Impression : Myopia simplex ODS
Presbyopia

RADIOLOGY DIAGNOSTIC

Name : ARI CAHYADI

Sex : Male

MR : 01.00079742

Visit : 10/06/2022

Comp. : INSPEKTINDO SINERGI PERSADA, PT

DOB : 09 April 1982

EXAMINATION**RESULT**

THORAX PA

No abnormality seen in both lungs.
Normal bronchovascular markings in both hili.
The heart is normal in size and shape.
The mediastinum is not widened.
Both sinus and diaphragms are good.
No evidence of pleural effusion.

Impression

Normal heart and lungs.

RADIOLOGY DIAGNOSTIC

Name : ARI CAHYADI

Sex : Male

MR : 01.00079742

Visit : 10/06/2022

Comp. : INSPEKTINDO SINERGI PERSADA, PT

DOB : 09 April 1982

EXAMINATION**RESULT**

USG ABDOMEN

LIVER:

Normal in size and contour, smooth surface, echoes structure parenchyme which are homogenous increase. No sign of SOL.

Intrahepatic vascularity and billiary tract are normal.

GALL BLADDER:

Normal in size, contour and surface. There are multiple hyperechoic lesion with posterior acoustic shadow, largest size +/- 0,75 cm.

BOTH KIDNEYS:

Normal in size, contour and surface. No sign of obstruction/ stone/ SOL.

PANCREAS:

Normal in size, contour and surface. No sign of SOL.

LIEN:

Normal in size and contour, the echoes are homogenous. No sign of SOL.

URINARY BLADDER:

Normal in contour and surface. No sign of stone/ SOL.

PROSTATE AND VESICULA SEMINALIS:

Normal in size and contour which are homogenous echoes and no sign of focal lesion/ SOL.

Impression

Fatty liver

Cholelithiasis multiple

Other intra abdominal organs are normal

LABORATORY RESULT

Name : ARI CAHYADI	MR : 01.00079742	Visit : 10/06/2022	#Lab : IN780026161410
Comp. : INSPEKTINDO SINERGI PERSADA, PT	Sex : Male	DOB : 09 April 1982	
EXAMINATION	RESULT	NORMAL RANGE	

HEMATOLOGI

ABO/Rh Typing "O" Rh(+) positive

Automated Blood Count

White Blood Cell (WBC)	7.8	3.8 - 11.0
Erythrocyte (RBC)	5.1	4.4 - 5.9
Haemoglobin	15.7	13.2 - 17.3
Hematocrit	46	40 - 52
Thrombocytes	287	150 - 440

MCV, MCH, MCHC

MCV	89	80 - 100
MCH	31	26 - 34
MCHC	34.4	32 - 36
ESR	10	0 - 10

Differential Count

Basophils	1	0 - 1
Eosinophil	5 *	2 - 4
Bands / Stab	4	3 - 5
Neutrophils	53	50 - 70
Lymphocytes	30	25 - 40
Monocytes	7	2 - 8

BLD CHEMISTRY/LIPID PROFILE

Total Cholesterol	212 *	Normal/Desireable: <200 Borderline High: 200-239 High: >=240
HDL Cholesterol	51.9	Normal : >40 - <60 Low HDL : <40 Desireable : >=60
LDL Cholesterol	127	Optimal: <100 Near/Above Optimal: 100-129 Borderline High: 130-159 High: 160-189 Very High: >=190
Triglycerides	165 *	Normal : <150 Borderline High: 150-199 High : 200-499 Very High : >=500

BLD CHEMISTRY/KIDNEY FUNCTION

LABORATORY RESULT

Name : ARI CAHYADI	MR : 01.00079742	Visit : 10/06/2022	#Lab : IN780026161410
Comp. : INSPEKTINDO SINERGI PERSADA, PT	Sex : Male	DOB : 09 April 1982	

EXAMINATION	RESULT	NORMAL RANGE
Ureum	19.0	10.0 - 50.0
Creatinine	1.27	0.60 - 1.30
Uric Acid	7.73 *	3.50 - 7.20

BLD CHEMISTRY/LIVER FUNCTION

Total Bilirubin	0.60	0.1 - 1.0
Direct Bilirubin	0.20	0.0 - 0.2
Indirect Bilirubin	0.40	0.0 - 0.8
SGOT(AST)	21	13 - 45
SGPT (ALT)	24	13 - 50
Alkaline Phosphatase	53	30 - 120
Gamma GT	55 *	0 - 50
Albumin	4.5	3.5 - 5.5
Globulin	3.40	2.3 - 3.5
Total Protein	7.9	6.6 - 8.7

BLD CHEMISTRY/ELECTROLYTES

Sodium (Na)	141	135 - 155
Potassium (K)	4.6	3.6 - 5.5
Chloride (Cl)	103	95 - 108

BLD CHEMISTRY/DIABETES

Glucose Fasting	93	< 100
Glucose Urine	Negative	Negative
Keton Urine	Negative	Negative

Blood Glucose 2 PP

Blood Sugar 2 Hours PP	111	< 140
Glucose Urine	Negative	Negative
Keton Urine	Negative	Negative

SEROLOGI / IMUNOLOGI

SARS CoV-2 Rapid Antigen	Negative	Negative
HBsAg (Quantitative)	0.00	0.00 - 0.03
Anti Hbs (Quantitative)	0,4 *	>= 5.0

TOXICOLOGY - DRUGS SCREENING

MDMA	Negative	Negative
Methadone	Negative	Negative
Phencyclidine	Negative	Negative
THC/Marijuana	Negative	Negative
Amphetamine	Negative	Negative
Benzodiazepines	Negative	Negative

LABORATORY RESULT

Name : ARI CAHYADI	MR : 01.00079742	Visit : 10/06/2022	#Lab : IN780026161410
Comp. : INSPEKTINDO SINERGI PERSADA, PT	Sex : Male	DOB : 09 April 1982	

EXAMINATION	RESULT	NORMAL RANGE
Opiat	Negative	Negative
Cocain	Negative	Negative
Metamphetamine	Negative	Negative
Alcohol	Negative	Negative

URINALYSIS**Complete Urine Analysis****Macroscopic**

Color	Yellow	
Turbidity	Clear	Clear
Specific Gravity	1.016	1.000 - 1.030
pH	5.0	4.5 - 8.0
Leucocyte	Negative	Negative
Glucose	Negative	Negative
Nitrit	Negative	Negative
Bilirubin	Negative	Negative
Blood	Negative	Negative
Urobilinogen	Normal	Normal
Protein	Negative	Negative
Keton	Negative	Negative

Microscopic

RBC	0-1	0 - 1
WBC	0-1	0 - 4
Cylinder	Negative	
Epithels Squamous	0-1	5 - 15
Crystals	Negative	
Bacteria	Negative	Negative
Others	Negative	

STOOL / RECTAL SWAP**Faeces Complete****Macroscopic**

Color	Brown	
Consistency	Smooth	
Mucus	Negative	Negative
Blood	Negative	Negative
Pus	Negative	Negative
Parasit	Negative	Negative
Lipid	Negative	Negative

LABORATORY RESULT

Name : ARI CAHYADI	MR : 01.00079742	Visit : 10/06/2022	#Lab : IN780026161410
Comp. : INSPEKTINDO SINERGI PERSADA, PT	Sex : Male	DOB : 09 April 1982	

EXAMINATION	RESULT	NORMAL RANGE
-------------	--------	--------------

Microscopic

RBC	0-1	0 - 1
WBC	0-1	0 - 5
Amoeba	Negative	
Ephitels	Positive	Positive
Worm Eggs	Negative	Negative
Yeast	Negative	Negative
Muscle Fiber	Negative	Negative
Others	Negative	Negative

Digestive

Amylum	Negative	Negative
Fat	Negative	
Fibers	Positive	Positive

SPIROMETRY DIAGNOSTIC

Name : ARI CAHYADI	Sex : Male	MR : 01.00079742	Visit : 10/06/2022
Comp. : INSPEKTINDO SINERGI PERSADA, PT		DOB : 09 April 1982	

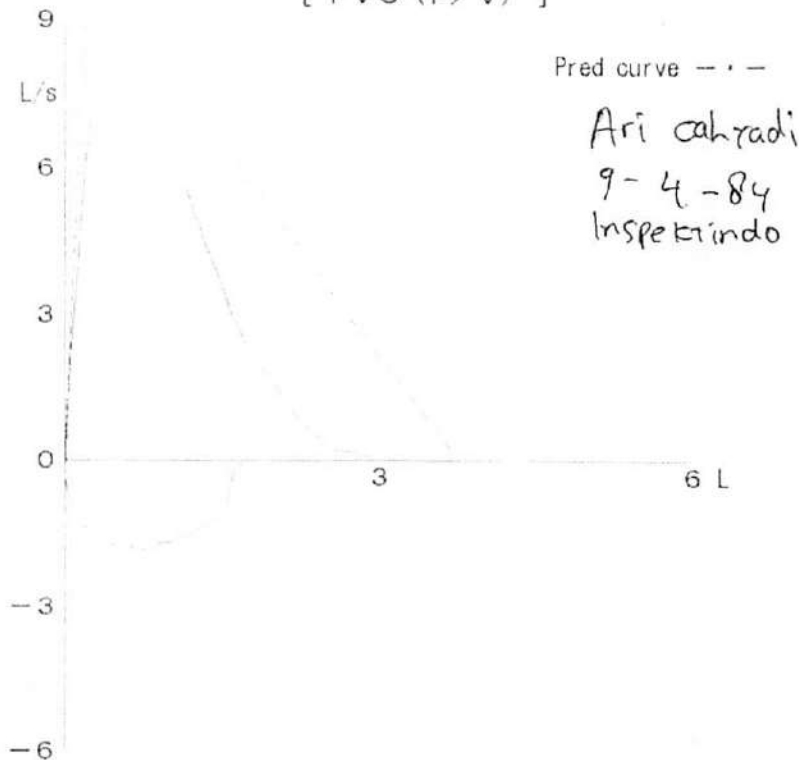
EXAMINATION	RESULT
FVC Result	: 2.91 L---> 77.2 %
FEV1 Result	: 2.43 L---> 73.9 %
FEV1/FVC Result	: 83.51 %---> 108.6 %
PEF Result	: 7.34 L/S---> 71.4 %
Indonesian Standart Result	:
Index	:
Spirometry Result	: Abnormal

Impression : Mild Restrictive & Mild Obstructive

[COPD CLASSIFICATION]

FEV1/FVC	83.51 %
%FEV1.0	73.90 %
Stage	Normal
Recommended treatment by GOLD	

[FVC (F/V)]



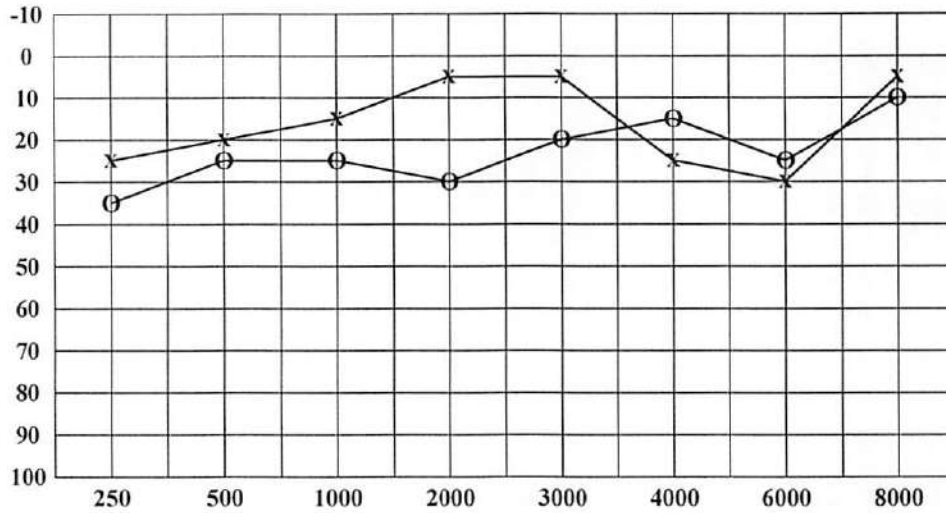
AUDIOMETRY DIAGNOSTIC

Name : ARI CAHYADI	Sex : Male	MR : 01.00079742	Visit : 10/06/2022
Comp. : INSPEKTINDO SINERGI PERSADA, PT		DOB : 09 April 1982	

RESULT

Left Ear	250	500	1000	2000	3000	4000	6000	8000
AC	25	20	15	5	5	25	30	5
BC	-	-	-	-	-	-	-	-

Right Ear	250	500	1000	2000	3000	4000	6000	8000
AC	35	25	25	30	20	15	25	10
BC	-	-	-	-	-	-	-	-



< : Right Ear (BC)
 > : Left Ear (BC)
 O : Right Ear (AC)
 X : Left Ear (AC)

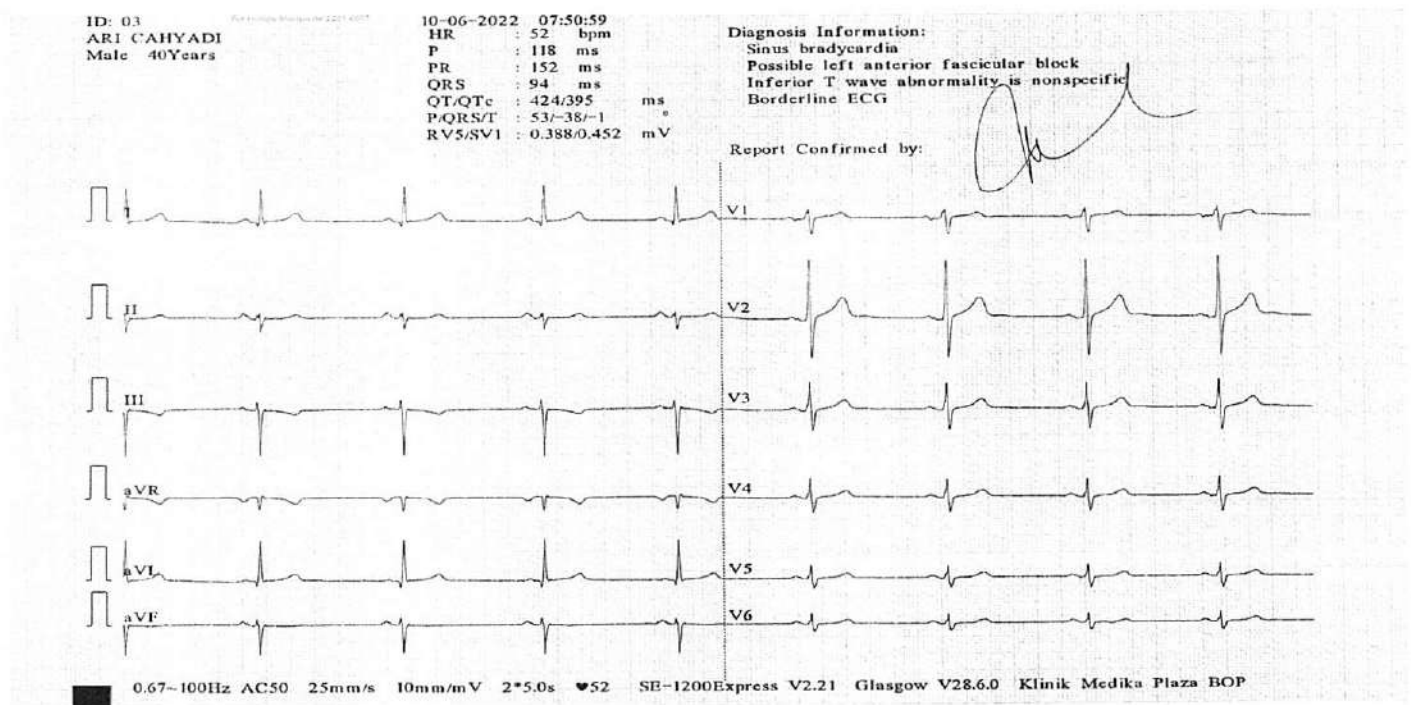
Conclusion Right Ear : Hearing threshold = 23.75 dB
 (Within normal limit)

Conclusion Left Ear : Hearing threshold = 16.25 dB
 (Within normal limit)
 With decreasing on frequency 6000Hz

CARDIOLOGY DIAGNOSTIC

Name : ARI CAHYADI	Sex : Male	MR : 01.00079742	Visit : 10/06/2022
Comp. : INSPEKTINDO SINERGI PERSADA, PT		DOB : 09 April 1982	

EXAMINATION	RESULT	Comments :
TREADMILL	Sinus Rythm axis (N), P wave (N), PR int 0.16" ST - T segment (N), aritmia (-)	Treadmill Exercise Test : Negative Cardiopulmonary Fitness Classification : Good METs : 11.8
ELECTROCARDIOGRAPHY	Sinus Rythm axis (N), P wave (N), PR int 0.16" ST - T segment (N), aritmia (-)	Normal ECG



12-LEAD REPORT

ARI CAITYADI
Patient ID: 01.00079742
10.06.2022
9:10:52

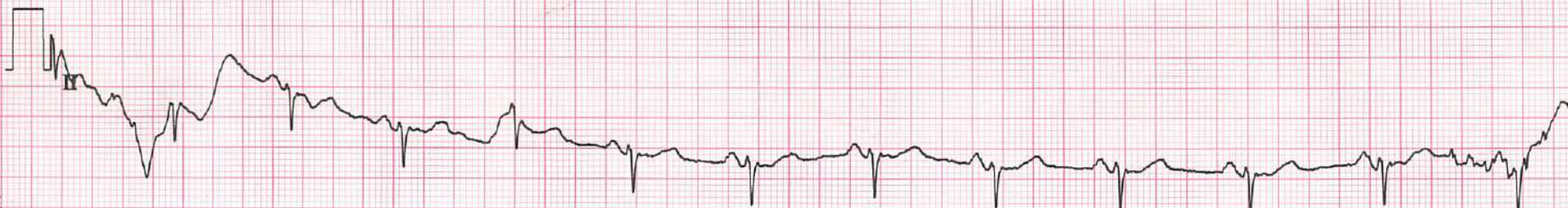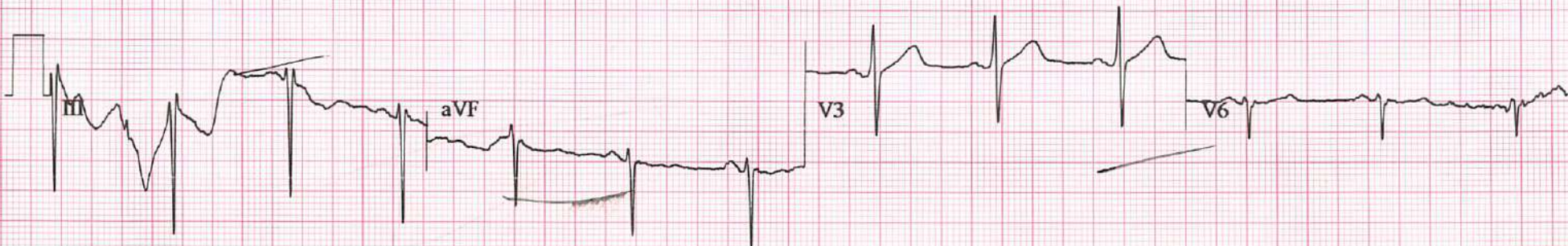
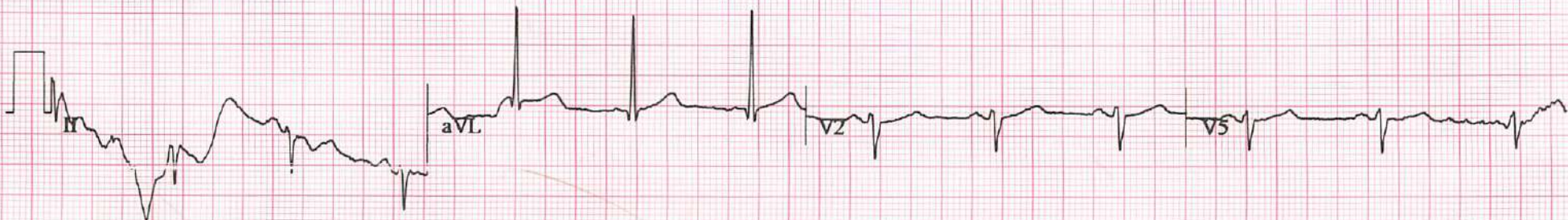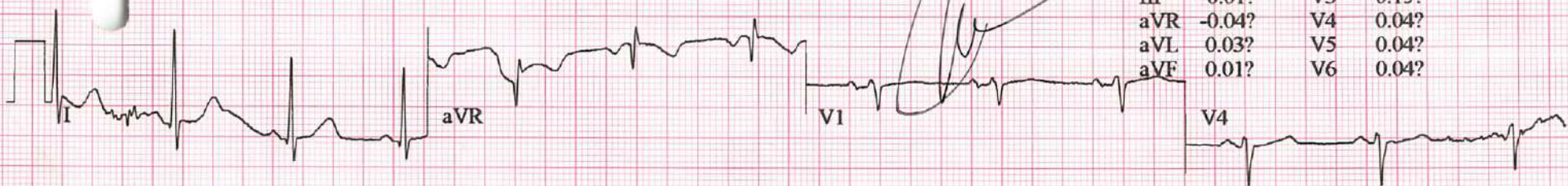88 bpm
120/80 mmHg

PRETEST
STANDING
00:07

BRUCE
0.0 km/h
0.0%

MEDIKA # A7A
Measured at 60ms Post J
Auto Points

Lead	ST(mV)	Lead	ST(mV)
I	0.04?	V1	0.06?
II	0.03?	V2	0.06?
III	-0.01?	V3	0.15?
aVR	-0.04?	V4	0.04?
aVL	0.03?	V5	0.04?
aVF	0.01?	V6	0.04?



ARI CAHYADI
Patient ID: 01.00079742
10.06.2022
9:13:45

LINKED MEDIANS

MEDIKA PLAZA

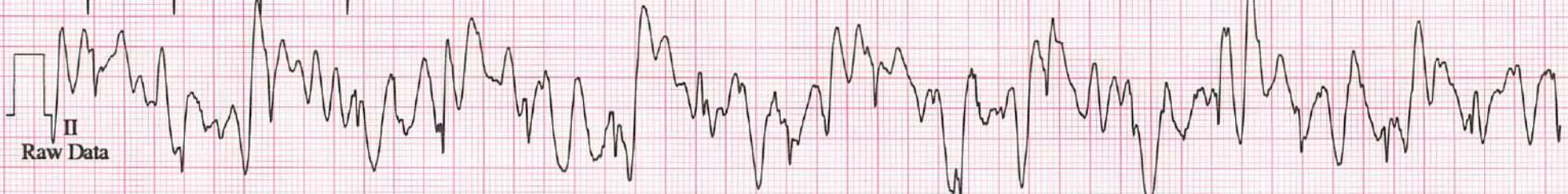
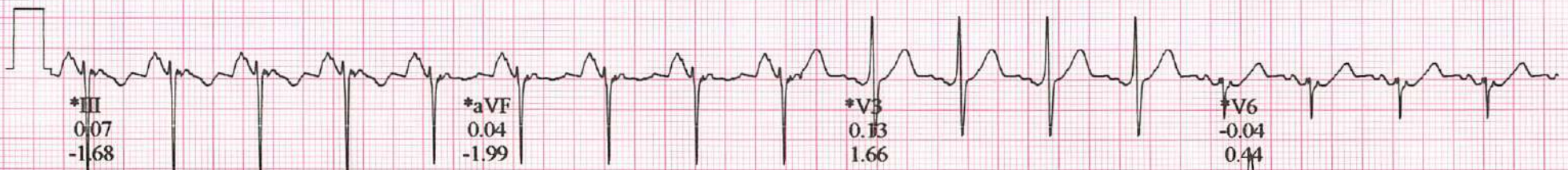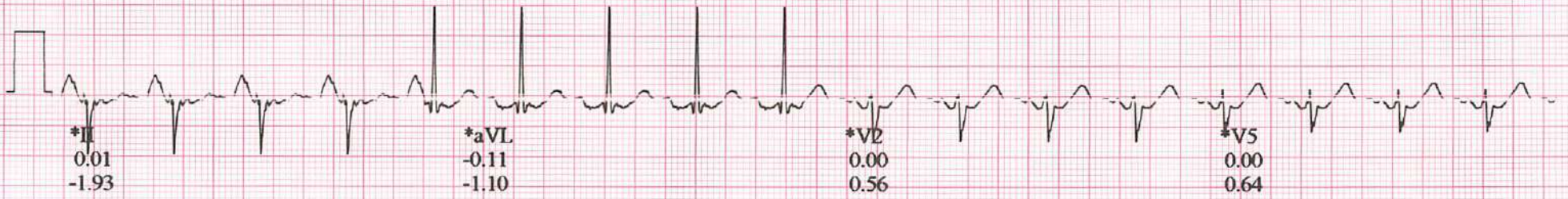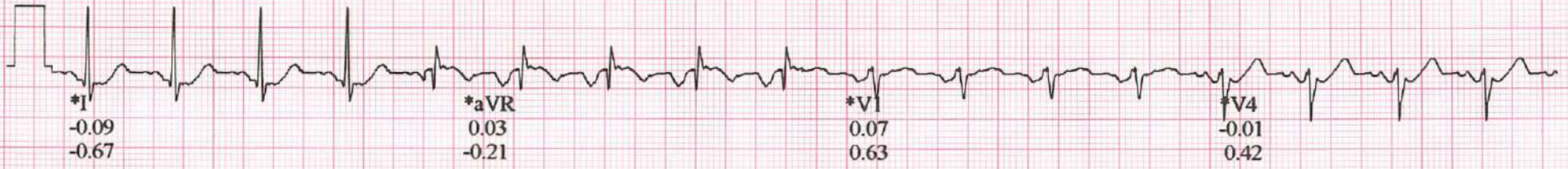103 bpm
120/80 mmHg

EXERCISE
STAGE 1
02:50

BRUCE
2.7 km/h
10.0 %

Lead
ST Level (mV)
ST Slope (mV/s)

60 ms post J



*Computer Synthesized Rhythms

ARI CAITYADI
Patient ID: 01.00079742
10.06.2022
9:16:45

LINKED MEDIANS

MEDIKA PLAZA

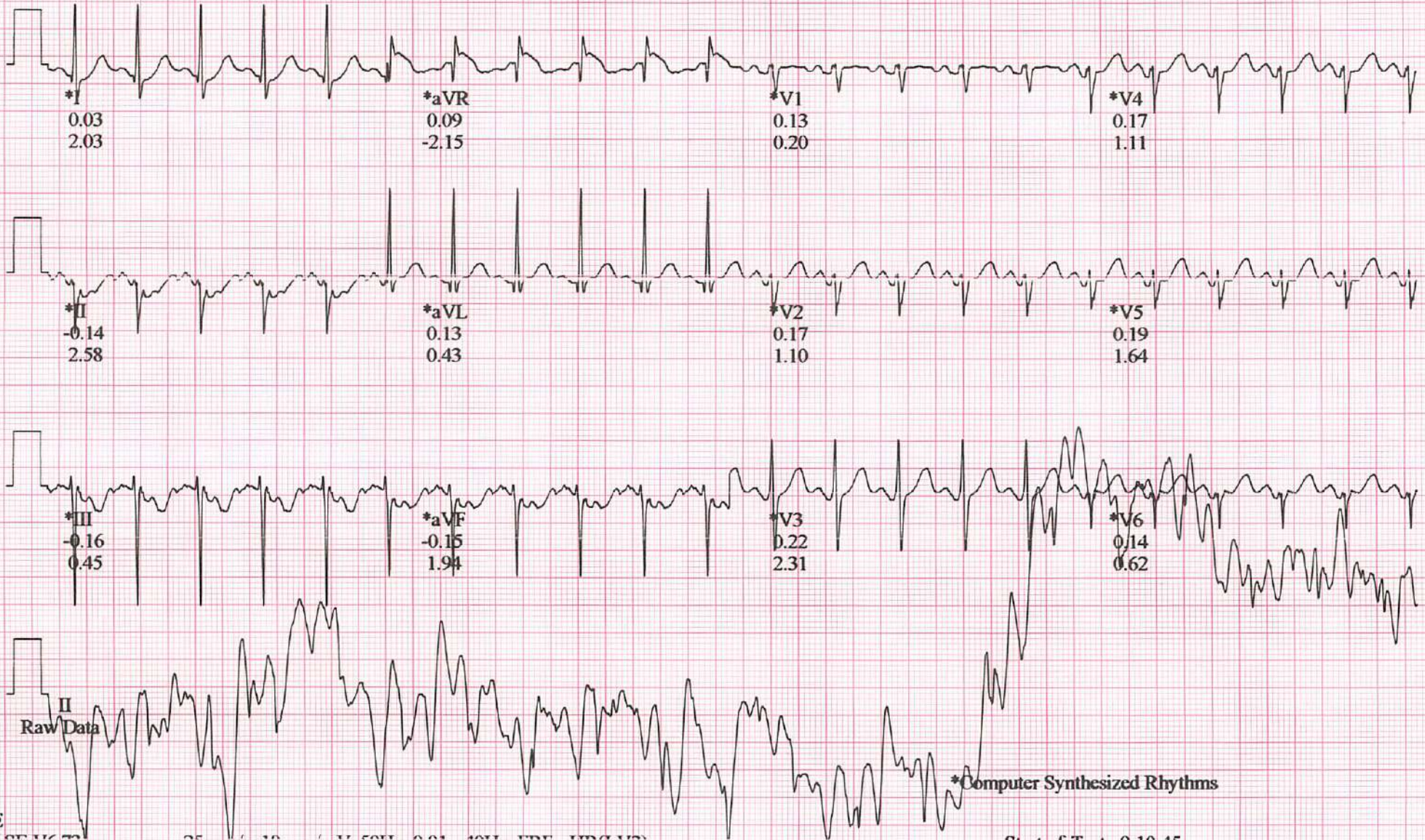
129 bpm

EXERCISE
STAGE 2
05:50

BRUCE
4.0 km/h
12.0%

Lead
ST Level (mV)
ST Slope (mV/s)

60 ms post J



ARI CAITYADI
 Patient ID: 01.00079742
 10.06.2022
 9:20:27

LINKED MEDIANS (PEAK EXERCISE)

EXERCISE
 STAGE 4
 09:32

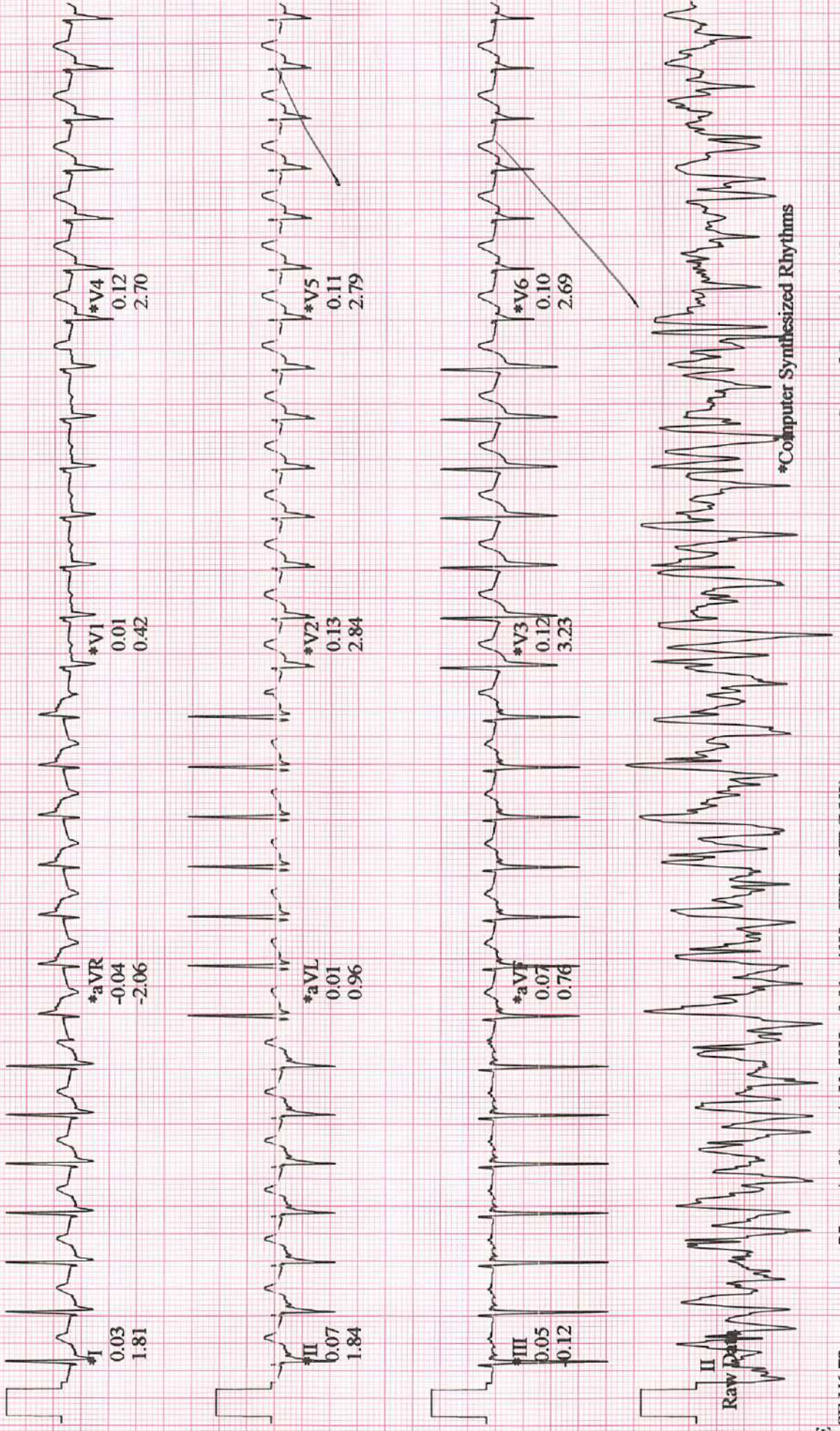
166 bpm

BRUCE
 6.7 km/h
 16.0 %

MPTDKA PT A7A

Lead
 ST Level (mV)
 ST Slope (mV/s)

60 ms post J



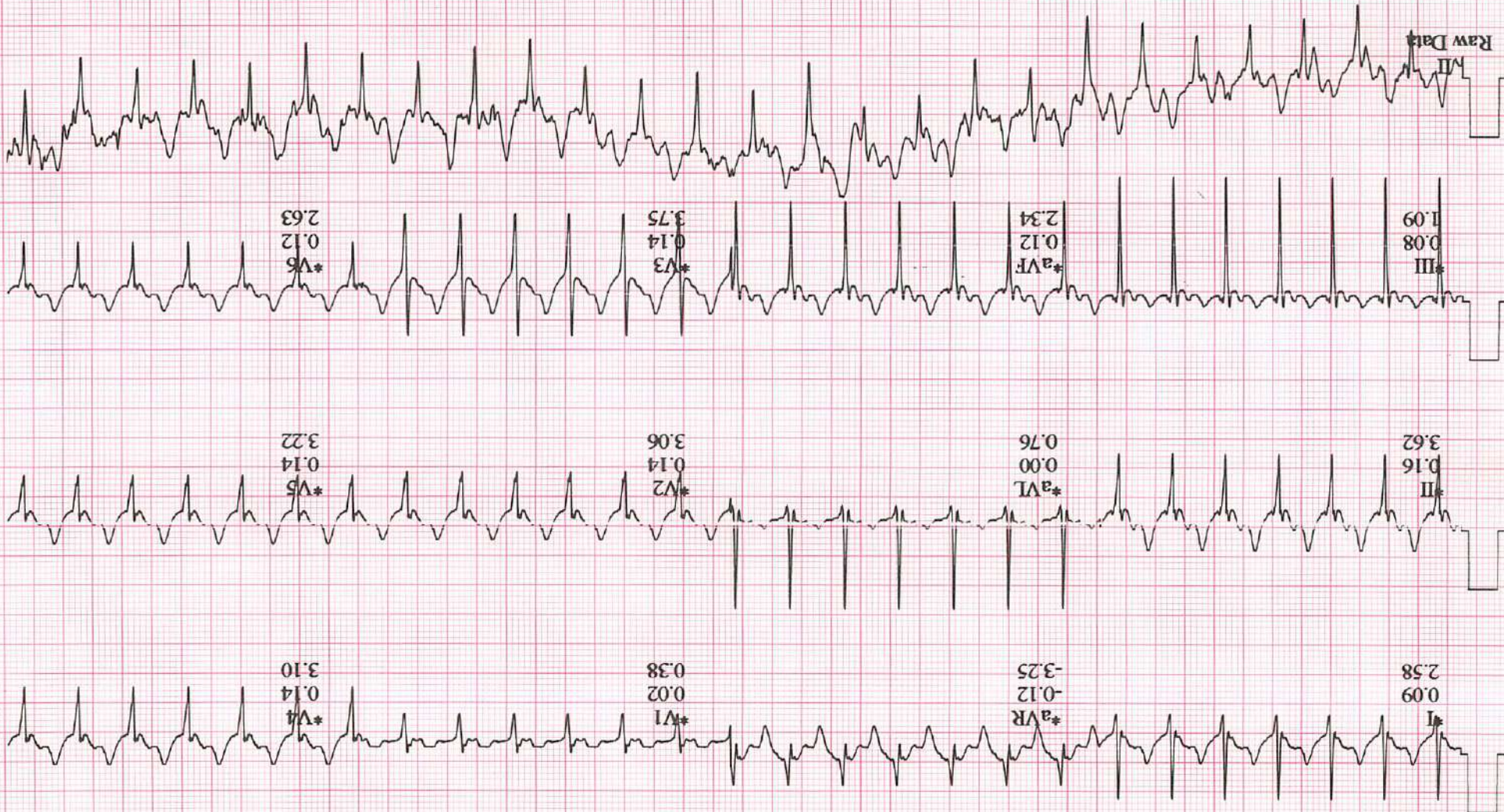
162 bpm

RECOVERY
 Recovery1
 00:20

BRUCE
 2.4 km/h
 0.0%

MPDKA P1 A7A

60 ms post J



*Computer Synthesized Rhythms

Tabular Summary

ARI CAHYADI,

Patient ID: 01.00079742

10.06.2022 Male 163 cm 86.4 kg

9:10:45 40yrs Asian

Meds:

Test Reason:

Medical History:

Ref. MD: Ordering MD:

Technician: JENI Test Type:

Comment:

BRUCE: Total Exercise Time 09:32

Max HR: 169 bpm 93% of max predicted 180 bpm HR at rest: 88

Max BP: 120/80 mmHg BP at rest: 120/80 Max RPP: 17520 mmHg*bpm

Maximum Workload: 11.80 METS

Max. ST: -0.17 mV, 0.00 mV/s in III; EXERCISE STAGE 2 -05:59

Arrhythmia: A:10, PVC:1, PSVC:3


HR reserve used: 85 %

Freq.VE recovery: 0 VE/min

QRS duration: BASELINE: 94 ms, PEAK EX: 86 ms, REC: 84 ms

Location Number: * 0 *

Phase Name	Stage Name	Time in Stage	Speed (km/h)	Grade (%)	Workload (METS)	HR (bpm)	BP (mmHg)	RPP (mmHg*bpm)	VE (/min)	ST Level (III mV)	Comment
PRETEST	SUPINE	00:05	0.00	0.00	1.0	95			0	--	
	STANDING	00:06	0.00	0.00	1.0	85	120/80	10200	0	-0.03	
EXERCISE	STAGE 1	03:00	2.80	10.00	4.7	107	120/80	12840	0	0.04	
	STAGE 2	03:00	4.00	12.00	7.0	126			1	-0.17	
	STAGE 3	03:00	5.50	14.00	10.2	155	120/80	18600	0	0.07	
	STAGE 4	00:32	6.70	16.00	11.8	166			0	0.05	
RECOVERY	Recovery1	00:31	2.10	0.00	6.8	157			0	0.07	

[Handwritten Signature]

[Handwritten Signature]

Tanggal Kunjungan : 10/06/2022

No. Registrasi : 20220610-137410

Rekam Medis : 01.00079742

Nama : ARI CAHYADI

Jenis Kelamin : Male

Tanggal Lahir : 09 April 1982

S : MCU

O :

18	17	16	15	14	13	12	11	21	22	23	24	25	26	27	28
R				R										R	

	D/HP	X											X		R
48	47	46	45	44	43	42	41	31	32	33	34	35	36	37	38

A : CALCULUS+2

18,14,27,38=RADIX

47=CARIES

36,46=MISSING

P : PRO SCALLING

18,14,27,38=PRO EKSTRAKSI

47=PRO FILLING

36,46=PRO GTS

Diperiksa Oleh,

 PT. KARTIKA BINA MEDIKATAMA
Dokter
Ilona Amalia

NAMA PASIEN : Ari Cahyadi
No. RM : 01.00079742
Klinik/MCU/HCU : co. E.N.T.

Yth. Ts. Dokter :
(Konsulen)

Mohon konsul Pasien yang kami rawat
dengan,

Diagnosis Kerja :
Ikhtisar Klinik :

Konsul yang diminta :

PENDAPAT KONSULEN

Penemuan :

Audiometri:

Diagnosis :

Nasehat/Anjuran :

- Stop smoking

- Use ear protection

When working in noisy area

- Avoid eating fast food

& drinking drink to much

Eaz : Tympanic intact sign, cerumen on dex.

Waze : can't euhpy, no secretion.

Abat : T3 T2 pharynx granular

Hardness: Heavy conductive with mild loss.

Deaf on 6000 Hz left ear

Chronic tonsillitis

Tanggal : 10 Juni 2022

Jam :

Dokter :

Tanda tangan

DR. MERISTIANA CHRISTIANE, Sp.THT-KL

0111-42001256/37001117-7779:376/2018

KARTIKA BINA MEDIKATAMA

Nama Jelas

No. Formulir : FM - DR - 008 - 02

No. Revisi : 00

Tanggal Terbit : 07 Juli 2017