

Certificate Of Health Assessment

Name	Age	Position	Department
ARI CAHYADI	38 yo	ASST. INSPECTOR	-

COMPANY :

INSPEKTINDO SINERGI PERSADA, PT

CONCLUSION

FIT TO WORK	
FIT WITH MEDICAL NOTE	✓
TEMPORARY UNFIT	
UNFIT	

Issued Date	Doctors Name	Prepared By
18 September 2020	Rezkha Amalia, MD PKTK : KEP.476/BINWASK3-PNK3/KK/XII/2018 SIP : 54/B.15a/31.74.04.1004/-1.779.3/e/2018	
Expired Date		Verified By
18 September 2021	dr. Muhammad Ilyas, Sp.Ok SIP : 29/B.15b/31.74.04.1004.02.009.K.1/3/-1.779.3/e/2019	 PT. KARTIKA BINA MEDIKATAMA

No. Formulir : FM-DR-008-05
 No. Revisi : 00
 Tanggal Terbit : 2 Mei 2011

Certificate Number : MP-BOP/1-20200918/125469
 MCU Validity Check
<https://mcu-validasi.medikapla.com>

PT. KARTIKA BINA MEDIKATAMA

TO WHOM IT MAY CONCERN

Kepada yang berkepentingan

This is certify that today Friday, 18 September 2020 Medika Plaza Clinic has performed urine drug screening and/or breath alcohol test to :

Dengan ini menyatakan bahwa, pada hari ini Jumat, 18 September 2020 Medika Plaza Clinic telah melakukan urine drug screening dan/atau breath alcohol test kepada :

ARI CAHYADI

With the results are as follows :
Dengan hasil sebagai berikut :

<u>Drugs Test</u> <i>Uji Obat</i>	<u>Result</u> <i>Hasil</i>		
URINE DRUGS SCREENING			
- Amphetamine	<input type="checkbox"/> Non-Negative	<input checked="" type="checkbox"/> Negative	<input type="checkbox"/> N/A
- Met-Amphetamine	<input type="checkbox"/> Non-Negative	<input checked="" type="checkbox"/> Negative	<input type="checkbox"/> N/A
- Cocain	<input type="checkbox"/> Non-Negative	<input checked="" type="checkbox"/> Negative	<input type="checkbox"/> N/A
- THC/Canabis/Marijuana	<input type="checkbox"/> Non-Negative	<input checked="" type="checkbox"/> Negative	<input type="checkbox"/> N/A
- Morphine/Opiates	<input type="checkbox"/> Non-Negative	<input checked="" type="checkbox"/> Negative	<input type="checkbox"/> N/A
- P C P/Phencyclidine	<input type="checkbox"/> Non-Negative	<input checked="" type="checkbox"/> Negative	<input type="checkbox"/> N/A
- Barbiturate	<input type="checkbox"/> Non-Negative	<input type="checkbox"/> Negative	<input checked="" type="checkbox"/> N/A
- Benzodiazepin	<input type="checkbox"/> Non-Negative	<input checked="" type="checkbox"/> Negative	<input type="checkbox"/> N/A
- Methadone	<input type="checkbox"/> Non-Negative	<input checked="" type="checkbox"/> Negative	<input type="checkbox"/> N/A
- Propoxyphene	<input type="checkbox"/> Non-Negative	<input type="checkbox"/> Negative	<input checked="" type="checkbox"/> N/A
- Oxycodone	<input type="checkbox"/> Non-Negative	<input type="checkbox"/> Negative	<input checked="" type="checkbox"/> N/A
- MDMA	<input type="checkbox"/> Non-Negative	<input type="checkbox"/> Negative	<input checked="" type="checkbox"/> N/A
- 6-MAM	<input type="checkbox"/> Non-Negative	<input type="checkbox"/> Negative	<input checked="" type="checkbox"/> N/A
BREATH ALCOHOL TEST			
- Alcohol	<input type="checkbox"/> Non-Negative	<input checked="" type="checkbox"/> Negative	<input type="checkbox"/> N/A

Jakarta, September 18, 2020



(dr. Dian Wahyu Tanjungsari, Sp.PK)

Clinical Patologist

HEALTH ASSESSMENT REPORT

Of

ARI CAHYADI

01.00079742

Friday, 18 September 2020

MP BELTWAY CLINIC

Beltway Office Park, Annex Building, Ground Floor

Jl. TB. Simatupang Kav.41, Jakarta Selatan 12550

Tlp :(62-21) 808 66 099, Fax :(62-21) 808 66 098

www.medikaplaza.com

MP BELTWAY CLINIC

Beltway Office Park, Annex Building, Ground Floor
Jl. TB. Simatupang Kav.41, Jakarta Selatan 12550
Tlp : (62-21) 808 66 099, Fax : (62-21) 808 66 098
www.medikapla.com

PATIENT DATA

MedRec. : 01.00079742	EMPLOY. STATUS : Employee
NAME : ARI CAHYADI	BIRTHDATE : 09 April 1982
EMPLOYEE No. : -	SEX : Male
JOB TITLE : ASST. INSPECTOR	STATUS :
COMP. NAME : INSPEKTINDO SINERGI PERSADA, PT	NASIONALITY : INDONESIA

SUMMARY

MEDICAL FINDING :

1. Dyslipidemia
2. Increase fasting blood sugar
3. Non reactive Anti HBs
4. Obesity
5. Cerumen obturans on right ear
6. Calculus, radix, missing, gangrene pulpa, and decayed teeth
7. Decreasing of visual acuity of both eyes
8. Partial colour blindness
9. USG Abdomen: Mild fatty liver
10. Moderate conductive hearing loss of right ear, and Decreasing of hearing acuity on low and high frequency of left ear


Your fitness status is fit with medical note:

1. Dyslipidemia
2. Gangrene pulpa
3. Decreasing of visual acuity of both eyes
4. Moderate conductive hearing loss of right ear

SUGGESTION :

1. Low fat and carbohydrate diet and exercise regularly minimal 3 times a week. Consultation with an Internist for further evaluation of dyslipidemia
2. Low sugar diet and repeat blood glucose examination 1 month later. Consultation with an Internist if blood glucose still increase
3. Need to get Hepatitis B vaccination (booster)
4. Reduce body weight gradually 0.5 Kgs/week, by doing regular exercise (aerobic/jogging), 3-4x/week, 30-45 minutes and reduce high calorie diet until maximal body weight is 68.06 Kgs (present body weight is 86.9 Kgs). Consultation with a Nutritionist for evaluation of obesity
5. Consultation with an ENT specialist for cerumen extraction
6. Consultation with a Dentist for dental care, minimal once a year or better once in six month. Consultation with a Dentist for further evaluation of Gangrene pulpa
7. You need to wear the glasses for distant vision and consultation with an Ophthalmologist for further evaluation of decreasing of visual acuity of both eyes
8. Avoid working which need an accurate colour differentiation
9. Low fat diet and exercise regularly minimum 3x/week. Repeat abdominal USG 6 months later and consultation with an Internist to evaluate mild fatty liver
10. Avoid noisy environment or use earplug properly while working at noisy work environment to prevent further hearing impairment. Consultation with an ENT Specialist for further evaluation and examination of moderate conductive hearing loss of right ear

Responsible Doctor



Rezkha Amalia, MD

Notes:

If you need the further information or consultation, please contact us via :

Email : - beltway.doctor@medikapla.com

PRIVATE

Printed by : revst

- beltway.doctor2@medikaplaza.com
Telepon Klinik : (62-21) 8086 6000

CLINICAL EVALUATION

Name : ARI CAHYADI	Sex : Male	MR : 01.00079742	Visit : 18/09/2020
Comp.: INSPEKTINDO SINERGI PERSADA, PT		DOB : 09 April 1982	

EXAMINATION	RESULT	NOTES
-------------	--------	-------

ANAMNESA

PRESENT COMPLAINT AND HISTORY OF PRESENT

ILLNESS

Present complaint

No complaint

MEDICAL HISTORY

Allergy

No

Imunisasi

No

Surgery

No

Hospitalization

No

Disease

Yes

Partial color blindness

LIFE STYLE

Alcohol intake

No

Smoking

Yes

Mild smoker

Exercise

Yes

Jogging 1x/ week

FAMILY MEDICAL HISTORY

Diabetes Melitus

No

Hypertension

No

Heart disease

No

Lung TB

No

Kidney disease

No

Astma

Yes

Sister

Mental disease

No

Epilepsy

No

Cancer

No

Color blind

No

Stroke

No

Liver disease

No

Bone & joint

No

Others disease

No

WORK EXPOSURE

Noise

Yes

Genset machine, only using ear plugg, 2x/ weel offshore: everyday, 3 hours/ day, including break every 1 hour, break every 30 minutes

Heat Stress

Yes

Sun, 1-2 hours/ day

Cold Stress

No

Vibration

No

Involving height

Yes

2 meters, 1-3x/ week, body harness (+)

CLINICAL EVALUATION

Name : ARI CAHYADI	Sex : Male	MR : 01.00079742	Visit : 18/09/2020
Comp.: INSPEKTINDO SINERGI PERSADA, PT		DOB : 09 April 1982	

EXAMINATION	RESULT	NOTES
Radiation	Yes	Sun
Dust	Yes	Paint dust, respirator (+), 2x/ week (but now, rarely)
Toxic chemical	Yes	Pylox
Irritating fluid	No	
Smoke	No	
Bacterium/Virus/Parasite	No	
Blood	No	
Animal	No	
Operating heavy mobile equipment	No	
Manual Handling	Yes	Tool box, 12 kg, pulling box with wheels
Sitting continuously over 4 hours	No	
Stand continuously over 4 hours	No	
Using monitor screen more than 4 hours per day	No	
Exposure	No	
Unergonomic body positions	No	
Shift work	No	
Work is not accordance with skills and knowledge	No	
Workload does not accordance with time	No	
Work conflict	No	
Inappropriate task	No	
Career barriers	No	
Family conflict	No	
Working around rotating machinery	Yes	Crane, and forklift
Administration work	No	
Handling food product	No	
Others	Yes	Field, inspection lifting gear
PHYSICAL EXAMINATION		
General Appearance	Good	
Body shape	Picnicus	
VITAL SIGN		
Body Weight	86.9 Kg	
Body Height	165 Cm	
BMI	31.91 Kg/m ²	
Normal Weight	50.37 - 68.06 Kg	
BMI Conclusion	Obesity	
Blood Pressure	120/80 mmHg	

CLINICAL EVALUATION

Name : ARI CAHYADI	Sex : Male	MR : 01.00079742	Visit : 18/09/2020
Comp.: INSPEKTINDO SINERGI PERSADA, PT		DOB : 09 April 1982	

EXAMINATION	RESULT	NOTES
Pulse	71 x/minute	
Body Temperature	36 °C	
RR	20	
Neck Circumference	40 Cm	
Arm Circumference	34 Cm	
Chest size	95 Cm	
Abdominal Circumference	87 Cm	
SKIN		
Skin	Normal	
EYE		
Left	Normal	
Right	Normal	
ENT		
Auricle	Normal	
Ear canal	Abnormal	Cerumen obturans on right ear
Drums	Abnormal	Right ear drum cannot be seen
Septum/Conchae	Normal	
Sinuses	Normal	
Pharynx	Normal	
Tonsil	Normal	
MOUTH		
Gum	Normal	
Dental	Abnormal	Calculus, radix, missing, gangrene pulpa, and decayed teeth
NECK		
General	Normal	
Thyroid Gland	Normal	
CHEST		
Form	Normal	
Lung	Normal	
Heart	Normal	
Breast	Normal	
ABDOMEN		
Form	Flat	
Palpation	Supple	
Liver	Not Palpable	
Spleen	Not Palpable	

CLINICAL EVALUATION

Name : ARI CAHYADI

Sex : Male

MR : 01.00079742

Visit : 18/09/2020

Comp.: INSPEKTINDO SINERGI PERSADA, PT

DOB : 09 April 1982

EXAMINATION	RESULT	NOTES
Kidney	No Ballotment	
-	No	
Hernia inguinal	No	
EXTRIMITIES		
Bones,joint	Normal	
Muscles,tonus	Normal	
Fingernails	Normal	
Hand	Normal	
Foot	Normal	
RECTAL EXAMINATION		
Hemorrhoid	Negative	
Rectum	Normal	
SENSORIK EXAMINATION		
Tes Raba	Normal	
MOTORIK EXAMINATION		
Tes Grip	Normal	
REFLEX EXAMINATION		
Physiologic reflex	Normal	
Patologic reflex	Normal	
OTHERS EXAMINATION		
Coordination	Normal	
LYMPHE SYSTEM		
Submandibula	Normal	
Neck Gland	Normal	
Armpit gland	Normal	
Inguinal	Normal	

OPHTHALMOLOGY DIAGNOSTIC

Name : ARI CAHYADI	Sex : Male	MR : 01.00079742	Visit : 18/09/2020
Comp.: INSPEKTINDO SINERGI PERSADA, PT		DOB : 09 April 1982	

EXAMINATION		Right	Left
Reading		-	
Previous Glasses		-	-
Without Glasses	Distant	20/50	20/50
	Near	J1	J1
Correction	Distant	S-1.00 C-0.50X90 20/20	S-1.00 C-0.50X90 20/20
	Near	-	-
Depth Perception		-	
Tonometry		16.0 mmHg	16.0 mmHg
Funduscopy		NORMAL	NORMAL
Visual Fields		Normal	
Colour Blind Test		Partial Colour Blindness	

Impression : Astigmatismus myopicus kompositus ODS

RADIOLOGY DIAGNOSTIC

Name : ARI CAHYADI

Sex : Male

MR : 01.00079742

Visit : 18/09/2020

Comp.: INSPEKTINDO SINERGI PERSADA, PT

DOB : 09 April 1982

EXAMINATION

RESULT

THORAX PA

No abnormality seen in both lungs.
Normal bronchovascular markings in both hili.
The heart is normal in size and shape.
The mediastinum is not widened.
Both sinus and diaphragms are good.
No evidence of pleural effusion.

Impression

Normal heart and lungs

RADIOLOGY DIAGNOSTIC

Name : ARI CAHYADI

Sex : Male

MR : 01.00079742

Visit : 18/09/2020

Comp.: INSPEKTINDO SINERGI PERSADA, PT

DOB : 09 April 1982

EXAMINATION

RESULT

USG ABDOMEN

LIVER:

Normal in size and contour, smooth surface, echoes structure parenchyme which are slight homogenous increase. No sign of SOL.

Intrahepatic vascularity and billiary tract are normal.

GALL BLADDER:

Normal in size, contour and surface. No sign of SOL/ sludge/ stone.

RIGHT KIDNEY :

Normal in size, contour and surface. No sign of obstruction/ stone/ SOL.

LEFT KIDNEY:

Normal in size, contour and surface. No sign of obstruction/ stone/ SOL.

PANCREAS:

Normal in size, contour and surface. No sign of SOL.

LIEN:

Normal in size and contour, the echoes are homogenous. No sign of SOL.

URINARY BLADDER:

Normal in contour and surface. No sign of stone/ SOL.

PROSTATE AND VESICULA SEMINALIS:

Normal in size and contour which are homogenous echoes and no sign of focal lesion/ SOL.

Impression

Mild fatty liver

Other intra abdominal organs are normal

LABORATORY RESULT

Name : ARI CAHYADI	MR : 01.00079742	Visit : 18/09/2020	#Lab : IN71702833446
Comp.: INSPEKTINDO SINERGI PERSADA, PT	Sex : Male	DOB : 09 April 1982	

EXAMINATION	RESULT	NORMAL RANGE
-------------	--------	--------------

HEMATOLOGI

ABO/Rh Typing "O" Rh(+) positive

Automated Blood Count

White Blood Cell (WBC)	9.2	3.8 - 11.0
Erythrocyte (RBC)	5.7	4.4 - 5.9
Haemoglobin	17.6 *	13.2 - 17.3
Hematocrit	48	40 - 52
Thrombocytes	305	150 - 440

MCV, MCH, MCHC

MCV	85	80 - 100
MCH	31	26 - 34
MCHC	36.4 *	32 - 36
ESR	11 *	0 - 10

Differential Count

Basophils	0	0 - 1
Eosinophil	2	2 - 4
Bands / Stab	3	3 - 5
Neutrophils	60	50 - 70
Lymphocytes	27	25 - 40
Monocytes	8	2 - 8

BLD CHEMISTRY/LIPID PROFILE

Total Cholesterol	207 *	Normal/Desireable: <200 Borderline High: 200-239 High: >=240
HDL Cholesterol	52.5	Normal : >40 - <60 Low HDL : <40 Desireable : >=60
LDL Cholesterol	110	Optimal: <100 Near/Above Optimal: 100-129 Borderline High: 130-159 High: 160-189 Very High: >=190
Triglycerides	222 *	Normal : <150 Borderline High: 150-199 High : 200-499 Very High : >=500

BLD CHEMISTRY/KIDNEY FUNCTION

LABORATORY RESULT

Name : ARI CAHYADI	MR : 01.00079742	Visit : 18/09/2020	#Lab : IN71702833446
Comp. : INSPEKTINDO SINERGI PERSADA, PT	Sex : Male	DOB : 09 April 1982	

EXAMINATION	RESULT	NORMAL RANGE
Ureum	33.5	10.0 - 50.0
Creatinine	1.2	0.6- 1.3
Uric Acid	5.20	3.50 - 7.20

BLD CHEMISTRY/LIVER FUNCTION

Total Bilirubin	0.70	0.1 - 1.0
Direct Bilirubin	0.19	0.0 - 0.2
Indirect Bilirubin	0.51	0.0 - 0.8
SGOT(AST)	26	13 - 45
SGPT (ALT)	23	13 - 50
Alkaline Phosphatase	81	30 - 120
Gamma GT	40	0 - 50
Albumin	5.2	3.5 - 5.5
Globulin	3.40	2.3 - 3.5
Total Protein	8.6	6.6 - 8.7

BLD CHEMISTRY/DIABETES

Glucose Fasting	105 *	< 100
Glucose Urine	Negative	Negative
Keton Urine	Negative	Negative

Blood Glucose 2 PP

Blood Sugar 2 Hours PP	110	< 140
Glucose Urine	Negative	Negative
Keton Urine	Negative	Negative

SEROLOGI / IMUNOLOGI

HBsAg (Quantitative)	0.00	0.00 - 0.03
Anti Hbs (Quantitative)	0.2 *	>= 5.0

TOXICOLOGY - DRUGS SCREENING

Methadone	Negative	Negative
Phencyclidine	Negative	Negative
THC/Marijuana	Negative	Negative
Amphetamine	Negative	Negative
Benzodiazepines	Negative	Negative
Opiat	Negative	Negative
Cocain	Negative	Negative
Metamphetamine	Negative	Negative
Alcohol	Negative	Negative

URINALYSIS**Complete Urine Analysis**

LABORATORY RESULT

Name : ARI CAHYADI	MR : 01.00079742	Visit : 18/09/2020	#Lab : IN71702833446
Comp. : INSPEKTINDO SINERGI PERSADA, PT	Sex : Male	DOB : 09 April 1982	

EXAMINATION	RESULT	NORMAL RANGE
-------------	--------	--------------

Macroscopic

Color	Yellow	
Turbidity	Clear	Clear
Specific Gravity	1.026	1.000 - 1.030
pH	5.5	4.5 - 8.0
Leucocyte	Negative	Negative
Glucose	Negative	Negative
Nitrit	Negative	Negative
Bilirubin	Negative	Negative
Blood	Negative	Negative
Urobilinogen	Normal	Normal
Protein	Negative	Negative
Keton	Negative	Negative

Microscopic

RBC	0-1	0 - 1
WBC	0-1	0 - 4
Cylinder	Negative	
Epithels Squamous	0-1	5 - 15
Crystals	Negative	
Bacteria	Negative	Negative
Others	Negative	

STOOL / RECTAL SWAP

Faeces Complete

Macroscopic

Color	Brown	
Consistency	Smooth	
Mucus	Negative	Negative
Blood	Negative	Negative
Pus	Negative	Negative
Parasit	Negative	Negative
Lipid	Negative	Negative

Microscopic

RBC	0-1	0 - 1
WBC	0-1	0 - 5
Amoeba	Negative	
Ephitels	Positive	Positive
Worm Eggs	Negative	Negative

LABORATORY RESULT

Name : ARI CAHYADI	MR : 01.00079742	Visit : 18/09/2020	#Lab : IN71702833440
Comp. : INSPEKTINDO SINERGI PERSADA, PT	Sex : Male	DOB : 09 April 1982	

EXAMINATION	RESULT	NORMAL RANGE
Yeast	Negative	Negative
Muscle Fiber	Negative	Negative
Others	Negative	Negative
Digestive		
Amylum	Negative	Negative
Fat	Negative	
Fibers	Positive	Positive

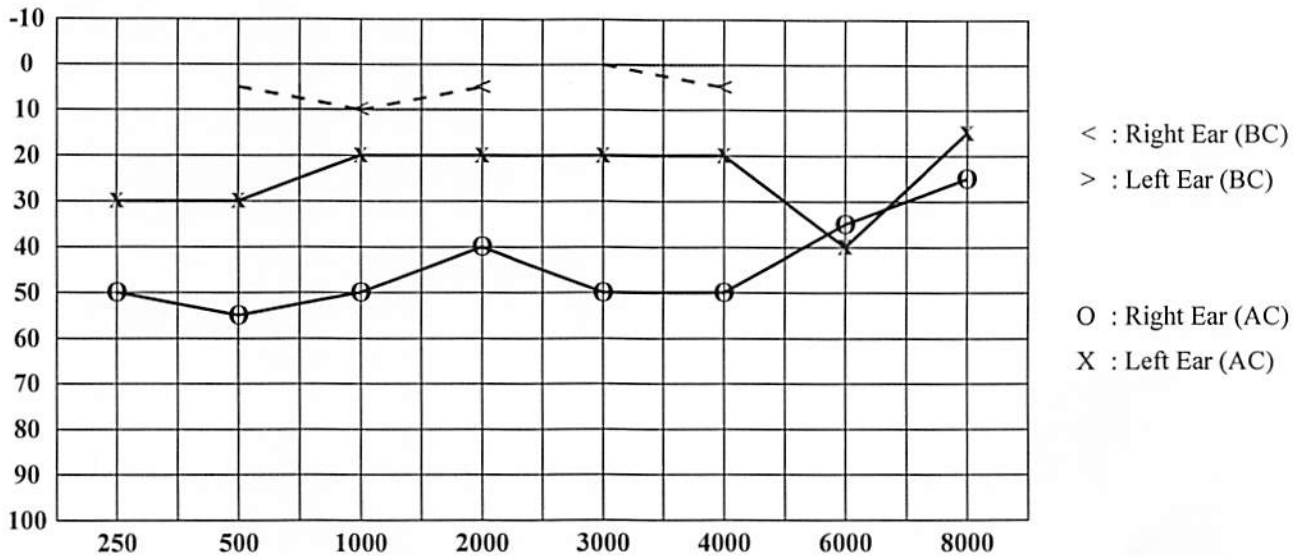
AUDIOMETRY DIAGNOSTIC

Name : ARI CAHYADI	Sex : Male	MR : 01.00079742	Visit : 18/09/2020
Comp.: INSPEKTINDO SINERGI PERSADA, PT		DOB : 09 April 1982	

RESULT

Left Ear	250	500	1000	2000	3000	4000	6000	8000
AC	30	30	20	20	20	20	40	15
BC	-	-	-	-	-	-	-	-

Right Ear	250	500	1000	2000	3000	4000	6000	8000
AC	50	55	50	40	50	50	35	25
BC	-	5	10	5	-	5	-	-



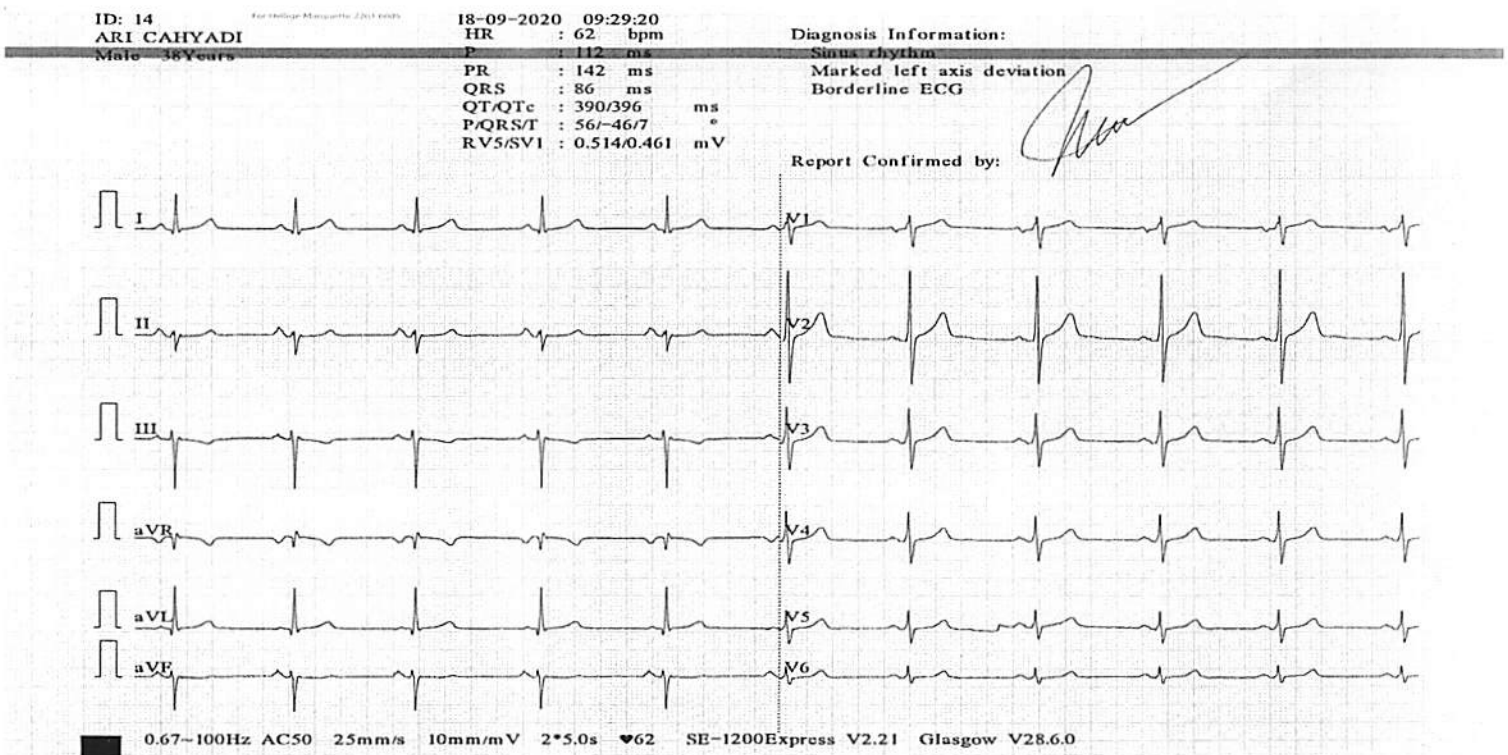
Conclusion Right Ear : Moderate conductive hearing loss = 48.75 dB
 With decreasing on frequency 250Hz, 4000Hz, 6000Hz

Conclusion Left Ear : Hearing threshold = 22.5 dB
 (Within normal limit)
 With decreasing on frequency 250Hz & 6000Hz

CARDIOLOGY DIAGNOSTIC

Name : ARI CAHYADI	Sex : Male	MR : 01.00079742	Visit : 18/09/2020
Comp.: INSPEKTINDO SINERGI PERSADA, PT		DOB : 09 April 1982	

EXAMINATION	RESULT	Comments :
TREADMILL	Sinus Rythm axis (N), P wave (N), PR int 0.16" ST - T segment (N), aritmia (-)	Treadmill Exercise Test : Negative Cardiopulmonary Fitness Classification : Good METs : 13.4
ELECTROCARDIOGRAPHY	Sinus Rythm axis (N), P wave (N), PR int 0.16" ST - T segment (N), aritmia (-)	Normal ECG





ARI CAHYADI, MR

ID: 01.00079742, Born: 4/9/1982 (Male 38), 86 kg, 165 cm
Test Date: 9/18/2020 10:38:39 AM

MEDIKA PLAZA

Patient info

Born: 4/9/1982
Age: 38
Sex: Male
Weight: 86 kg
Height: 165 cm
Smoker:
Pacemaker:

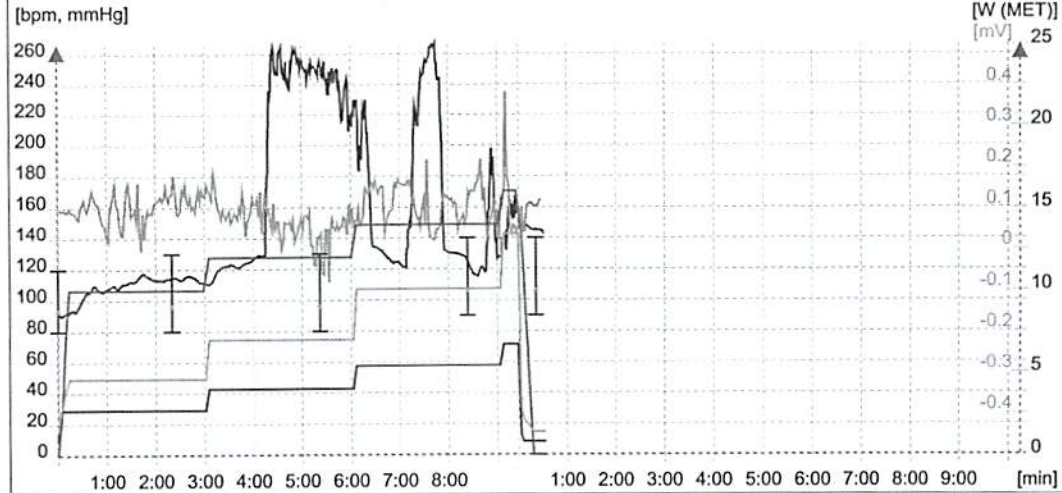
Medical history

Medications

Reason for admission

Reason for Stop

Trends



Conclusion

Agatu
Good
 MP
 MEDIKA PLAZA MEDIKATAMA

Staff

Physician: user
Technician:

Test info

Test date: 9/18/2020
 Test time: 10:38 AM
 Stress device: BTL Treadmill
 Protocol: Bruce
 Total duration: 09:26
 Stress achieved: 6.7km/h, 16.0% (~13.4MET
 111% predicted (~12.3MET sec)
 HR rest: 105
 HR peak: 153 = 85% predicted (181)
 Exercise (13.4MET)
 Handgrip test: --
 BP rest: 120/80
 BP peak: --
 BP recovery: 140/90
 DP rest: 12600
 DP peak: 17647 = 1.4x DP at rest
 ST depression max: aVR -0.35mV 01:36 Exercise
 4.6MET
 ST elevation max: II 0.40mV 01:54 Exercise 4
 ST/HR index: 2.7 µV/bpm (abnormal)




ARI CAHYADI, MR

ID: 01.00079742, Born: 4/9/1982 (Male 38), 86 kg, 165 cm
Test Date: 9/18/2020 10:38:39 AM

MEDIKA PLAZA

Time: P 00:05 - Reference

Load: 1.4MET, HR: 105bpm, BP: 120/80



Filter: 0.07 Spline - 90 Adapt, -50 [Hz]

25.00 mm/sec 10.0 r




ARI CAHYADI, MR

ID: 01.00079742, Born: 4/9/1982 (Male 38), 86 kg, 165 cm
Test Date: 9/18/2020 10:38:39 AM

MEDIKA PLAZA

Time: E 02:56 - E1

Load: 4.6MET, HR: 111bpm, BP: 130/80



Filter: 0.07 Spine - 90 Adapt, -50 [Hz]

25.00 mm/sec 10.0 r

Medika Plaza Clinic

BTL CardioPoint 2.30.33006.0, DIAG: 2.0.2.0; ECG: BTL-08 ECG, SN: 071D-B-05775

BTL CardioPoint - Stress Test



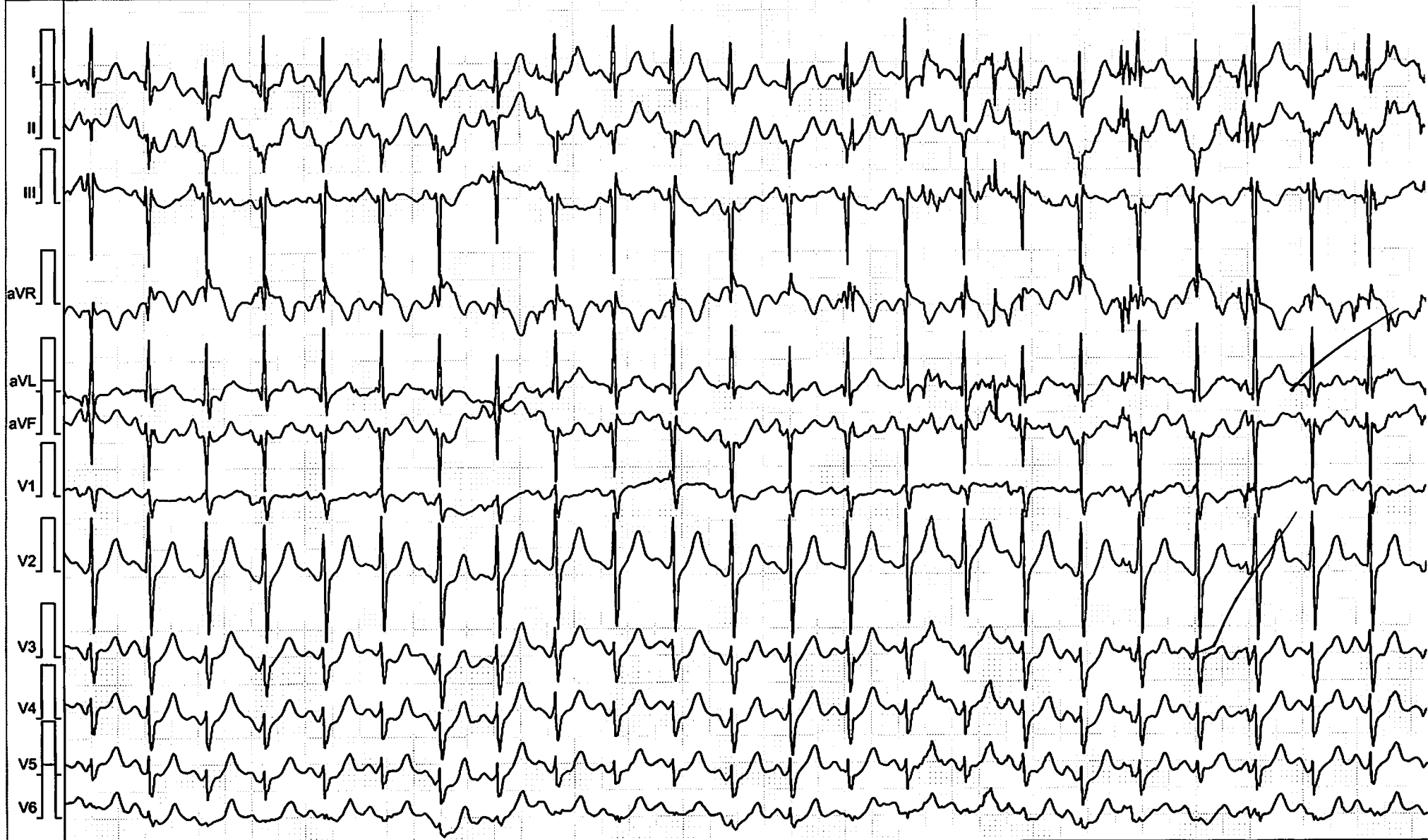ARI CAHYADI, MR

ID: 01.00079742, Born: 4/9/1982 (Male 38), 86 kg, 165 cm
Test Date: 9/18/2020 10:38:39 AM

MEDIKA PLAZA

Time: E 05:58 - E2

Load: 7.0MET, HR: 221bpm, BP: 130/80



Filter: 0.07 Spline - 90 Adapt, -50 [Hz]

25.00 mm/sec 10.0 r



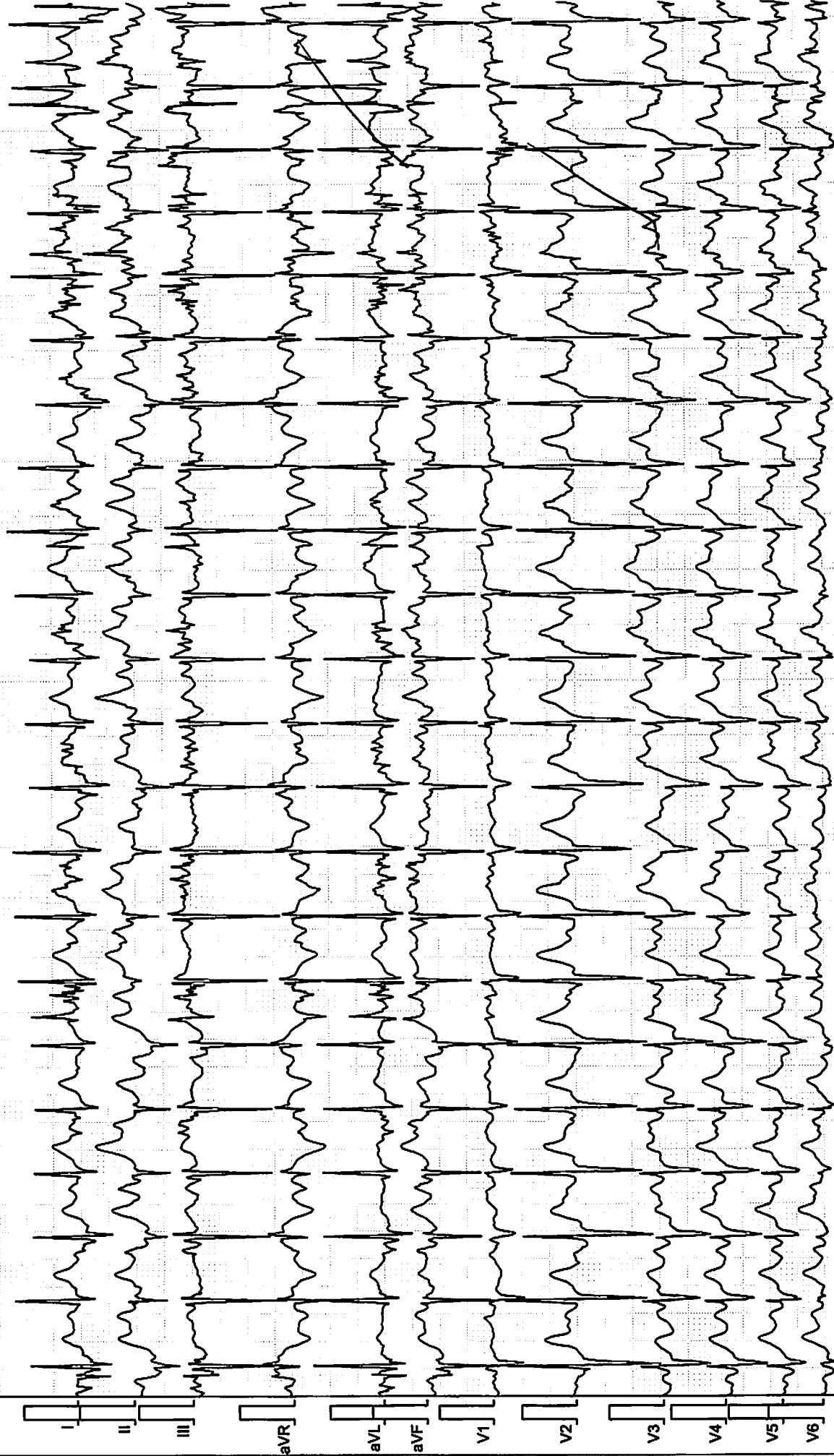
ARI CAHYADI, MR

ID: 01.00079742, Born: 4/9/1982 (Male 38), 86 kg, 165 cm
Test Date: 9/18/2020 10:38:39 AM

MEDIKA PLAZA

Time: E 08:59 - E3

Load: 10.1MET, HR: 128bpm, BP: 140/90



Filter: 0.07 Spline - 90 Adapt, ~50 [Hz]

25.00 mm/sec 10.0 r

Medika Plaza Clinic

BTL CardioPoint 2.30.33006.0, DIAG: 2.0.2.0; ECG: BTL-08 ECG, SN: 071D-B-05775

BTL CardioPoint - Stress Test




ARI CAHYADI, MR

ID: 01.00079742, Born: 4/9/1982 (Male 38), 86 kg, 165 cm
Test Date: 9/18/2020 10:38:39 AM

MEDIKA PLAZA

Time: E 09:21 - Peak

Load: 13.4MET, HR: 159bpm, BP: -



Filter: 0.07 Spline - 90 Adapt, ~50 [Hz]

25.00 mm/sec 10.0 r

Medika Plaza Clinic

BTL CardioPoint 2.30.33006.0, DIAG: 2.0.2.0; ECG: BTL-08 ECG, SN: 071D-B-05775

BTL CardioPoint - Stress Test



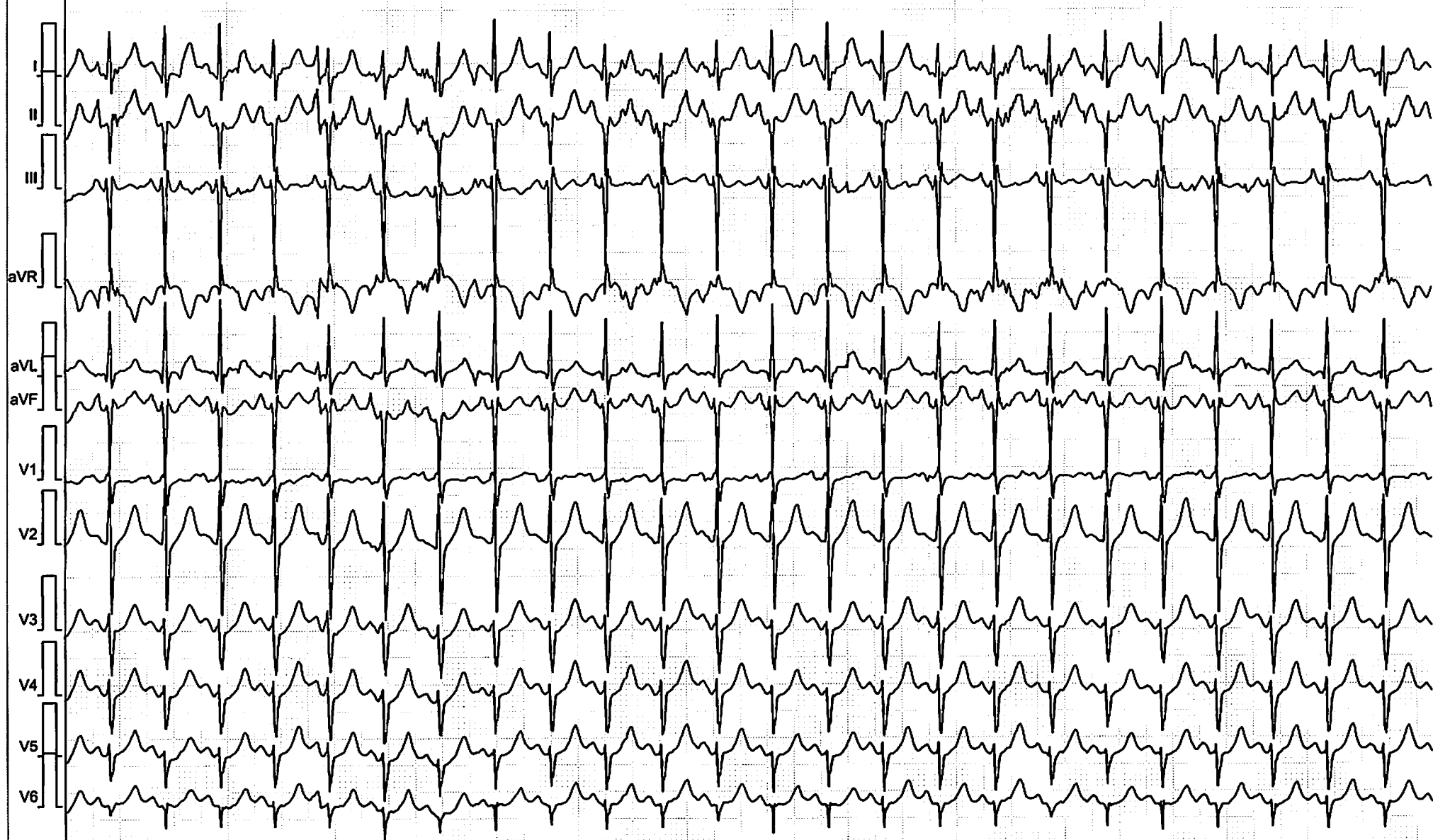
ARI CAHYADI, MR

ID: 01.00079742, Born: 4/9/1982 (Male 38), 86 kg, 165 cm
Test Date: 9/18/2020 10:38:39 AM

MEDIKA PLAZA

Time: R 00:10 - Recovery

Load: 1.5MET, HR: 146bpm, BP: 140/90



Filter: 0.07 Spline - 90 Adapt, ~50 [Hz]

25.00 mm/sec 10.0 r

**ARI CAHYADI, MR**ID: 01.00079742, Born: 4/9/1982 (Male 38), 86 kg, 165 cm
Test Date: 9/18/2020 10:38:39 AM

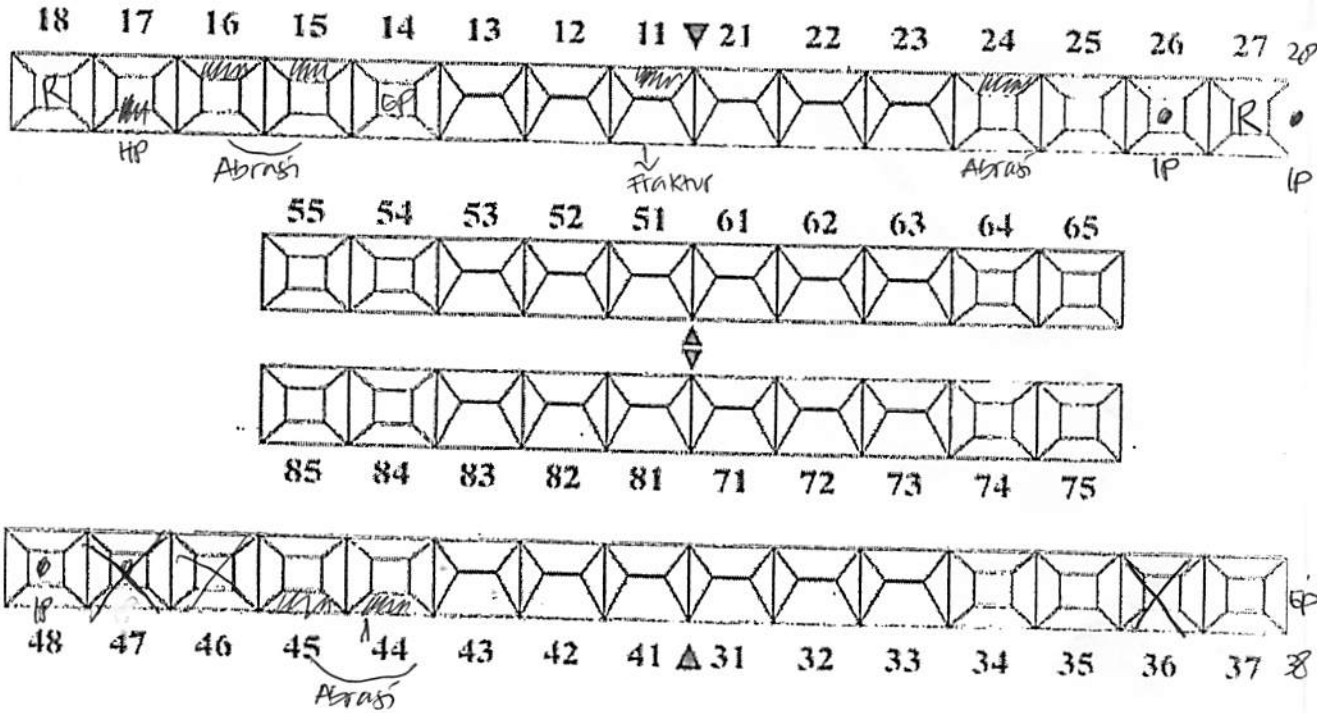
MEDIKA PLAZA

Stage	Time	Load			HR bpm	BP mmHg	SpO2 %	ST Level [mV], J+: 1/8RR										
		km/h	%	MET				I	II	III	aVR	aVL	aVF	V1	V2	V3	V4	V5
Reference	E 00:03	0.8	0.0	1.4	105	120/80	-	0.18	0.10	-0.08	-0.14	0.13	0.01	0.07	0.32	0.15	0.14	0.09
E 1 stage	E 03:01	2.7	10.0	4.6	112	130/80	-	0.08	0.01	-0.07	-0.35	0.09	-0.03	0.04	0.14	0.11	0.08	0.07
E 2 stage	E 06:03	4.0	12.0	7.0	209	130/80	-	0.05	-0.03	0.00	-0.11	0.03	0.03	0.04	0.18	0.13	0.18	0.10
E 3 stage	E 09:04	5.4	14.0	10.1	139	140/90	-	0.15	0.16	0.02	-0.10	0.07	0.09	0.02	0.20	0.18	0.15	0.12
E 4 peak	E 09:26	6.7	16.0	13.4	153	-	-	0.08	-0.05	-0.16	-0.03	0.19	-0.02	0.07	0.22	0.19	0.16	0.06
Recovery	R 00:20	0.8	16.0	2.5	146	140/90	-	0.10	0.12	0.04	-0.11	0.03	0.09	0.01	0.27	0.12	0.13	0.11

DENTAL EXAMINATION

Name: Ari Cahya	Sex: M/F	MR :	Visit 8
Comp.: Inspectindo Sinergi		DOB :	5

ODONTOGRAM



Calculus dan Stain + 2

DIAGNOSA

- | | |
|------------------------|----------------------|
| kalculus + stain Lt II | 28 |
| 17 HP oklusi | 26 IP oklusi |
| 16, 15 abrasi serebr | 27 Radix |
| 14 GP | 35 GP, 48 IP oklusi |
| 11 Fraktur email | 44, 45 abrasi serebr |
| 24, 25 abra | |

TREATMENT PLANNING

- Scaller + Polishing
- 17, 16, 15, 11, 24, 26, 28, 48, 45, 48 Perambatan
- 27, 38 pencabutan
- 14 PSA / pencabutan

Verified by: drg. Ilona Amalia/ drg. Fajar Sulawati/drg. Siti Darjah/drg. Herlina

Datu
drg. Datu Permata

PATIENT NAME : *Tn An Cahyadi*
No. RM :
Klinik/MCU/HCU : *TNT*

To. Dokter :
(Counsel)

Kindly please counsel for patient who has take cares of

Diagnose :
Clinik Summary :

Counsel Request :

COUNSEL ADVISE

Finding :

Diagnosis :

Recommendation :

- tonsilectomy
- ear toilet at ENT EP
- Readvianly after ear toilet
- Uyg ear protection when work in noisy area.

Ear: Cerumen dextra hypome unit 4 evakuasi
Nose: Catuca euhay, nascenta
Throat: T4 T4 pharynx granth
Audimely: Moderate Hany loss. dextra. Sudo
Hany normal sinistra dany on 6000db,

Hyperthyroid, cerumnt dextrum

Date : *18/9/16*

Time :

EP :

Signature



PT. KARTIKA BINA MEDIKATAMA
SIP: 1318.14
Complete Name