

## Certificate Of Health Assessment



Name	Age	Position	Department
AGUS PRIYONO	34 yo	INSPECTOR	INSPECTION

**COMPANY :**

**INSPEKTINDO SINERGI PERSADA, PT**

### CONCLUSION

<b>FIT TO WORK</b>	
<b>FIT WITH MEDICAL NOTE</b>	
<b>TEMPORARY UNFIT</b>	✓
<b>UNFIT</b>	

Issued Date	Doctors Name	Prepared By
<b>27 August 2020</b>	<b>Puteri Melati, MD</b> <small>PKTK : KEP.264/BINWASK3-PNK3/KK/VI/2019            SIP : 23/B.15a/31.74.04.1004/-1.779.3/e/2019</small>	
Expired Date		Verified By
<b>27 August 2021</b>	<b>dr. Muhammad Ilyas, Sp.Ok</b> <small>SIP : 29/B.15b/31.74.04.1004.02.009.K.1/3/-1.779.3/e/2019</small>	<b>PT. KARTIKA BINA MEDIKATAMA</b> 

No. Formulir : FM-DR-008-05  
 No. Revisi : 00  
 Tanggal Terbit : 2 Mei 2011

Certificate Number : **MP-BOP/1-20200827/125000**  
 MCU Validity Check  
<https://mcu-validasi.medikaplaza.com>

**PT. KARTIKA BINA MEDIKATAMA**

## TO WHOM IT MAY CONCERN

### *Kepada yang berkepentingan*

This is certify that today Thursday, 27 August 2020 Medika Plaza Clinic has performed urine drug screening and/or breath alcohol test to :

*Dengan ini menyatakan bahwa, pada hari ini Kamis, 27 Agustus 2020 Medika Plaza Clinic telah melakukan urine drug screening dan/atau breath alcohol test kepada :*

### **AGUS PRIYONO**

With the results are as follows :

*Dengan hasil sebagai berikut :*

Drugs Test <i>Uji Obat</i>	Result <i>Hasil</i>		
<b>URINE DRUGS SCREENING</b>			
- Amphetamine	<input type="checkbox"/> Non-Negative	<input checked="" type="checkbox"/> Negative	<input type="checkbox"/> N/A
- Met-Amphetamine	<input type="checkbox"/> Non-Negative	<input checked="" type="checkbox"/> Negative	<input type="checkbox"/> N/A
- Cocain	<input type="checkbox"/> Non-Negative	<input checked="" type="checkbox"/> Negative	<input type="checkbox"/> N/A
- THC/Canabis/Marijuana	<input type="checkbox"/> Non-Negative	<input checked="" type="checkbox"/> Negative	<input type="checkbox"/> N/A
- Morphine/Opiates	<input type="checkbox"/> Non-Negative	<input checked="" type="checkbox"/> Negative	<input type="checkbox"/> N/A
- P C P/Phencyclidine	<input type="checkbox"/> Non-Negative	<input checked="" type="checkbox"/> Negative	<input type="checkbox"/> N/A
- Barbiturate	<input type="checkbox"/> Non-Negative	<input type="checkbox"/> Negative	<input checked="" type="checkbox"/> N/A
- Benzodiazepin	<input type="checkbox"/> Non-Negative	<input checked="" type="checkbox"/> Negative	<input type="checkbox"/> N/A
- Methadone	<input type="checkbox"/> Non-Negative	<input checked="" type="checkbox"/> Negative	<input type="checkbox"/> N/A
- Propoxyphene	<input type="checkbox"/> Non-Negative	<input type="checkbox"/> Negative	<input checked="" type="checkbox"/> N/A
- Oxycodone	<input type="checkbox"/> Non-Negative	<input type="checkbox"/> Negative	<input checked="" type="checkbox"/> N/A
- MDMA	<input type="checkbox"/> Non-Negative	<input type="checkbox"/> Negative	<input checked="" type="checkbox"/> N/A
- 6-MAM	<input type="checkbox"/> Non-Negative	<input type="checkbox"/> Negative	<input checked="" type="checkbox"/> N/A
<b>BREATH ALCOHOL TEST</b>			
- Alcohol	<input type="checkbox"/> Non-Negative	<input checked="" type="checkbox"/> Negative	<input type="checkbox"/> N/A

Jakarta, August 27, 2020



**PT. KARTIKA BINA MEDIKATAMA**  
( dr. Dian Wahyu Tanjungsari, Sp.PK )  
Clinical Patologist

# **HEALTH ASSESSMENT REPORT**

*Of*

**AGUS PRIYONO**

**01023919**

**Thursday, 27 August 2020**

## **MP BELTWAY CLINIC**

Beltway Office Park, Annex Building, Ground Floor

Jl. TB. Simatupang Kav.41, Jakarta Selatan 12550

Tlp : (62-21) 808 66 099, Fax : (62-21) 808 66 098

[www.medikaplaza.com](http://www.medikaplaza.com)

## MP BELTWAY CLINIC

Beltway Office Park, Annex Building, Ground Floor  
Jl. TB. Simatupang Kav.41, Jakarta Selatan 12550  
Tlp : (62-21) 808 66 099, Fax : (62-21) 808 66 098  
www.medikapla.com

### PATIENT DATA

MedRec.	: 01023919	EMPLOY. STATUS	: Employee
NAME	: AGUS PRIYONO	BIRTHDATE	: 14 May 1986
EMPLOYEE No.	: -	SEX	: Male
JOB TITLE	: INSPECTOR	STATUS	: Married
COMP. NAME	: INSPEKTINDO SINERGI PERSADA, PT	NASIONALITY	: Indonesia

### SUMMARY

#### MEDICAL FINDING :

1. Hypertriglyceridemia
2. Increase SGPT level
3. Non reactive Anti Hbs
4. Obesity
5. Calculus, decayed, and radix teeth
6. USG abdomen : Fatty liver
7. Decreasing of hearing acuity on high frequency of both ears
8. Treadmill Exercise Test : Mild positive ischemic

Your fitness status is temporary unfit

#### PERCEPTIONS OF EXPOSURE BY WORKERS :

- Others (Inspector)

#### SUGGESTION :

1. Low fat and carbohydrate diet, exercise regularly minimal 3 times a week. Consultation with an Internist for further evaluation of hypertriglyceridemia
2. Take enough rest minimal 8 hours/day. Repeat SGPT examination 1 month later and consult to an Internist if still increase
3. Need to get Hepatitis B vaccination (booster)
4. Reduce body weight gradually 0.5 Kgs/week, by doing regular exercise (aerobic/jogging), 3-4x/week, 30-45 minutes and reduce high calorie diet until maximal body weight is 68.89 Kgs (present body weight is 89.3 Kgs). Consultation with a Nutritionist for evaluation of obesity
5. Consultation with a Dentist for dental care, minimal once a year or better once in six month
6. Low fat diet and exercise regularly minimum 3x/week. Repeat abdominal USG 6 months later and consultation with an Internist to evaluate fatty liver
7. Avoid noisy environment and use earplug properly while working at noisy work environment to prevent further hearing impairment
8. Consultation with a Cardiologist for further evaluation of Treadmill Exercise Test : Mild positive ischemic

#### Responsible Doctor



Puferi Melati, MD

#### Notes:

If you need the further information or consultation, please contact us via :

Email : - beltway.doctor@medikapla.com  
- beltway.doctor2@medikapla.com  
Telepon Klinik : (62-21) 8086 6000

## CLINICAL EVALUATION

Name : AGUS PRIYONO	Sex : Male	MR : 01023919	Visit : 27/08/2020
Comp.: INSPEKTINDO SINERGI PERSADA, PT		DOB : 14 May 1986	

EXAMINATION	RESULT	NOTES
-------------	--------	-------

### ANAMNESA

#### PRESENT COMPLAINT AND HISTORY OF PRESENT

#### ILLNESS

Present complaint Cough since 2 days ago, fever (-)

#### MEDICAL HISTORY

Alergy	No
Imunisasi	Yes
Surgery	No
Hospitalization	No
Disease	No

#### LIFE STYLE

Alcohol intake	No
Smoking	Yes <span style="float: right;">Mild smoker</span>
Exercise	Yes <span style="float: right;">Jogging</span>

#### FAMILY MEDICAL HISTORY

Diabetes Melitus	No
Hypertension	No
Heart disease	No
Lung TB	No
Kidney disease	No
Astma	No
Mental disease	No
Epilepsy	No
Cancer	No
Color blind	No
Stroke	No
Liver disease	No
Bone & joint	No
Others disease	No

#### WORK EXPOSURE

Noise	No
Heat Stress	No
Cold Stress	No
Vibration	No
Involving height	No
Radiation	No
Dust	No



## CLINICAL EVALUATION

Name : AGUS PRIYONO	Sex : Male	MR : 01023919	Visit : 27/08/2020
Comp.: INSPEKTINDO SINERGI PERSADA, PT		DOB : 14 May 1986	

EXAMINATION	RESULT	NOTES
Toxic chemical	No	
Irritating fluid	No	
Smoke	No	
Bacterium/Virus/Parasite	No	
Blood	No	
Animal	No	
Operating heavy mobile equipment	No	
Manual Handling	No	
Sitting continuously over 4 hours	No	
Stand continuously over 4 hours	No	
Using monitor screen more than 4 hours per day	No	
Exposure	No	
Unergonomic body positions	No	
Shift work	No	
Work is not accordance with skills and knowledge	No	
Workload does not accordance with time	No	
Work conflict	No	
Inappropriate task	No	
Career barriers	No	
Family conflict	No	
Working arround rotating machinery	No	
Administration work	No	
Handling food product	No	
Others	Yes	Inspector
<b>PHYSICAL EXAMINATION</b>		
General Appearance	Good	
Body shape	Picnicus	
<b>VITAL SIGN</b>		
Body Weight	89.3 Kg	
Body Height	166 Cm	
BMI	32.4 Kg/m <sup>2</sup>	
Normal Weight	50.98 - 68.89 Kg	
BMI Conclusion	Obesity	
Blood Pressure	120/80 mmHg	
Pulse	78 x/minute	
Body Temperature	36.2 °C	
RR	20	

## CLINICAL EVALUATION

Name : AGUS PRIYONO	Sex : Male	MR : 01023919	Visit : 27/08/2020
Comp.: INSPEKTINDO SINERGI PERSADA, PT		DOB : 14 May 1986	

EXAMINATION	RESULT	NOTES
Neck Circumference	40 Cm	
Arm Circumference	34 Cm	
Chest size	98 Cm	
Abdominal Circumference	96 Cm	
<b>SKIN</b>		
Skin	Normal	
<b>EYE</b>		
Left	Normal	
Right	Normal	
<b>ENT</b>		
Auricle	Normal	
Ear canal	Normal	
Drums	Normal	
Septum/Conchae	Normal	
Sinuses	Normal	
Pharynx	Normal	
Tonsil	Normal	
<b>MOUTH</b>		
Gum	Normal	
Dental	Abnormal	Calculus, decayed, and radix teeth
<b>NECK</b>		
General	Normal	
Thyroid Gland	Normal	
<b>CHEST</b>		
Form	Normal	
Lung	Normal	
Heart	Normal	
Breast	Normal	
<b>ABDOMEN</b>		
Form	Flat	
Palpation	Supple	
Liver	Not Palpable	
Spleen	Not Palpable	
Kidney	No Ballotment	
-	No	
Hernia inguinal	No	
<b>EXTRIMITIES</b>		

## CLINICAL EVALUATION

Name : AGUS PRIYONO	Sex : Male	MR : 01023919	Visit : 27/08/2020
Comp.: INSPEKTINDO SINERGI PERSADA, PT		DOB : 14 May 1986	

EXAMINATION	RESULT	NOTES
Bones, joint	Normal	
Muscles, tonus	Normal	
Fingernails	Normal	
Hand	Normal	
Foot	Normal	
<b>RECTAL EXAMINATION</b>		
Hemorrhoid	Negative	
Rectum	Normal	
<b>SENSORIK EXAMINATION</b>		
Tes Raba	Normal	
<b>MOTORIK EXAMINATION</b>		
Tes Grip	Normal	
<b>REFLEX EXAMINATION</b>		
Physiologic reflex	Normal	
Patologic reflex	Normal	
<b>OTHERS EXAMINATION</b>		
Coordination	Normal	
<b>LYMPHE SYSTEM</b>		
Submandibula	Normal	
Neck Gland	Normal	
Armpit gland	Normal	
Inguinal	Normal	



## OPHTHALMOLOGY DIAGNOSTIC

Name : AGUS PRIYONO	Sex : Male	MR : 01023919	Visit : 27/08/2020
Comp.: INSPEKTINDO SINERGI PERSADA, PT		DOB : 14 May 1986	

EXAMINATION		Right	Left
Reading		-	
Previous Glasses		-	-
Without Glasses	Distant	20/20	20/20
	Near	J1	J1
Correction	Distant	-	-
	Near	-	-
Depth Perception		-	
Tonometry		20.0 mmHg	20.0 mmHg
Funduscopy		NORMAL	NORMAL
Visual Fields		Normal	
Colour Blind Test		Normal	

Impression :

## RADIOLOGY DIAGNOSTIC

Name : AGUS PRIYONO

Sex : Male

MR : 01023919

Visit : 27/08/2020

Comp.: INSPEKTINDO SINERGI PERSADA, PT

DOB : 14 May 1986

### EXAMINATION

### RESULT

THORAX PA

No abnormality seen in both lungs.  
Normal bronchovascular markings in both hili.  
The heart is normal in size and shape.  
The mediastinum is not widened.  
Both sinus and diaphragms are good.  
No evidence of pleural effusion.

Impression

Normal heart and lungs

## RADIOLOGY DIAGNOSTIC

Name : AGUS PRIYONO

Sex : Male

MR : 01023919

Visit : 27/08/2020

Comp.: INSPEKTINDO SINERGI PERSADA, PT

DOB : 14 May 1986

### EXAMINATION

### RESULT

USG ABDOMEN

LIVER:

Normal in size and contour, smooth surface, parenchyme echoes structures increased. No sign of SOL.

Intrahepatic vascularity and billiary tract are normal.

GALL BLADDER:

Normal in size, contour and surface. No sign of SOL/ sludge/ stone.

RIGHT KIDNEY :

Normal in size, contour and surface. No sign of obstruction/ stone/ SOL.

LEFT KIDNEY:

Normal in size, contour and surface. No sign of obstruction/ stone/ SOL.

PANCREAS:

Normal in size, contour and surface. No sign of SOL.

LIEN:

Normal in size and contour, the echoes are homogenous. No sign of SOL.

URINARY BLADDER:

Normal in size, contour and surface. No sign of stone/ SOL.

PROSTATE AND VESICULA SEMINALIS:

Normal in size and contour which are homogenous echoes and no sign of focal lesion/ SOL.

Impression

Fatty liver

Other abdominal organs are normal.

## LABORATORY RESULT

Name : AGUS PRIYONO	MR : 01023919	Visit : 27/08/2020	#Lab : IN71482615500
Comp.: INSPEKTINDO SINERGI PERSADA, PT	Sex : Male	DOB : 14 May 1986	

EXAMINATION	RESULT	NORMAL RANGE
-------------	--------	--------------

### HEMATOLOGI

ABO/Rh Typing "A" Rh(+) positive

#### Automated Blood Count

White Blood Cell (WBC)	9.2	3.8 - 11.0
Erythrocyte (RBC)	5.1	4.4 - 5.9
Haemoglobin	16.8	13.2 - 17.3
Hematocrit	44	40 - 52
Thrombocytes	249	150 - 440

#### MCV, MCH, MCHC

MCV	85	80 - 100
MCH	33	26 - 34
MCHC	38.5 *	32 - 36
ESR	2	0 - 10

#### Differential Count

Basophils	1	0 - 1
Eosinophil	2	2 - 4
Bands / Stab	3	3 - 5
Neutrophils	56	50 - 70
Lymphocytes	27	25 - 40
Monocytes	11 *	2 - 8

### BLD CHEMISTRY/LIPID PROFILE

Total Cholesterol	178	Normal/Desireable: <200 Borderline High: 200-239 High: >=240
HDL Cholesterol	43.2	Normal : >40 - <60 Low HDL : <40 Desireable : >=60
LDL Cholesterol	94	Optimal: <100 Near/Above Optimal: 100-129 Borderline High: 130-159 High: 160-189 Very High: >=190
Triglycerides	203 *	Normal : <150 Borderline High: 150-199 High : 200-499 Very High : >=500

### BLD CHEMISTRY/KIDNEY FUNCTION

## LABORATORY RESULT

Name : AGUS PRIYONO	MR : 01023919	Visit : 27/08/2020	#Lab : IN71482615500
Comp.: INSPEKTINDO SINERGI PERSADA, PT	Sex : Male	DOB : 14 May 1986	

EXAMINATION	RESULT	NORMAL RANGE
Ureum	25.7	10.0 - 50.0
Creatinine	1.2	0.6- 1.3
Uric Acid	5.81	3.50 - 7.20

### BLD CHEMISTRY/LIVER FUNCTION

Total Bilirubin	0.50	0.1 - 1.0
Direct Bilirubin	0.16	0.0 - 0.2
Indirect Bilirubin	0.34	0.0 - 0.8
SGOT(AST)	38	13 - 45
SGPT (ALT)	68 *	13 - 50
Alkaline Phosphatase	64	30 - 120
Gamma GT	34	0 - 50
Albumin	4.5	3.5 - 5.5
Globulin	2.30	2.3 - 3.5
Total Protein	6.8	6.6 - 8.7

### BLD CHEMISTRY/DIABETES

Glucose Fasting	91	< 100
Glucose Urine	Negative	Negative
Keton Urine	Negative	Negative

#### Blood Glucose 2 PP

Blood Sugar 2 Hours PP	80	< 140
Glucose Urine	Negative	Negative
Keton Urine	Negative	Negative

### SEROLOGI / IMUNOLOGI

HBsAg (Quantitative)	0.00	0.00 - 0.03
Anti Hbs (Quantitative)	0.1 *	>= 5.0

### TOXICOLOGY - DRUGS SCREENING

Methadone	Negative	Negative
Phencyclidine	Negative	Negative
THC/Marijuana	Negative	Negative
Amphetamine	Negative	Negative
Benzodiazepines	Negative	Negative
Opiat	Negative	Negative
Cocain	Negative	Negative
Metamphetamine	Negative	Negative
Alcohol	Negative	Negative

### URINALYSIS

#### Complete Urine Analysis

## LABORATORY RESULT

Name : AGUS PRIYONO	MR : 01023919	Visit : 27/08/2020	#Lab : IN71482615500
Comp. : INSPEKTINDO SINERGI PERSADA, PT	Sex : Male	DOB : 14 May 1986	

EXAMINATION	RESULT	NORMAL RANGE
-------------	--------	--------------

### Macroscopic

Color	Yellow	
Turbidity	Clear	Clear
Specific Gravity	1.025	1.000 - 1.030
pH	6.0	4.5 - 8.0
Leucocyte	Negative	Negative
Glucose	Negative	Negative
Nitrit	Negative	Negative
Bilirubin	Negative	Negative
Blood	Negative	Negative
Urobilinogen	Normal	Normal
Protein	Negative	Negative
Keton	Negative	Negative

### Microscopic

RBC	0-1	0 - 1
WBC	0-1	0 - 4
Cylinder	Negative	
Epithels Squamous	0-1	5 - 15
Crystals	Negative	
Bacteria	Negative	Negative
Others	Negative	

## STOOL / RECTAL SWAP

### Faeces Complete

#### Macroscopic

Color	Brown	
Consistency	Smooth	
Mucus	Negative	Negative
Blood	Negative	Negative
Pus	Negative	Negative
Parasitologi Faeces	Negative	Negative
Lipid	Negative	Negative

#### Microscopic

RBC	0-1	0 - 1
WBC	0-1	0 - 5
Amoeba	Negative	
Ephitels	Positive	Positive
Worm Eggs	Negative	Negative



## LABORATORY RESULT

Name : AGUS PRIYONO	MR : 01023919	Visit : 27/08/2020	#Lab : IN71482615500
Comp. : INSPEKTINDO SINERGI PERSADA, PT	Sex : Male	DOB : 14 May 1986	

EXAMINATION	RESULT	NORMAL RANGE
Yeast	Negative	Negative
Muscle Fiber	Negative	Negative
Others	Negative	Negative
<b>Digestive</b>		
Amylum	Negative	Negative
Fat	Negative	
Fibers	Positive	Positive

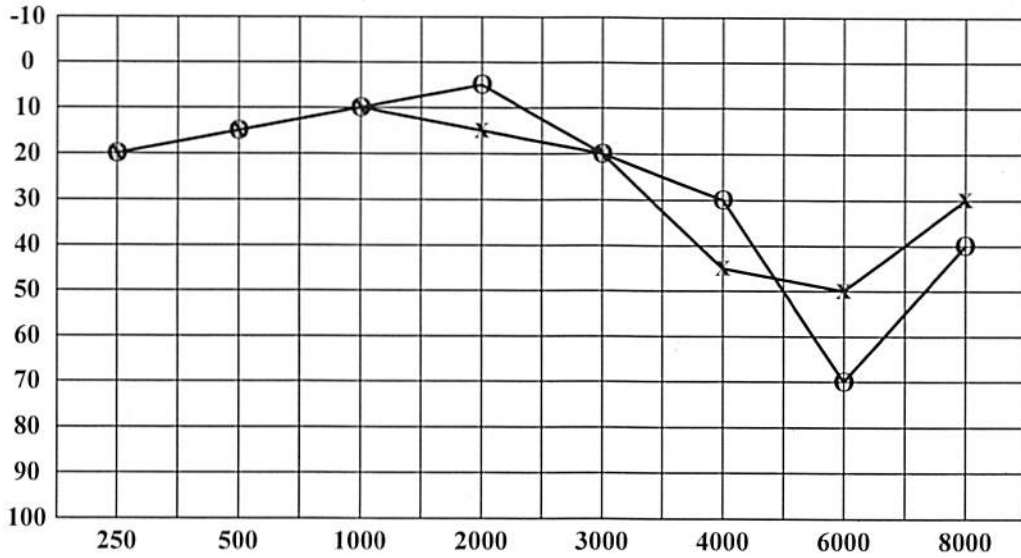
# AUDIOMETRY DIAGNOSTIC

Name : AGUS PRIYONO	Sex : Male	MR : 01023919	Visit : 27/08/2020
Comp. : INSPEKTINDO SINERGI PERSADA, PT		DOB : 14 May 1986	

## RESULT

Left Ear	250	500	1000	2000	3000	4000	6000	8000
AC	20	15	10	15	20	45	50	30
BC	-	-	-	-	-	-	-	-

Right Ear	250	500	1000	2000	3000	4000	6000	8000
AC	20	15	10	5	20	30	70	40
BC	-	-	-	-	-	-	-	-



< : Right Ear (BC)  
 > : Left Ear (BC)  
 O : Right Ear (AC)  
 X : Left Ear (AC)

Conclusion Right Ear : Hearing threshold = 15 dB  
 (Within normal limit)  
 With decreasing on frequency 4000Hz - 8000Hz

Conclusion Left Ear : Hearing threshold = 21.25 dB  
 (Within normal limit)  
 With decreasing on frequency 4000Hz - 8000Hz

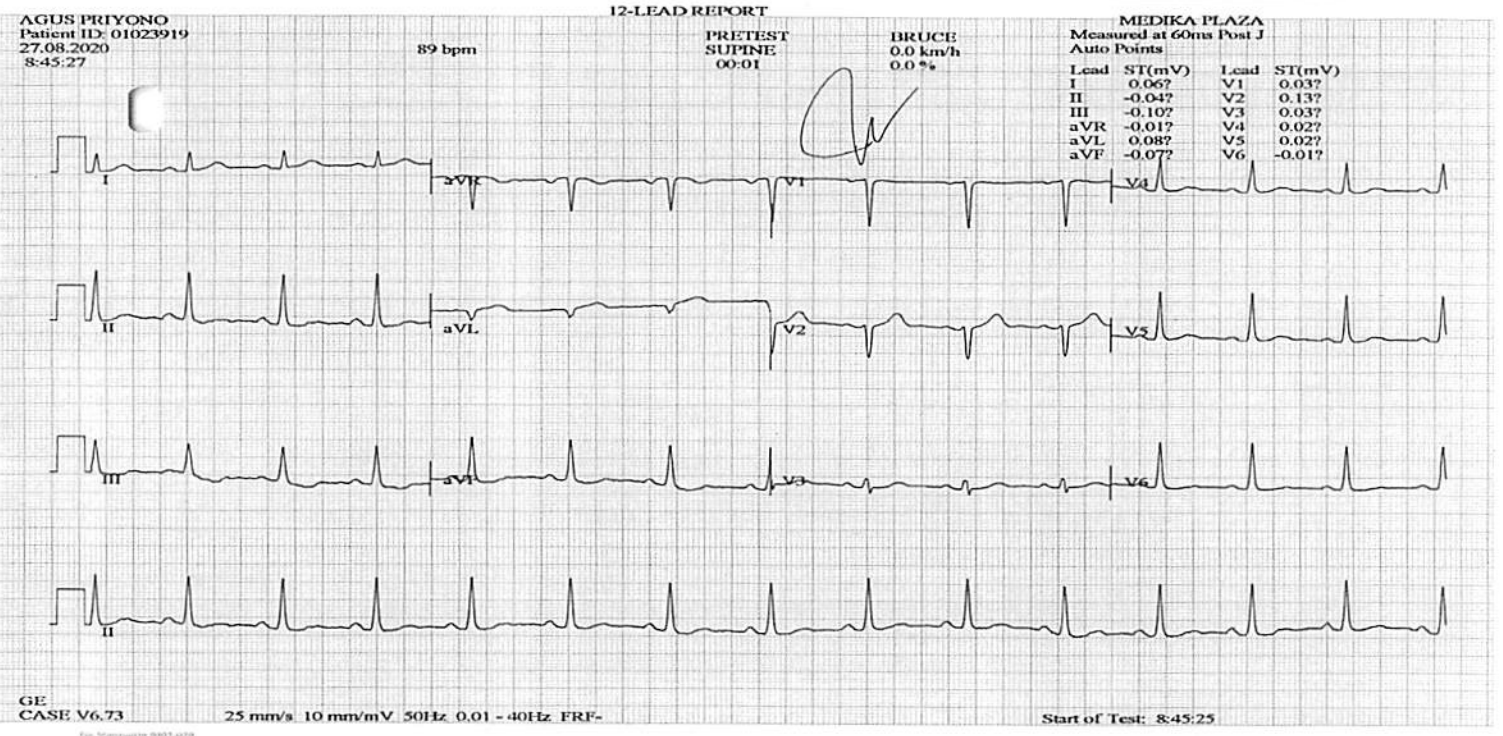
# CARDIOLOGY DIAGNOSTIC

Name : AGUS PRIYONO	Sex : Male	MR : 01023919	Visit : 27/08/2020
Comp. : INSPEKTINDO SINERGI PERSADA, PT		DOB : 14 May 1986	

EXAMINATION	RESULT	Comments :
-------------	--------	------------

TREADMILL	Sinus Rythm axis ( N ), P wave ( N ), PR int 0.16" ST - T segment ( N ), aritmia (-)	Treadmill Exercise Test : Mild positive ischemic  Cardiopulmonary Fitness Classification : Good METs : 10.8
-----------	---	---

ELECTROCARDIOGRAPHY	Sinus Rythm axis ( N ), P wave ( N ), PR int 0.16" ST - T segment ( N ), aritmia (-)	Normal ECG
---------------------	---	------------





AGUS PRIYONO  
Patient ID: 01023919  
27.08.2020  
8:45:46

12-LEAD REPORT

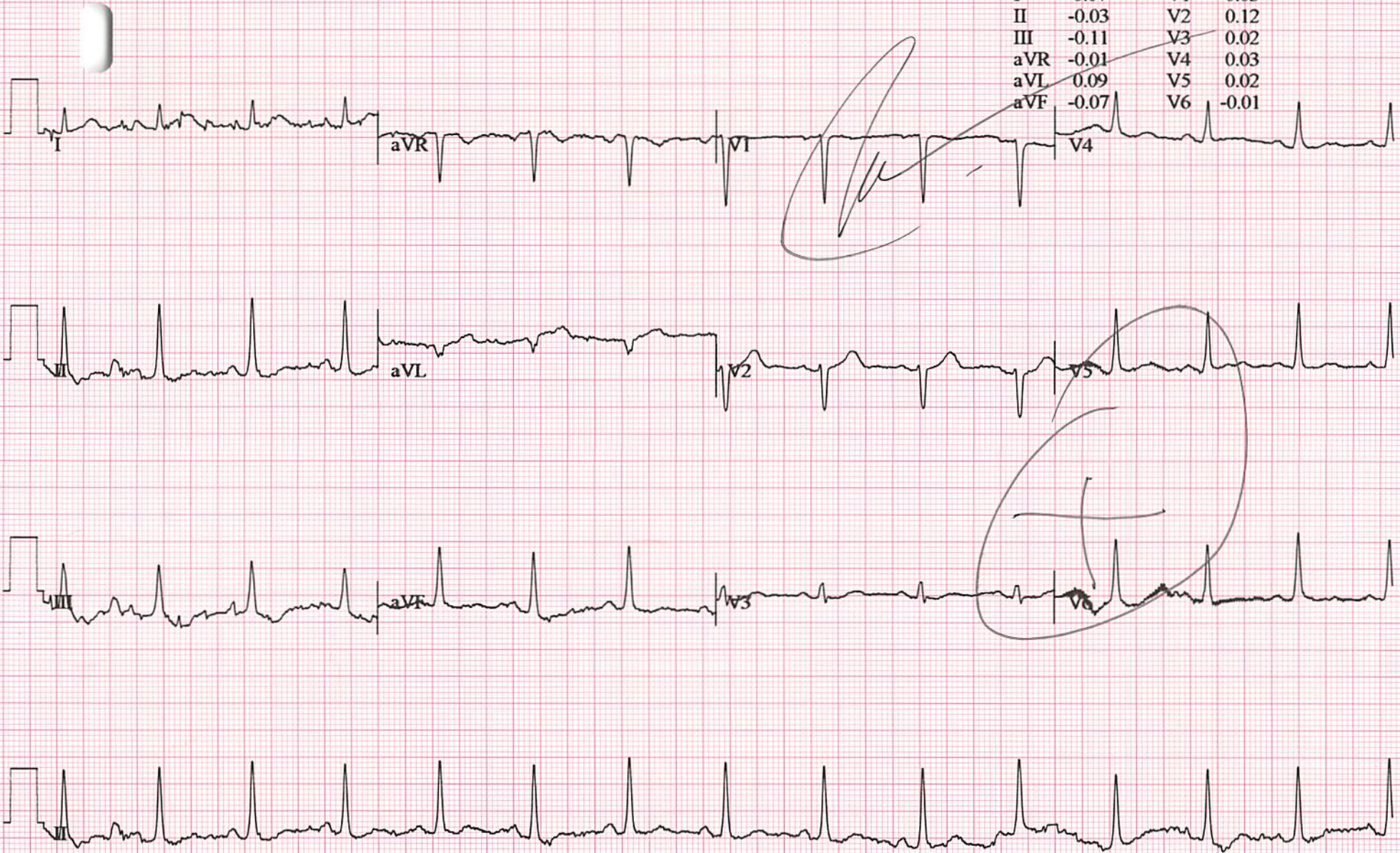
85 bpm

PRETEST  
STANDING  
00:20

BRUCE  
0.0 km/h  
0.0 %

MEDIKA PLAZA  
Measured at 60ms Post J  
Auto Points

Lead	ST(mV)	Lead	ST(mV)
I	0.07	V1	0.03
II	-0.03	V2	0.12
III	-0.11	V3	0.02
aVR	-0.01	V4	0.03
aVL	0.09	V5	0.02
aVF	-0.07	V6	-0.01





12-LEAD REPORT

AGUS PRIYONO  
Patient ID: 01023919  
27.08.2020  
8:46:04

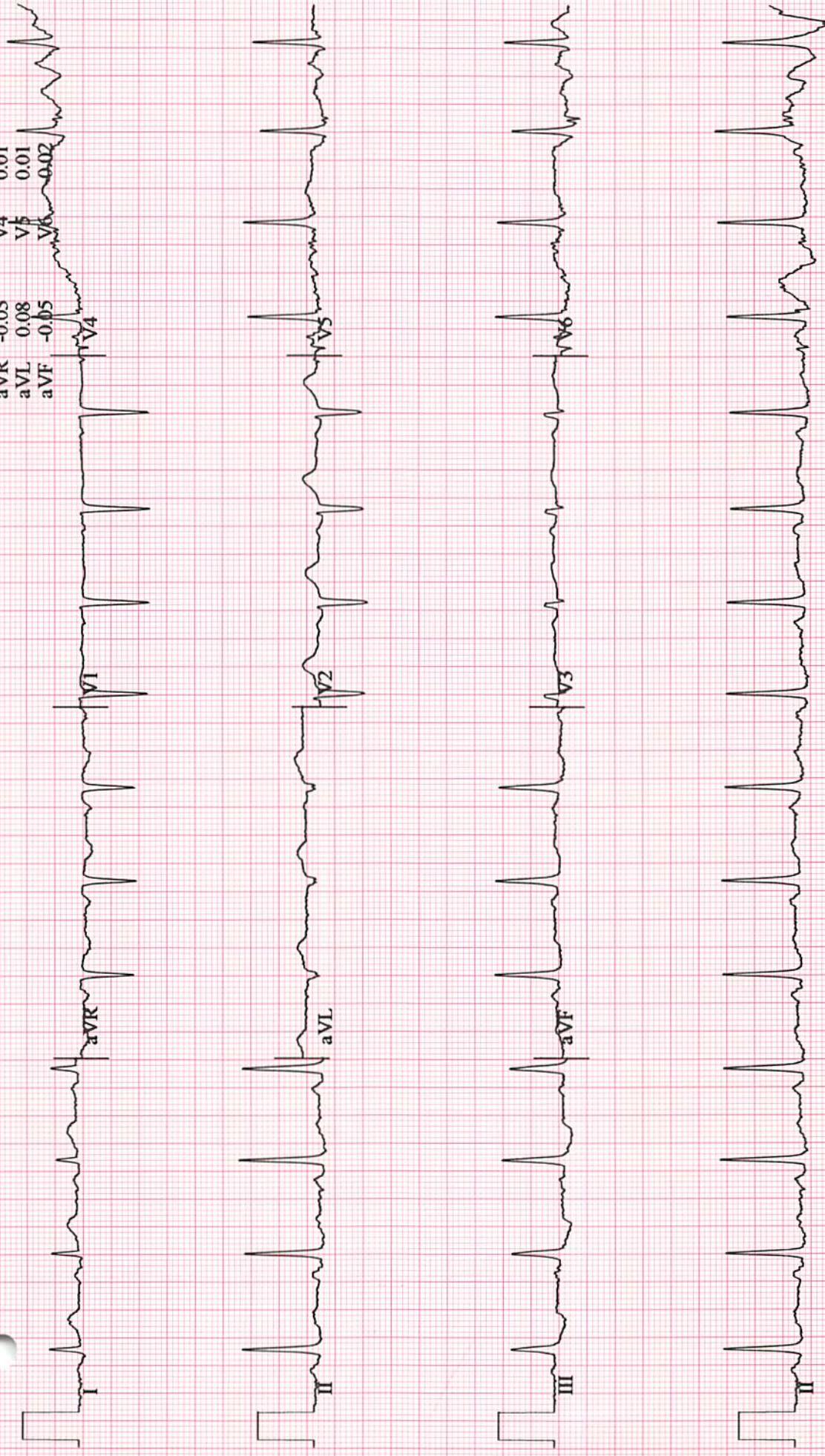
86 bpm

PRETEST  
WARM-UP  
00:38

BRUCE  
0.0 km/h  
0.0 %

MEDIKA PLAZA  
Measured at 60ms Post J  
Auto Points

Lead	ST(mV)	Lead	ST(mV)
I	0.07	V1	0.01
II	-0.02	V2	0.10
III	-0.09	V3	0.01
aVR	-0.03	V4	0.01
aVL	0.08	V5	0.01
aVF	-0.05	V6	-0.02





AGUS PRIYONO  
Patient ID: 01023919  
27.08.2020  
8:48:56

LINKED MEDIANS

112 bpm

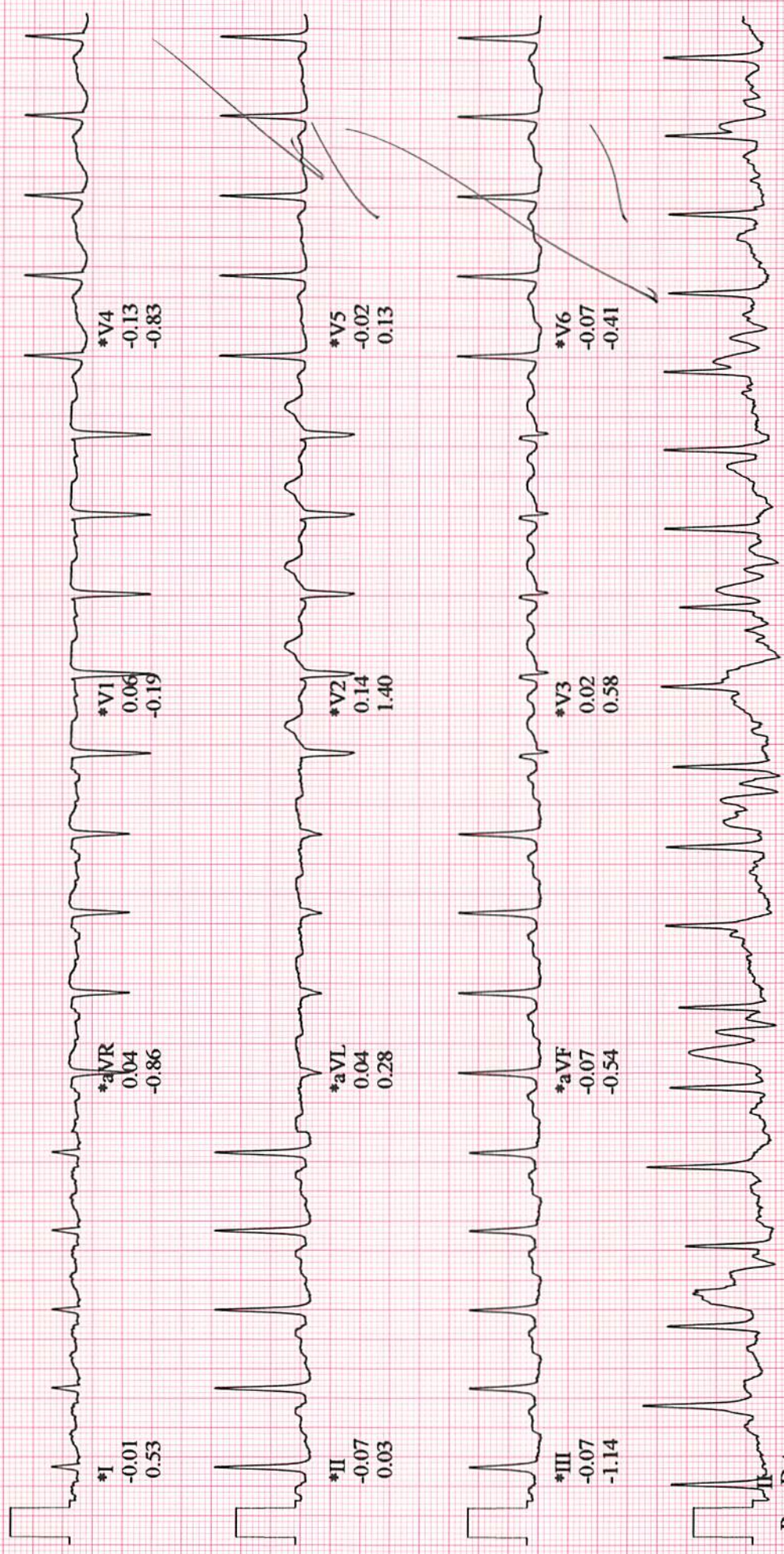
EXERCISE  
STAGE 1  
02:50

BRUCE  
2.7 km/h  
10.0 %

MEDIKA PLAZA

Lead  
ST Level (mV)  
ST Slope (mV/s)

60 ms post J



Raw Data

\*Computer Synthesized Rhythms



AGUS PRIYONO  
Patient ID: 01023919  
27.08.2020  
8:51:56

LINKED MEDIANS

MEDIKA PLAZA

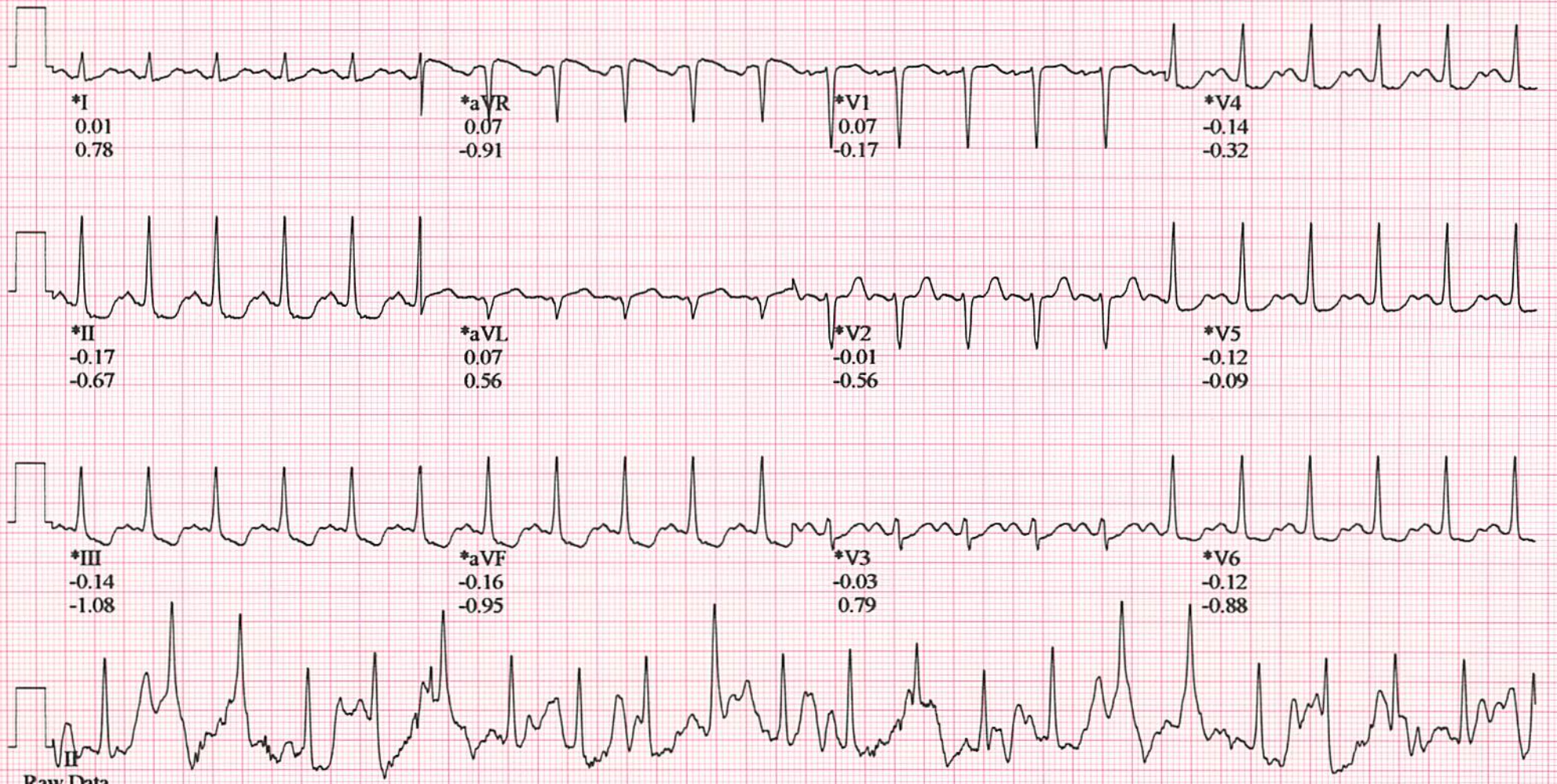
130 bpm

EXERCISE  
STAGE 2  
05:50

BRUCE  
4.0 km/h  
12.0 %

Lead  
ST Level (mV)  
ST Slope (mV/s)

60 ms post J



Raw Data

\*Computer Synthesized Rhythms

GE  
CASE V6.73

25 mm/s 10 mm/mV 50Hz 0.01 - 40Hz FRF- HR(V1,II)

Start of Test: 8:45:25



AGUS PRIYONO  
Patient ID: 01023919  
27.08.2020  
8:54:56

LINKED MEDIANS

164 bpm  
130/90 mmHg

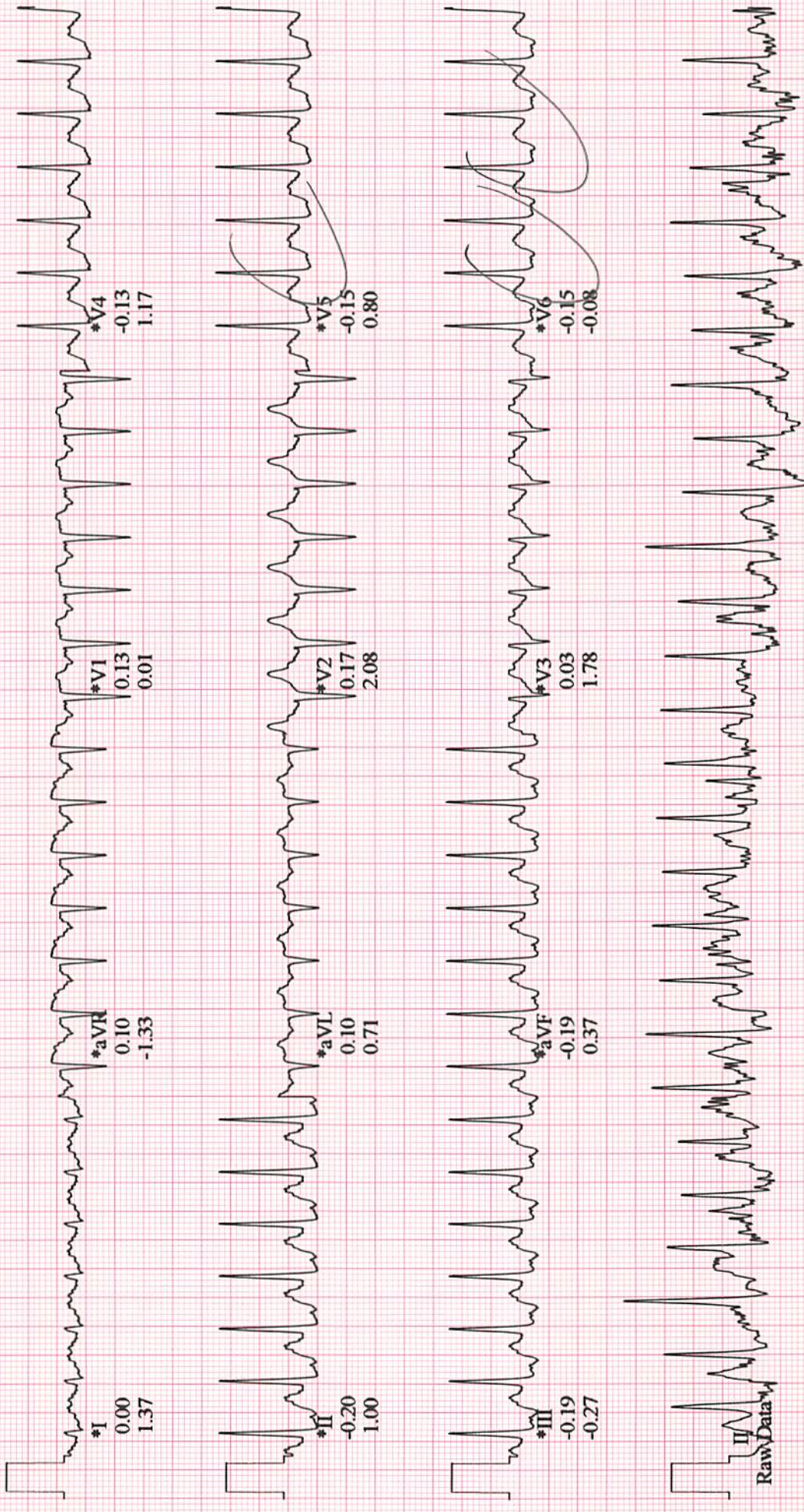
EXERCISE  
STAGE 3  
08:50

BRUCE  
5.5 km/h  
14.0 %

MEDIKA PLAZA

Lead  
ST Level (mV)  
ST Slope (mV/s)

60 ms post J



RawData

\*Computer Synthesized Rhythms



AGUS PRIYONO  
Patient ID: 01023919  
27.08.2020  
8:55:18

LINKED MEDIANS (PEAK EXERCISE)

EXERCISE  
STAGE 4  
09:12

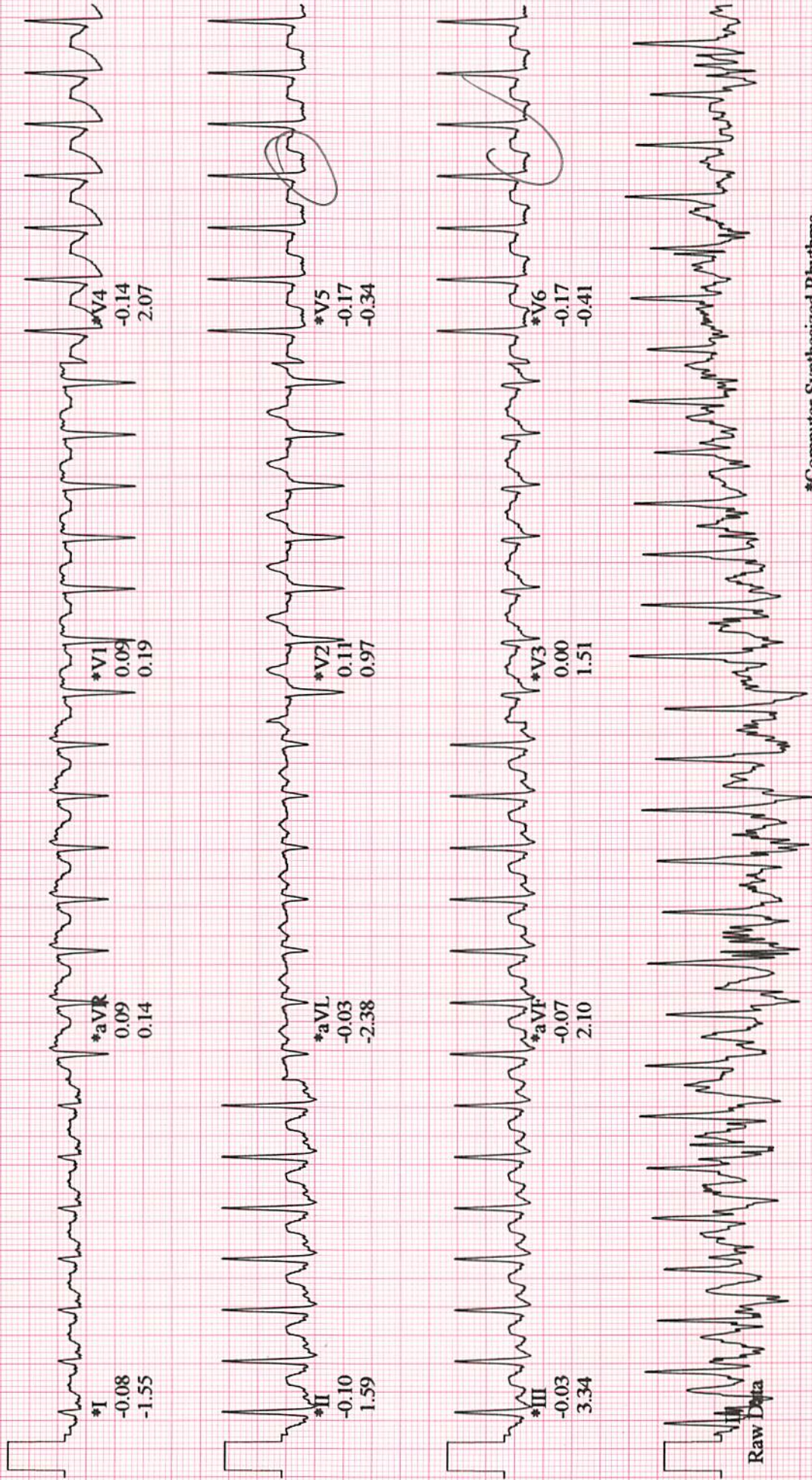
BRUCE  
6.8 km/h  
16.0 %

166 bpm  
130/90 mmHg

MEDIKA PLAZA

Lead  
ST Level (mV)  
ST Slope (mV/s)

60 ms post J



\*Computer Synthesized Rhythms



AGUS PRIYONO  
Patient ID: 01023919  
27.08.2020  
8:55:38

LINKED MEDIANS

160 bpm  
130/90 mmHg

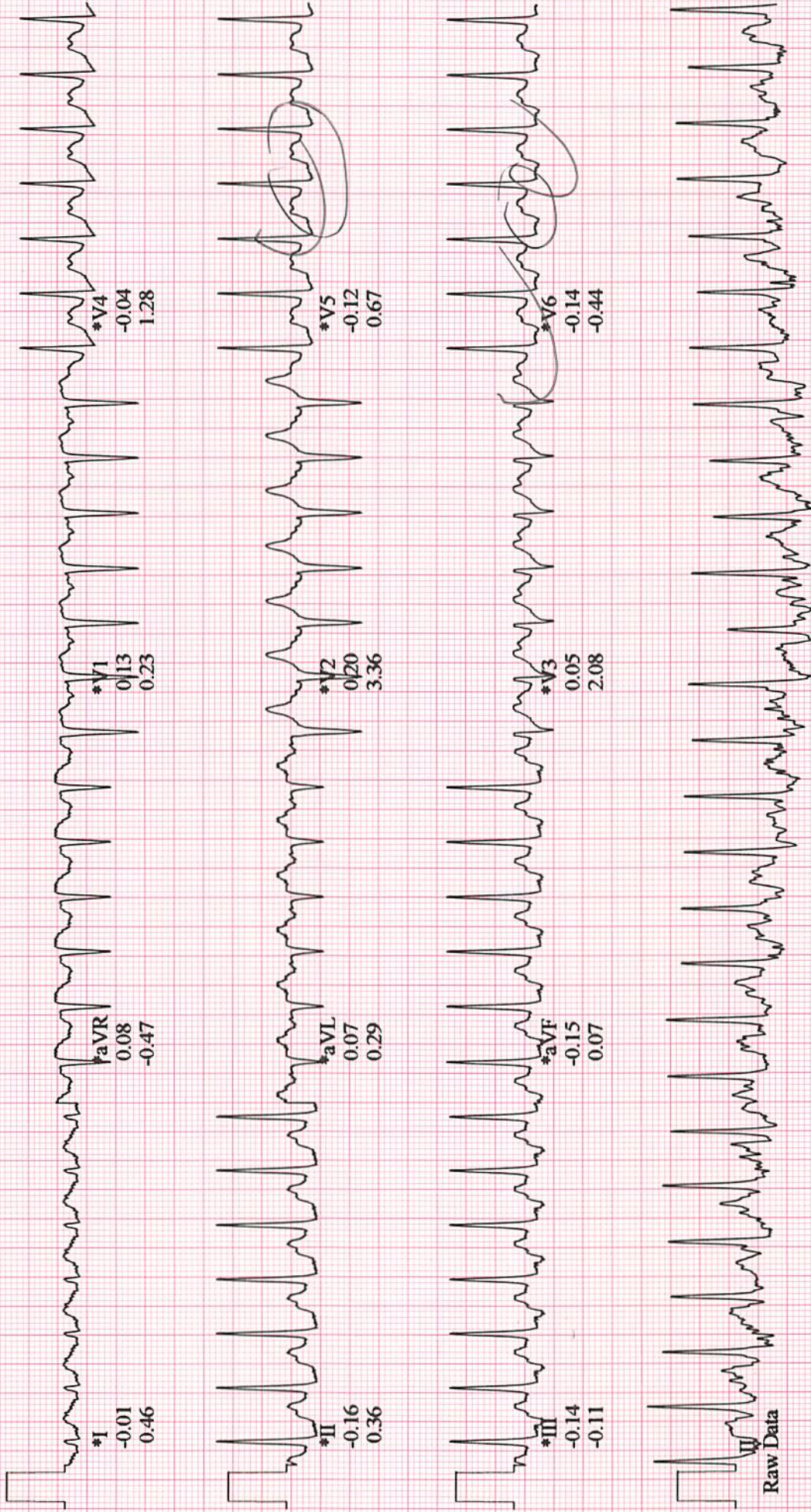
RECOVERY  
Recovery1  
00:20

BRUCE  
2.4 km/h  
0.0 %

MEDIKA PLAZA

Lead  
ST Level (mV)  
ST Slope (mV/s)

60 ms post J



Raw Data

\*Computer Synthesized Rhythms



Tabular Summary

MEDIKA PLAZA

**AGUS PRIYONO,**  
Patient ID 01023919

27.08.2020 Male 166 cm 89 kg  
8:45:25 34yrs Asian  
Meds:

Test Reason:  
Medical History:

Ref. MD: Ordering MD:  
Technician: JENI Test Type:  
Comment:

BRUCE: Total Exercise Time 09:12  
Max HR: 169 bpm 90% of max predicted 186 bpm HR at rest: 85  
Max BP: 130/90 mmHg Max RPP: 21320 mmHg\*bpm  
Maximum Workload: 10.80 METS  
Max. ST: -0.23 mV, 0.00 mV/s in V4; EXERCISE STAGE 2 05:30  
Arrhythmia: A:14, PVC:9, PSVC:1  
ST/HR index: 2.16  $\mu$ V/bpm  
ST/HR slope: 2.74  $\mu$ V/bpm (aVF)  
HR reserve used: 80 %  
Freq.VE recovery: 0 VE/min  
QRS duration: BASELINE: 88 ms, PEAK EX: 84 ms, REC: 82 ms  
Location Number: \* 0 \*

Phase Name	Stage Name	Time in Stage	Speed (km/h)	Grade (%)	Workload (METS)	HR (bpm)	BP (mmHg)	RPP (mmHg*bpm)	VE (/min)	ST Level (V4 mV)	Comment
PRETEST	SUPINE	00:20	0.00	0.00	1.0	85			0	0.03	
	STANDING	00:11	0.00	0.00	1.0	86			0	0.01	
	HYPERV.	00:02	0.00	0.00	1.0	86			0	0.01	
	WARM-UP	00:09	0.00	0.00	1.0	86			0	0.01	
EXERCISE	STAGE 1	03:00	2.70	10.00	4.6	113	120/80	13560	0	-0.12	
	STAGE 2	03:00	4.00	12.00	7.0	130	130/90	16900	0	-0.16	
	STAGE 3	03:00	5.50	14.00	10.2	162	130/90	21060	0	-0.10	
	STAGE 4	00:12	6.80	16.00	10.8	166			0	-0.14	
RECOVERY	Recovery1	00:32	2.40	0.00	6.2	155			0	-0.04	

*Agus Priyono*  
  
 PT. KARTIKA BINA MEDIKATAMA

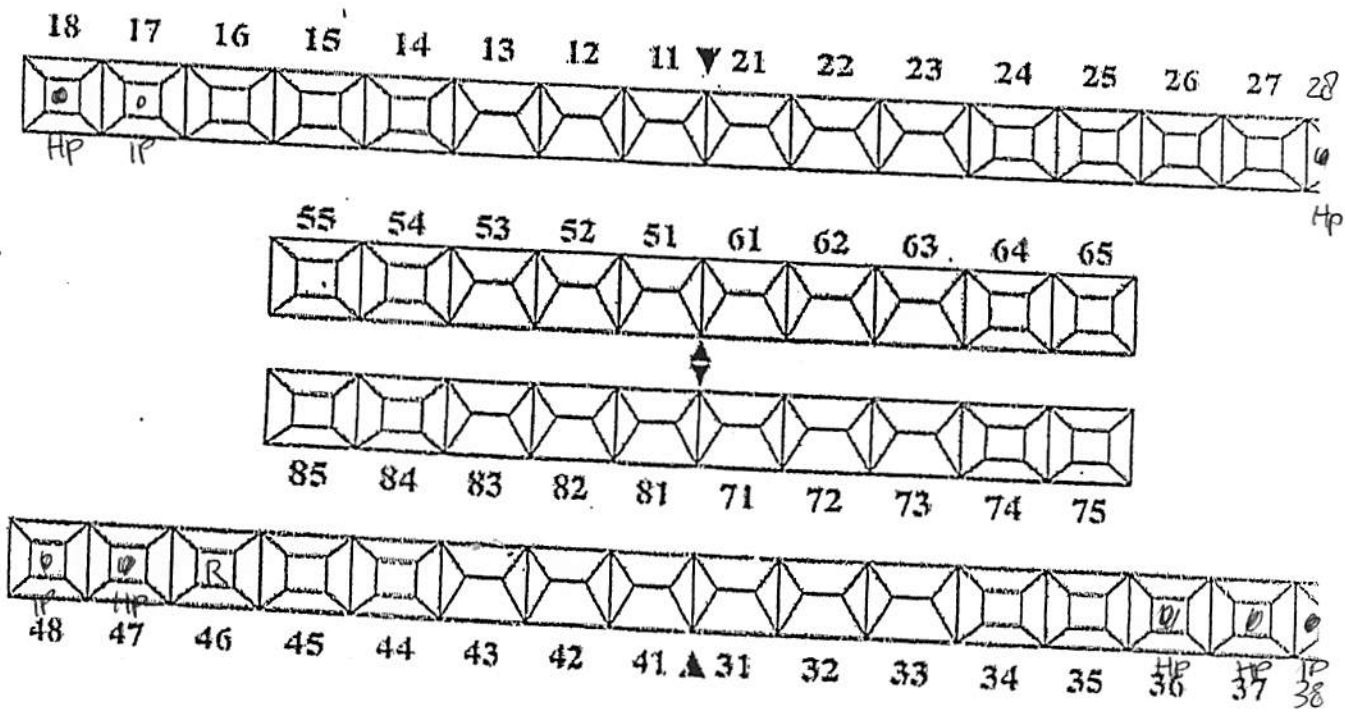


DENTAL EXAMINATION

Name: Agus Priono      Sex: M/P      MR :      Visit 27

Comp.: Inspektindo Sinerji      DOB : .....

ODONTOGRAM



Calculus +1

DIAGNOSA

- OH sedang
- Gingivitis
- Gangren Radix 46
- Hiperemia Rlpq 18 28 37 36 47
- Iritasi Rlpq 17 38 40

TREATMENT PLANNING

- Pro Scaling
- Pro Exo 46
- Pro Filling 18 28 37 36 47 17 38 40
- Pro Protesa pasca exo

Verified by: drg. Ilona Amalia/ drg. Fajar Sulawati/ drg. Siti Darjah/ drg. Herlina

27/9/20



**NAMA PASIEN** : Tn. Agus Priyono  
**No. RM** : 01-023919 / inspetindo  
**Klinik/MCU/HCU** : E/UT / 3

Yth. Ts. Dokter :  
(Konsulen)

Mohon konsul Pasien yang kami rawat  
dengan,

Diagnosis Kerja :  
Ikhtisar Klinik :

Konsul yang diminta :

**PENDAPAT KONSULEN** Ear : Tympanum mid tubed  
Nose : Concha bulging, no septum.  
Throat : T.T. pharynx grand  
Ardinary : Any threshold with normal hist.  
Diagnosis : Decaying on 4000 - 8000 Hz pda ear  
Chronic pharyngitis, Sleep sleep disorder.  
Nasehat/Anjuran :  
- Stop smoking  
- Use eye protection.  
- Use goggles in noisy area.  
- Avoid any head set.  
for long period & high intensity.

Tanggal : 27 / 8 / 2020  
Jam :  
Dokter :  
Tanda tangan  
dr. MERISTIANA  
SIP: 13/B.155/31.74.04/1.779.3/e/2018  
PT. KARTIKA BINA MEDIKATAMA  
Nama Jelas

No. Formulir : FM - DR - 008 - 02  
No. Revisi : 00  
Tanggal Terbit : 07 Juli 2017


## Medical Screening Questionnaire And Examination Record

Surname: <u>ARIS PRATONO</u>		Forenames:	
Address: <u>Purabaya, Jawa Tengah</u>		Tel No: <u>081295943382</u>	
Date of Birth: <u>14/05/1986</u>			
GP's Name:			
GP's Address:			
Date of Last Offshore Medical: <u>September 2019</u>		Offshore Occupation/Job Title: <u>Inspector</u>	
Emergency Response Role :			
<b>Social / Occupational History</b>			
		<b>Yes</b>	<b>No</b>
			<b>Comments</b>
(1)	Do you smoke? If so, how many per day?	✓	<u>6 batang / day.</u>
(2)	If an ex-smoker, when did you give up?	✓	
(3)	Average weekly alcohol consumption: state quantity and type.		✓
(4)	Have you been exposed to any known occupational hazard such as noise, radiation, dusts, asbestos, chemicals or lead?		✓
(5)	Do you use protective clothing, safety glasses or hearing protection?		✓
(6)	Have you ever developed any medical condition in connection with your occupation? If so, please give details eg hearing loss/skin condition/wheeze/backache/muscle strain/blood disease?		✓
(7)	Have you suffered any industrial injury? If so, please give details:		✓
(8)	Have you ever had any previous audiometric screening? Was this normal? State when and where.		✓
(9)	Have you ever had any previous lung function screening? Was this normal? State when and where.		✓
(10)	Have you ever been rejected from employment on medical ground?		✓
(11)	Have you ever received compensation, or is there any industrial claim pending?		✓
(12)	Have you ever been medivaced from an offshore installation?	✓	
<b>Examining Physician's comments :</b>			

\* Source : Medical Aspects of Fitness for Work Offshore Guidance for Examining Physicians Oil & Gas UK, March 2008

**Medical Screening Questionnaire And  
 Examination Record (cont'd)**

<b>Do you have, or have you been diagnosed as suffering from any of the following?</b> <i>(Please circle and elaborate)</i>		
<i>Please circle and elaborate</i>		
(1) Chest pain/heart pain	Yes	<input checked="" type="radio"/> No
(2) High blood pressure / stroke	Yes	<input checked="" type="radio"/> No
(3) Asthma / Epilepsy/Diabetes	Yes	<input checked="" type="radio"/> No
(4) Peptic ulcer disease	Yes	<input checked="" type="radio"/> No
(5) Kidney disease (eg stones)	Yes	<input checked="" type="radio"/> No
(6) Psychiatric disorder (eg anxiety, depression)	Yes	<input checked="" type="radio"/> No
(7) Tuberculosis	Yes	<input checked="" type="radio"/> No
(8) Cancer	Yes	<input checked="" type="radio"/> No
<b>Do any of your immediate family (parents/brothers/sisters) have a history of any of the above conditions? Please specify :</b>		

<b>Do you currently have any of the following?</b>		
(1) Backache/joint or muscular pain	Yes	<input checked="" type="radio"/> No
(2) Hernia/rupture	Yes	<input checked="" type="radio"/> No
(3) Visual impairment	Yes	<input checked="" type="radio"/> No
(4) Perforated eardrum / discharge from ear	Yes	<input checked="" type="radio"/> No
(5) Recurrent indigestion	Yes	<input checked="" type="radio"/> No
(6) Jaundice/hepatitis/gall bladder disease	Yes	<input checked="" type="radio"/> No
(7) Change in bowel habit/diarrhoea	Yes	<input checked="" type="radio"/> No
(8) Blood in stools/piles/haemorrhoids	Yes	<input checked="" type="radio"/> No
(9) Shortness of breath/coughing up blood	Yes	<input checked="" type="radio"/> No
(10) Recurrent bronchitis/pneumonia	Yes	<input checked="" type="radio"/> No
(11) Blood in urine/kidney complications/stones	Yes	<input checked="" type="radio"/> No
(12) Headaches/migraine/dizziness	Yes	<input checked="" type="radio"/> No
<b>Physician's comments :</b>		
<b>I certify that the above information is correct :</b>		
Signed :  [ Employee ]		

\* Source : Medical Aspects of Fitness for Work Offshore Guidance for Examining Physicians Oil & Gas UK, March 2008



**Medical Screening Questionnaire And  
 Examination Record (cont'd)**

**Medical Examination**

*To Be Completed By Examining Physician*

<b>Photographic ID :</b>	Passport number :	
	Driver's license number :	
	Other :	

Height	Weight	BMI	BP	Pulse	FEV <sub>1</sub>	FVC	FEV <sub>1</sub> / FVC	Urinalysis		
								Protein	Blood	Glucose
166 cm	84,3 kg	32,4 kg/m <sup>2</sup>	120/80 mmHg	70x/ mm			N/A	Neg	Neg	Neg

Vision Distance			Vision Near			Colour		VDU
L	Aided L	Both	L	Aided L	Both	Normal	Abnormal	
L			L			Normal	Abnormal	
						✓		
R			R			✓		


	Normal	Abnormal	Comments
Audiometric Screening		✓	Decreasing of hearing acuity on high frequency of both ears.
Substance Abuse Screening	✓		
Stool Culture (Catering Crew)	✓		
<b>Further investigations</b>			(Has been consulted to internist)
Blood tests			1. Hypertriglyceridemic 2. Increase SGPT level 3. Non reactive Anti Hbs.
Chest X-Ray	✓		
Electrocardiograph (ECG) / Treadmill		✓	Mild positive Ischemic (Has been consulted to cardiologist)
Spirometry			N/A.
USG		✓	Fatty liver.

\* Source : Medical Aspects of Fitness for Work Offshore Guidance for Examining Physicians Oil & Gas UK, March 2008

### Medical Screening Questionnaire And Examination Record (cont'd)

	Normal	Abnormal	Comments
1. Eyes/pupils	✓		calculus, decayed, radiar teeth
2. Ear, nose and throat	✓		
3. Teeth		✓	
4. Lungs/chest	✓		
5. Cardiovascular	✓		
6. Abdomen	✓		
7. Hernial orifices	✓		
8. Genitourinary	✓		
9. Musculoskeletal	✓		
10. Skin	✓		
11. Varicose veins	✓		
12. Neurological	✓		
<b>Physician to comment on any abnormalities :</b>			

Certification	Comment/Reason
Fit for offshore work as per Oil & Gas UK guidelines	✓
Fit for restricted offshore work following discussion with operating company's medical adviser	
Temporarily unfit for offshore work	
Permanently unfit for offshore work	


Physician's signature :  **dr. Puteri Melati**  
 Print name : PT. KARTIKA BINA MEDIKA MA  
 Date of examination : 27/08/2020  
IP: 23/B. 15A/31.74.04.10001.779.3/e/2019

\* Source : Medical Aspects of Fitness for Work Offshore Guidance for Examining Physicians Oil & Gas UK, March 2008

## Unrestricted Offshore Work Certificate

### Medical Certificate of Fitness for Offshore Work

( Issued in accordance with Oil and gas UK Guidelines )

<b>Name :</b>	AGUS PRIYONO
<b>Date of Birth :</b>	14 May 1986
<b>Employing Company Name :</b>	INSPEKTINDO SINERGI PERSADA, PT
<b>Occupation :</b>	INSPECTOR
<p>This individual has been examined in accordance          with Oil &amp; Gas UK Guidelines and is  <b>Medical Fit for Unrestricted To The Job Described At Offshore Work</b></p>	
<b>Examining Physician Name :</b>	dr. Frans Denis Martogi
<b>Oil &amp; Gas UK PIN No. :</b>	OGUK/2017/2465
<b>Date of Examination :</b>	27 August 2020
<b>Date of Expiry of Certificate :</b>	27 August 2022
<b>Signed :</b>	

  
 PT. KARTIKA BINA MEDIKATAMA

**PT. KARTIKA BINA MEDIKATAMA**



## MP BELTWAY CLINIC

Beltway Office Park, Annex Building, Ground Floor  
Jl. TB. Simatupang Kav.41, Jakarta Selatan 12550  
Tlp : (62-21) 808 66 099, Fax : (62-21) 808 66 098  
www.medikaplaza.com

### PATIENT DATA

MedRec.	: 01023919	EMPLOY. STATUS	: Employee
NAME	: AGUS PRIYONO	BIRTHDATE	: 14 May 1986
EMPLOYEE No.	: -	SEX	: Male
JOB TITLE	: INSPECTOR	STATUS	: Married
COMP. NAME	: INSPEKTINDO SINERGI PERSADA, PT	NASIONALITY	: Indonesia

### SUMMARY

#### MEDICAL FINDING :

1. Hypertriglyceridemia (has been consulted to internist)
2. Increase SGPT level
3. Non reactive Anti Hbs
4. Obesity
5. Calculus, decayed, and radix teeth
6. USG abdomen : Fatty liver
7. Decreasing of hearing acuity on high frequency of both ears
8. Treadmill Exercise Test : Mild positive ischemic (has been consulted to cardiologist)

#### PERCEPTIONS OF EXPOSURE BY WORKERS :

- Others (Inspector)

Your fitness status is fit for unrestricted to the job described at offshore work.

#### SUGGESTION :

1. Low fat and carbohydrate diet, exercise regularly minimal 3 times a week. Consultation with an Internist for further evaluation of hypertriglyceridemia
2. Take enough rest minimal 8 hours/day. Repeat SGPT examination 1 month later and consult to an Internist if still increase
3. Need to get Hepatitis B vaccination (booster)
4. Reduce body weight gradually 0.5 Kgs/week, by doing regular exercise (aerobic/jogging), 3-4x/week, 30-45 minutes and reduce high calorie diet until maximal body weight is 68.89 Kgs (present body weight is 89.3 Kgs). Consultation with a Nutritionist for evaluation of obesity
5. Consultation with a Dentist for dental care, minimal once a year or better once in six month
6. Low fat diet and exercise regularly minimum 3x/week. Repeat abdominal USG 6 months later and consultation with an Internist to evaluate fatty liver
7. Avoid noisy environment and use earplug properly while working at noisy work environment to prevent further hearing impairment
8. Consultation with a Cardiologist for further evaluation of Treadmill Exercise Test : Mild positive ischemic

#### Responsible Doctor



Puteri Melati, MD

#### Notes:

If you need the further information or consultation, please contact us via :

Email : - beltway.doctor@medikaplaza.com  
- beltway.doctor2@medikaplaza.com  
Telepon Klinik : (62-21) 8086 6000

CONSULTATION  
SHEET

PATIENT NAME : Tn. Agus Priyono  
No. RM : 01.023919 / Inspektindo  
Klinik/MCU/HCU : Cardiologist

To. Dokter :  
(Counsel)

Kindly please counsel for patient who has take cares of

Diagnose :  
Clinik Summary :

Counsel Request :

COUNSEL ADVISE

Finding :

Diagnosis :

Recomendation :

*Agus Priyono*  
*Alert tanda FA*

*Per/pada*  
*FA risiko*

*Mrs. Good (Name)*

*Child / 2 / 19 / 2020*  
*EP : / Non specific*  
*See area*  
*= Ee*  
*- CAVA*

dr. Adh... Anthonseja, SpJP  
Complete Name... 74.04/-1.779.3/c/2017

Formulir Number : FM - DR - 008 - 02  
Revisi Number : 00  
Date : 07 Juli 2017

*FIT*

PATIENT NAME : Tn. Agus Pnyono  
 No. RM : 01-023919 / Inspektando  
 Klinik/MCU/HCU : Internist

To. Dokter (Counsel) :

Kindly please counsel for patient who has take cares of

Diagnose :  
 Klinik Summary :

Counsel Request :

S: *Andreas* *Andreas*, *Smk* *Valun* *Hep B* *1 tahun* *ix*

**COUNSEL ADVISE**

**Finding**  
 O: *norma* *157-67*  
*ves, cl, 7-*  
 Jantung: *B, TB* *1, mm* *1, 5* *1*  
 Abdomen: *debu, leus, Dv 41*

**Diagnosis**  
 Exit' *abd ft, edn 7-*

Tb: *203*  
 SgPT: *68*  
 Ah Hbs *0,1*  
 T6: *203*

**Recomendation :**

*A. I. Fatty liver*  
*2. per pemeriksaan Valun Hep B*  
*3. Hipertensi*

Date : *2 / 9 / 2020*  
 Time :  
 EP :

P. - *Blabaja* *Dr/muzn*  
 - *VIT E 1x1*  
 - *Valun Hep B booster*

Signature  
*dr. Virly Ningsih, Sp.PD*  
 Spesialis Penyakit Dalam  
 PT. KARTIKA BINA MEDIKATAMA...

Complete Name

Formulir Number : *FM - DR - 008 - 02* - *Cek ah Hbs 1-3 bulan setelah Valun*  
 Revisi Number : *00*  
 Date : *07 Juli 2017* - *Fenofibrate 1x100mg*

*1 FFA to work 4*