



## Certificate Of Health Assessment

Name	Age	Position	Department
ACHMAD CHOIRONI	38 yo	Inspection Supervisor	TESTING

COMPANY :

**INSPEKTINDO SINERGI PERSADA, PT**

### CONCLUSION

FIT TO WORK		
FIT WITH MEDICAL NOTE		✓
TEMPORARY UNFIT		
UNFIT		
Issued Date	Doctors Name	Prepared By
11 October 2021	<b>Yosephine Simanungkalit, MD</b> PKTK : KEP.043/BINWASK3-PNK3/KK/II/2018	 <b>MP+</b>
Expired Date		Verified By
11 October 2022	<b>dr. Muhammad Ilyas, Sp.Ok</b> SIP : 29/B.15b/31.74.04.1004.02.009.K.1/3/-1.779.3/e/2019	 PT. KARTIKA BINA MEDIKATAMA

No. Formulir : FM-DR-008-05  
 No. Revisi : 00  
 Tanggal Terbit : 2 Mei 2011

Certificate Number : **MP-BOP/1-20211011/131884**  
 MCU Validity Check  
<https://mcu-validasi.medikapla.com>

**PT. KARTIKA BINA MEDIKATAMA**

## TO WHOM IT MAY CONCERN

### *Kepada yang berkepentingan*

This is certify that today Monday, 11 October 2021 Medika Plaza Clinic has performed urine drug screening and/or breath alcohol test to :

*Dengan ini menyatakan bahwa, pada hari ini Senin, 11 Oktober 2021 Medika Plaza Clinic telah melakukan urine drug screening dan/atau breath alcohol test kepada :*


## **ACHMAD CHOIRONI**

With the results are as follows :

*Dengan hasil sebagai berikut :*

<u>Drugs Test</u> <i>Uji Obat</i>	<u>Result</u> <i>Hasil</i>		
<b>URINE DRUGS SCREENING</b>			
- Amphetamine	<input type="checkbox"/> Non-Negative	<input checked="" type="checkbox"/> Negative	<input type="checkbox"/> N/A
- Met-Amphetamine	<input type="checkbox"/> Non-Negative	<input checked="" type="checkbox"/> Negative	<input type="checkbox"/> N/A
- Cocain	<input type="checkbox"/> Non-Negative	<input checked="" type="checkbox"/> Negative	<input type="checkbox"/> N/A
- THC/Canabis/Marijuana	<input type="checkbox"/> Non-Negative	<input checked="" type="checkbox"/> Negative	<input type="checkbox"/> N/A
- Morphine/Opiates	<input type="checkbox"/> Non-Negative	<input checked="" type="checkbox"/> Negative	<input type="checkbox"/> N/A
- P C P/Phencyclidine	<input type="checkbox"/> Non-Negative	<input checked="" type="checkbox"/> Negative	<input type="checkbox"/> N/A
- Barbiturate	<input type="checkbox"/> Non-Negative	<input type="checkbox"/> Negative	<input checked="" type="checkbox"/> N/A
- Benzodiazepin	<input type="checkbox"/> Non-Negative	<input checked="" type="checkbox"/> Negative	<input type="checkbox"/> N/A
- Methadone	<input type="checkbox"/> Non-Negative	<input checked="" type="checkbox"/> Negative	<input type="checkbox"/> N/A
- Propoxyphene	<input type="checkbox"/> Non-Negative	<input type="checkbox"/> Negative	<input checked="" type="checkbox"/> N/A
- Oxycodone	<input type="checkbox"/> Non-Negative	<input type="checkbox"/> Negative	<input checked="" type="checkbox"/> N/A
- MDMA	<input type="checkbox"/> Non-Negative	<input type="checkbox"/> Negative	<input checked="" type="checkbox"/> N/A
- 6-MAM	<input type="checkbox"/> Non-Negative	<input type="checkbox"/> Negative	<input checked="" type="checkbox"/> N/A
<b>BREATH ALCOHOL TEST</b>			
- Alcohol	<input type="checkbox"/> Non-Negative	<input checked="" type="checkbox"/> Negative	<input type="checkbox"/> N/A

Jakarta, October 11, 2021



**PT. KARTIKA BINA MEDIKATAMA**  
( dr. Petty Atmadja, Sp.PK )  
Clinical Patologist

**PT. KARTIKA BINA MEDIKATAMA**

HEAD OFFICE : BELTWAY OFFICE PARK, TOWER C, 2<sup>nd</sup> Floor, Jl. TB. Simatupang Kav 41. Jakarta Selatan 12550, Phone : +62 21 808 66 088, Fax : +62 21 808 66 089

BELTWAY CLINIC : BELTWAY OFFICE PARK, ANNEX BUILDING, Ground Floor, Jl. TB. Simatupang Kav 41. Jakarta Selatan 12550, Phone : +62 21 808 66 099, Fax : +62 21 808 66 098

WTC 2 CLINIC : World Trade Center 2, Lower Ground Floor, Jl. Jend. Sudirman Kav 29. Jakarta Selatan 12920, Phone : +62 21 295 22 611, Fax : +62 21 295 22 610

www.medikaplaza.com

# **HEALTH ASSESSMENT REPORT**

*Of*

**ACHMAD CHOIRONI**

**01035755**

**Monday, 11 October 2021**

## **MP BELTWAY CLINIC**

Beltway Office Park, Annex Building, Ground Floor

Jl. TB. Simatupang Kav.41, Jakarta Selatan 12550

Tlp : (62-21) 808 66 099, Fax : (62-21) 808 66 098

[www.medikaplaza.com](http://www.medikaplaza.com)

## MP BELTWAY CLINIC

Beltway Office Park, Annex Building, Ground Floor  
Jl. TB. Simatupang Kav.41, Jakarta Selatan 12550  
Tlp : (62-21) 808 66 099, Fax : (62-21) 808 66 098  
www.medikaplaza.com

### PATIENT DATA

MedRec.	: 01035755	EMPLOY. STATUS	: Employee
NAME	: ACHMAD CHOIRONI	BIRTHDATE	: 02 March 1983
EMPLOYEE No.	:	SEX	: Male
JOB TITLE	: Inspection Supervisor	STATUS	: Married
COMP. NAME	: INSPEKTINDO SINERGI PERSADA, PT	NASIONALITY	: Indonesia

### SUMMARY

#### MEDICAL FINDING :

1. Hypertriglyceridemia
2. Non reactive anti HBs
3. Abdominal USG: Fatty liver. Left kidney non visualized, suspect left kidney agenesis DD/ ectopic. Advice : CT scan
4. Moderate conductive hearing loss with decreasing on low and high frequency of right ear, Decreasing of hearing acuity on high frequency of left ear
5. Overweight
6. Calculus, stain, decayed and radix teeth


Your fitness status is fit with medical note:

1. Hypertriglyceridemia
2. Moderate conductive hearing loss with decreasing on low and high frequency of right ear
3. Abdominal USG: Left kidney non visualized, suspect left kidney agenesis DD/ ectopic.  
Advice : CT scan

#### SUGGESTION :

1. Low fat and carbohydrate diet, exercise regularly minimal 3 times a week. Consultation with an Internist for further evaluation of Hypertriglyceridemia
2. Need to get Hepatitis B vaccination (booster)
3. Low fat diet and exercise regularly minimum 3x/week. Consultation with an Internist for further evaluation of Abdominal USG: Left kidney non visualized, suspect left kidney agenesis DD/ ectopic. Advice : CT scan
4. Avoid noisy environment or use earplug properly while working at noisy work environment to prevent further hearing impairment. Consultation with an ENT Specialist for further evaluation and examination of Moderate conductive hearing loss with decreasing on low and high frequency of right ear
5. Reduce body weight gradually 0.5 Kgs/week, by doing regular exercise (aerobic/jogging), 3-4x/week, 30-45 minutes and reduce high calorie diet until maximal body weight is 60.84Kgs (present body weight is 72.9Kgs). Consultation with a Nutritionist for evaluation of overweight
6. Consultation with a Dentist for dental care, minimal once a year or better once in six month

#### Responsible Doctor



Yosephine Sumanungkalit, MD

#### Notes:

If you need the further information or consultation, please contact us via :

Email : - beltway.doctor@medikaplaza.com  
- Rezkha.Amalia@medikaplaza.com  
- Puteri.Melati@medikaplaza.com  
Telepon Klinik : (62-21) 8086 6099

PRIVATE

Printed by : nurhasanah



## CLINICAL EVALUATION

Name : ACHMAD CHOIRONI	Sex : Male	MR : 01035755	Visit : 11/10/2021
Comp. : INSPEKTINDO SINERGI PERSADA, PT		DOB : 02 March 1983	

EXAMINATION	RESULT	NOTES
-------------	--------	-------

### ANAMNESA

#### PRESENT COMPLAINT AND HISTORY OF PRESENT

#### ILLNESS

Present complaint

No complaint

#### MEDICAL HISTORY

Alergy	No	
Imunisasi	Yes	
Surgery	Yes	Nose fracture
Hospitalization	No	
Disease	Yes	COVID-19 (June 2021)

#### LIFE STYLE

Alcohol intake	No	
Smoking	Yes	Vaping
Exercise	Yes	Weighlifting, 30 minutes, 5-7x/week

#### FAMILY MEDICAL HISTORY

Diabetes Melitus	Yes	Mother
Hypertension	No	
Heart disease	No	
Lung TB	No	
Kidney disease	No	
Astma	Yes	Father
Mental disease	No	
Epilepsy	No	
Cancer	No	
Color blind	No	
Stroke	No	
Liver disease	No	
Bone & joint	No	
Others disease	No	

#### WORK EXPOSURE

Noise	No	
Heat Stress	No	
Cold Stress	No	
Vibration	No	
Involving height	No	
Radiation	No	
Dust	No	

## CLINICAL EVALUATION

Name : ACHMAD CHOIRONI	Sex : Male	MR : 01035755	Visit : 11/10/2021
Comp.: INSPEKTINDO SINERGI PERSADA, PT		DOB : 02 March 1983	

EXAMINATION	RESULT	NOTES
Toxic chemical	No	
Irritating fluid	No	
Smoke	No	
Bacterium/Virus/Parasite	No	
Blood	No	
Animal	No	
Operating heavy mobile equipment	No	
Manual Handling	No	
Sitting continuously over 4 hours	No	
Stand continuously over 4 hours	No	
Using monitor screen more than 4 hours per day	Yes	
Exposure	No	
Unergonomic body positions	No	
Shift work	No	
Work is not accordance with skills and knowledge	No	
Workload does not accordance with time	No	
Work conflict	No	
Inappropriate task	No	
Career barriers	No	
Family conflict	No	
Working arround rotating machinery	No	
Administration work	Yes	
Handling food product	No	
Others	No	
<b>PHYSICAL EXAMINATION</b>		
General Appearance	Good	
Body shape	Picnicus	
<b>VITAL SIGN</b>		
Body Weight	72.9 Kg	
Body Height	156 Cm	
BMI	29.95 Kg/m2	
Normal Weight	45.02 - 60.84 Kg	
BMI Conclusion	Overweight	
Blood Pressure	120/80 mmHg	
Pulse	78 x/minute	
Body Temperature	36.2 °C	
RR	20	

## CLINICAL EVALUATION

Name : ACHMAD CHOIRONI	Sex : Male	MR : 01035755	Visit : 11/10/2021
Comp.: INSPEKTINDO SINERGI PERSADA, PT		DOB : 02 March 1983	

EXAMINATION	RESULT	NOTES
Neck Circumference	45 Cm	
Arm Circumference	34 Cm	
Chest size	90 Cm	
Abdominal Circumference	84 Cm	
<b>SKIN</b>		
Skin	Normal	
<b>EYE</b>		
Left	Normal	
Right	Normal	
<b>ENT</b>		
Auricle	Normal	
Ear canal	Normal	
Drums	Normal	
Septum/Conchae	Not Examined	
Sinuses	Not Examined	
Pharynx	Not Examined	
Tonsil	Not Examined	
<b>MOUTH</b>		
Gum	Normal	
Dental	Abnormal	Calculus, stain, decayed and radix teeth
<b>NECK</b>		
General	Normal	
Thyroid Gland	Normal	
<b>CHEST</b>		
Form	Normal	
Lung	Normal	
Heart	Normal	
Breast	Normal	
<b>ABDOMEN</b>		
Form	Flat	
Palpation	Supple	
Liver	Not Palpable	
Spleen	Not Palpable	
Kidney	No Ballotment	
-	No	
Hernia inguinal	No	
<b>EXTRIMITIES</b>		

## CLINICAL EVALUATION

Name : ACHMAD CHOIRONI

Sex : Male

MR : 01035755

Visit : 11/10/2021

Comp. : INSPEKTINDO SINERGI PERSADA, PT

DOB : 02 March 1983

EXAMINATION	RESULT	NOTES
Bones, joint	Normal	
Muscles, tonus	Normal	
Fingernails	Normal	
Hand	Normal	
Foot	Normal	
<b>RECTAL EXAMINATION</b>		
Hemorrhoid	Negative	
Rectum	Not Examined	
<b>SENSORIK EXAMINATION</b>		
Tes Raba	Normal	
<b>MOTORIK EXAMINATION</b>		
Tes Grip	Normal	
<b>REFLEX EXAMINATION</b>		
Physiologic reflex	Normal	
Patologic reflex	Normal	
<b>OTHERS EXAMINATION</b>		
Coordination	Normal	
<b>LIMPHE SYSTEM</b>		
Submandibula	Normal	
Neck Gland	Normal	
Armpit gland	Normal	
Inguinal	Normal	
<b>MUSKULOSKLETAL EXAMINATION</b>		
Lhermitte Test	Negative	
Spurling Test	Negative	
Neers Test	Negative	
Yergason Test	Negative	
Phalen Test	Negative	
Tinel Test	Negative	
Finkelstein Test	Negative	
Straight Leg Raise Test	Negative	



## OPHTHALMOLOGY DIAGNOSTIC

Name : ACHMAD CHOIRONI	Sex : Male	MR : 01035755	Visit : 11/10/2021
Comp. : INSPEKTINDO SINERGI PERSADA, PT		DOB : 02 March 1983	

EXAMINATION		Right	Left
Reading		-	
Previous Glasses		-	-
Without Glasses	Distant	20/20	20/20
	Near	J1	J1
Correction	Distant	-	-
	Near	-	-
Depth Perception		-	
Tonometry		12.0 mmHg	14.0 mmHg
Funduscopy		NORMAL	NORMAL
Visual Fields		Normal	
Colour Blind Test		Normal	

Impression :

## RADIOLOGY DIAGNOSTIC

Name : ACHMAD CHOIRONI

Sex : Male

MR : 01035755

Visit : 11/10/2021

Comp.: INSPEKTINDO SINERGI PERSADA, PT

DOB : 02 March 1983

### EXAMINATION

### RESULT

THORAX PA

No abnormality seen in both lungs.  
Normal bronchovascular markings in both hili.  
The heart is normal in size and shape.  
The mediastinum is not widened.  
Both sinus and diaphragms are good.  
No evidence of pleural effusion.  
Right cervical rib.

Impression

Normal heart and lungs.

## RADIOLOGY DIAGNOSTIC

Name : ACHMAD CHOIRONI

Sex : Male

MR : 01035755

Visit : 11/10/2021

Comp.: INSPEKTINDO SINERGI PERSADA, PT

DOB : 02 March 1983

### EXAMINATION

### RESULT

USG ABDOMEN

LIVER:

Normal in size and contour, smooth surface, parenchyme echoes structures increased. No sign of SOL.

Intrahepatic vascularity and billiary tract are normal.

GALL BLADDER:

Normal in size, contour and surface. No sign of SOL/ sludge/ stone.

RIGHT KIDNEY:

Normal in size, contour and surface. Size : 13,5 x 5,7 cm. No sign of obstruction/ stone/ SOL.

LEFT KIDNEY :

Left kidney's echostructure was not visualized.

PANCREAS:

Normal in size, contour and surface. No sign of SOL.

LIEN:

Normal in size and contour, the echoes are homogenous. No sign of SOL.

URINARY BLADDER:

Normal in size, contour and surface. No sign of stone/ SOL.

PROSTATE AND VESICULA SEMINALIS:

Normal in size and contour which are homogenous echoes and no sign of focal lesion/ SOL.

Impression

Fatty liver.

Left kidney non visualized, suspect left kidney agenesis DD/ ectopic. Advice : CT scan.

Other abdominal organs are normal.

**LABORATORY RESULT**

Name : ACHMAD CHOIRONI MR : 01035755 Visit : 11/10/2021 #Lab : IN755929735884

Comp.: INSPEKTINDO SINERGI PERSADA, PT Sex : Male DOB : 02 March 1983

**EXAMINATION****RESULT****NORMAL RANGE****HEMATOLOGI**

ABO/Rh Typing "A" Rh(+) positive

**Automated Blood Count**

White Blood Cell (WBC)	10.5	3.8 - 11.0
Erythrocyte (RBC)	5.3	4.4 - 5.9
Haemoglobin	15.1	13.2 - 17.3
Hematocrit	44	40 - 52
Thrombocytes	310	150 - 440

**MCV, MCH, MCHC**

MCV	84	80 - 100
MCH	29	26 - 34
MCHC	34.1	32 - 36
ESR	28 *	0 - 10

**Differential Count**

Basophils	1	0 - 1
Eosinophil	7 *	2 - 4
Bands / Stab	3	3 - 5
Neutrophils	54	50 - 70
Lymphocytes	28	25 - 40
Monocytes	7	2 - 8

**BLD CHEMISTRY/LIPID PROFILE**

Total Cholesterol	150	Normal/Desireable: <200 Borderline High: 200-239 High: >=240
HDL Cholesterol	40.5	Normal : >40 - <60 Low HDL : <40 Desireable : >=60
LDL Cholesterol	37	Optimal: <100 Near/Above Optimal: 100-129 Borderline High: 130-159 High: 160-189 Very High: >=190
Triglycerides	362 *	Normal : <150 Borderline High: 150-199 High : 200-499 Very High : >=500

**BLD CHEMISTRY/KIDNEY FUNCTION**

**LABORATORY RESULT**

Name : ACHMAD CHOIRONI MR : 01035755 Visit : 11/10/2021 #Lab : IN755929735884

Comp. : INSPEKTINDO SINERGI PERSADA, PT Sex : Male DOB : 02 March 1983

EXAMINATION	RESULT	NORMAL RANGE
Ureum	29.3	10.0 - 50.0
Creatinine	0.95	0.60 - 1.30
Uric Acid	7.19	3.50 - 7.20

**BLD CHEMISTRY/LIVER FUNCTION**

Total Bilirubin	0.70	0.1 - 1.0
Direct Bilirubin	0.05	0.0 - 0.2
Indirect Bilirubin	0.65	0.0 - 0.8
SGOT(AST)	23	13 - 45
SGPT (ALT)	33	13 - 50
Alkaline Phosphatase	45	30 - 120
Gamma GT	28	0 - 50
Albumin	4.6	3.5 - 5.5
Globulin	2.40	2.3 - 3.5
Total Protein	7.0	6.6 - 8.7

**BLD CHEMISTRY/DIABETES**

Glucose Fasting	83	< 100
Glucose Urine	Negative	Negative
Keton Urine	Negative	Negative

**Blood Glucose 2 PP**

Blood Sugar 2 Hours PP	82	< 140
Glucose Urine	Negative	Negative
Keton Urine	Negative	Negative

**SEROLOGI / IMUNOLOGI**

HBsAg (Quantitative)	0.00	0.00 - 0.03
Anti Hbs (Quantitative)	0.1 *	>= 5.0

**TOXICOLOGY - DRUGS SCREENING**

Methadone	Negative	Negative
Phencyclidine	Negative	Negative
THC/Marijuana	Negative	Negative
Amphetamine	Negative	Negative
Benzodiazepines	Negative	Negative
Opiat	Negative	Negative
Cocain	Negative	Negative
Metamphetamine	Negative	Negative
Alcohol	Negative	Negative

**URINALYSIS****Complete Urine Analysis**



## LABORATORY RESULT

Name : ACHMAD CHOIRONI	MR : 01035755	Visit : 11/10/2021	#Lab : IN755929735884
------------------------	---------------	--------------------	-----------------------

Comp.: INSPEKTINDO SINERGI PERSADA, PT	Sex : Male	DOB : 02 March 1983
--	------------	---------------------

EXAMINATION	RESULT	NORMAL RANGE
-------------	--------	--------------

### Macroscopic

Color	Light Yellow	
Turbidity	Clear	Clear
Specific Gravity	1.021	1.000 - 1.030
pH	5.5	4.5 - 8.0
Leucocyte	Negative	Negative
Glucose	Negative	Negative
Nitrit	Negative	Negative
Bilirubin	Negative	Negative
Blood	Negative	Negative
Urobilinogen	Normal	Normal
Protein	Negative	Negative
Keton	Negative	Negative

### Microscopic

RBC	0-1	0 - 1
WBC	0-1	0 - 4
Cylinder	Negative	
Epithels Squamous	0-1	5 - 15
Crystals	Negative	
Bacteria	Negative	Negative
Others	Negative	

## STOOL / RECTAL SWAP

### Faeces Complete

#### Macroscopic

Color	Brown	
Consistency	Smooth	
Mucus	Negative	Negative
Blood	Negative	Negative
Pus	Negative	Negative
Parasit	Negative	Negative
Lipid	Negative	Negative

#### Microscopic

RBC	0-1	0 - 1
WBC	0-1	0 - 5
Amoeba	Negative	
Ephitels	Positive	Positive
Worm Eggs	Negative	Negative

**LABORATORY RESULT**

Name : ACHMAD CHOIRONI	MR : 01035755	Visit : 11/10/2021	#Lab : IN755929735884
------------------------	---------------	--------------------	-----------------------

Comp.: INSPEKTINDO SINERGI PERSADA, PT	Sex : Male	DOB : 02 March 1983
--	------------	---------------------

EXAMINATION	RESULT	NORMAL RANGE
Yeast	Negative	Negative
Muscle Fiber	Negative	Negative
Others	Negative	Negative
<b>Digestive</b>		
Amylum	Negative	Negative
Fat	Negative	
Fibers	Positive	Positive

# AUDIOMETRY DIAGNOSTIC

Name : ACHMAD CHOIRONI

Sex : Male

MR : 01035755

Visit : 11/10/2021

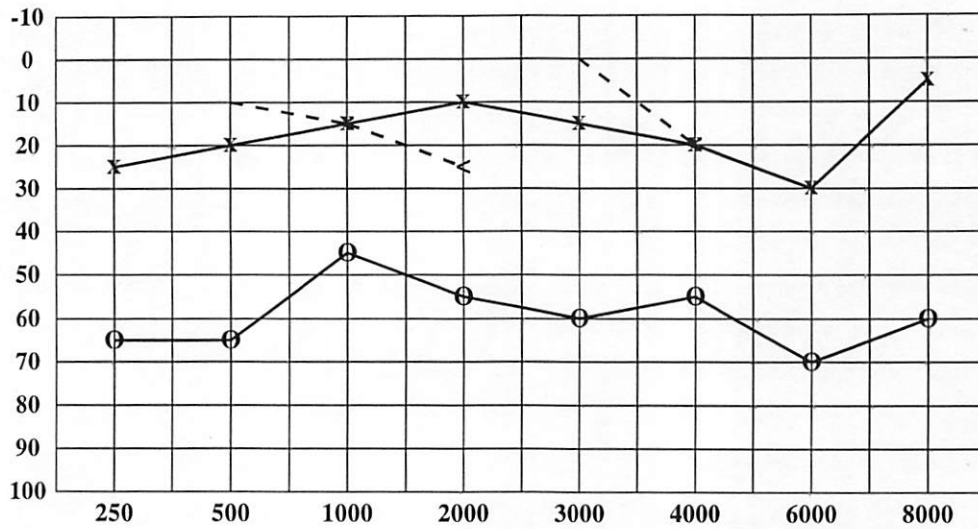
Comp.: INSPEKTINDO SINERGI PERSADA, PT

DOB : 02 March 1983

## RESULT

Left Ear	250	500	1000	2000	3000	4000	6000	8000
AC	25	20	15	10	15	20	30	5
BC	-	-	-	-	-	-	-	-

Right Ear	250	500	1000	2000	3000	4000	6000	8000
AC	65	65	45	55	60	55	70	60
BC	-	10	15	25	-	20	-	-



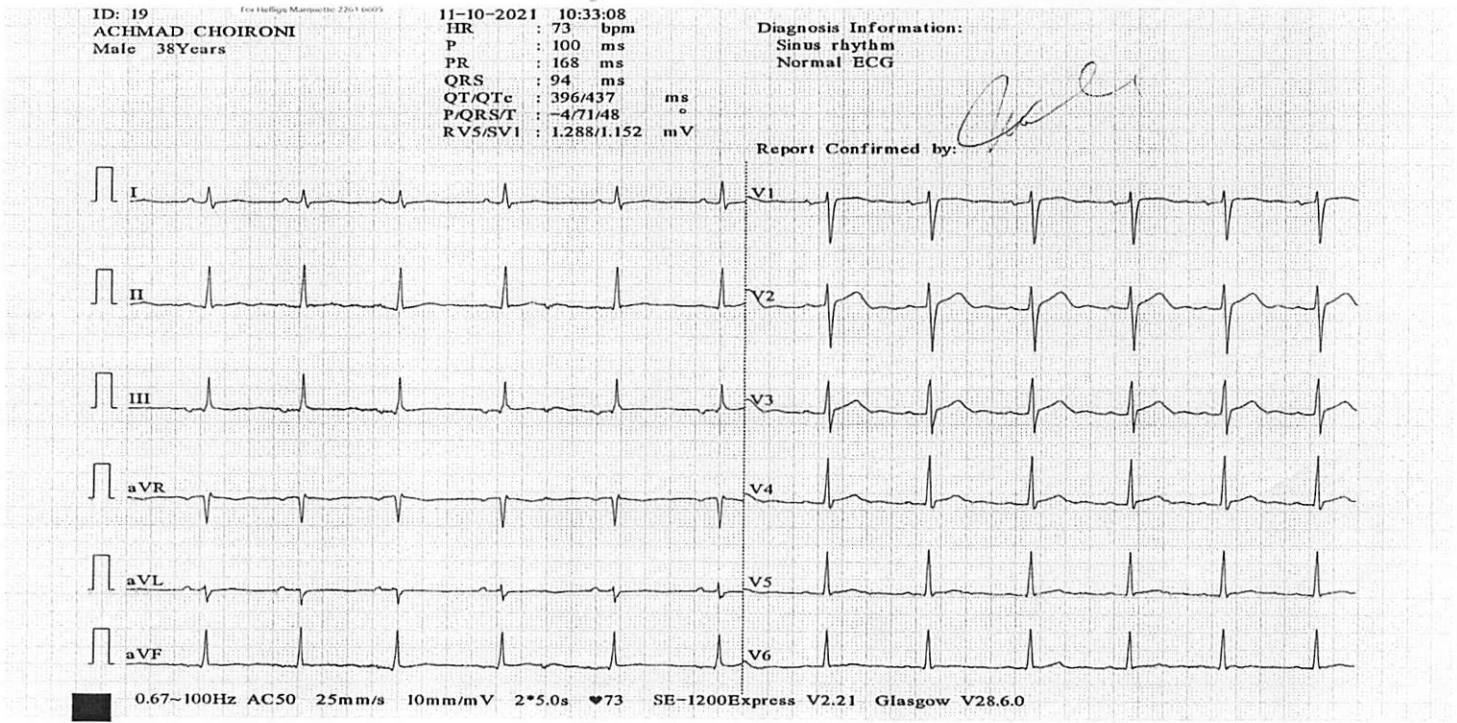
Conclusion Right Ear : Moderate conductive hearing loss = 55 dB  
 With decreasing on frequency  
 250Hz, 4000Hz, 6000Hz, 8000Hz

Conclusion Left Ear : Hearing threshold = 16.25 dB  
 (Within normal limit)  
 With decreasing on frequency 6000Hz

# CARDIOLOGY DIAGNOSTIC

Name : ACHMAD CHOIRONI	Sex : Male	MR : 01035755	Visit : 11/10/2021
Comp.: INSPEKTINDO SINERGI PERSADA, PT		DOB : 02 March 1983	

EXAMINATION	RESULT	Comments :
ELECTROCARDIOGRAPHY	Sinus Rythm axis ( N ), P wave ( N ), PR int 0.16" ST - T segment ( N ), aritmia (-)	Normal ECG
TREADMILL	Sinus Rythm axis ( N ), P wave ( N ), PR int 0.16" ST - T segment ( N ), aritmia (-)	Treadmill Exercise Test : Negative Cardiopulmonary Fitness Classification : Good METs : 13.4







# ACHMAD CHOIRONI, Mr

ID: 01035755, Born: 3/2/1983 (Male 38), 72 kg, 156 cm  
Test Date: 10/11/2021 9:37:50 AM

MEDIKA PLAZA

## Patient info

orn: 3/2/1983  
ge: 38  
ex: Male  
Veight: 72 kg  
leight: 156 cm  
moker:  
acemaker:

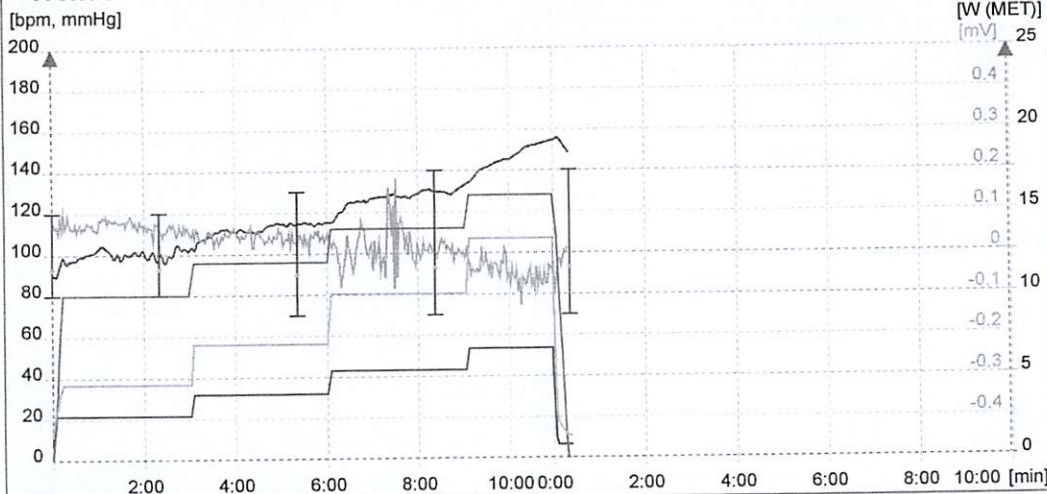
## Medical history

## Medications

## Reason for admission

## Reason for Stop

## Trends



## Conclusion

*[Handwritten signature]*  
 PT. KARTIKA BINA MEDICAL ATAMA

## Staff

Physician: user  
Technician:

## Test info

Test date: 10/11/2021  
 Test time: 9:37 AM  
 Stress device: BTL Treadmill  
 Protocol: Bruce  
 Total duration: 10:57  
 Stress achieved: 6.7km/h, 16.0% (~13.4MET) = 110% predicted (~12.3MET) - for 144 sec  
 HR rest: 87  
 HR peak: 154 = 85% predicted (181) -- 10:5 Exercise (13.4MET)  
 Handgrip test: --  
 BP rest: 120/80  
 BP peak: --  
 BP recovery: 140/70  
 DP rest: 10440  
 DP peak: 18143 = 1.7x DP at rest  
 ST depression max: aVR -0.35mV 07:13 Exercise 10.1MET  
 ST elevation max: V3 0.38mV 08:05 Exercise 10.1MET  
 ST/HR index: 2.6  $\mu$ V/bpm (abnormal)





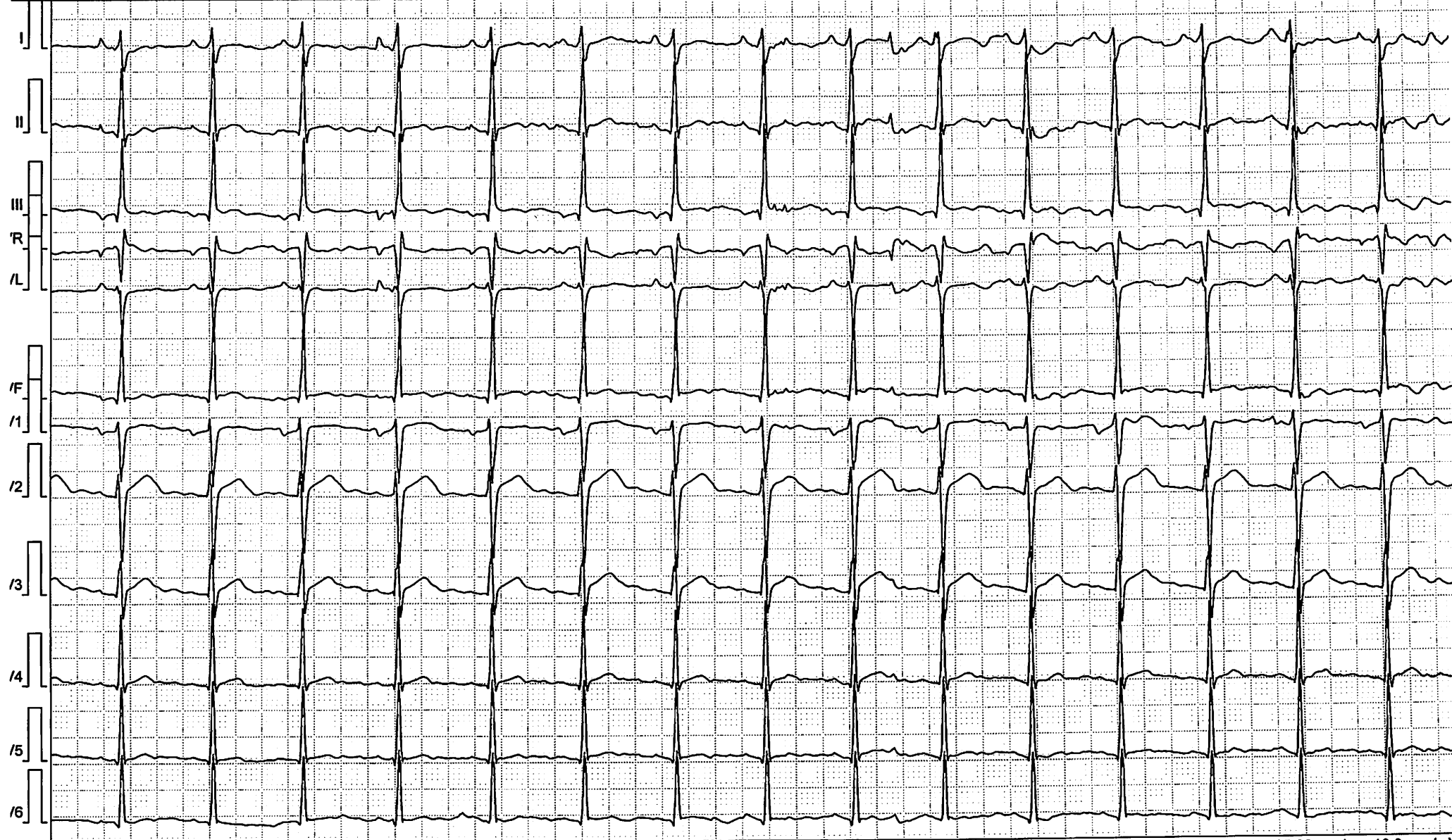
**ACHMAD CHOIRONI, Mr**

ID: 01035755, Born: 3/2/1983 (Male 38), 72 kg, 156 cm  
Test Date: 10/11/2021 9:37:50 AM

MEDIKA PLAZA

Time: P 00:51 - Reference

Load: 1.4MET, HR: 87bpm, BP: 120/80



Filter: 0.07 Spline - 90 Adapt, ~50 [Hz]

25.00 mm/sec 10.0 mm/mV



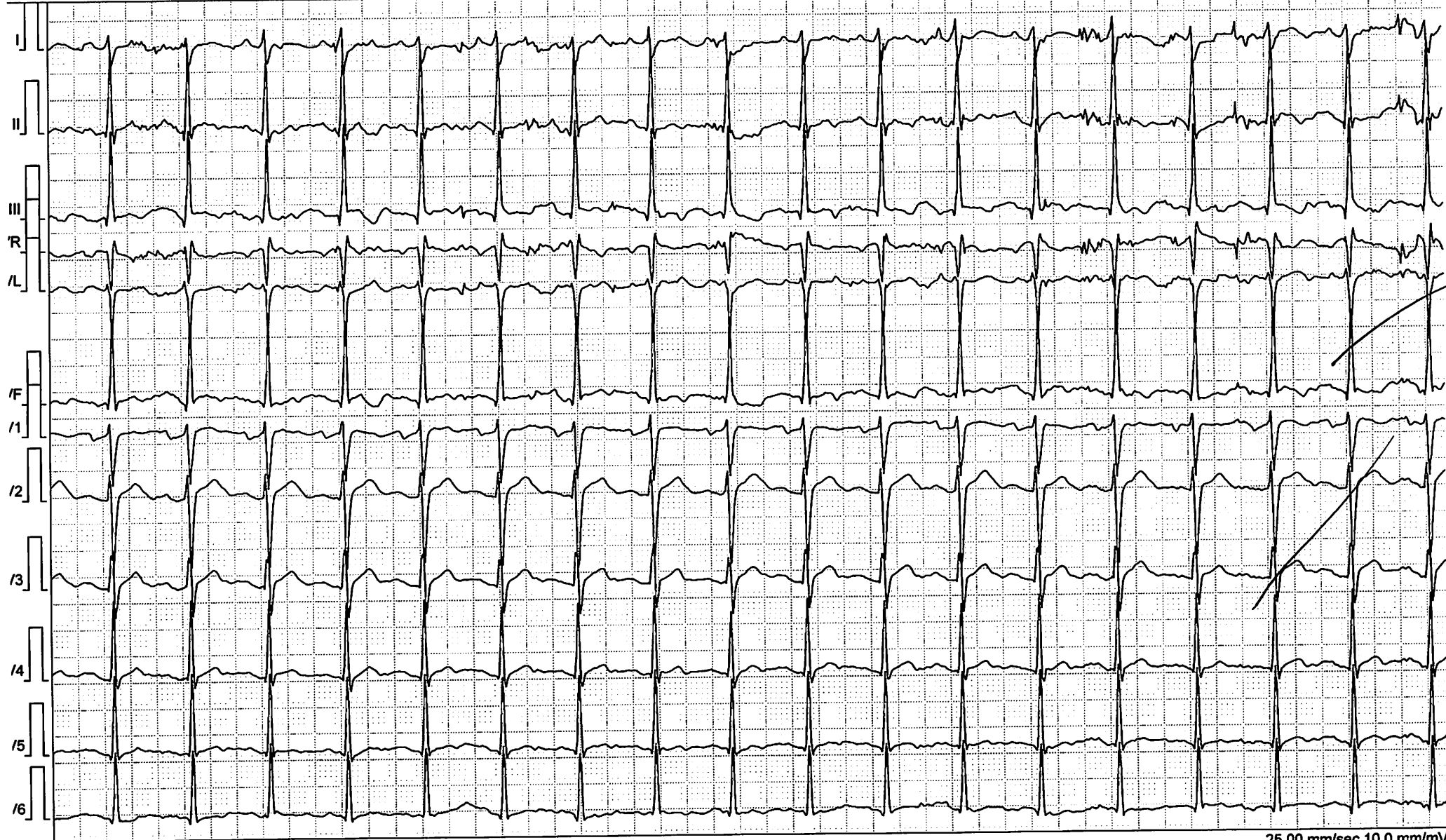
**ACHMAD CHOIRONI, Mr**

ID: 01035755, Born: 3/2/1983 (Male 38), 72 kg, 156 cm  
Test Date: 10/11/2021 9:37:50 AM

MEDIKA PLAZA

Time: E 02:56 - E1

Load: 4.6MET, HR: 103bpm, BP: 120/80



25.00 mm/sec 10.0 mm/mV

Filter: 0.07 Spline - 90 Adapt, ~50 [Hz]



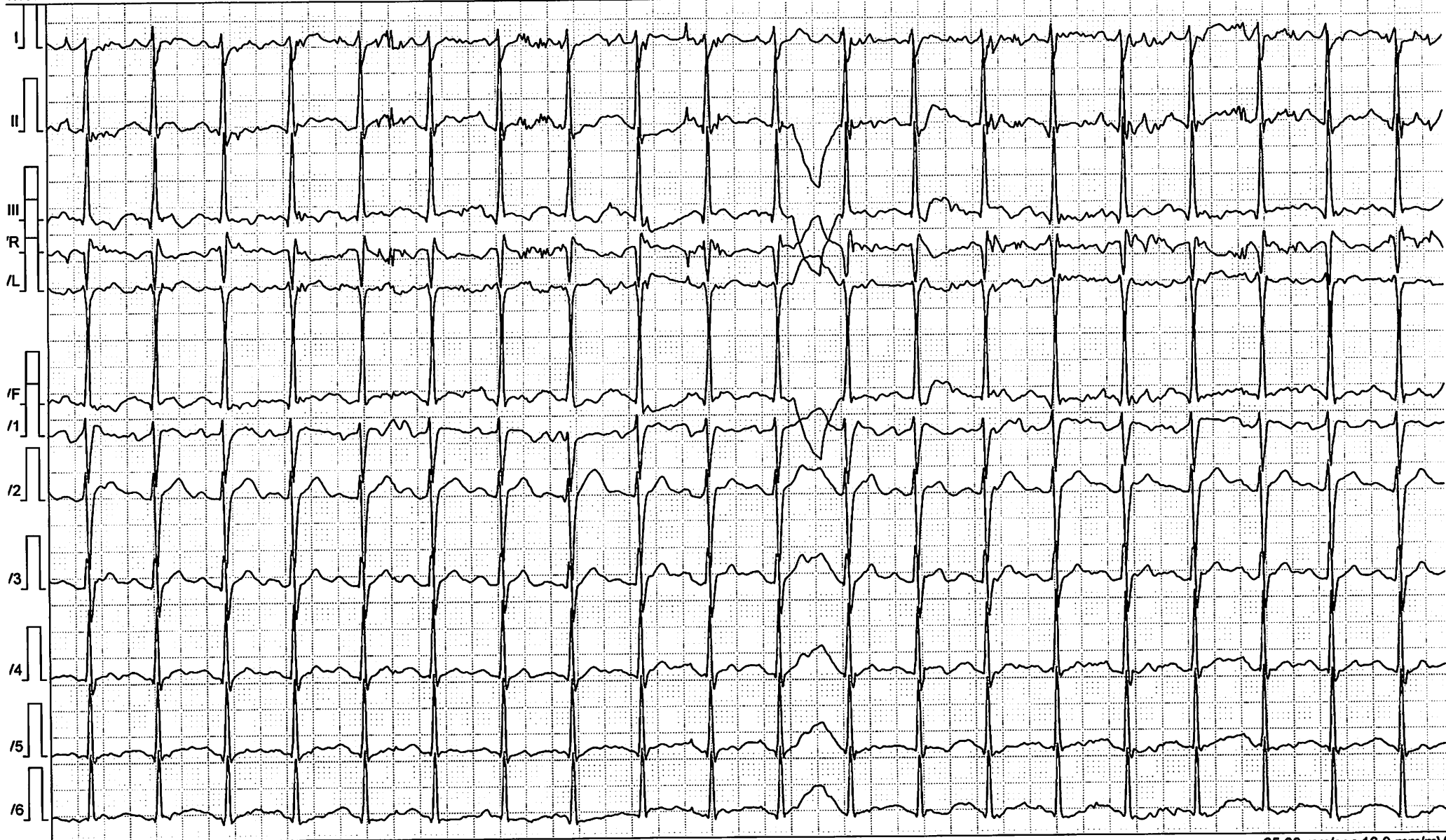
**ACHMAD CHOIRONI, Mr**

ID: 01035755, Born: 3/2/1983 (Male 38), 72 kg, 156 cm  
Test Date: 10/11/2021 9:37:50 AM

MEDIKA PLAZA

Time: E 05:57 - E2

Load: 7.0MET, HR: 115bpm, BP: 130/70



Filter: 0.07 Spline - 90 Adapt, ~50 [Hz]

25.00 mm/sec 10.0 mm/mV



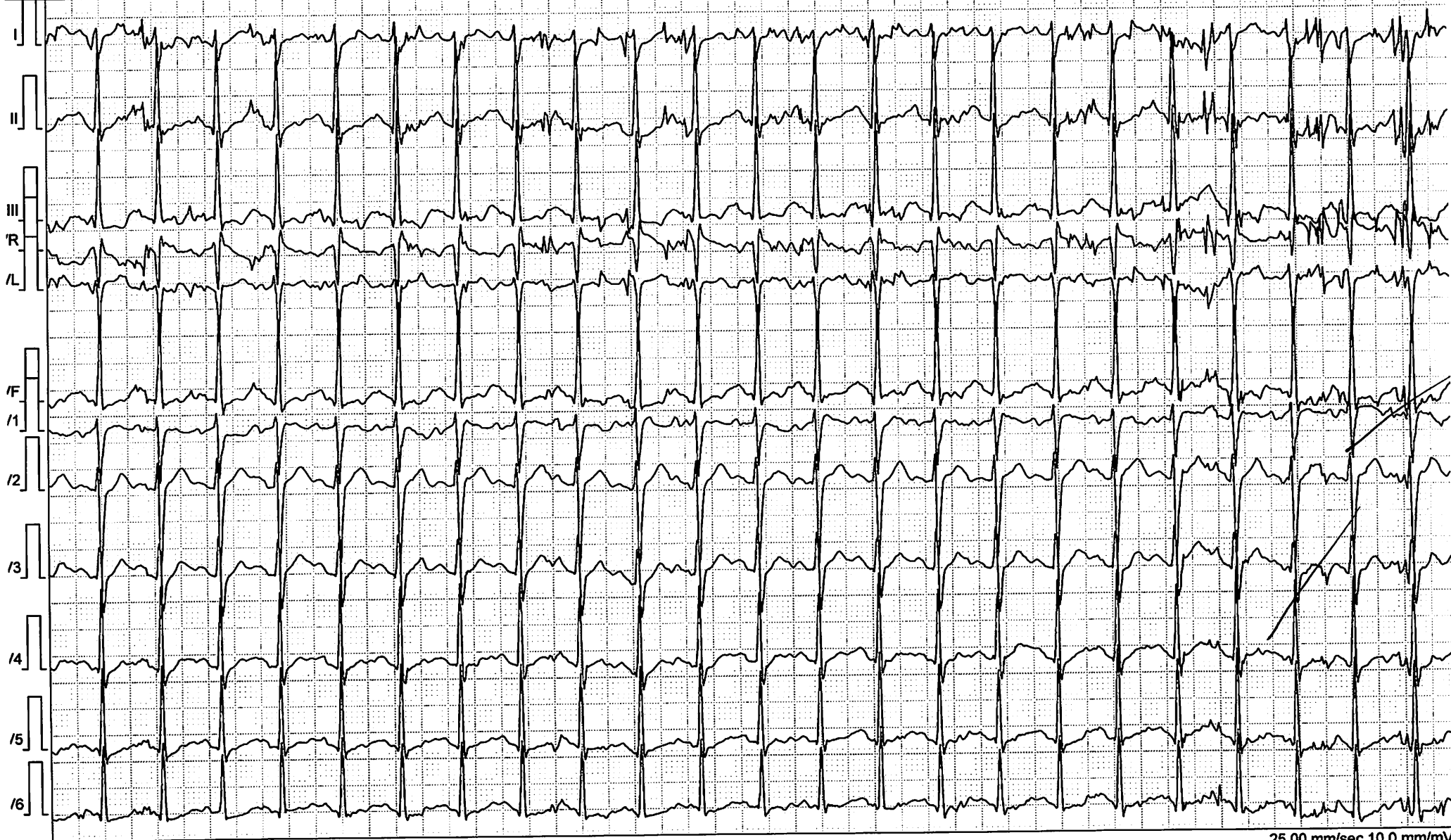
**ACHMAD CHOIRONI, Mr**

ID: 01035755, Born: 3/2/1983 (Male 38), 72 kg, 156 cm  
Test Date: 10/11/2021 9:37:50 AM

MEDIKA PLAZA

Time: E 08:58 - E3

Load: 10.1MET, HR: 133bpm, BP: 140/70



25.00 mm/sec 10.0 mm/mV

Filter: 0.07 Spline - 90 Adapt, ~50 [Hz]



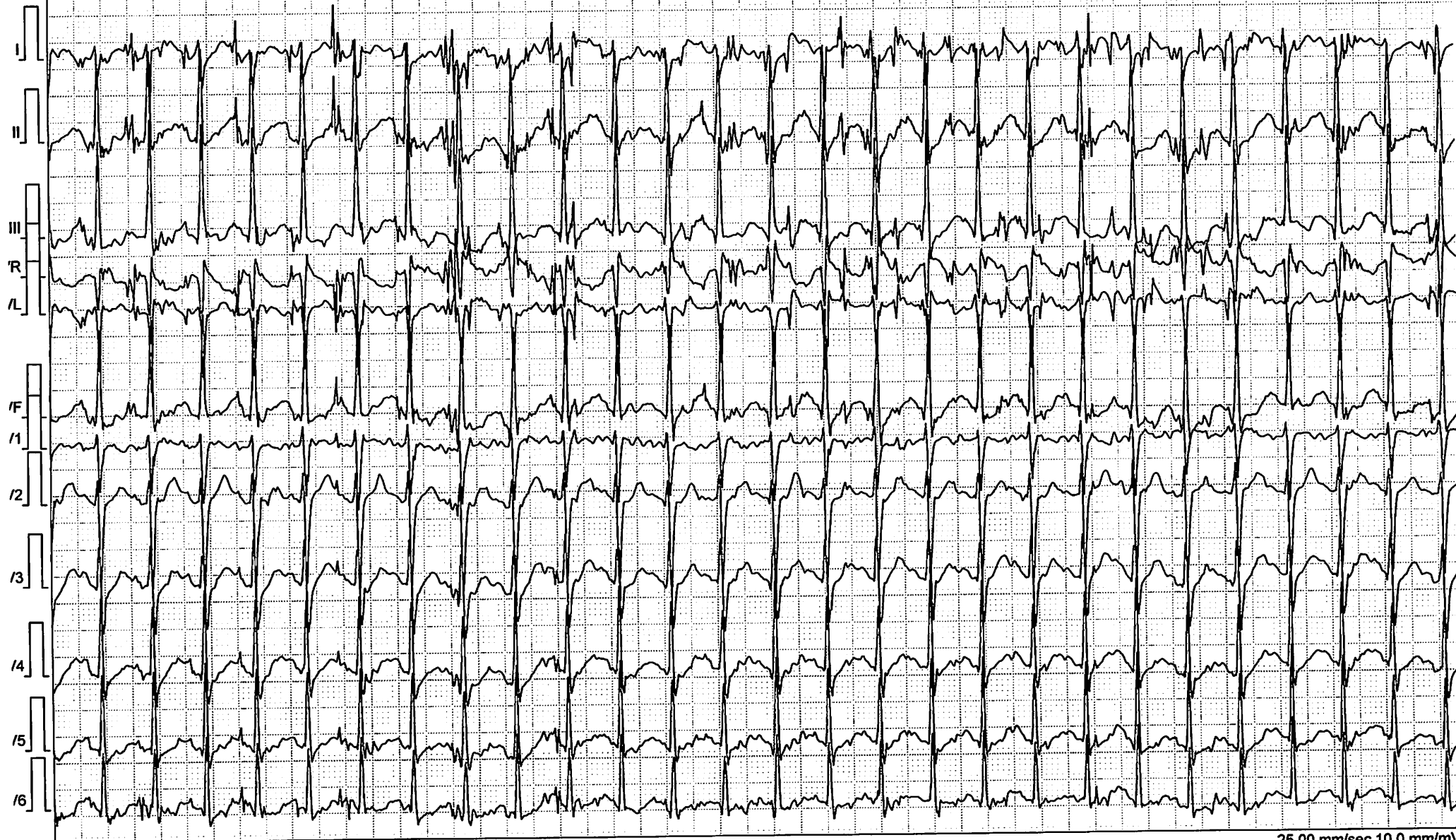
**ACHMAD CHOIRONI, Mr**

ID: 01035755, Born: 3/2/1983 (Male 38), 72 kg, 156 cm  
Test Date: 10/11/2021 9:37:50 AM

MEDIKA PLAZA

Time: E 10:53 - Peak

Load: 13.4MET, HR: 155bpm, BP: -



25.00 mm/sec 10.0 mm/mV

Filter: 0.07 Spline - 90 Adapt, ~50 [Hz]





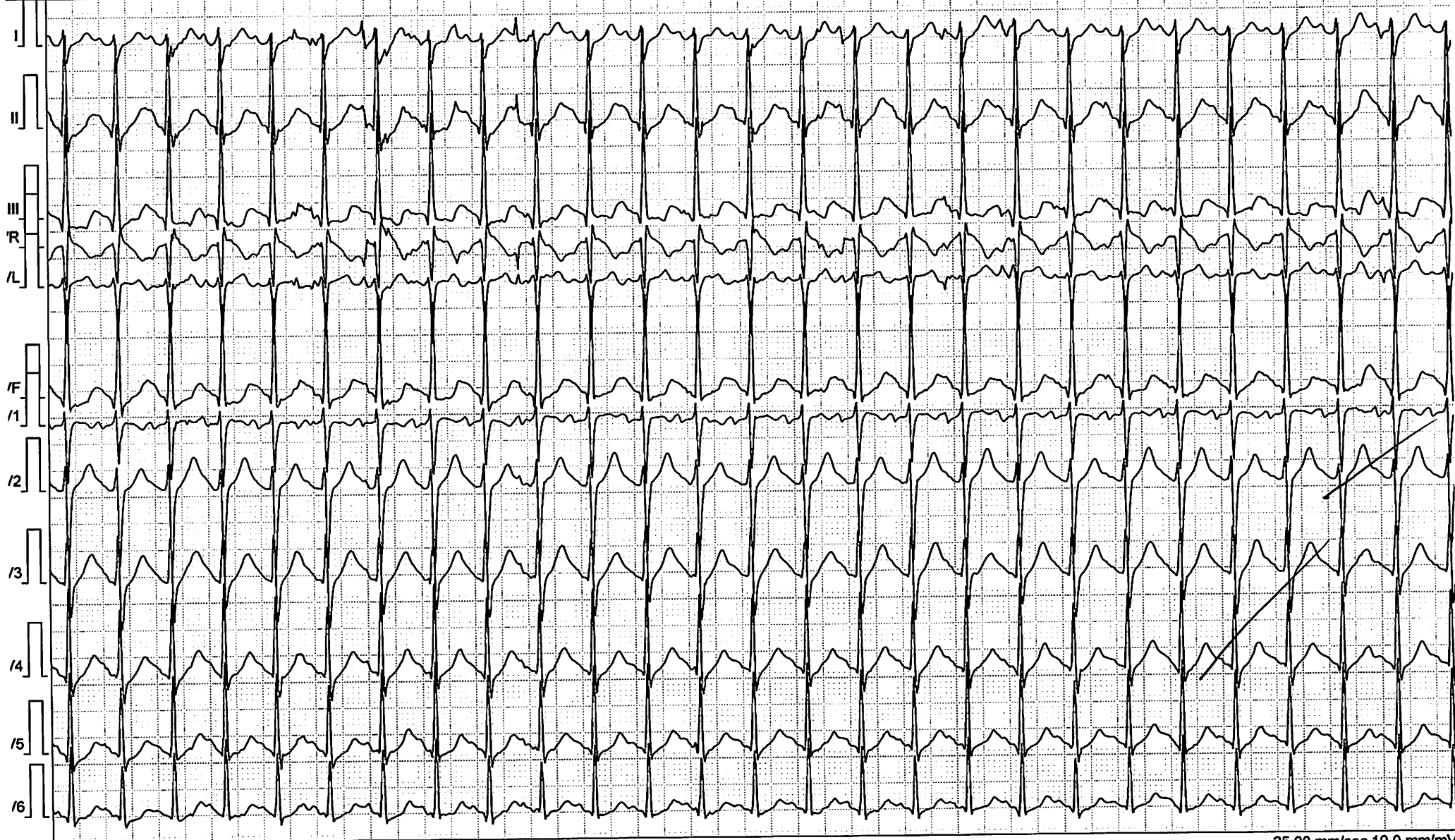
**ACHMAD CHOIRONI, Mr**

ID: 01035755, Born: 3/2/1983 (Male 38), 72 kg, 156 cm  
Test Date: 10/11/2021 9:37:50 AM

MEDIKA PLAZA

Time: R 00:10 - Recovery

Load: 1.7MET, HR: 152bpm, BP: 140/70



Filter: 0.07 Spline - 90 Adapt, ~50 [Hz]

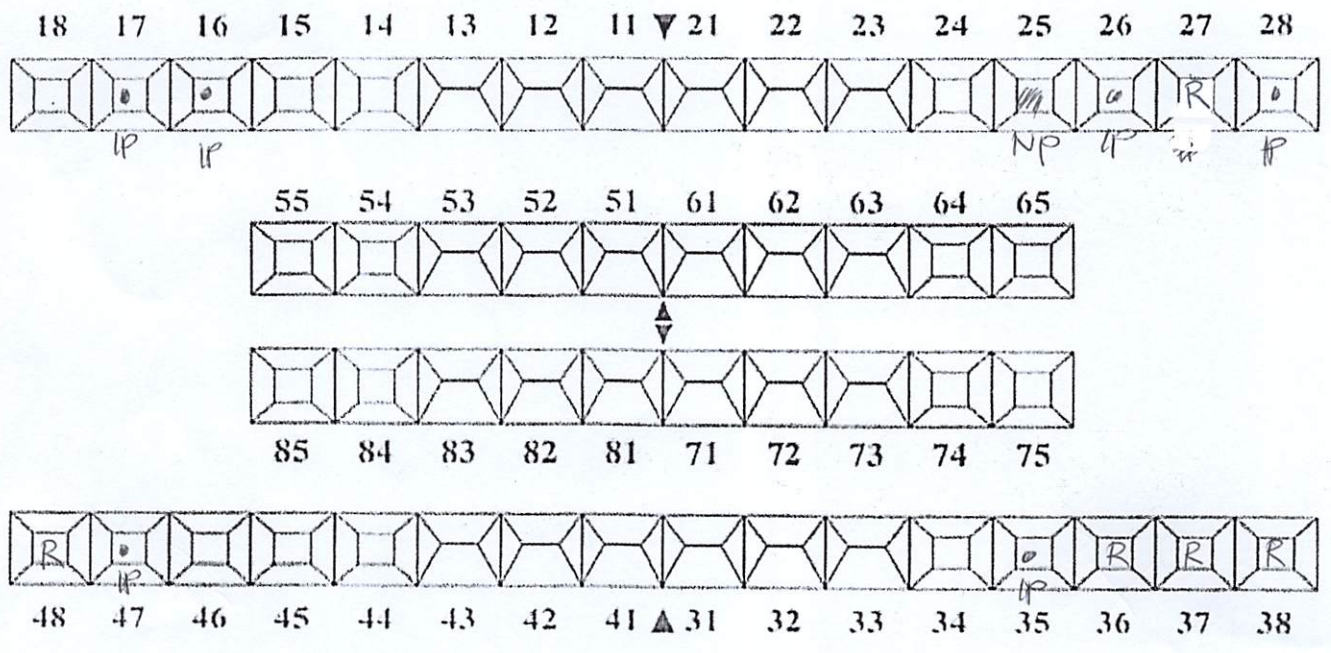
25.00 mm/sec 10.0 mm/mV

**ACHMAD CHOIRONI, Mr**ID: 01035755, Born: 3/2/1983 (Male 38), 72 kg, 156 cm  
Test Date: 10/11/2021 9:37:50 AM

MEDIKA PLAZA

Stage	Time	Load			HR bpm	BP mmHg	SpO2 %	ST Level [ mV ], J+: 1/8RR											
		km/h	%	MET				I	II	III	aVR	aVL	aVF	V1	V2	V3	V4	V5	V6
Reference	E 00:03	0.8	0.0	1.4	<b>87</b>	120/80	-	0.05	0.13	0.07	-0.09	-0.01	0.10	0.10	0.31	0.26	0.14	0.08	0.03
E 1 stage	E 03:01	2.7	10.0	4.6	<b>102</b>	120/80	-	0.03	0.07	0.04	-0.05	-0.01	0.06	0.07	0.24	0.22	0.12	0.05	0.00
E 2 stage	E 06:02	4.0	12.0	7.0	<b>115</b>	130/70	-	0.06	0.08	0.01	-0.07	0.02	0.04	0.07	0.25	0.21	0.12	0.05	0.04
E 3 stage	E 09:03	5.4	14.0	10.1	<b>132</b>	140/70	-	0.34	0.24	-0.01	-0.35	0.12	0.11	0.08	0.24	0.20	0.12	-0.02	0.03
E 4 stage	E 10:01	6.7	16.0	13.4	<b>145</b>	-	-	0.07	-0.08	-0.07	0.01	0.08	-0.04	0.04	0.04	0.09	0.05	-0.05	-0.06
E 4 peak	E 10:58	6.7	16.0	13.4	<b>154</b>	-	-	0.02	0.01	-0.03	-0.02	0.02	-0.01	0.01	0.17	0.08	-0.02	-0.04	-0.10
Recovery	R 00:20	0.8	16.0	2.5	<b>152</b>	140/70	-	0.06	0.01	-0.05	-0.01	0.05	-0.01	0.07	0.15	0.15	0.07	0.01	0.01

DENTAL EXAMINATION			
Name : Achmad Choironi	Sex : M / F	MR :	Visit : 11/10 21
Comp. : Inspektindo Sinergi	DOB : .....		
ODONTOGRAM			



DIAGNOSA

Calculus dan stain +3  
 17, 16, 26, 28, 35, 47 = caries  
 25 = nekrose  
 27, 36, 37, 38, 48 = radix

TREATMENT PLANNING

scaling all regio  
 17, 16, 26, 28, 35, 47 = filling  
 25 = exo.  
 27, 36, 37, 38, 48 = exo.

Verified by: drg. Ilona Amalia / drg. Fajar Sulawati / drg. Siti Darjah / drg. Herlina





**CONSULTATION  
SHEET**

PATIENT NAME : Tn. Achmad Choirani  
No. RM : 01.035755  
Klinik/MCU/HCU : ENT

To. Dokter :  
(Counsel)

Kindly please counsel for patient who has take cares of

Diagnose :  
Clinik Summary :

Counsel Request :

**COUNSEL ADVISE**

Finding :

Diagnosis :

Recomendation :

Ear. Tympanic memel Intact. No Scarbe

Nose : Conk edging, noseambe.

throat = T<sub>2</sub> T<sub>2</sub> with lymph.

Audimely : Moderate Hany loss 55dB Right ear  
Normal Hany thuch 16.5dB Left ear

Chronic transllha, Moderate hany loss.

Date : 11 / 10 / 2021

Time :

EP :

- Stop Smoko

- Use ear protection  
when working in noisy Area

Signature

**MD**  
Dr. MERISTIANA CHRISTIANE, Sp.THT-KL  
SIP: 1316.156731-1779.3/6/2018

PT. KARTIKA BINA MEDIKA  
Complete Name