

**Certificate Of Health Assessment**


Name	Age	Position	Department
ALIMUSA SIAGIAN	41 yo	INSPECTOR	INSPECTION

**COMPANY :**

**INSPEKTINDO SINERGI PERSADA**

**CONCLUSION**

Fit for work to the job described	
Fit with Medical Note (Restriction and/or Limitation)	✓
Unfit for work to the job described	

Date	Doctors Name	Signature
23 January 2018	Maria Erlin, MD	 <b>MP+</b> PT. KARTIKA BINA MEDIKATAMA

No. Formulir : FM-DR-008-05  
 No. Revisi : 00  
 Tanggal Terbit : 2 Mei 2011

## TO WHOM IT MAY CONCERN

### *Kepada yang berkepentingan*

This is certify that today Tuesday, 23 January 2018 Medika Plaza Clinic has performed urine drug screening and/or breath alcohol test to :

*Dengan ini menyatakan bahwa, pada hari ini Selasa, 23 Januari 2018 Medika Plaza Clinic telah melakukan urine drug screening dan/atau breath alcohol test kepada :*

## ALIMUSA SIAGIAN

With the results are as follows :  
*Dengan hasil sebagai berikut :*

Drugs Test <i>Uji Obat</i>	Result <i>Hasil</i>		
<b>URINE DRUGS SCREENING</b>			
- Amphetamine	<input type="checkbox"/> Non-Negative	<input checked="" type="checkbox"/> Negative	<input type="checkbox"/> N/A
- Met-Amphetamine	<input type="checkbox"/> Non-Negative	<input type="checkbox"/> Negative	<input checked="" type="checkbox"/> N/A
- Cocain	<input type="checkbox"/> Non-Negative	<input checked="" type="checkbox"/> Negative	<input type="checkbox"/> N/A
- THC/Canabis/Marijuana	<input type="checkbox"/> Non-Negative	<input checked="" type="checkbox"/> Negative	<input type="checkbox"/> N/A
- Morphine/Opiates	<input type="checkbox"/> Non-Negative	<input checked="" type="checkbox"/> Negative	<input type="checkbox"/> N/A
- P C P/Phencyclidine	<input type="checkbox"/> Non-Negative	<input type="checkbox"/> Negative	<input checked="" type="checkbox"/> N/A
- Barbiturate	<input type="checkbox"/> Non-Negative	<input type="checkbox"/> Negative	<input checked="" type="checkbox"/> N/A
- Benzodiazepin	<input type="checkbox"/> Non-Negative	<input type="checkbox"/> Negative	<input checked="" type="checkbox"/> N/A
- Methadone	<input type="checkbox"/> Non-Negative	<input type="checkbox"/> Negative	<input checked="" type="checkbox"/> N/A
- Propoxyphene	<input type="checkbox"/> Non-Negative	<input type="checkbox"/> Negative	<input checked="" type="checkbox"/> N/A
- Oxycodone	<input type="checkbox"/> Non-Negative	<input type="checkbox"/> Negative	<input checked="" type="checkbox"/> N/A
- MDMA	<input type="checkbox"/> Non-Negative	<input checked="" type="checkbox"/> Negative	<input type="checkbox"/> N/A
- 6-MAM	<input type="checkbox"/> Non-Negative	<input type="checkbox"/> Negative	<input checked="" type="checkbox"/> N/A
<b>BREATH ALCOHOL TEST</b>			
- Alcohol	<input type="checkbox"/> Non-Negative	<input checked="" type="checkbox"/> Negative	<input type="checkbox"/> N/A

Jakarta, January 23, 2018

  
**PT. KARTIKA BINA MEDIKATAMA**  
 Clinical Patologist

## MP BELTWAY CLINIC

Beltway Office Park, Annex Building, Ground Floor  
Jl. TB. Simatupang Kav.41, Jakarta Selatan 12550  
Tlp : (62-21) 808 66 099, Fax : (62-21) 808 66 098  
www.medikaplaza.com

### PATIENT DATA

MedRec.	: 01015394	EMPLOY. STATUS	: Employee
NAME	: ALIMUSA SIAGIAN	BIRTHDATE	: 15 October 1976
EMPLOYEE No.	:	SEX	: Male
JOB TITLE	: INSPECTOR	STATUS	: Married
COMP. NAME	: INSPEKTINDO SINERGI PERSADA	NASIONALITY	: Indonesia

### SUMMARY


#### MEDICAL FINDING :

1. Non reactive anti HBs
  2. LV Strain ec HHD + VES on ECG and Treadmill test
  3. USG : Multiple small polyps of gallbladder. No sign of stone
  4. Overweight
  5. Perforation of right ear drum
  6. Decreasing of hearing acuity at high frequency of left ear
  7. Radix, missing, decayed, calculus teeth
- Your fitness status is fit with medical note :
1. LV Strain ec HHD + VES on ECG and Treadmill test
  2. USG : Multiple small polyps of gallbladder. No sign of stone

#### SUGGESTION :

1. Need to get Hepatitis B vaccination
2. Consult to a Cardiologist for evaluation of LV Strain ec HHD + VES on ECG and Treadmill test
3. Consult to an Internist for evaluation of USG : Multiple small polyps of gallbladder. No sign of stone
4. Reduce body weight gradually 0.5 Kgs/week, by doing regular exercise (aerobic/jogging), 3-4x/week, 30-45 minutes and reduce high calorie diet until maximal body weight is 64.80 Kgs (present body weight is 68.30 Kgs)
5. See an ENT specialist for treatment of Perforation of right ear drum
6. Avoid noisy environment or use earplug properly while working at noisy work environment to prevent further hearing impairment
7. See a dentist for dental care minimal once a year or better once in 6 months

#### Responsible Doctor

  
Maria Erlin, MD

#### Notes:

If you need the further information or consultation, please contact us via :

Email : - dr.Meiwulandari@medikaplaza.com  
- dr.yosephine@medikaplaza.com

Telepon Klinik : (62-21) 295 22 610

PRIVATE

Printed by : vicka l



## CLINICAL EVALUATION

Name : ALIMUSA SIAGIAN		Sex : Male	MR : 01015394	Visit : 23/01/2018
Comp.: INSPEKTINDO SINERGI PERSADA			DOB : 15 October 1976	
EXAMINATION	RESULT	NOTES		

### ANAMNESIS

#### PRESENT COMPLAINT AND HISTORY OF PRESENT

#### ILLNESS

Present complaint

No complaint

#### MEDICAL HISTORY

Alergy	No
Imunisasi	Yes
Surgery	No
Hospitalization	No
Disease	No

#### LIFE STYLE

Alcohol intake	No
Smoking	No
Exercise	Yes

Running 3x/week

#### FAMILY MEDICAL HISTORY

Diabetes Melitus	No
Hypertension	No
Heart disease	No
Lung TB	No
Kidney disease	No
Astma	No
Mental disease	No
Epilepsy	No
Cancer	No
Color blind	No
Stroke	No
Liver disease	No
Bone & joint	No
Others disease	No

#### WORK EXPOSURE

Noise	Yes
Heat Stress	Yes
Cold Stress	No
Vibration	No
Involving height	Yes
Radiation	No
Dust	Yes

## CLINICAL EVALUATION

Name : ALIMUSA SIAGIAN	Sex : Male	MR : 01015394	Visit : 23/01/2018
Comp. : INSPEKTINDO SINERGI PERSADA		DOB : 15 October 1976	

EXAMINATION	RESULT	NOTES
Toxic chemical	No	
Iritating fluid	No	
Smoke	Yes	
Bacterium/Virus/Parasite	No	
Blood	No	
Animal	No	
Operating heavy mobile equipment	No	
Manual Handling	No	
Sitting continuously over 4 hours	No	
Stand continuously over 4 hours	No	
Using monitor screen more than 4 hours per day	No	
Exposure	No	
Unergonomic body positions	No	
Shift work	No	
Work is not accordance with skills and knowledge	No	
Workload does not accordance with time	No	
Work conflict	No	
Inappropriate task	No	
Career barriers	No	
Family conflict	No	
Working arround rotating machinery	No	
Administration work	No	
Handling food product	No	
Others	No	
<b>PHYSICAL EXAMINATION</b>		
General Appearance	Good	
Body shape	Athleticus	
<b>VITAL SIGN</b>		
Body Weight	68.3 Kg	
Body Height	161 Cm	
BMI	26.34 Kg/m2	
Normal Weight	47.95 - 64.80 Kg	
BMI Conclusion	Overweight	
Blood Pressure	110/80 mmHg	
Pulse	84 x/minute	
Body Temperature	36.1 °C	
RR	20	

## CLINICAL EVALUATION

Name : ALIMUSA SIAGIAN	Sex : Male	MR : 01015394	Visit : 23/01/2018
Comp. : INSPEKTINDO SINERGI PERSADA		DOB : 15 October 1976	

EXAMINATION	RESULT	NOTES
Neck Circumference	-	
Arm Circumference	-	
Chest size	-	
Abdominal Circumference	93 Cm	
<b>SKIN</b>		
Skin	Normal	
<b>EYE</b>		
Left	Normal	
Right	Normal	
<b>ENT</b>		
Auricle	Normal	
Ear canal	Normal	
Drums	Abnormal	Perforation of right ear drum
Septum/Conchae	Normal	
Sinuses	Normal	
Pharynx	Normal	
Tonsil	Normal	
<b>MOUTH</b>		
Gum	Normal	
Dental	Abnormal	Radix, missing, decayed, calculus teeth
<b>NECK</b>		
General	Normal	
Thyroid Gland	Normal	
<b>CHEST</b>		
Form	Normal	
Lung	Normal	
Heart	Normal	
Breast	Normal	
<b>ABDOMEN</b>		
Form	Flat	
Palpation	Supple	
Liver	Not Palpable	
Spleen	Not Palpable	
Kidney	No Ballotment	
-	No	
Hernia inguinal	No	
<b>EXTRIMITIES</b>		

## CLINICAL EVALUATION

Name : ALIMUSA SIAGIAN

Sex : Male

MR : 01015394

Visit : 23/01/2018

Comp.: INSPEKTINDO SINERGI PERSADA

DOB : 15 October 1976

EXAMINATION	RESULT	NOTES
Bones, joint	Normal	
Muscles, tonus	Normal	
Fingernails	Normal	
Hand	Normal	
Foot	Normal	
<b>RECTAL EXAMINATION</b>		
Hemorrhoid	Negative	
Rectum	Normal	
<b>SENSORIK EXAMINATION</b>		
Tes Raba	Normal	
<b>MOTORIK EXAMINATION</b>		
Tes Grip	Normal	
<b>REFLEX EXAMINATION</b>		
Physiologic reflex	Normal	
Patologic reflex	Normal	
<b>OTHERS EXAMINATION</b>		
Coordination	Normal	
<b>LYMPHE SYSTEM</b>		
Submandibula	Normal	
Neck Gland	Normal	
Armpit gland	Normal	
Inguinal	Normal	

## OPHTHALMOLOGY DIAGNOSTIC

Name : ALIMUSA SIAGIAN		Sex : Male	MR : 01015394	Visit : 23/01/2018
Comp. : INSPEKTINDO SINERGI PERSADA			DOB : 15 October 1976	
EXAMINATION		Right	Left	
Reading		-		
Previous Glasses		-		
Without Glasses	Distant	20/20	20/20	
	Near	J1	J1	
Correction	Distant	-	-	
	Near	-	-	
		-		
Tonometry		19.0 mmHg	21.0 mmHg	
Funduscopy		NORMAL	NORMAL	
Visual Fields		-		
Colour Blind Test		Normal		

Impression :



## RADIOLOGY DIAGNOSTIC

Name : ALIMUSA SIAGIAN	Sex : Male	MR : 01015394	Visit : 23/01/2018
Comp. : INSPEKTINDO SINERGI PERSADA		DOB : 15 October 1976	

EXAMINATION	RESULT
-------------	--------

THORAX PA

No abnormality seen in both lungs.  
Normal bronchovascular markings in both hili.  
The heart is normal in size and shape.  
The mediastinum is not widened.  
Both sinus and diaphragms are good.  
No evidence of pleural effusion.

Impression

Normal chest.  
No evidence of specific process in both lungs.

## RADIOLOGY DIAGNOSTIC

Name : ALIMUSA SIAGIAN	Sex : Male	MR : 01015394	Visit : 23/01/2018
Comp. : INSPEKTINDO SINERGI PERSADA		DOB : 15 October 1976	

EXAMINATION	RESULT
-------------	--------

USG ABDOMEN

LIVER:

Normal in size and contour, smooth surface, echoes structure parenchyme which are homogenous. No sign of SOL.

Intrahepatic vascularity and billiary tract are normal.

GALL BLADDER:

Normal in size. Multiple small polyps ( diameter 2-3 mm ) at gallbladder wall. No sign of stone.

RIGHT KIDNEY :

Normal in size, contour and surface. No sign of obstruction/ stone/ SOL.

LEFT KIDNEY:

Normal in size, contour and surface. No sign of obstruction/ stone/ SOL.

PANCREAS:

Normal in size, contour and surface. No sign of SOL.

LIEN:

Normal in size and contour, the echoes are homogenous. No sign of SOL.

URINARY BLADDER:

Normal in size, contour and surface. No sign of stone/ SOL.

PROSTATE AND VESICULA SEMINALIS:

Normal in size and contour which are homogenous echoes and no sign of focal lesion/ SOL.

Impression

Multiple small polyps of gallbladder. No sign of stone.

Other abdominal organs are normal.

**LABORATORY RESULT**

Name : ALIMUSA SIAGIAN	MR : 01015394	Visit : 23/01/2018	#Lab : IN623224976799
Comp. : INSPEKTINDO SINERGI PERSADA	Sex : Male	DOB : 15 October 1976	

**EXAMINATION****RESULT****NORMAL RANGE****HEMATOLOGI****Automated Blood Count**

White Blood Cell (WBC)	7.9	3.8 - 11.0
Erythrocyte (RBC)	5.2	4.4 - 5.9
Haemoglobin	15.6	13.2 - 17.3
Hematocrit	44	40 - 52
Thrombocytes	260	150 - 440

**MCV, MCH, MCHC**

MCV	84	80 - 100
MCH	30	26 - 34
MCHC	35.6	32 - 36
ESR	5	0 - 10

**Differential Count**

Basophils	0	0 - 1
Eosinophil	3	2 - 4
Bands / Stab	1 *	3 - 5
Neutrophils	66	50 - 70
Lymphocytes	20 *	25 - 40
Monocytes	10 *	2 - 8

**BLD CHEMISTRY/LIPID PROFILE**

Total Cholesterol	157	Normal/Desireable: <200 Borderline High: 200-239 High: >=240
HDL Cholesterol	61.1 *	Normal : >40 - <60 Low HDL : <40 Desireable : >=60
LDL Cholesterol	83	Optimal: <100 Near/Above Optimal: 100-129 Borderline High: 130-159 High: 160-189 Very High: >=190
Tryglicerides	65	Normal : <150 Borderline High: 150-199 High : 200-499 Very High : >=500

**BLD CHEMISTRY/KIDNEY FUNCTION**

Ureum	15.6	10.0 - 50.0
-------	------	-------------



## LABORATORY RESULT

Name : ALIMUSA SIAGIAN	MR : 01015394	Visit : 23/01/2018	#Lab : IN623224976799
Comp. : INSPEKTINDO SINERGI PERSADA	Sex : Male	DOB : 15 October 1976	

EXAMINATION	RESULT	NORMAL RANGE
Creatinine	0.9	0.6- 1.3
Uric Acid	6.2	3.5 - 7.2

### BLD CHEMISTRY/LIVER FUNCTION

Total Bilirubin	1.0	0.1 - 1.0
SGOT(AST)	16	13 - 45
SGPT (ALT)	21	13 - 50
Alkaline Phosphatase	55	30 - 120
Gamma GT	28	0 - 50
Albumin	5.4	3.5 - 5.5
Globulin	2.00 *	2.3 - 3.5
Total Protein	7.4	6.6 - 8.7

### BLD CHEMISTRY/DIABETES

Glucose Fasting	74	< 100
Glucose Urine	Negative	Negative
Keton Urine	Negative	Negative

### Blood Glucose 2 PP

Blood Sugar 2 Hours PP	84	< 140
Glucose Urine	Negative	Negative
Keton Urine	Negative	Negative

### SEROLOGI / IMUNOLOGI

HBsAg (Quantitative)	0.00	0.00 - 0.03
Anti Hbs (Quantative)	0.5 * -	>= 5.0
VDRL	Negative	Negative

### TOXICOLOGY - DRUGS SCREENING

MDMA	Negative	Negative
THC/Marijuana	Negative	Negative
Amphetamine	Negative	Negative
Opiat	Negative	Negative
Cocain	Negative	Negative
Alcohol	Negative	Negative

### URINALYSIS

#### Complete Urine Analysis

#### Macroscopic

Color	Colorless	
Turbidity	Clear	Clear
Specific Gravity	1.013	1.000 - 1.030
pH	6.0	4.5 - 8.0



## LABORATORY RESULT

Name : ALIMUSA SIAGIAN	MR : 01015394	Visit : 23/01/2018	#Lab : IN623224976799
Comp. : INSPEKTINDO SINERGI PERSADA	Sex : Male	DOB : 15 October 1976	

EXAMINATION	RESULT	NORMAL RANGE
Leucocyte	Negative	Negative
Glucose	Negative	Negative
Nitrit	Negative	Negative
Bilirubin	Negative	Negative
Blood	Negative	Negative
Urobilinogen	Normal	Normal
Protein	Negative	Negative
Keton	Negative	Negative
<b>Microscopic</b>		
RBC	0-1	0 - 1
WBC	0-1	0 - 4
Cylinder	Negative	
Epithels Squamous	0-1	5 - 15
Crystals	Negative	
Bacteria	Negative	Negative
Others	Negative	

## SPIROMETRY DIAGNOSTIC

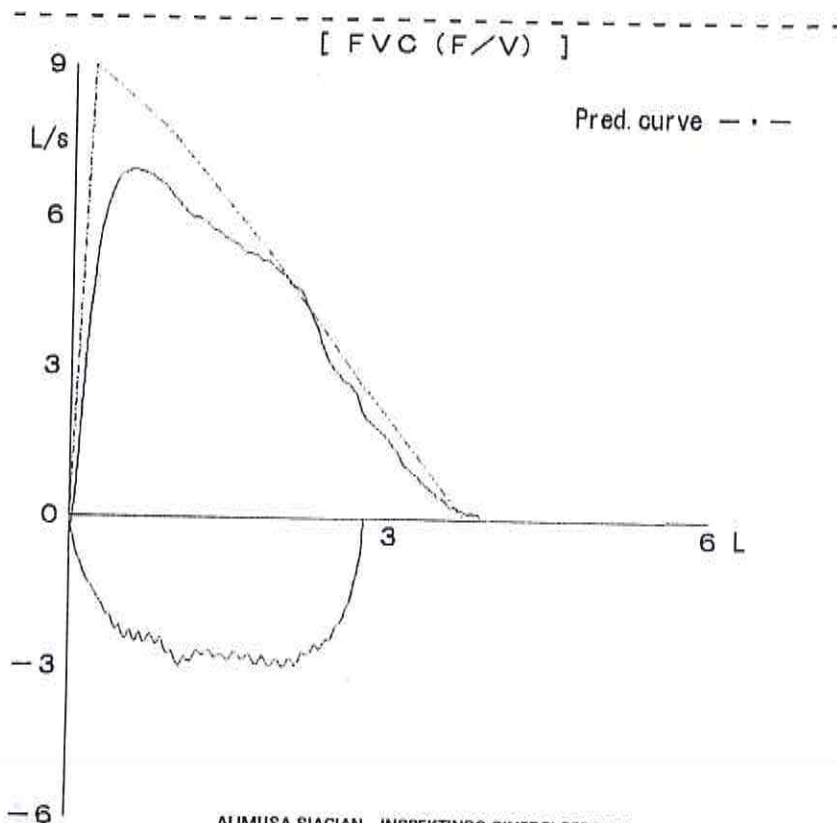
Name : ALIMUSA SIAGIAN		Sex : Male	MR : 01015394	Visit : 23/01/2018
Comp.: INSPEKTINDO SINERGI PERSADA			DOB : 15 October 1976	
EXAMINATION	RESULT			

**FVC Result** : 3.87 L---> 104.3 %  
**FEV1 Result** : 3.31 L---> 103.8 %  
**FEV1/FVC Result** : 85.53 %---> 111.8 %  
**PEF Result** : 6.93 L/S---> 67.9 %  
**Indonesian Standart Result** :  
**Index** :  
**Spirometry Result** : Normal

**Impression** : Normal Spirometric Functions

### [ COPD CLASSIFICATION ]

FEV1/FVC : 85.53 %  
 %FEV1, 0 : 103.80 %  
 Stage : Normal  
 Recommended treatment by GOLD:



ALIMUSA SIAGIAN - INSPEKTINDO SINERGI PERSADA

## AUDIOMETRY DIAGNOSTIC

Name : ALIMUSA SIAGIAN

Sex : Male

MR : 01015394

Visit : 23/01/2018

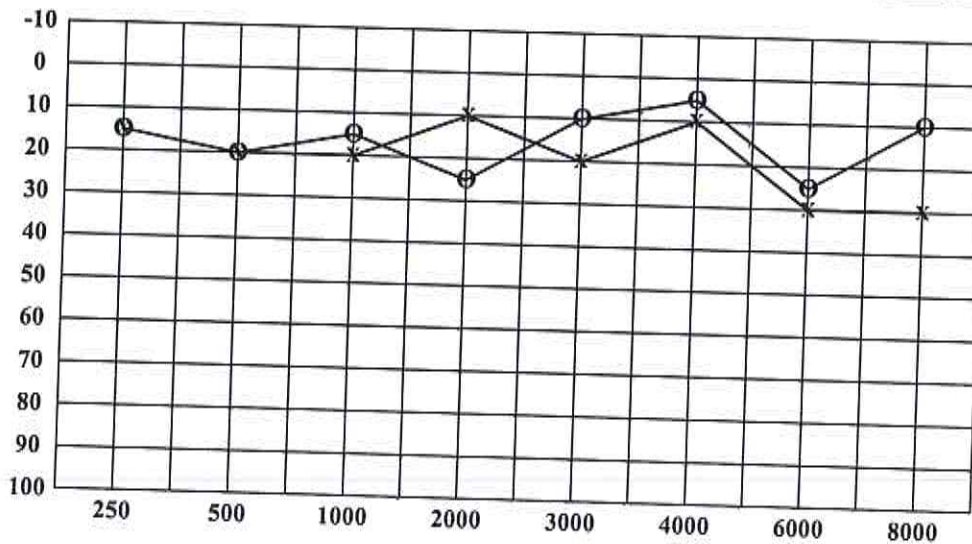
Comp. : INSPEKTINDO SINERGI PERSADA

DOB : 15 October 1976

### RESULT

Left Ear	250	500	1000	2000	3000	4000	6000	8000
AC	15	20	20	10	20	10	30	30
BC	-	-	-	-	-	-	-	-

Right Ear	250	500	1000	2000	3000	4000	6000	8000
AC	15	20	15	25	10	5	25	10
BC	-	-	-	-	-	-	-	-



< : Right Ear (BC)  
> : Left Ear (BC)

O : Right Ear (AC)  
X : Left Ear (AC)

Conclusion Right Ear : Hearing threshold = 16.25 dB  
(Within normal limit)

Conclusion Left Ear : Hearing threshold = 15 dB  
(Within normal limit)  
With decreasing on frequency  
6000Hz & 8000Hz



## CARDIOLOGY DIAGNOSTIC

Name : ALIMUSA SIAGIAN

Sex : Male

MR : 01015394

Visit : 23/01/2018

Comp.: INSPEKTINDO SINERGI PERSADA

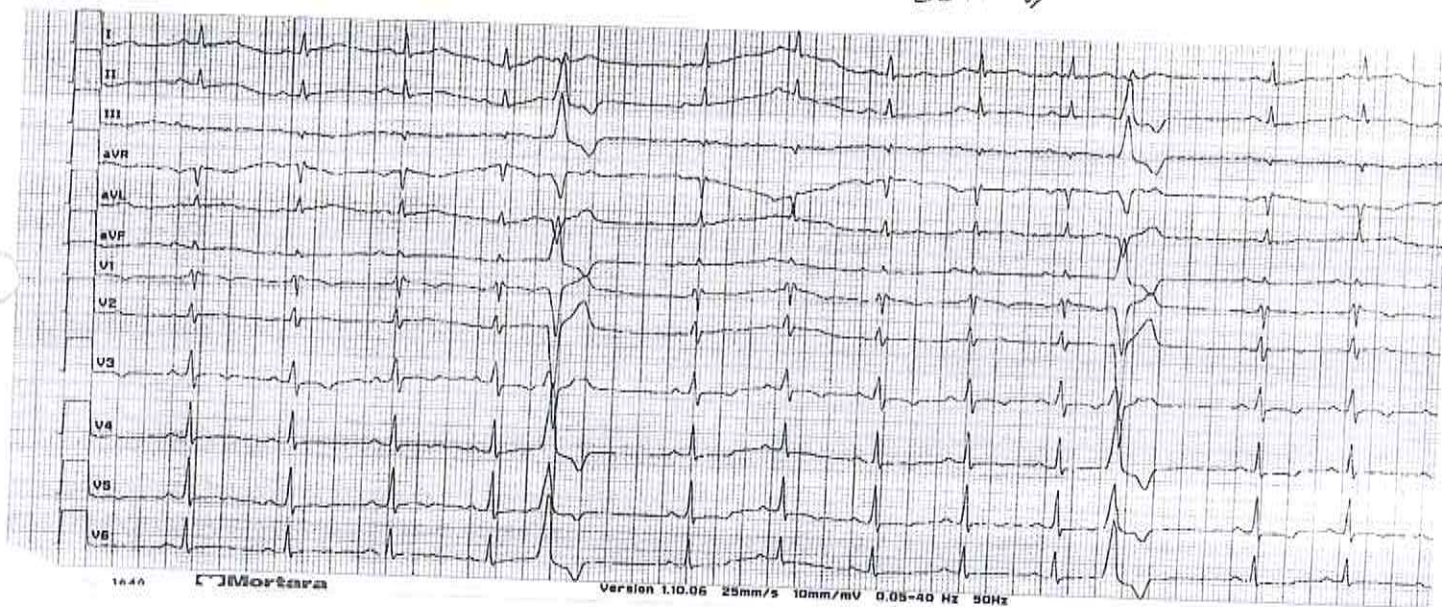
DOB : 15 October 1976

EXAMINATION	RESULT	Comments :
ELECTROCARDIOGRAPHY	Sinus Rythm axis ( N ), P wave ( N ) PR int 0.16",ST depresi V3 - V6,I,AVL aritmia (+)	LV Strain ec HHD + VES
TREADMILL	Sinus Rythm axis ( N ), P wave ( N ) PR int 0.16",ST depresi V3 - V6,I,AVL aritmia (+)  LV Strain ec HHD + VES	Treadmill Exercise Test : Negative Cardiopulmonary Fitness Classification : Good METs :13.4

ALIMUSA SIAGIAN  
DOB: 15/10/1976  
W: 41 yo  
INSPEKTINDO SINERGI PERSADA

23-Jan-2018 6:43:57

*LV Strain + VES  
ec HHD*








# ALIMUSA SIAGIAN, MR

ID 01015394, Born: 15/10/1976(Male 41), 68 kg, 161 cm  
Test Date: 23/01/2018 7:40:14

MEDIKA PLAZA



### Patient info

Born: 15/10/1976  
Age: 41  
Sex: Male  
Weight: 68 kg  
Height: 161 cm  
Smoker:  
Pacemaker:

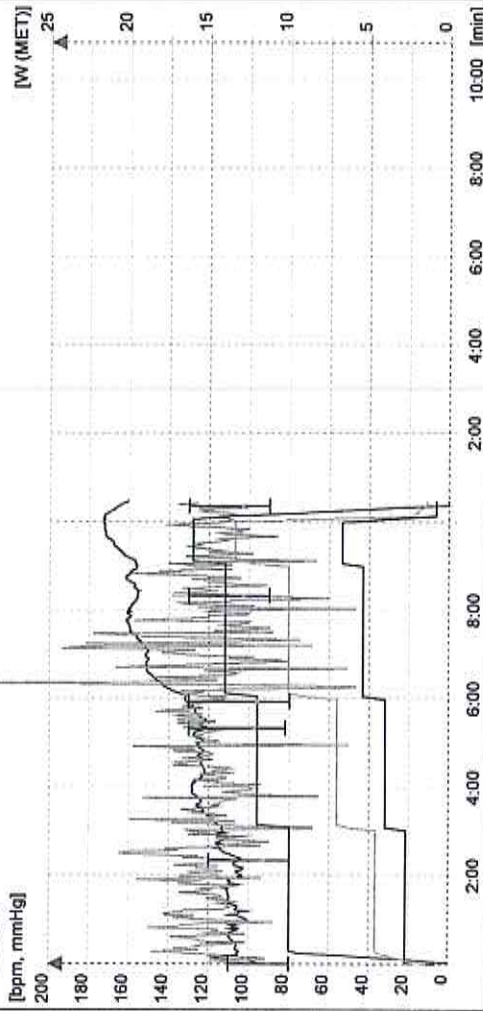
### Medical history

### Medications

### Reason for Admission

### Reason for Stop

### Trends



### Conclusion

*L. S. Siagian*  
*Spesialist*  
*Spesialist*

**MP+**  
 dr. KARTIKA BINA MEDIANE

### Staff

Attending doctor: Adolf Amahorseya, SpJP  
Technician: Jeni, NR

### Test info

Test date: 23/01/2018  
Test time: 7:40  
Stress device: BTL Treadmill  
Protocol: Bruce  
Total duration: 10:01  
Stress achieved: 6,7km/h, 16,0% (~13,4MET) = 115% predicted (~11,9MET) - for 61 sec  
HR rest: 88  
HR peak: 172 = 97% predicted (178) — 10:02 Exercise (13,4MET)  
Handgrip test: —  
BP rest: 110/80  
BP peak: 130/90  
BP recovery: —  
DP rest: 9680  
DP peak: 20260 = 2,1x DP at rest  
ST depression max: V3 -0,24mV 07:35 Exercise 10,1MET  
ST elevation max: V5 0,51mV 06:20 Exercise 10,1MET  
ST/HR index: 1,9 µV/bpm (abnormal)





**ALIMUSA SIAGIAN, MR**

ID 01015394, Born: 15/10/1976 (Male 41), 68 kg, 161 cm  
Test Date: 23/01/2018 7:40:14

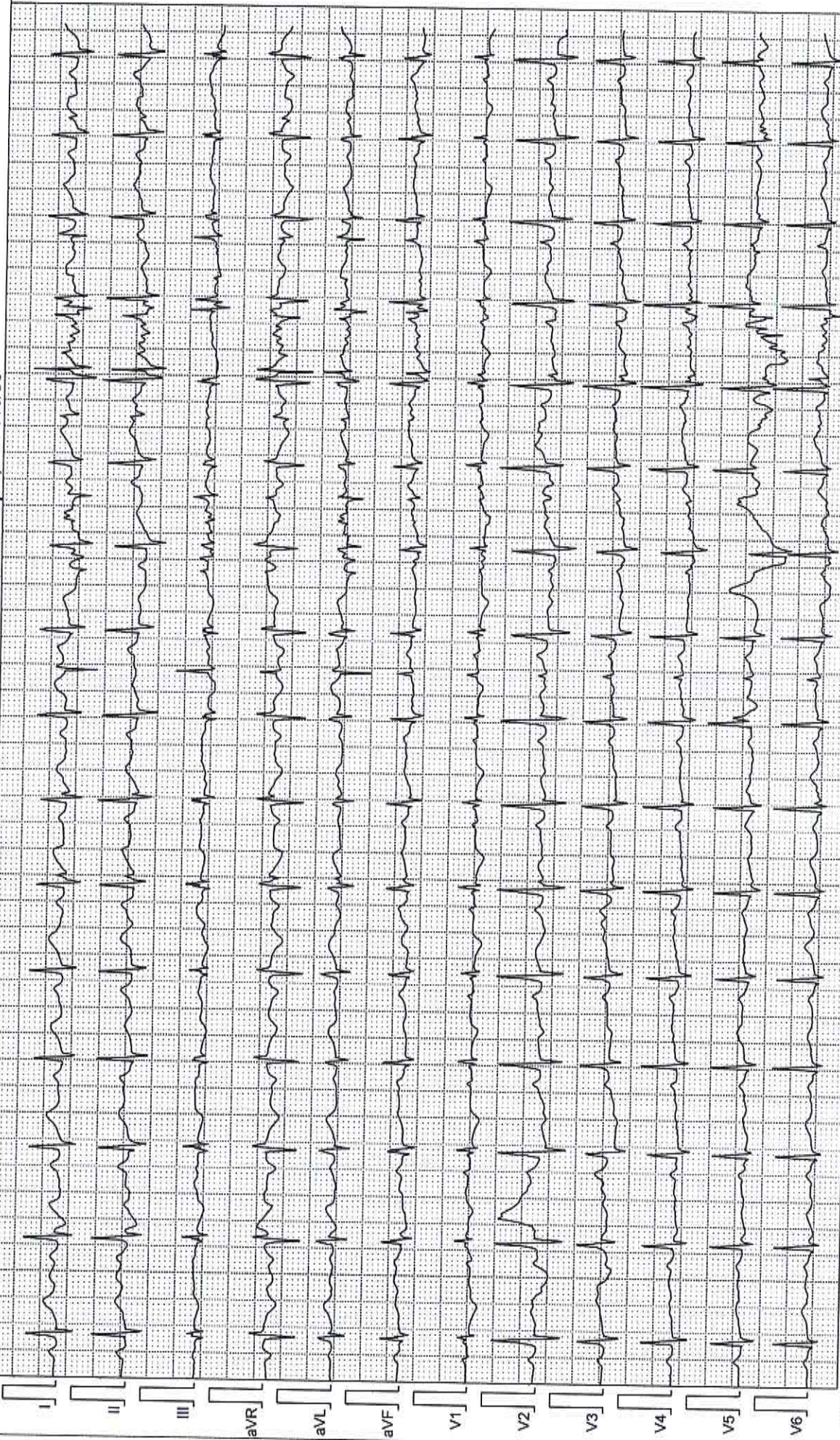
MEDIKA PLAZA

MP+

MEDIKA PLAZA

Time: P 00:07 - Reference

Load: 1,4MET, HR: 88bpm, BP: 110/80



Filter: 0,07 Spline - 90 Adapt, ~50 [Hz]

MEDIKA PLAZA

25,00 mm/sec 10,0 mm/mV





**ALIMUSA SIAGIAN, MR**

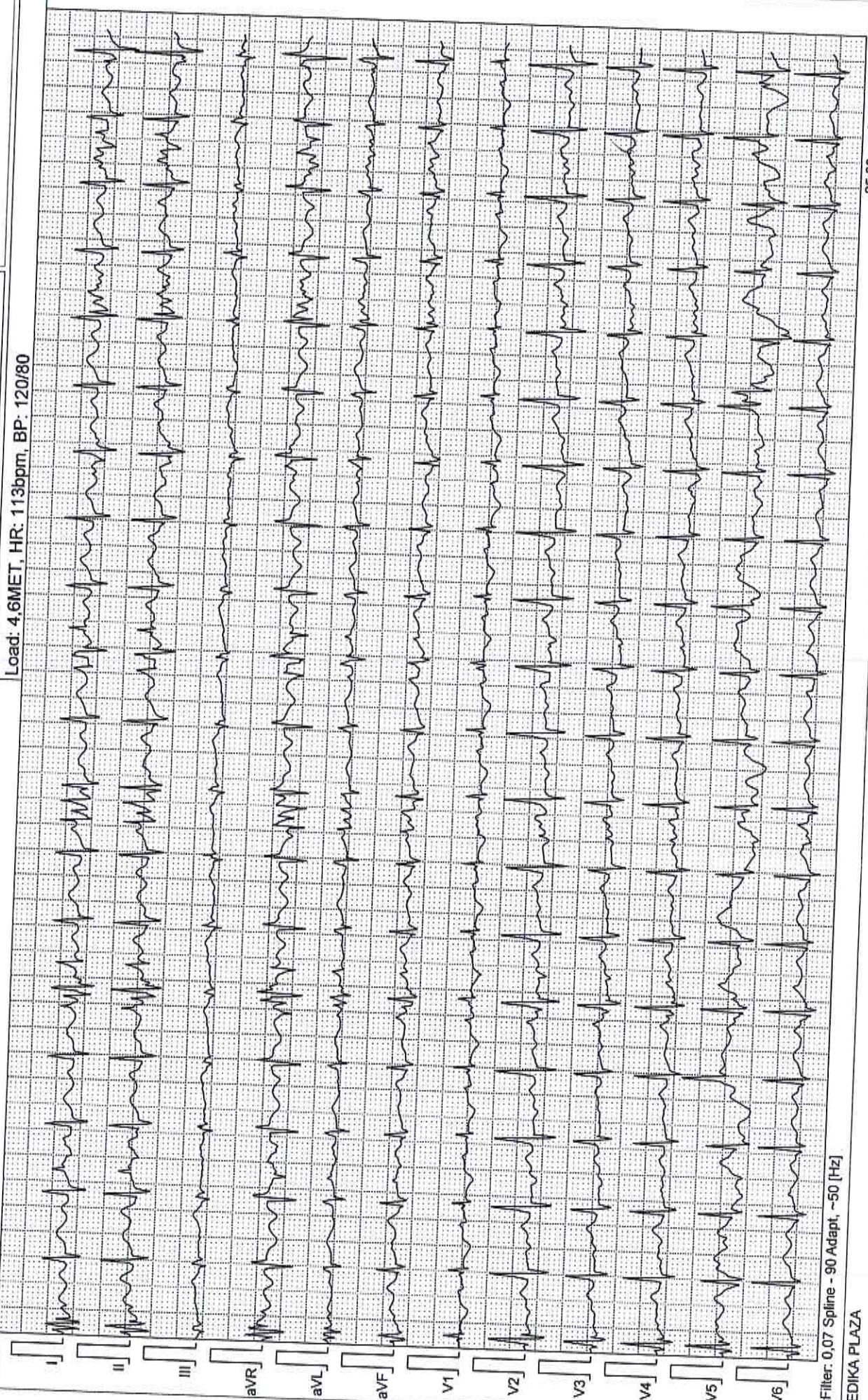
ID 01015394, Born: 15/10/1976 (Male 41), 68 kg, 161 cm  
Test Date: 23/01/2018 7:40:14

MEDIKA PLAZA

MP+

Time: E 02:56 - E1

Load: 4.6MET, HR: 113bpm, BP: 120/80



Filter: 0.07 Spine - 90 Adapt. ~50 [Hz]

MEDIKA PLAZA

CardioPoint 2.23.18524.0, DIAG 1.7.17214.0, ECG:071D-B-05775

25,00 mm/sec 10,0 mm/mV

CardioPoint - Stress Test

Page: 3






**ALIMUSA SIAGIAN, MR**

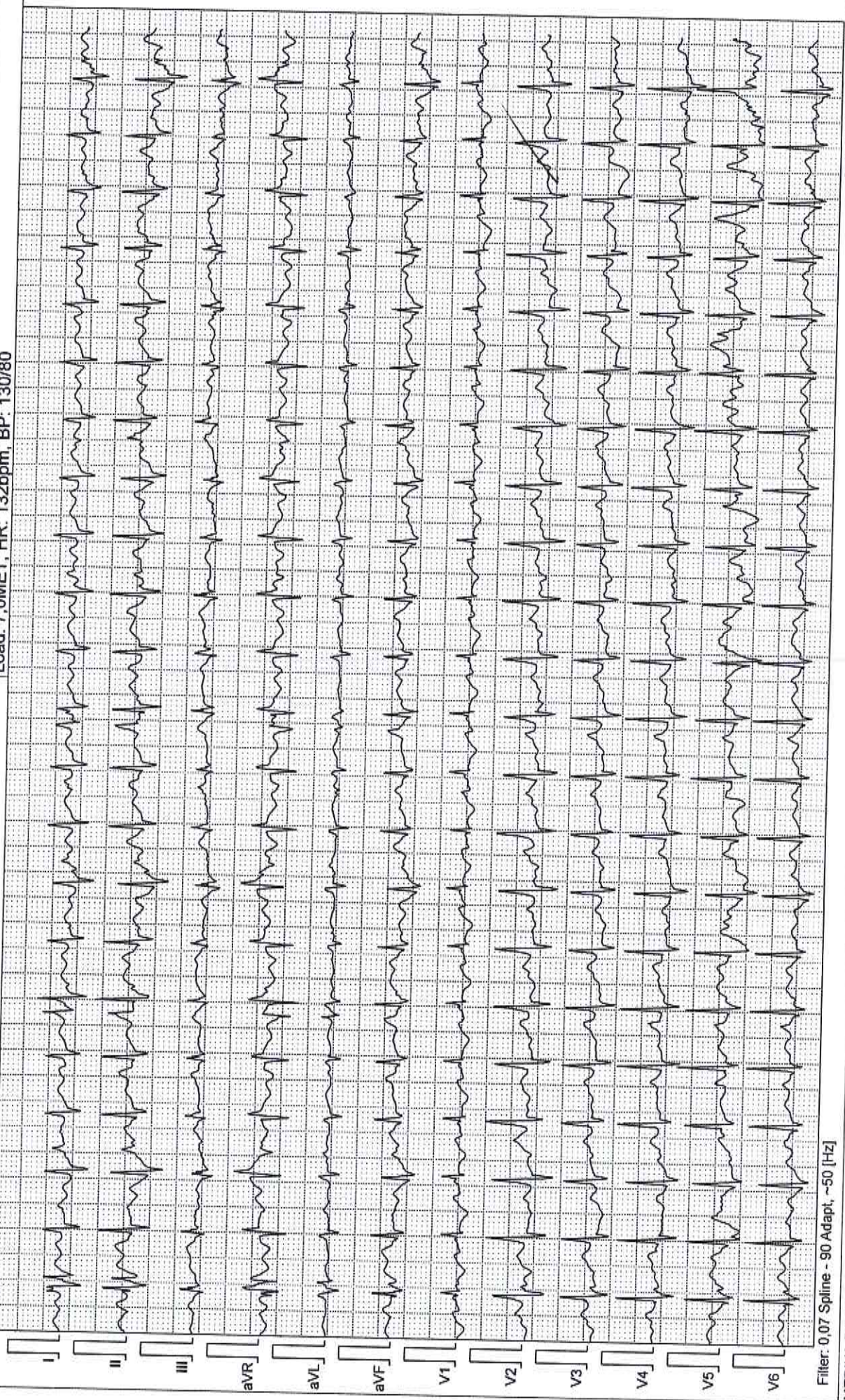
ID 01015394, Born: 15/10/1976(Male 41), 68 kg, 161 cm  
Test Date: 23/01/2018 7:40:14

MEDIKA PLAZA



Time: E 05:56 - E2

Load: 7,0MET, HR: 132bpm, BP: 130/80



MEDIKA PLAZA

25,00 mm/sec 10,0 mm/mV






**ALIMUSA SIAGIAN, MR**

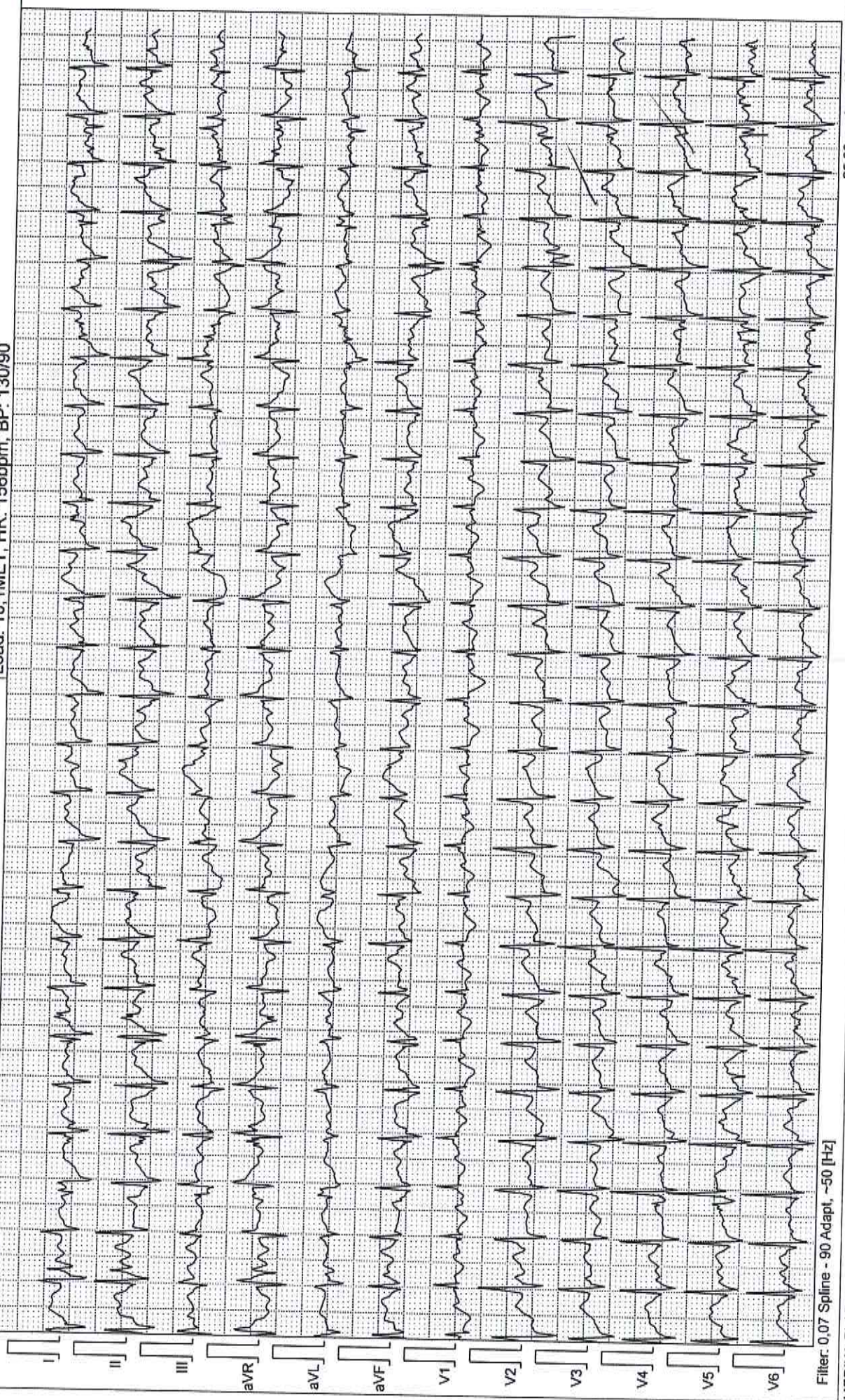
ID 01015394, Born: 15/10/1976(Male 41), 68 kg, 161 cm  
Test Date: 23/01/2018 7:40:14

MEDIKA PLAZA



Time: E 08:55 - E3

Load: 10,1MET, HR: 156bpm, BP: 130/90



Filter: 0.07 Splice - 90 Adapt, ~50 [Hz]

MEDIKA PLAZA

25,00 mm/sec 10,0 mm/mV





**ALIMUSA SIAGIAN, MR**

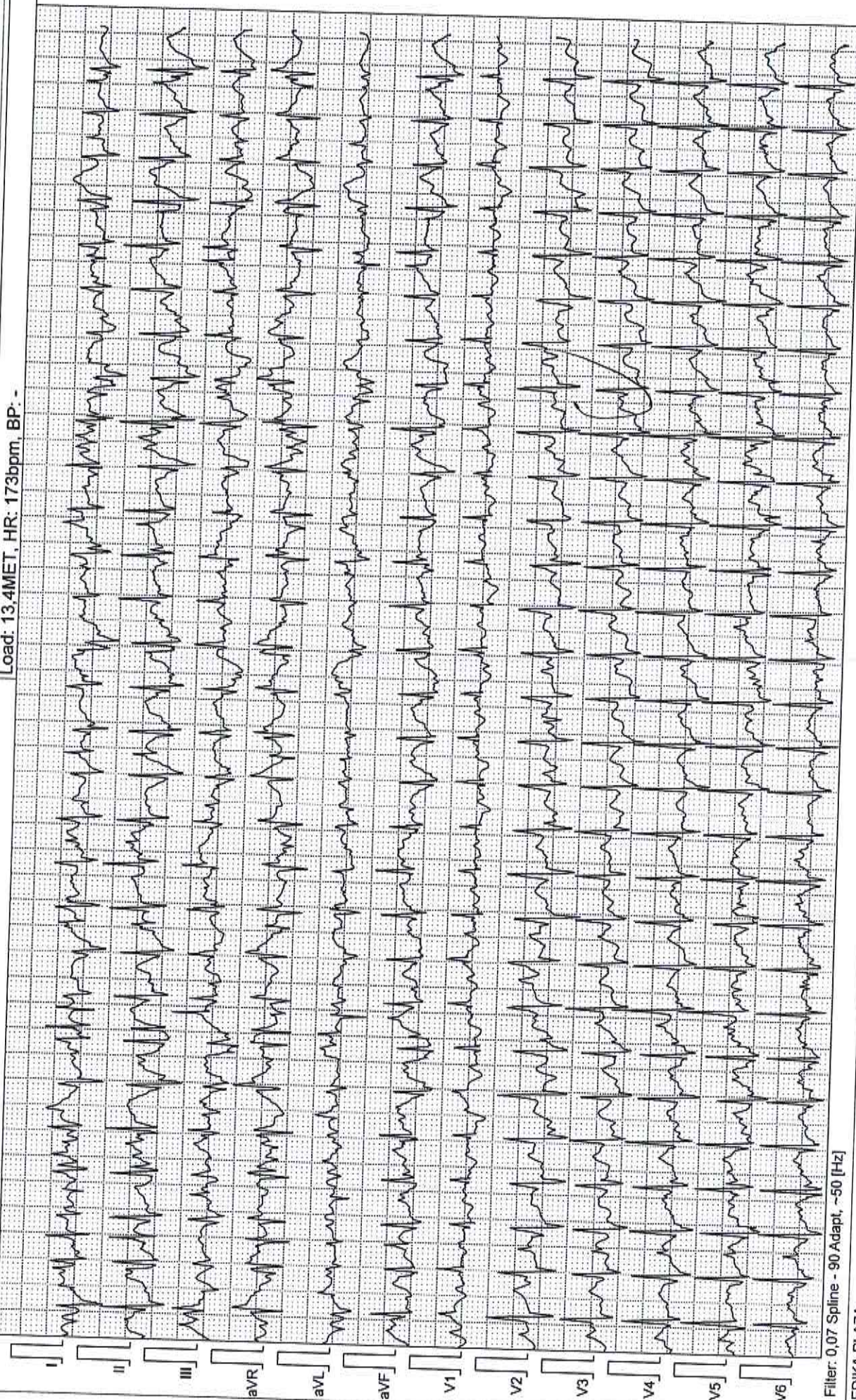
ID 01015394, Born: 15/10/1976 (Male 41), 68 kg, 161 cm  
Test Date: 23/01/2018 7:40:14

MEDIKA PLAZA

MP+  
MEDIKA PLAZA

Time: E 09:57 - Peak

Load: 13.4MET, HR: 173bpm, BP: -



Filter: 0.07 Spine - 90 Adapt, ~50 [Hz]

MEDIKA PLAZA

25.00 mm/sec 10.0 mm/mV

CardioPoint 2.23.18524.0, DIAG 1.7.17214.0, ECG-071D-B-05775

CardioPoint - Stress Test

Page: 6





**ALIMUSA SIAGIAN, MR**

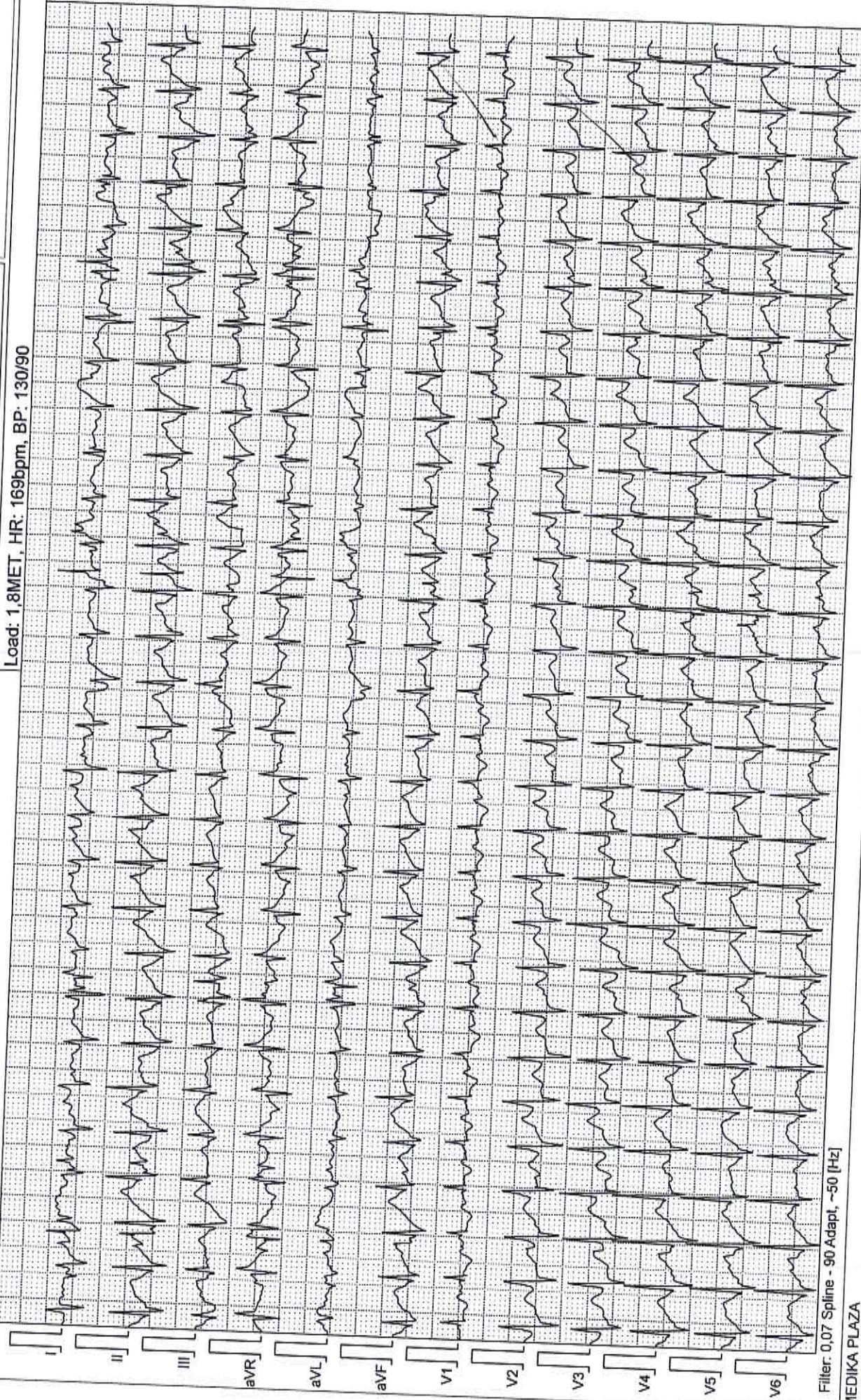
ID 01015394, Born: 15/10/1976 (Male 41), 68 kg, 161 cm  
Test Date: 23/01/2018 7:40:14

MEDIKA PLAZA

MP<sup>+</sup>  
MEDIKA PLAZA

Time: R 00:10 - RECOVERY

Load: 1.8MET, HR: 169bpm, BP: 130/90



Filter: 0.07 Spline - 90 Adapt, ~50 [Hz]

MEDIKA PLAZA





**ALIMUSA SIAGIAN, MR**

ID 01015394, Born: 15/10/1976(Male 41), 68 kg, 161 cm  
 Test Date: 23/01/2018 7:40:14

MEDIKA PLAZA

MP<sup>+</sup>  
 MEDIKA PLAZA

Stage	Time	Load		HR bpm	BP mmhg	SpO2 %	ST Level [mV], J+: 1/8RRR																		
		km/h	%				MET	I	II	III	aVR	aVL	aVF	V1	V2	V3	V4	V5	V6						
Reference	E 00:02	0,8	0,0	1,4	88	-	0,05	0,00	-0,04	-0,02	0,04	-0,02	0,04	-0,02	0,04	-0,03	0,04	0,04	0,04	0,04	0,00	0,00	0,01	0,02	
E 1 step	E 03:01	2,7	10,0	4,6	115	-	0,04	0,03	-0,01	-0,04	0,02	-0,04	0,02	0,01	0,02	-0,02	0,02	0,02	0,02	0,02	0,00	0,00	0,00	0,01	0,02
E 2 step	E 06:01	4,0	12,0	7,0	131	-	-0,01	0,04	0,06	0,06	-0,02	-0,02	-0,03	0,05	-0,02	-0,05	-0,08	-0,05	-0,05	-0,01	0,00	0,00	0,05	0,03	0,03
E 3 step	E 09:00	5,4	14,0	10,1	158	-	-0,02	-0,13	-0,10	-0,10	0,07	0,03	0,03	-0,11	0,07	-0,03	-0,11	-0,24	-0,11	-0,09	-0,09	-0,09	-0,09	0,01	0,05
E 4 peak	E 10:02	6,7	16,0	13,4	172	-	-0,02	0,04	0,07	0,07	-0,01	-0,04	0,05	0,05	-0,06	-0,06	-0,12	-0,10	-0,10	-0,03	-0,03	-0,03	-0,01	0,03	-0,06
RECOVERY	R 00:20	0,8	16,0	2,5	169	-	0,04	0,07	0,05	0,05	-0,05	-0,01	0,06	0,06	-0,05	-0,07	-0,07	-0,07	-0,07	-0,03	-0,03	-0,03	-0,05	0,04	0,04



PATIENT NAME : TN ALI MUSA  
No. RM : 01.01.5394  
Clinik/MCU/HCU : ENT

To, Dokter :  
(Counsel)

Kindly please counsel for patient who has take cares of

Diagnose :  
Clinik Summary :

Counsel Request :

**COUNSEL ADVISE**

Finding

Eae : Tympanic intact no. cerumen  
nose : Concha euthophy, no secreta, deviated septum  
throat : TIT, foamy salivation

Diagnosis

Audionefy : Heary threshold within normal limit  
Decreasing at freq 6000 & 8000 Hz left ear.

Deviated septum, Laryngopharyngo  
Recomendation

Date

23/01/2018

- Using ear protection when  
warkly in noisy Area.


Time

EP

- Healthy life style

(exercise Regularly, drink plenty  
water, avoid eating junk food.)

Signataure

  
Dr. Kartika Bina  
Complete Name

Formulir Number : FM - DR - 008 - 02

Revisi Number : 00

Date : 2 Mei 2011