

Certificate Of Health Assessment



Name	Age	Position	Department
TAMBOK PARSAULIAN NAPITUPULU	42 yo	INSPECTOR	-

COMPANY :

INSPEKTINDO SINERGI PERSADA

CONCLUSION

Fit for work to the job described	✓
Fit with Medical Note (Restriction and/or Limitation)	
Unfit for work to the job described	

Date	Doctors Name	Signature
15 March 2017	Yosephine Simanungkalit, MD	  PT. KARTIKA BINA MEDIKATAMA

No. Formulir : FM-DR-008-05
 No. Revisi : 00
 Tanggal Terbit : 2 Mei 2011

PT. KARTIKA BINA MEDIKATAMA

OFFICE Menara Kuningan 5th Fl. Jl. HR. Rasuna Said X7 Kav. 5, Jakarta 12940 TEL +62 21 3002 7070 HUNTING, FAX +62 21 3002 7065
 CLINIC Menara Kartika Chandra 3rd Fl. Jl. Jend. Gatot Subroto Kav. 18-20, Jakarta 12060 TEL +62 21 525 1207 HUNTING, FAX +62 21 521 0815

www.medikaplaza.com

TO WHOM IT MAY CONCERN

Kepada yang berkepentingan

This is certify that today Wednesday, 15 March 2017 Medika Plaza Clinic has performed urine drug screening and/or breath alcohol test to :

Dengan ini menyatakan bahwa, pada hari ini Rabu, 15 Maret 2017 Medika Plaza Clinic telah melakukan urine drug screening dan/atau breath alcohol test kepada :

TAMBOK PARSAULIAN NAPITUPULU

With the results are as follows :
Dengan hasil sebagai berikut :

<u>Drugs Test</u> <i>Uji Obat</i>	<u>Result</u> <i>Hasil</i>		
URINE DRUGS SCREENING			
- Amphetamine	<input type="checkbox"/> Non-Negative	<input checked="" type="checkbox"/> Negative	<input type="checkbox"/> N/A
- Met-Amphetamine	<input type="checkbox"/> Non-Negative	<input type="checkbox"/> Negative	<input checked="" type="checkbox"/> N/A
- Cocain	<input type="checkbox"/> Non-Negative	<input checked="" type="checkbox"/> Negative	<input type="checkbox"/> N/A
- THC/Canabis/Marijuana	<input type="checkbox"/> Non-Negative	<input checked="" type="checkbox"/> Negative	<input type="checkbox"/> N/A
- Morphine/Opiates	<input type="checkbox"/> Non-Negative	<input checked="" type="checkbox"/> Negative	<input type="checkbox"/> N/A
- P C P/Phencyclidine	<input type="checkbox"/> Non-Negative	<input type="checkbox"/> Negative	<input checked="" type="checkbox"/> N/A
- Barbiturate	<input type="checkbox"/> Non-Negative	<input type="checkbox"/> Negative	<input checked="" type="checkbox"/> N/A
- Benzodiazepin	<input type="checkbox"/> Non-Negative	<input type="checkbox"/> Negative	<input checked="" type="checkbox"/> N/A
- Methadone	<input type="checkbox"/> Non-Negative	<input type="checkbox"/> Negative	<input checked="" type="checkbox"/> N/A
- Propoxyphene	<input type="checkbox"/> Non-Negative	<input type="checkbox"/> Negative	<input checked="" type="checkbox"/> N/A
- Oxycodone	<input type="checkbox"/> Non-Negative	<input type="checkbox"/> Negative	<input checked="" type="checkbox"/> N/A
- MDMA	<input type="checkbox"/> Non-Negative	<input checked="" type="checkbox"/> Negative	<input type="checkbox"/> N/A
- 6-MAM	<input type="checkbox"/> Non-Negative	<input type="checkbox"/> Negative	<input checked="" type="checkbox"/> N/A
BREATH ALCOHOL TEST			
- Alcohol	<input type="checkbox"/> Non-Negative	<input checked="" type="checkbox"/> Negative	<input type="checkbox"/> N/A

Jakarta, March 15, 2017


PT. KARTIKA BINA MEDIKATAMA
(Esther Poerwantoro, Sp.PK)
Clinical Patologist

MEDIKA PLAZA CLINIC

Kartika Chandra - Office Tower 3rd Floor
Jl. Jend. Gatot Subroto, Kav. 18-20 Jakarta Selatan 12940
Tlp : (62-21) 525 1207, Fax : (62-21) 521 0815
Appointment Hotline (62-21) 528 80088
www.medikaplaza.com

PATIENT DATA

MedRec.	: 01022516	EMPLOY. STATUS	: Employee
NAME	: TAMBOK PARSAULIAN NAPITUPULU	BIRTHDATE	: 27 July 1974
EMPLOYEE No.	:	SEX	: Male
JOB TITLE	: INSPECTOR	STATUS	: Married
COMP. NAME	: INSPEKTINDO SINERGI PERSADA	NASIONALITY	: Indonesia

SUMMARY


MEDICAL FINDING :

1. Increase fasting blood sugar
 2. Increase ESR count
 3. Non reactive anti HBs
 4. Overweight
 5. Decreasing of visual acuity of both eyes
 6. Radix, missing, calculus teeth
- Your fitness status is fit for work to the job described

SUGGESTION :

1. Low sugar diet
2. Repeat ESR examination 1 month later
3. Need to get Hepatitis B vaccination
4. Reduce body weight gradually 0.5 Kgs/week, by doing regular exercise (aerobic/jogging), 3-4x/week, 30-45 minutes and reduce high calorie diet until maximal body weight is 72.25 Kgs (present body weight is 84.50 Kgs)
5. Need to wear a glasses for near vision
6. See a dentist for dental care minimal once a year or better once in 6 months

Responsible Doctor



Yosephine Simanungkalit, MD

Notes:

If you need the further information or consultation, please contact us via :

Email : - kdoctor01@medikaplaza.com
- dr.yosephine@medikaplaza.com

Clinic Number : (021) 5251207

CLINICAL EVALUATION

Name : TAMBOK PARSAULIAN NAPITUPULU		Sex : Male	MR : 01022516	Visit : 15/03/2017
Comp.: INSPEKTINDO SINERGI PERSADA			DOB : 27 July 1974	
EXAMINATION	RESULT	NOTES		

PHYSICAL EXAMINATION**PRESENT COMPLAINT**

Present complaint

No complaint

MEDICAL HISTORY

Allergy	No
Imunisasi	Yes
Surgery	No
Hospitalization	No
Disease	No

LIFE STYLE

Alcohol intake	No	
Smoking	Yes	20 cigs/day
Exercise	Yes	1x/week, swimming
Appetite	Good	

FAMILY MEDICAL HISTORY

Diabetes Melitus	No	
Hypertension	No	
Heart disease	No	
Lung TB	No	
Kidney disease	No	
Astma	No	
Mental disease	No	
Epilepsy	No	
Chronic skin disease	No	
Cancer	Yes	Mother
Color blind	No	
Stroke	No	
Liver disease	No	
Bone & joint	No	
Pulmonary disease	No	
Others disease	No	

WORK EXPOSURE

Noise	Yes
Heat Stress	Yes
Cold Stress	Yes
Vibration	Yes
Dust	Yes

CLINICAL EVALUATION

Name : TAMBOK PARSAULIAN NAPITUPULU	Sex : Male	MR : 01022516	Visit : 15/03/2017
Comp.: INSPEKTINDO SINERGI PERSADA		DOB : 27 July 1974	
EXAMINATION	RESULT	NOTES	

Toxic chemical	Yes
Iritating fluid	Yes
Heat Stress	No
Operating heavy mobile equipment	Yes
Working arround rotating machinery	No
Requires color vision	No
Involving height	Yes
Administration work	No
Handling food product	No
Others	No

GENERAL

General Appearance	Good
Nutrition Status	Normal

VITAL SIGN

Body Weight	84.5 Kg
Body Height	170 Cm
BMI	29.23 Kg/m ²
Normal Weight	53.47 - 72.25 Kg
BMI Conclusion	Overweight
Blood Pressure	100/70 mmHg
Pulse	80 x/minute
Body Temperature	36.5 °C
RR	18
Neck Circumference	-
Arm Circumference	-
Chest size	-
Abdominal Circumference	-

SKIN

Skin	Abnormal	Tatoo at right thigh
Pale	No	
Jaundice	No	

EYE

Left	Normal
Right	Normal

ENT

Auricle	Normal
Ear canal	Normal

CLINICAL EVALUATION

Name : TAMBOK PARSAULIAN NAPITUPULU	Sex : Male	MR : 01022516	Visit : 15/03/2017
-------------------------------------	------------	---------------	--------------------

Comp.: INSPEKTINDO SINERGI PERSADA	DOB : 27 July 1974
------------------------------------	--------------------

EXAMINATION	RESULT	NOTES
Drums	Normal	
Septum/Conchae	Normal	
Sinuses	Normal	
Pharynx	Normal	
Tonsil	Normal	
MOUTH		
Gum	Normal	
Dental	Abnormal	Radix, missing, calculus teeth
NECK		
General	Normal	
Thyroid Gland	Normal	
CHEST		
Form	Normal	
Expansion	Normal	
Lung	Normal	
Heart	Normal	
Breast	Normal	
Heart sound	Normal	
Murmurs	Normal	
ABDOMEN		
Form	Globular	
Palpation	Supple	
Liver	Not Palpable	
Spleen	Not Palpable	
Kidney	No Ballotment	
Hernia inguinal	No	
EXTRIMITIES		
Bones, joint	Normal	
Muscles, tonus	Normal	
Fingernails	Normal	
Hand	Normal	
Foot	Normal	
RECTAL EXAMINATION		
Hemorrhoid	Negative	
Rectum	Normal	
NEUROLOGICAL EXAMINATION		
Motoric function	Normal	

CLINICAL EVALUATION

Name : TAMBOK PARSAULIAN NAPITUPULU	Sex : Male	MR : 01022516	Visit : 15/03/2017
Comp. : INSPEKTINDO SINERGI PERSADA		DOB : 27 July 1974	
EXAMINATION	RESULT	NOTES	

Sensoric function	Normal
Coordination	Normal
Physiologic reflex	Normal
Extra piramidal function	Normal
Romberg Test	Not Examined

LYMPHE SYSTEM

Neck Gland	Normal
Armpit gland	Normal
Inguinal	Normal

OPHTHALMOLOGY DIAGNOSTIC

Name : TAMBOK PARSAULIAN NAPITUPULU		Sex : Male	MR : 01022516	Visit : 15/03/2017
Comp. : INSPEKTINDO SINERGI PERSADA			DOB : 27 July 1974	
EXAMINATION		Right	Left	
Reading		-		
Previous Glasses		-	-	
Without Glasses	Distant	20/20	20/20	
	Near	J3	J3	
Correction	Distant	-	-	
	Near	S+1.25 J1	S+1.25 J1	
Tonometry		16.0 mmHg	18.0 mmHg	
Funduscopy		NORMAL	NORMAL	
Visual Fields		-		
Colour Blind Test		Normal		

Impression : Presbiopia

RADIOLOGY DIAGNOSTIC

Name : TAMBOK PARSAULIAN NAPITUPULU

Sex : Male

MR : 01022516

Visit : 15/03/2017

Comp. : INSPEKTINDO SINERGI PERSADA

DOB : 27 July 1974

EXAMINATION	RESULT
Thorax PA	No abnormality seen in both lungs. Normal bronchovascular markings in both hili. The heart is normal in size and shape. The mediastinum is not widened. Both sinus and diaphragms are good. No evidence of pleural effusion.
Impression	Normal chest. No evidence of specific process in both lungs.

RADIOLOGY DIAGNOSTIC

Name : TAMBOK PARSAULIAN NAPITUPULU	Sex : Male	MR : 01022516	Visit : 15/03/2017
Comp. : INSPEKTINDO SINERGI PERSADA			DOB : 27 July 1974

EXAMINATION	RESULT
-------------	--------

UPPER-LOWER ABDOMEN
SONOGRAPHY

LIVER:
Normal in size and contour, smooth surface, echoes structure parenchyme which are homogenous. No sign of SOL.
Intrahepatic vascularity and billiary tract are normal.

GALL BLADDER:
Normal in size, contour and surface. No sign of SOL/ sludge/ stone.

BOTH KIDNEYS:
Normal in size, contour and surface. No sign of obstruction/ stone/ SOL.

PANCREAS:
Normal in size, contour and surface. No sign of SOL.

LIEN:
Normal in size and contour, the echoes are homogenous. No sign of SOL.

URINARY BLADDER:
Normal in size, contour and surface. No sign of stone/ SOL.

PROSTATE AND VESICULA SEMINALIS:
Normal in size and contour which are homogenous echoes and no sign of focal lesion/ SOL.

Impression

Normal Sonography.

LABORATORY RESULT

Name : TAMBOK PARSAULIAN NAPITUPULU	MR : 01022516	Visit : 15/03/2017	#Lab : IN589027726009
Comp.: INSPEKTINDO SINERGI PERSADA	Sex : Male	DOB : 27 July 1974	
EXAMINATION	RESULT	NORMAL RANGE	

HEMATOLOGI

Automated Blood Count

White Blood Cell (WBC)	7.6	3.8 - 11.0
Erythrocyte (RBC)	4.8	4.4 - 5.9
Haemoglobin	14.9	13.2 - 17.3
Hematocrit	43	40 - 52
Thrombocytes	323	150 - 440

MCV, MCH, MCHC

MCV	89	80 - 100
MCH	31	26 - 34
MCHC	35.1	32 - 36
ESR	30 *	0 - 10

Differential Count

Basophils	0	0 - 1
Eosinophil	5 *	2 - 4
Bands / Stab	1 *	3 - 5
Neutrophils	49 *	50 - 70
Lymphocytes	37	25 - 40
Monocytes	8	2 - 8

BLD CHEMISTRY/LIPID PROFILE

Total Cholesterol	179	Normal/Desireable: <200 Borderline High: 200-239 High: >=240
HDL Cholesterol	40.0 *	Normal : >40 - <60 Low HDL : <40 Desireable : >=60
LDL Cholesterol	109	Optimal: <100 Near/Above Optimal: 100-129 Borderline High: 130-159 High: 160-189 Very High: >=190
Tryglicerides	150	Normal : <150 Borderline High: 150-199 High : 200-499 Very High : >=500

BLD CHEMISTRY/KIDNEY FUNCTION

Ureum	26.0	10.0 - 50.0
-------	------	-------------

LABORATORY RESULT

Name : TAMBOK PARSAULIAN NAPITUPULU MR : 01022516 Visit : 15/03/2017 #Lab : IN589027726009

Comp.: INSPEKTINDO SINERGI PERSADA Sex : Male DOB : 27 July 1974

EXAMINATION	RESULT	NORMAL RANGE
Creatinine	1.2	0.6- 1.3
Uric Acid	6.5	3.5 - 7.2

BLD CHEMISTRY/LIVER FUNCTION

Total Bilirubin	0.4	0.1 - 1.0
SGOT(AST)	17	13 - 45
SGPT (ALT)	27	13 - 50
Alkaline Phosphatase	90	30 - 120
Gamma GT	40	0 - 50
Albumin	4.7	3.5 - 5.5
Globulin	3.00	2.3 - 3.5
Total Protein	7.7	6.6 - 8.7

BLD CHEMISTRY/DIABETES**Fasting Glucose**

Glucose Fasting	104 *	< 100
Glucose Urine	Negative	Negative
Keton Urine	Negative	Negative

Blood Glucose 2 PP

Blood Sugar 2 Hours PP	96	< 140
Glucose Urine	Negative	Negative
Keton Urine	Negative	Negative

SEROLOGI / IMUNOLOGI

HBsAg	Non Reactive	Non Reactive
Anti HBs	Non Reactive	
VDRL	Negative	Negative

TOXICOLOGY - DRUGS SCREENING

THC/Marijuana	Negative	Negative
MDMA	Negative	Negative
Amphetamine	Negative	Negative
Opiat	Negative	Negative
Cocain	Negative	Negative
Alcohol	Negative	Negative

URINALYSIS**Complete Urine Analysis****Macroscopic**

Color	Yellow	
Turbidity	Clear	Clear
Specific Gravity	1.027	1.000 - 1.030

LABORATORY RESULT

Name : TAMBOK PARSAULIAN NAPITUPULU MR : 01022516 Visit : 15/03/2017 #Lab : IN589027726009

Comp.: INSPEKTINDO SINERGI PERSADA Sex : Male DOB : 27 July 1974

EXAMINATION	RESULT	NORMAL RANGE
pH	5.5	4.5 - 8.0
Leucocyte	Negative	Negative
Glucose	Negative	Negative
Nitrit	Negative	Negative
Bilirubin	Negative	Negative
Blood	Negative	Negative
Urobilinogen	Normal	Negative
Protein	Negative	Negative
Keton	Negative	Negative
Microscopic		
RBC	0-1	0 - 1
WBC	0-1	0 - 4
Cylinder	Negative	
Epithels Squamous	0-1	5 - 15
Crystals	Negative	
Bacteria	Negative	Negative
Others	Negative	

SPIROMETRY DIAGNOSTIC

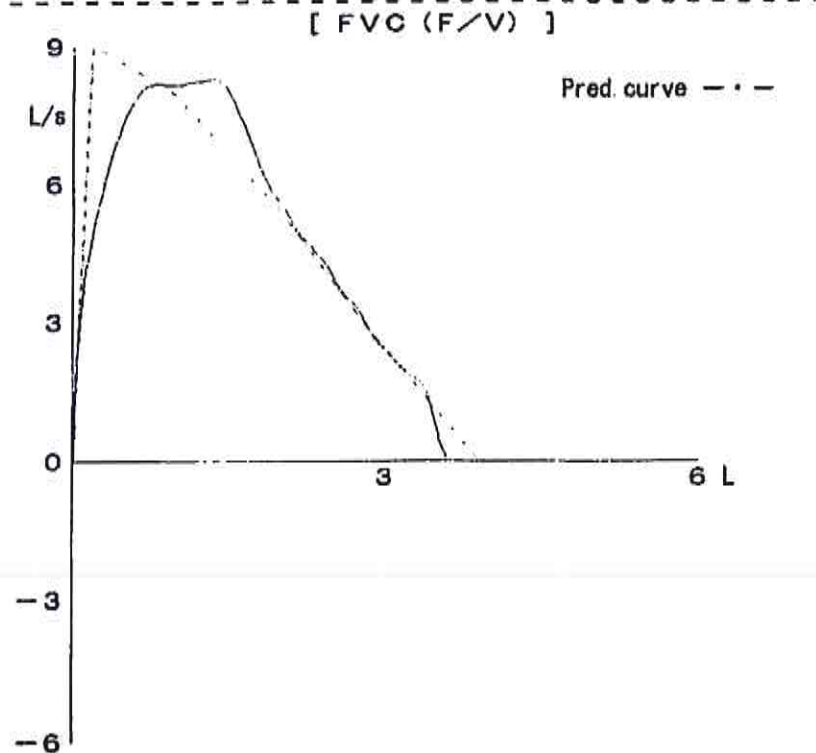
Name : TAMBOK PARSAULIAN NAPITUPULU	Sex : Male	MR : 01022516	Visit : 15/03/2017
Comp.: INSPEKTINDO SINERGI PERSADA		DOB : 27 July 1974	

EXAMINATION	RESULT
FVC Result	: 3.60 L---> 92.3 %
FEV1 Result	: 3.55 L---> 102.9 %
FEV1/FVC Result	: 98.89 %---> 129.9 %
PEF Result	: 8.26 L/S---> 79.1 %
Indonesian Standart Result	:
Index	:
Spirometry Result	: Normal

Impression : Normal Spirometric Functions

[COPD CLASSIFICATION]

FEV1/FVC : 98.89 %
 %FEV1.0 : 102.90 %
 Stage : Normal
 Recommended treatment by GOLD:



TAMBOK PARSAULIAN NAPITUPULU

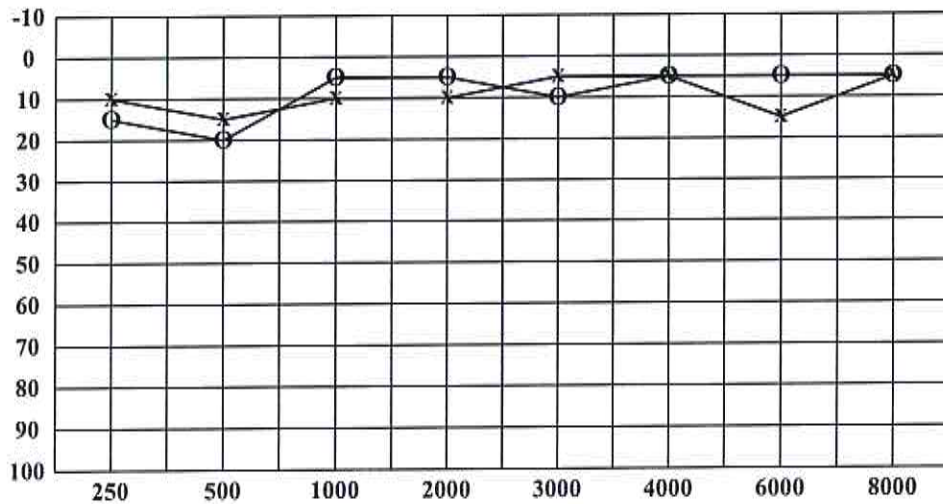
AUDIOMETRY DIAGNOSTIC

Name : TAMBOK PARSAULIAN NAPITUPULU	Sex : Male	MR : 01022516	Visit : 15/03/2017
Comp.: INSPEKTINDO SINERGI PERSADA		DOB : 27 July 1974	

RESULT

Left Ear	250	500	1000	2000	3000	4000	6000	8000
AC	10	15	10	10	5	5	15	5
BC	-	-	-	-	-	-	-	-

Right Ear	250	500	1000	2000	3000	4000	6000	8000
AC	15	20	5	5	10	5	5	5
BC	-	-	-	-	-	-	-	-



< : Right Ear (BC)
 > : Left Ear (BC)

 O : Right Ear (AC)
 X : Left Ear (AC)

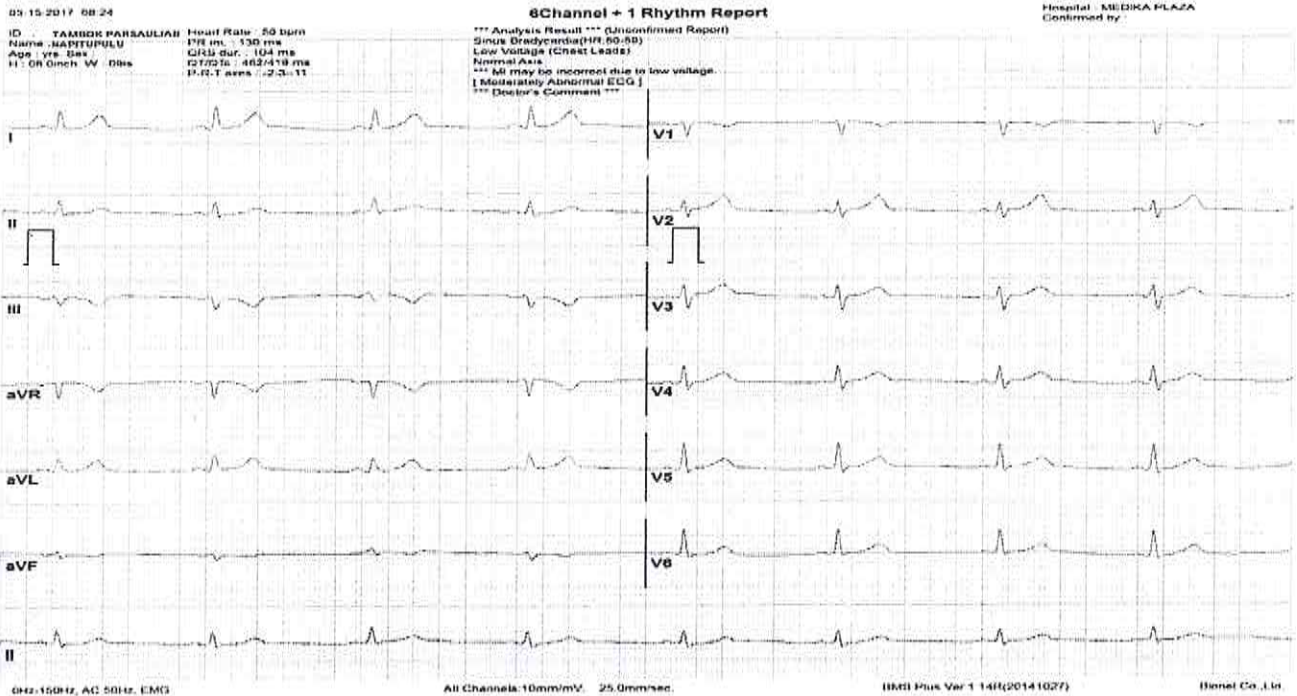
Conclusion Right Ear : Hearing threshold = 8.75 dB
(Within normal limit)

Conclusion Left Ear : Hearing threshold = 10 dB
(Within normal limit)

CARDIOLOGY DIAGNOSTIC

Name : TAMBOK PARSAULIAN NAPITUPULU	Sex : Male	MR : 01022516	Visit : 15/03/2017
Comp.: INSPEKTINDO SINERGI PERSADA		DOB : 27 July 1974	
EXAMINATION	RESULT	Comments :	

ELECTROCARDIOGRAPHY	Sinus Rythm axis (N), P wave (N), PR int 0.16" ST - T segment (N), aritmia (-)	Normal ECG
TREADMILL	Sinus Rythm axis (N), P wave (N), PR int 0.16" ST - T segment (N), aritmia (-)	Treadmill Exercise Test : Negative Cardiopulmonary Fitness Classification : Good METs : 11.6



Name: MR TAMBOX P
 ID: IINSPEKTINDO
 Date: 3/15/2017 07:54

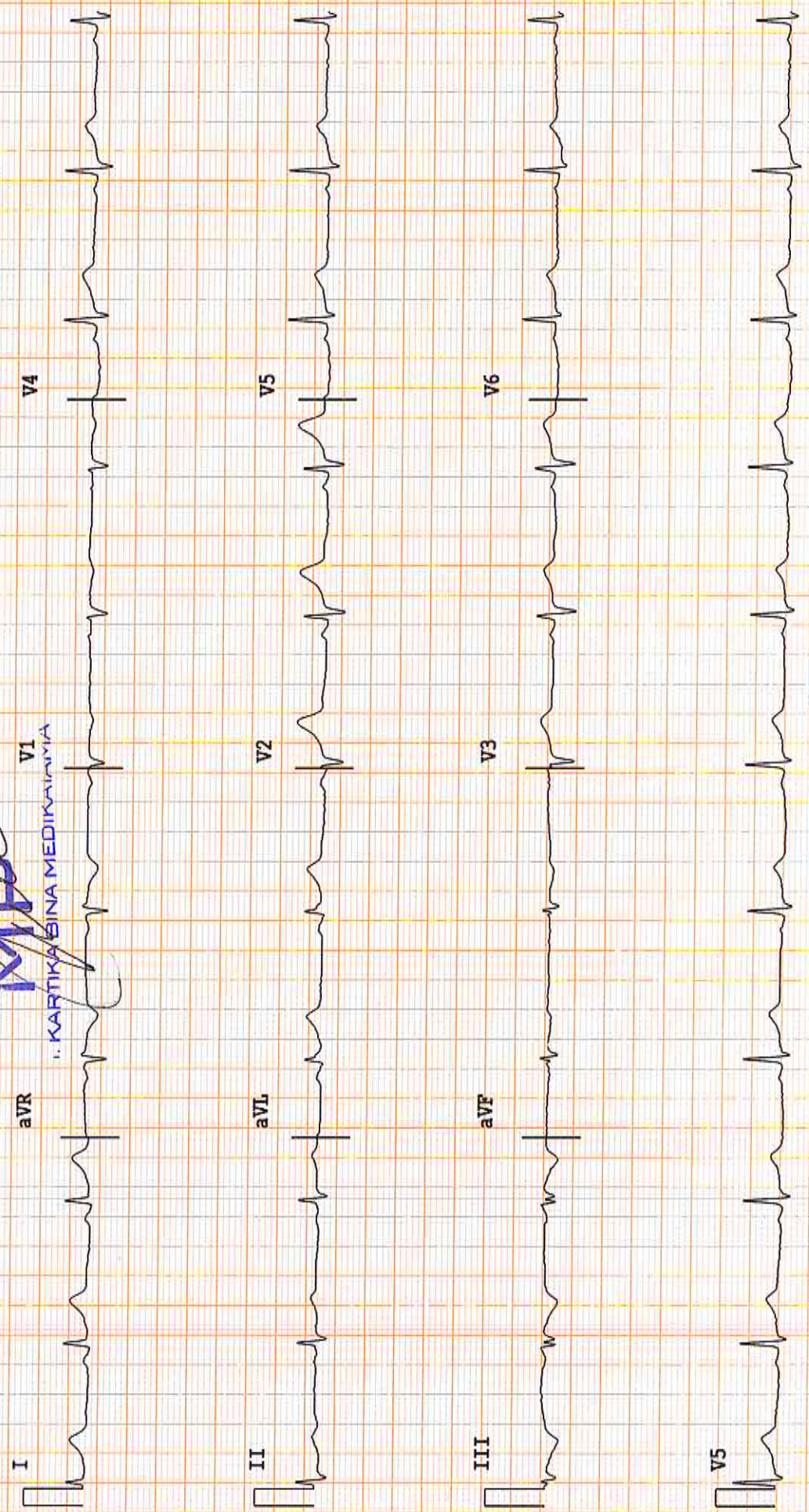
HR: 60
 BP: 100/70
 Medication(s): No Medication
 Age: 42 Years
 Clin. Class: No Medication
 Gender: Male
 Race: Oriental
 Height: 170 cm
 Weight: 84 Kg

Medication(s): No Medication
 Clin. Class: No Medication
 Department: MEDIKA PLAZA
 Technician: Mr. Jeni Emil
 Physician: Dr. Adolf DSJP

Baseline ECG

Levels measured at 80ms Post-J Levels in mm Slope in uV/mS

MP
 I. KARTIKA BINA MEDIKA PLAZA




Name: MR TAMBOK P
ID: IINSPEKTINDO

3/15/2017 07:57

Worst Case S-T Depression

HR: 108
BP: 100/70
RPE: 4.5
METs: 4.5
Phase: Exercise
Exercise Time: 02:50
Stage/Time: 1/02:50
Workload: 2.7 kmh 9.9 % grade
Protocol: Bruce

Baseline

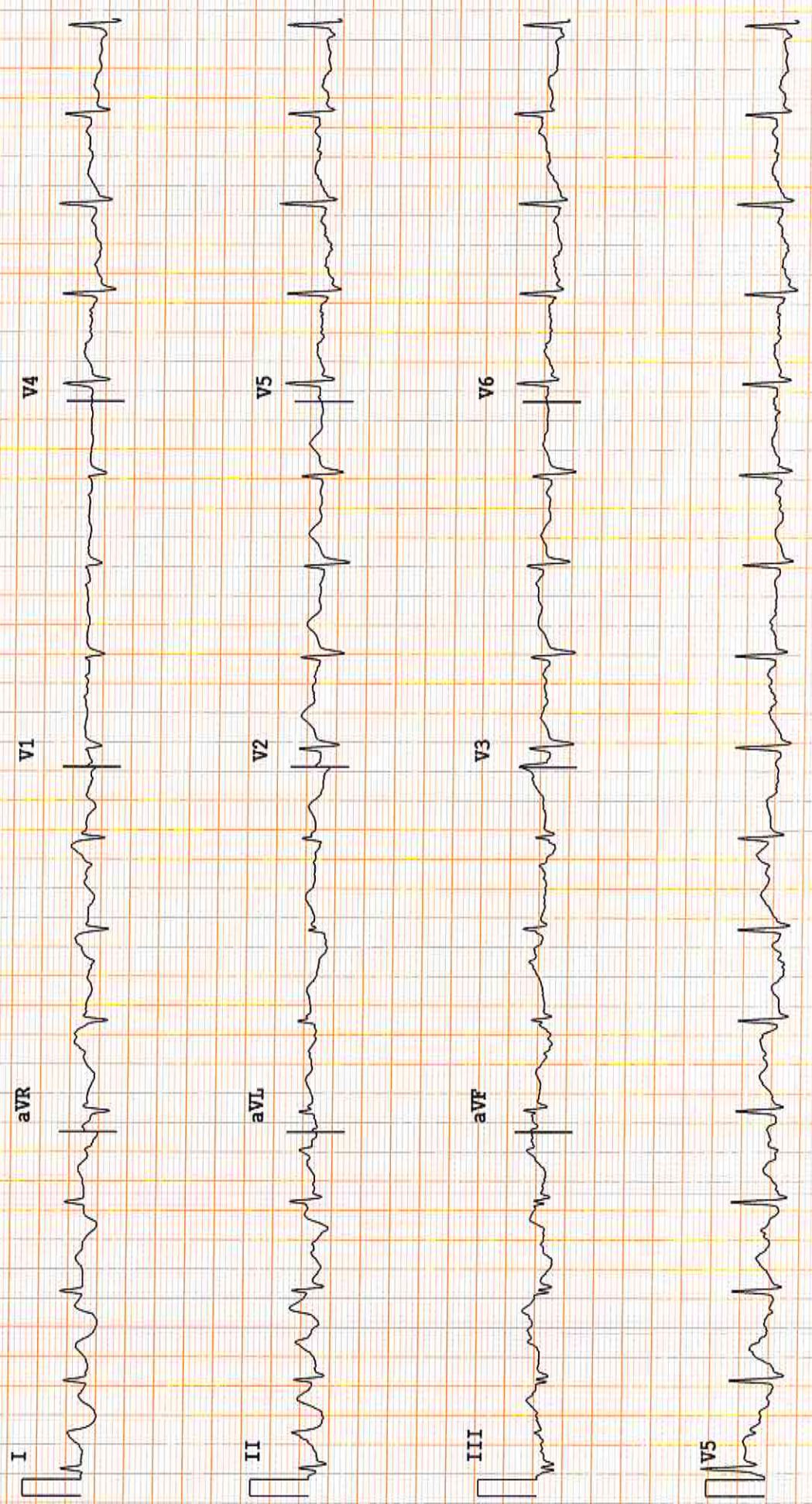


Current



III -0.9
L -0.9
S -0.5
J+80ms

III -0.7
L -0.7
S -0.7
J+80ms



Name: MR TAMBOK P
ID: IINSPEKTINDO

3/15/2017 08:00

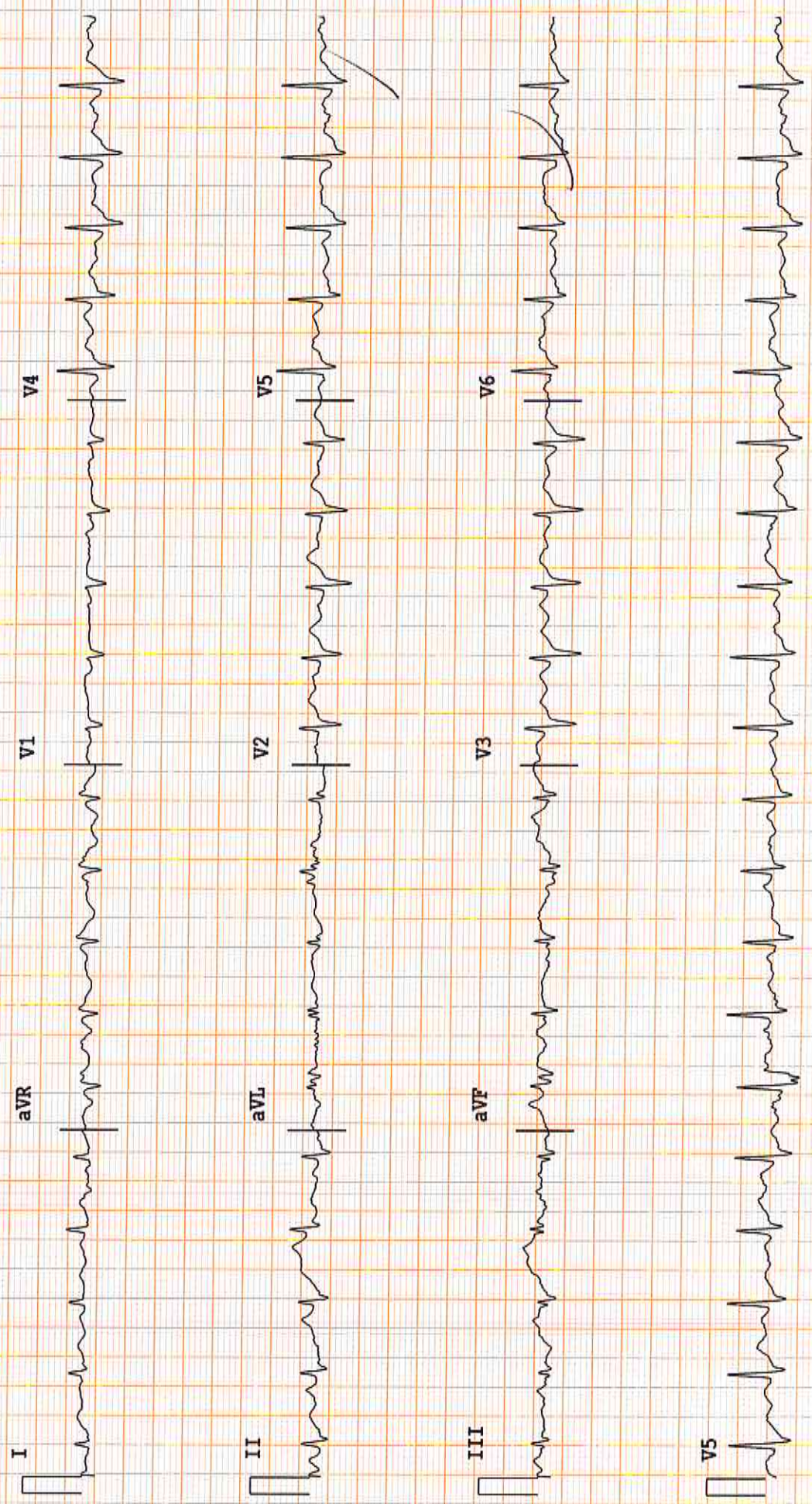
Worst Case S-T Depression

HR: 123 Phase: Exercise
BP: Exercise Time: 05:50
RPE: Stage/Time: 2/02:50
METs: 6.8 Workload: 4.0 kmh 12.0 % grade
Protocol: Bruce

Baseline Current



III L -0.9 S -0.5 J+80ms
III L -0.8 S 0.0 J+80ms



Name: MR TAMBOK P
ID: IINSPEKTINDO

3/15/2017 08:03:

Worst Case S-T Depression

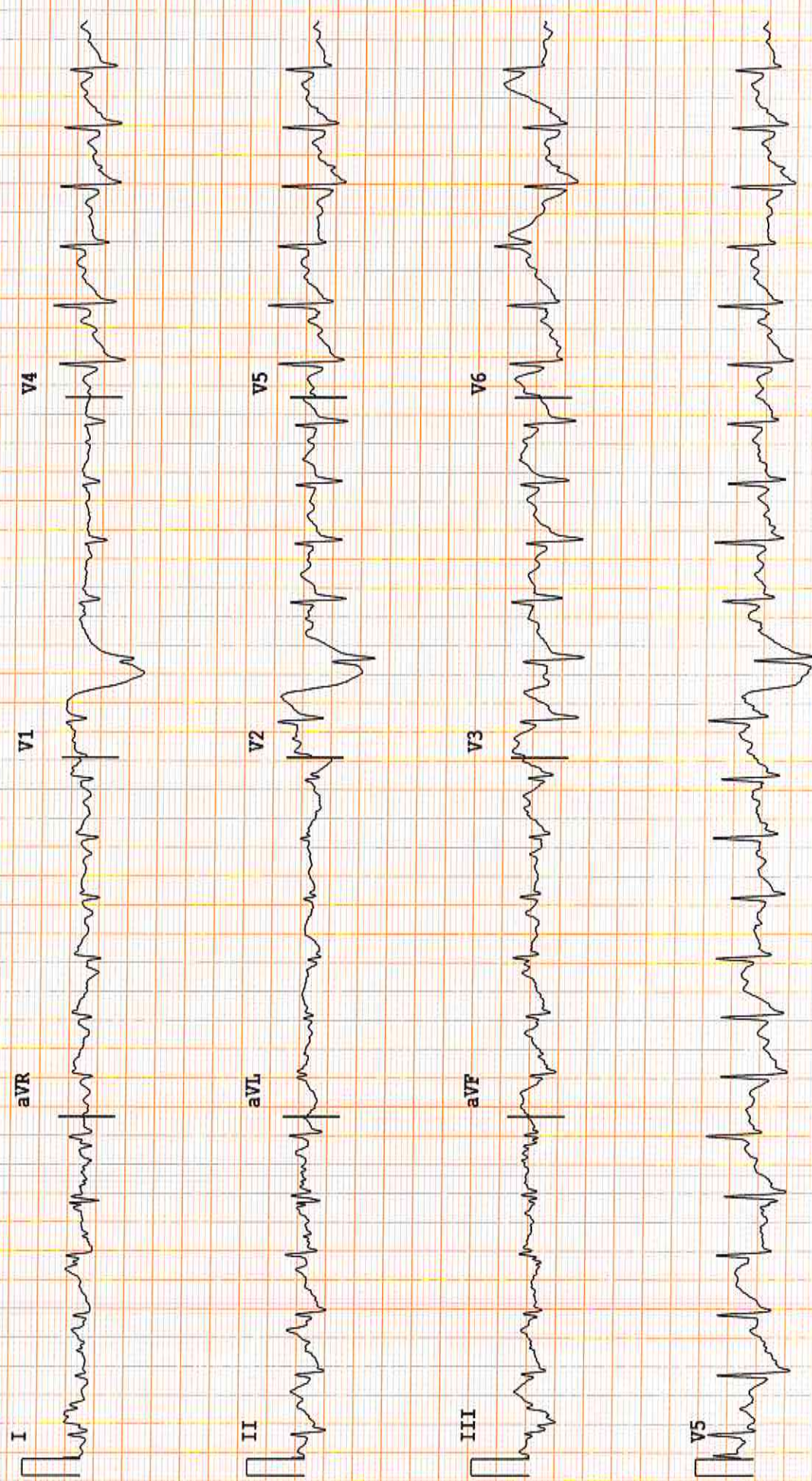
HR: 144 Phase: Exercise
BP: 130/90 Exercise Time: 08:50
RPE: Stage/Time: 3/02:50
METs: 9.9 Workload: 5.4 kmh 13.9 % grade
Protocol: Bruce

Baseline Current



III L -0.9
S -0.5
J+80ms

III L -0.7
S 0.1
J+80ms



Name: MR TAMBOK P
ID: IINSPEKTINDO

Worst Case S-T Depression

3/15/2017 08:04

HR: 168
BP: 130/90
RPE: 11.5
METs: 11.5
Maximum Exercise
Exercise Time: 10:00
Stage/Time: 4/01:00
Workload: 6.7 kmh 15.9 % grade
Protocol: Bruce

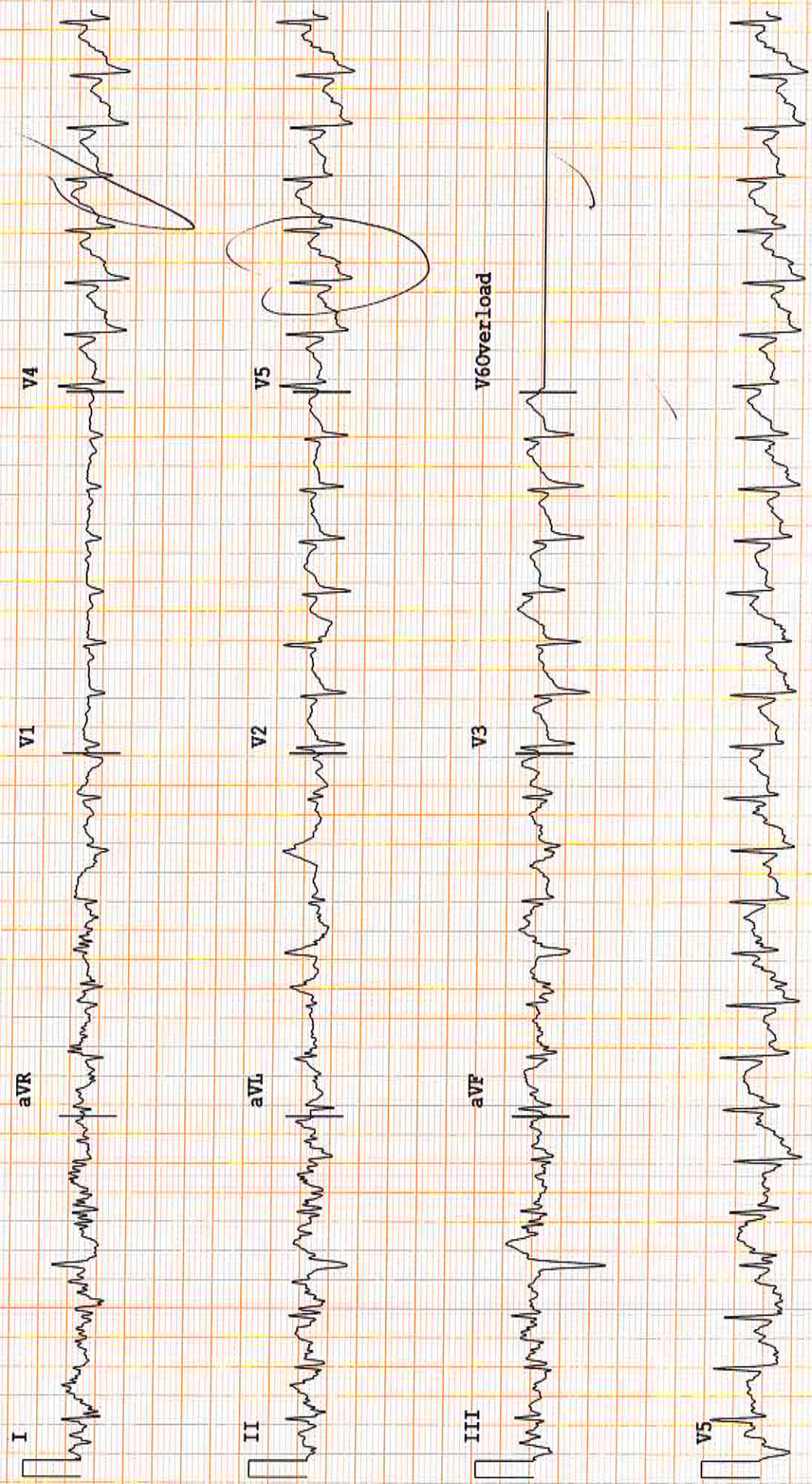
Baseline Current



III L -0.9
S -0.5
J+80ms

III L -1.2
S 0.2
J+80ms

MAXIMUM EXERCISE ECG



Name: MR TAMBOK P
ID: IINSPEKTINDO


3/15/2017 08:05

Worst Case S-T Depression

HR: 160 Phase: Recovery
BP: Exercise Time: 10:00
RPE: Stage/Time: -/00:27
Workload: 0.3 kmh 0.0 % grade
Protocol: Bruce

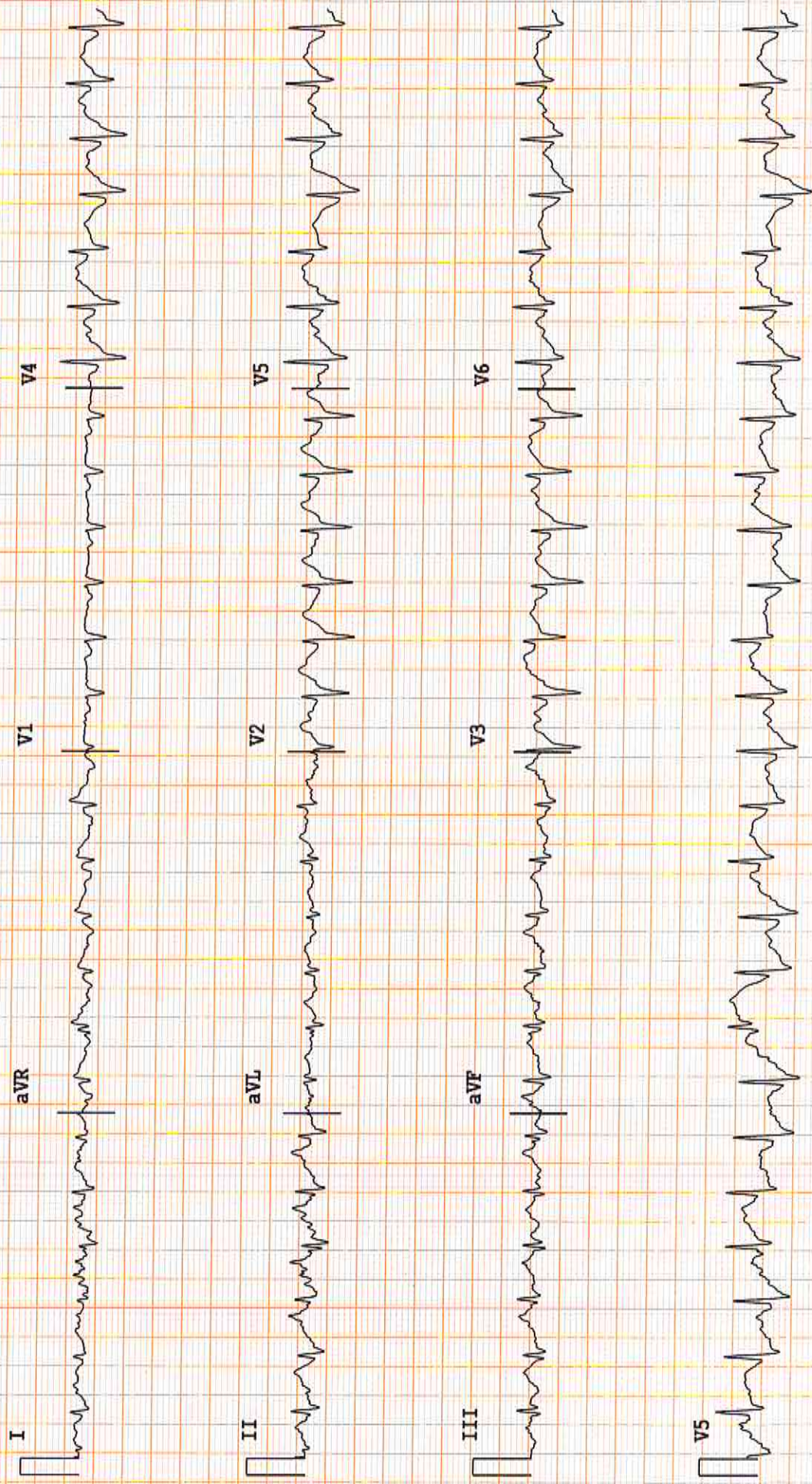
Baseline

Current



V4
L 0.4
S 0.4
J+80ms

V4
L -1.2
S 0.6
J+80ms



Name: MR TAMBOK P
ID: IINSPEKTINDO

3/15/2017 08:05

FINAL REPORT TEST SUMMARY

S-T SEGMENT ANALYSIS:
- Lead V4 first exhibited ST depression exceeding 1mm at 10:00 of Exercise.
- ST depression exceeded 1m at 00:30 mins.
- 1.7mm maximum depression was exhibited at 00:10 min Recovery.

SUMMARY:
- The Bruce test ran for 1.00 mins. Peak METs was 11.6.
- A peak heart rate of 168 bpm was achieved at 09:53 mins in exercise.
- 94% of the 178 bpm max was reached.
- The peak BP was 130/90 (during Exercise). Baseline was 100/70.

Medication(s): No Medication
: No Medication
Clin. Class: Normal
: Normal
Department: MEDIKA PLAZA
Technician: Nr. Jeni Emil
Physician: Dr. Adolf DSJP

Age: 42 Years
Gender: Male
Race: Oriental
Height: 170 cm
Weight: 84 Kg

Protocol: Bruce

TIME	PHASE	KMH	GRADE	HR	BP	RPP	METS	ECTOPIC	RPE	EVENTS
00:00	Exercise	0.4	0.0	60	100/70	60	1.0			
01:00	Exercise	2.7	9.9	95	100/70	95	2.1			Bruce
02:00	Exercise	2.7	9.9	98	100/70	98	4.3			
03:00	Exercise	2.7	9.9	97	100/70	97	4.5			
04:00	Exercise	4.0	12.0	115	110/80	126	5.6			
05:00	Exercise	4.0	12.0	122			6.8			
06:00	Exercise	4.0	12.0	123			6.8			
07:00	Exercise	5.4	13.9	135			8.4			
08:00	Exercise	5.4	13.9	142	130/90	184	9.8			
09:00	Exercise	5.4	13.9	146	130/90	189	9.9			
10:00	Max Exer.	6.7	15.9	167	130/90	217	11.5			
00:29	Recovery	0.0	0.0	159			9.3			

1

[Handwritten Signature]

MP4

I. KARTIKA BINA MEDIKA PLAZA



CONSULTATION SHEET

PATIENT NAME : Tn. Tambok Parsaulian

No. RM : 01022516

CHIR/MCU/HEU : E.N.T

To. Dokter :
(Counsel)

Kindly please counsel for patient who has take cares of

Diagnose :
Clinik Summary :

Counsel Request :

COUNSEL ADVISE

Finding : Ear : wide, no ear wax, tympanic membrane was intact
 Nose : wide, inferior turbinate was eutrophic, no septal deviation
 Throat : T1 - T1, not hyperaemic, posterior pharyngeal wall not hyperaemic.
 Neck : no cervical node enlargement

Diagnosis : ENT within normal limits

Recomendation : -

secretory

Right ear : normal hearing threshold
8.17 dB

Left ear : normal hearing threshold
10 dB

Date : March, 15 2017

Time : 10.00

EP :

Signataure

Dr. M. B. T. SPTHTTL

MP
Complete Name

PT. KARTIKA BINA MEDICAL

Formulir Number : FM - DR - 008 - 02

Revisi Number : 00

Date : 2 Mei 2011